PASSMEDICINE PART 2

# DERMATOLOGY

2024

A 32-year-old woman presents to her GP with a rash of several weeks, across the elbows and knees. She also mentions generalised tiredness. Upon examination, the following rash is noticed:

© Image used on license from DermNet NZ

Blood tests reveal iron-deficiency anaemia.

Given the most likely diagnosis, which of the following is an appropriate first-line option?

- Oral cetirizine
- Oral dapsone
- Oral prednisolone
- Topical clobetasol
- Topical tacrolimus

Submit answer

Reference ranges

Score: **0%**

**1** -

All contents of this site are © 2024 Passmedicine Limited

A 32-year-old woman presents to her GP with a rash of several weeks, across the elbows and knees. She also mentions generalised tiredness. Upon examination, the following rash is noticed:

© Image used on license from DermNet NZ

Blood tests reveal iron-deficiency anaemia.

Given the most likely diagnosis, which of the following is an appropriate first-line option?

| | |
|---|---|
| Oral cetirizine | 2% |
| Oral dapsone | 76% |
| Oral prednisolone | 11% |
| Topical clobetasol | 10% |
| Topical tacrolimus | 1% |

The diagnosis here is that of dermatitis herpetiformis. The photo above depicts a vesicular rash on an erythematous background, overlying an extensor surface (in this case, a knee). As in this photo, the lesions often appear somewhat excoriated due to the intense pruritus associated with the condition. The question also gives some additional clues by way of the tiredness and iron-deficiency anaemia - commonly present in coeliac disease, which is very strongly associated with dermatitis herpetiformis. First-line treatment involves the use of oral dapsone.

Oral cetirizine is inappropriate. Whilst useful for the alleviation of itch, it does not help to resolve the condition. If the diagnosis were instead prickly heat rash or urticaria, cetirizine would be the sole appropriate option.

Oral prednisolone may be used as a second- or third-line option if initial measures fail. However, with regards to initial management, oral dapsone is considered most effective for dermatitis herpetiformis.

Topical clobetasol is a second-line option for dermatitis herpetiformis, not first-line. It is first-line for bullous pemphigoid, which would appear quite differently - tense blisters would be visible, rather than the bullae seen here.

Topical tacrolimus is a steroid-sparing agent sometimes used in the management of steroid-resistant eczema, especially for children and on sensitive areas such as the face. It also plays a role in the management of bullous pemphigoid. It is not routinely used in dermatitis herpetiformis.

Discuss (4) Improve

Next question

# Dermatitis herpetiformis

Dermatitis herpetiformis is an autoimmune blistering skin disorder associated with coeliac disease. It is caused by deposition of IgA in the dermis. More than 90% of patients exhibit small bowel biopsy findings consistent with some degree of gluten-sensitive enteropathy.

Features

- itchy, vesicular skin lesions on the extensor surfaces (e.g. elbows, knees, buttocks)

Diagnosis

- skin biopsy: direct immunofluorescence shows deposition of IgA in a granular pattern in the upper dermis

Management

- gluten-free diet
- dapsone

+ Q 123

Next question

**Textbooks**

High-yield textbook

Extended textbook

## Links

DermNet NZ 34 6

Dermatitis herpetiformis

Suggest link Report broken link

Score: **14%**

| | |
|---|---|
| **1** | ✗ |
| 2 | ✗ |
| 3 | ✓ |
| 4 | ✗ |
| 5 | ✗ |
| 6 | ✗ |
| 7 | ✗ |
| 8 | ✗ |
| 9 | ✗ |
| 10 | ✗ |
| 11 | ✓ |
| 12 | ✗ |
| 13 | ✓ |
| 14 | ✗ |
| 15 | ✗ |
| 16 | ✗ |
| 17 | ✗ |
| 18 | ✗ |
| 19 | ✗ |
| 20 | ✗ |

| | |
|---|---|
| 21 | ✗ |
| 22 | ✗ |
| 23 | ✗ |
| 24 | ✗ |
| 25 | ✗ |
| 26 | ✓ |
| 27 | ✗ |
| 28 | ✗ |
| 29 | ✗ |
| 30 | ✗ |
| 31 | ✗ |
| 32 | ✓ |
| 33 | ✗ |
| 34 | ✗ |
| 35 | ✗ |
| 36 | ✗ |
| 37 | ✗ |
| 38 | ✗ |
| 39 | ✗ |
| 40 | ✗ |
| 41 | ✗ |
| 42 | ✗ |
| 43 | ✗ |
| 44 | ✓ |
| 45 | ✗ |
| 46 | ✗ |
| 47 | ✓ |
| 48 | ✗ |
| 49 | ✗ |
| 50 | ✗ |

All contents of this site are © 2024 Passmedicine Limited

A 45-year-old man has been referred to the dermatology clinic for a long-standing facial rash that has not been evaluated before. You note that multiple erythematous papules and pustules are present over his nose and cheeks in a centrofacial distribution. The consultant diagnoses him with moderate to severe papulopustular rosacea.

What is the most appropriate management of this patient?

- Oral isotretinoin
- Topical azelaic acid and oral isotretinoin
- Topical ivermectin
- Topical ivermectin and oral doxycycline
- Topical metronidazole and oral isotretinoin

Submit answer

Reference ranges

Score: **0%**

1 -
**2** -

All contents of this site are © 2024 Passmedicine Limited

A 45-year-old man has been referred to the dermatology clinic for a long-standing facial rash that has not been evaluated before. You note that multiple erythematous papules and pustules are present over his nose and cheeks in a centrofacial distribution. The consultant diagnoses him with moderate to severe papulopustular rosacea.

What is the most appropriate management of this patient?

| | |
|---|---|
| Oral isotretinoin | 2% |
| Topical azelaic acid and oral isotretinoin | 6% |
| Topical ivermectin | 12% |
| Topical ivermectin and oral doxycycline | 71% |
| Topical metronidazole and oral isotretinoin | 9% |

Rosacea: a combination of topical ivermectin + oral doxycycline is first-line for patients with severe papules and/or pustules

Important for me Less important

**Topical ivermectin and oral doxycycline** is the correct answer. Rosacea is a chronic skin disorder which primarily affects the central portion of the face. It is characterised by centrofacial erythema, papules, pustules flushing and telangiectasias. Ocular involvement may also be seen in the form of conjunctiva injection and lid telangiectasias. The management of rosacea is detailed in the notes linked to this question. This patient has been diagnosed with moderate-to-severe papulopustular disease, which is treated with a combination of topical ivermectin and oral doxycycline.

**Oral isotretinoin** is incorrect. Oral isotretinoin is not used as first-line therapy in rosacea. It is used only when patients fail to respond to topical therapies and oral antibiotics. Since this patient is treatment-naive, he should initially be prescribed the standard topical treatment along with an oral antibiotic.

**Topical azelaic acid and oral isotretinoin** is incorrect. Topical azelaic acid is used to treat mild-to-moderate rosacea with papules and pustules. Hence, it will not apply to this patient with a greater disease severity. As mentioned previously, isotretinoin is not to be used as a first-line treatment, making this an unlikely prescription for this patient.

**Topical ivermectin** is incorrect. It is a first-line therapy for mild-to-moderate papulopustular rosacea. This patient, however, has a more severe rosacea phenotype and will require a combination of topical therapy and an oral antibiotic like doxycycline.

**Topical metronidazole and oral isotretinoin** is incorrect. Topical metronidazole is another topical treatment used as first-line therapy for mild-to-moderate papulopustular rosacea. Isotretinoin is not used as first-line therapy, as explained previously. Hence, a combination of topical metronidazole and oral isotretinoin will not be suitable for this patient who has severe disease and is treatment naïve.

Discuss | Improve

Next question >

## Rosacea

Rosacea (sometimes referred to as acne rosacea) is a chronic skin disease of unknown aetiology.

Features
- typically affects nose, cheeks and forehead
- flushing is often first symptom
- telangiectasia are common
- later develops into persistent erythema with papules and pustules
- rhinophyma
- ocular involvement: blepharitis
- sunlight may exacerbate symptoms

Management
- simple measures
  - recommend daily application of a high-factor sunscreen
  - camouflage creams may help conceal redness
- predominant erythema/flushing

    - topical brimonidine gel may be considered for patients with predominant flushing but limited telangiectasia
    - brimonidine is a topical alpha-adrenergic agonist
    - this can be used on an 'as required basis' to temporarily reduce redness
    - it typically reduces redness within 30 minutes, reaching peak action at 3-6 hours, after which the redness returns to the baseline
- mild-to-moderate papules and/or pustules
    - topical ivermectin is first-line
    - alternatives include: topical metronidazole or topical azelaic acid
- moderate-to-severe papules and/or pustules
    - combination of topical ivermectin + oral doxycycline

Referral should be considered if
- symptoms have not improved with optimal management in primary care
    - laser therapy may be appropriate for patients with prominent telangiectasia
- patients with a rhinophyma

+ Q 123

Next question >

### Textbooks

High-yield textbook

Extended textbook

### Links

DermNet NZ 11 17

Rhinophyma

BNF 10 11

Acne rosacea

Dermnet NZ 23 13

Acne rosacea

Clinical Knowledge Summaries 19 10

Acne rosacea guidelines

Primary Care Dermatology Society 27 9

Rosacea review

Suggest link Report broken link

Score: **14%**

| | |
|---|---|
| 1 | ✗ |
| **2** | ✗ |
| 3 | ✓ |
| 4 | ✗ |
| 5 | ✗ |
| 6 | ✗ |
| 7 | ✗ |
| 8 | ✗ |
| 9 | ✗ |
| 10 | ✗ |
| 11 | ✓ |
| 12 | ✗ |
| 13 | ✓ |
| 14 | ✗ |
| 15 | ✗ |
| 16 | ✗ |

| | |
|---|---|
| 17 | ✗ |
| 18 | ✗ |
| 19 | ✗ |
| 20 | ✗ |
| 21 | ✗ |
| 22 | ✗ |
| 23 | ✗ |
| 24 | ✗ |
| 25 | ✗ |
| 26 | ✓ |
| 27 | ✗ |
| 28 | ✗ |
| 29 | ✗ |
| 30 | ✗ |
| 31 | ✗ |
| 32 | ✓ |
| 33 | ✗ |
| 34 | ✗ |
| 35 | ✗ |
| 36 | ✗ |
| 37 | ✗ |
| 38 | ✗ |
| 39 | ✗ |
| 40 | ✗ |
| 41 | ✗ |
| 42 | ✗ |
| 43 | ✗ |
| 44 | ✓ |
| 45 | ✗ |
| 46 | ✗ |
| 47 | ✓ |
| 48 | ✗ |
| 49 | ✗ |
| 50 | ✗ |

All contents of this site are © 2024 Passmedicine Limited

A 21-year-old man presents with an itchy rash around 2 weeks after a brief illness with mild fever and malaise. He first noticed a scaly patch on his chest around 2cm in diameter, and 2 days later developed the lesions as shown in the image. He is otherwise well.

© Image used on license from DermNet NZ

What virus has been hypothesized to be a trigger for this condition?

- Adenovirus
- Cytomegalovirus
- Enterovirus
- Epstein Barr virus
- Human herpes virus 7

Submit answer

A 21-year-old man presents with an itchy rash around 2 weeks after a brief illness with mild fever and malaise. He first noticed a scaly patch on his chest around 2cm in diameter, and 2 days later developed the lesions as shown in the image. He is otherwise well.

© Image used on license from DermNet NZ

What virus has been hypothesized to be a trigger for this condition?

| | |
|---|---|
| Adenovirus | 9% |
| Cytomegalovirus | 2% |
| Enterovirus | 3% |
| Epstein Barr virus | 13% |
| Human herpes virus 7 | 73% |

This patient has pityriasis rosea. This is a self-limiting skin condition that presents numerous itchy, scaly oval lesions, mainly on the trunk and proximal aspects of the limbs. In over half the cases, the

rash is preceded by the appearance of a 'herald patch' which is a larger lesion around 2-5cm in diameter and which appears around 2 days before the onset of the wider rash. Pityriasis rosea occurs mainly in older children and young adults.

The trigger for the rash is not definitively known but a viral cause is thought likely given that many cases are preceded by a viral-type illness with fever, malaise, headache, and sore throat and because cases can occur in clusters or outbreaks. The strongest evidence is for an association with **human herpes virus 7** (HHV7). This is a similar virus to human herpes virus 6 (HHV6), both of which cause exanthem subitum (also called roseola) in infants, as well as a non-specific febrile illness in older children.

**Adenovirus** is incorrect. This virus can cause a range of presentations, including conjunctivitis, pharyngitis, and gastroenteritis, but there is no known association with pityriasis rosea.

**Cytomegalovirus** is incorrect. This virus is also in the herpes virus family. It can cause an acute febrile illness similar to infectious mononucleosis and is associated with complications in immune-suppressed patients or pregnant women, but no association has been shown with pityriasis rosea.

**Enterovirus** is incorrect. This is a group of viruses that can a range of conditions including gastroenteritis, meningitis/encephalitis, hand foot, and mouth disease, and non-specific rashes. They are not thought to be a trigger for pityriasis rosea.

**Epstein Barr virus** is incorrect. This is again a herpes virus, but it is not known to trigger pityriasis rosea.

Discuss Improve

Next question

## Pityriasis rosea

Pityriasis rosea describes an acute, self-limiting rash which tends to affect young adults. The aetiology is not fully understood but is thought that herpes hominis virus 7 (HHV-7) may play a role.

Features
- in the majority of patients there is no prodrome, but a minority may give a history of a recent viral infection
- herald patch (usually on trunk)
- followed by erythematous, oval, scaly patches which follow a characteristic distribution with the longitudinal diameters of the oval lesions running parallel to the line of Langer. This may

produce a 'fir-tree' appearance

Management

- self-limiting - usually disappears after 6-12 weeks

## Differentiating guttate psoriasis and pityriasis rosea

| | Guttate psoriasis | Pityriasis rosea |
|---|---|---|
| **Prodrome** | Classically preceded by a streptococcal sore throat 2-4 weeks | Many patients report recent respiratory tract infections but this is not common in questions |
| **Appearance** | 'Tear drop', scaly papules on the trunk and limbs | Herald patch followed 1-2 weeks later by multiple erythematous, slightly raised oval lesions with a fine scale confined to the outer aspects of the lesions.<br><br>May follow a characteristic distribution with the longitudinal diameters of the oval lesions running parallel to the line of Langer. This may produce a 'fir-tree' appearance |
| **Treatment / natural history** | Most cases resolve spontaneously within 2-3 months<br>Topical agents as per | Self-limiting, resolves after around 6 weeks |

| | Guttate psoriasis | Pityriasis rosea |
|---|---|---|
| | psoriasis<br>UVB phototherapy | |

123

Next question

Textbooks

High-yield textbook

Extended textbook

Links

Clinical Knowledge Summaries 9 6

Pityriasis rosea

DermNet NZ 11 4

Pityriasis rosea

Suggest link

Report broken link

Score: **14%**

1 ✗

| | |
|---|---|
| 2 | ✗ |
| **3** | ✓ |
| 4 | ✗ |
| 5 | ✗ |
| 6 | ✗ |
| 7 | ✗ |
| 8 | ✗ |
| 9 | ✗ |
| 10 | ✗ |
| 11 | ✓ |
| 12 | ✗ |
| 13 | ✓ |
| 14 | ✗ |
| 15 | ✗ |
| 16 | ✗ |
| 17 | ✗ |
| 18 | ✗ |
| 19 | ✗ |
| 20 | ✗ |
| 21 | ✗ |
| 22 | ✗ |
| 23 | ✗ |
| 24 | ✗ |
| 25 | ✗ |
| 26 | ✓ |
| 27 | ✗ |
| 28 | ✗ |
| 29 | ✗ |
| 30 | ✗ |
| 31 | ✗ |
| 32 | ✓ |
| 33 | ✗ |
| 34 | ✗ |
| 35 | ✗ |
| 36 | ✗ |
| 37 | ✗ |

| | |
|---|---|
| 38 | ✗ |
| 39 | ✗ |
| 40 | ✗ |
| 41 | ✗ |
| 42 | ✗ |
| 43 | ✗ |
| 44 | ✓ |
| 45 | ✗ |
| 46 | ✗ |
| 47 | ✓ |
| 48 | ✗ |
| 49 | ✗ |
| 50 | ✗ |

All contents of this site are © 2024 Passmedicine Limited

A 34-year-old male sex worker presents with a sudden onset of a flaky, erythematous rash affecting his nasolabial folds and upper chest. He has also noticed dandruff, which has not previously been an issue.

On examination, there is fissuring behind his ears and yellow scaling between his eyelashes.

© Image used on license from DermNet NZ

What investigation is most likely to diagnose the underlying condition predisposing to this patient's skin changes?

- Anti-dsDNA antibodies
- HIV serology
- Hepatitis B serology
- Oral glucose tolerance test
- Treponemal EIA

Submit answer

Reference ranges

Score: **0%**

| | |
|---|---|
| 1 | - |
| 2 | - |
| 3 | - |
| **4** | - |

All contents of this site are © 2024 Passmedicine Limited

Back to top

A 34-year-old male sex worker presents with a sudden onset of a flaky, erythematous rash affecting his nasolabial folds and upper chest. He has also noticed dandruff, which has not previously been an issue.

On examination, there is fissuring behind his ears and yellow scaling between his eyelashes.

© Image used on license from DermNet NZ

What investigation is most likely to diagnose the underlying condition predisposing to this patient's skin changes?

| | |
|---|---|
| Anti-dsDNA antibodies | 0% |
| HIV serology | 33% |
| Hepatitis B serology | 0% |
| Oral glucose tolerance test | 0% |
| Treponemal EIA | 67% |

The patient in this scenario presents with seborrhoeic dermatitis. While seborrhoeic dermatitis is commonly seen in individuals without underlying medical conditions, it occurs more frequently in immunocompromised patients, particularly those with HIV. Therefore, **HIV serology** testing is recommended to exclude HIV as a predisposing factor, especially given the patient's increased risk

as a male sex worker.

**Anti-dsDNA antibodies** are highly specific to systemic lupus erythematosus (SLE). Although SLE can present with various skin manifestations, such as a malar or discoid rash, it does not cause seborrhoeic dermatitis. Therefore, testing for anti-dsDNA antibodies would be inappropriate in this case.

While it would be prudent to test for hepatitis B given the patient's risk of blood-borne viruses, hepatitis B does not cause seborrhoeic dermatitis. Thus, **hepatitis B serology** is less appropriate than HIV serology. Hepatitis B can present with skin manifestations like erythema nodosum, erythema multiforme, and urticaria, but not seborrhoeic dermatitis.

Diabetes mellitus can present with skin conditions such as diabetic dermopathy, acanthosis nigricans, and necrobiosis lipoidica; however, seborrhoeic dermatitis is not associated with diabetes. An **oral glucose tolerance test** would therefore be unnecessary, as it would not help diagnose the skin condition and there are no indications of diabetes in the patient's history.

While testing for syphilis may be advisable for a sex worker, syphilis does not cause seborrhoeic dermatitis. **Treponema EIA** testing is therefore also incorrect, as seborrhoeic dermatitis is more likely to be related to HIV. Syphilis has characteristic skin manifestations, including the primary chancre and the rash found on the soles of the feet and palms of the hands in secondary syphilis.

Discuss Improve

Next question

# Seborrhoeic dermatitis in adults

Seborrhoeic dermatitis in adults is a chronic dermatitis thought to be caused by an inflammatory reaction related to a proliferation of a normal skin inhabitant, a fungus called *Malassezia furfur* (formerly known as *Pityrosporum ovale*). It is common, affecting around 2% of the general population.

Features

- eczematous lesions on the sebum-rich areas: scalp (may cause dandruff), periorbital, auricular and nasolabial folds
- otitis externa and blepharitis may develop

Associated conditions include

- HIV
- Parkinson's disease

Scalp disease management

- the first-line treatment is ketoconazole 2% shampoo
- over the counter preparations containing zinc pyrithione ('Head & Shoulders') and tar ('Neutrogena T/Gel') may be used if ketoconazole is not appropriate or acceptable to the person
- selenium sulphide and topical corticosteroid may also be useful

Face and body management

- topical antifungals: e.g. ketoconazole
- topical steroids: best used for short periods
- difficult to treat - recurrences are common

AI + Q 123

Next question >

**Textbooks**

High-yield textbook

Extended textbook

**Links**

Clinical Knowledge Summaries 20 11

Seborrhoeic dermatitis guidelines

DermNet NZ 24 4

Overview and pictures of seborrhoeic dermatitis

Suggest link Report broken link

Score: **14%**

| | |
|---|---|
| 1 | ✗ |
| 2 | ✗ |
| 3 | ✓ |
| **4** | ✗ |
| 5 | ✗ |
| 6 | ✗ |
| 7 | ✗ |
| 8 | ✗ |
| 9 | ✗ |
| 10 | ✗ |
| 11 | ✓ |
| 12 | ✗ |
| 13 | ✓ |
| 14 | ✗ |
| 15 | ✗ |
| 16 | ✗ |
| 17 | ✗ |
| 18 | ✗ |
| 19 | ✗ |
| 20 | ✗ |
| 21 | ✗ |

| | |
|---|---|
| 22 | ✗ |
| 23 | ✗ |
| 24 | ✗ |
| 25 | ✗ |
| 26 | ✓ |
| 27 | ✗ |
| 28 | ✗ |
| 29 | ✗ |
| 30 | ✗ |
| 31 | ✗ |
| 32 | ✓ |
| 33 | ✗ |
| 34 | ✗ |
| 35 | ✗ |
| 36 | ✗ |
| 37 | ✗ |
| 38 | ✗ |
| 39 | ✗ |
| 40 | ✗ |
| 41 | ✗ |
| 42 | ✗ |
| 43 | ✗ |
| 44 | ✓ |
| 45 | ✗ |
| 46 | ✗ |
| 47 | ✓ |
| 48 | ✗ |
| 49 | ✗ |
| 50 | ✗ |

All contents of this site are © 2024 Passmedicine Limited

A 82-year-old man is reviewed in dermatology clinic as part of ongoing treatment for metastatic melanoma. He had been diagnosed with melanoma three years previously after resection of a lesion on his left shoulder. Surgical margins had been satisfactory, however a metastatic lesion had been identified in the patient's liver four months prior to the present day. Following oncology MDT discussion, patient had been treated with vemurafenib. Initial follow-up with repeat abdominal CT scan had demonstrated an excellent response with dramatic reduction in size of metastatic deposit.

The patient reported continuing to feel well in himself. However, he was concerned about a new skin lesion he had noticed on his right thigh. While he could not recall exactly when this lesion had first appeared, he was confident that it had been present for less than two months. It had not been present during a full dermatological examination at the previous clinic appointment three months previously. The patient reported that the lesion was a bit uncomfortable when he caught it on his trousers but denied any other symptoms.

Examination of the lesion on the patient's thigh revealed a 11 mm diameter erythematous papule with minimally everted edges. A slight scale was noted on the surface of the lesion. There was no evidence of telangiectasia associated with the lesion. Examination of the inguinal lymph nodes was unremarkable.

Following assessment in clinic, a biopsy of the lesion was taken. What is the most likely diagnosis following histological examination of the biopsy specimen?

- Melanoma
- Merkel cell carcinoma
- Squamous cell carcinoma
- Atypical fibroxanthoma
- Keratocanthoma

Submit answer

Reference ranges

Score: **0%**

1 -
2 -
3 -
4 -
**5** -

All contents of this site are © 2024 Passmedicine Limited

A 82-year-old man is reviewed in dermatology clinic as part of ongoing treatment for metastatic melanoma. He had been diagnosed with melanoma three years previously after resection of a lesion on his left shoulder. Surgical margins had been satisfactory, however a metastatic lesion had been identified in the patient's liver four months prior to the present day. Following oncology MDT discussion, patient had been treated with vemurafenib. Initial follow-up with repeat abdominal CT scan had demonstrated an excellent response with dramatic reduction in size of metastatic deposit.

The patient reported continuing to feel well in himself. However, he was concerned about a new skin lesion he had noticed on his right thigh. While he could not recall exactly when this lesion had first appeared, he was confident that it had been present for less than two months. It had not been present during a full dermatological examination at the previous clinic appointment three months previously. The patient reported that the lesion was a bit uncomfortable when he caught it on his trousers but denied any other symptoms.

Examination of the lesion on the patient's thigh revealed a 11 mm diameter erythematous papule with minimally everted edges. A slight scale was noted on the surface of the lesion. There was no evidence of telangiectasia associated with the lesion. Examination of the inguinal lymph nodes was unremarkable.

Following assessment in clinic, a biopsy of the lesion was taken. What is the most likely diagnosis following histological examination of the biopsy specimen?

| | |
|---|---|
| Melanoma | 6% |
| Merkel cell carcinoma | 10% |
| Squamous cell carcinoma | 50% |
| Atypical fibroxanthoma | 10% |
| Keratocanthoma | 24% |

Vemurafenib and dabrafenib are selective BRAF inhibitors that increase overall survival in metastatic melanoma. These drugs paradoxically activates the MAPK pathway in keratinocytes and so can cause squamous cell carcinomas, often within the first three months of therapy. The risk of squamous cell carcinoma with vemurafenib and dabrafenib is higher in older patients and they can

occur in sun-protected sites.

Given the typical appearance of the above lesion and the recent treatment with vemurafenib, the most likely histology of the lesion in this case is squamous cell carcinoma. Melanoma is less likely due to the atypical appearance and apparent good treatment response to vemurafenib.

The description of the lesion is not consistent with the typical appearance of the other possible answers.

Aslam A, Patel A. Facial cutaneous squamous cell carcinoma. BMJ 2016;352:i1513.

Discuss (8) Improve

Next question

## Squamous cell carcinoma of the skin

Squamous cell carcinoma is a common variant of skin cancer. Metastases are rare but may occur in 2-5% of patients.

Risk factors include:

- excessive exposure to sunlight / psoralen UVA therapy
- actinic keratoses and Bowen's disease
- immunosuppression e.g. following renal transplant, HIV
- smoking
- long-standing leg ulcers (Marjolin's ulcer)
- genetic conditions e.g. xeroderma pigmentosum, oculocutaneous albinism

Features

- typically on sun-exposed sites such as the head and neck or dorsum of the hands and arms
- rapidly expanding painless, ulcerate nodules
- may have a cauliflower-like appearance
- there may be areas of bleeding

## Image gallery

## Treatment

Surgical excision with 4mm margins if lesion <20mm in diameter. If tumour >20mm then margins should be 6mm. Mohs micrographic surgery may be used in high-risk patients and in cosmetically important sites.

## Prognosis

| Good Prognosis | Poor prognosis |
|---|---|
| Well differentiated tumours | Poorly differentiated tumours |
| <20mm diameter | >20mm in diameter |
| <2mm deep | >4mm deep |
| No associated diseases | Immunosupression for whatever reason |

123

Next question

## Textbooks

High-yield textbook

Extended textbook

## Links

DermNet NZ 28 4

Squamous cell carcinoma

Suggest link Report broken link

## Media

Skin cancers

Osmosis - YouTube 4 1

Report broken media

Score: **14%**

1 ✗
2 ✗
3 ✓
4 ✗
**5** ✗
6 ✗
7 ✗
8 ✗
9 ✗

| | |
|---|---|
| 10 | ✗ |
| 11 | ✓ |
| 12 | ✗ |
| 13 | ✓ |
| 14 | ✗ |
| 15 | ✗ |
| 16 | ✗ |
| 17 | ✗ |
| 18 | ✗ |
| 19 | ✗ |
| 20 | ✗ |
| 21 | ✗ |
| 22 | ✗ |
| 23 | ✗ |
| 24 | ✗ |
| 25 | ✗ |
| 26 | ✓ |
| 27 | ✗ |
| 28 | ✗ |
| 29 | ✗ |
| 30 | ✗ |
| 31 | ✗ |
| 32 | ✓ |
| 33 | ✗ |
| 34 | ✗ |
| 35 | ✗ |
| 36 | ✗ |
| 37 | ✗ |
| 38 | ✗ |
| 39 | ✗ |
| 40 | ✗ |
| 41 | ✗ |
| 42 | ✗ |
| 43 | ✗ |
| 44 | ✓ |
| 45 | ✗ |

| | |
|---|---|
| 46 | ✗ |
| 47 | ✓ |
| 48 | ✗ |
| 49 | ✗ |
| 50 | ✗ |

All contents of this site are © 2024 Passmedicine Limited

A 35-year-old man is reviewed in the medical clinic. He has severe eczema and over the last two weeks has had a flare of eczema which the GP has been unable to manage. He normally manages his condition with emollients and hydrocortisone 1%, but has noted worsening flexural irritation and pruritus. He denies any systemic symptoms. He also has a past medical history of asthma for which he rarely needs his salbutamol inhaler, and hay-fever. He takes no oral medications. He has a previous dermatology appointment letter which advises that if his eczema remains poorly controlled he should have a short course of a moderate topical steroid. Which prescription is most appropriate?

On examination, he has macular erythema of his flexural surfaces, especially elbow and knee creases.

- Clobetasone butyrate 0.05% (Eumovate)
- Betamethasone valerate 0.1% (Betnovate)
- Fluticasone propionate 0.05% (Cutivate)
- Clobetasol propionate 0.05% (Dermovate)
- Hydrocortisone 2.5%

Submit answer

Reference ranges

Score: **0%**

1 -
2 -
3 -
4 -

| | |
|---|---|
| 5 | - |
| 6 | - |

All contents of this site are © 2024 Passmedicine Limited

A 35-year-old man is reviewed in the medical clinic. He has severe eczema and over the last two weeks has had a flare of eczema which the GP has been unable to manage. He normally manages his condition with emollients and hydrocortisone 1%, but has noted worsening flexural irritation and pruritus. He denies any systemic symptoms. He also has a past medical history of asthma for which he rarely needs his salbutamol inhaler, and hay-fever. He takes no oral medications. He has a previous dermatology appointment letter which advises that if his eczema remains poorly controlled he should have a short course of a moderate topical steroid. Which prescription is most appropriate?

On examination, he has macular erythema of his flexural surfaces, especially elbow and knee creases.

| | |
|---|---|
| Clobetasone butyrate 0.05% (Eumovate) | 37% |
| Betamethasone valerate 0.1% (Betnovate) | 33% |
| Fluticasone propionate 0.05% (Cutivate) | 4% |
| Clobetasol propionate 0.05% (Dermovate) | 21% |
| Hydrocortisone 2.5% | 3% |

Clobetasol is the most potent topical steroid compared to clobetasone, betamethasone valarate and hydrocortisone

Important for me    Less important

This patient has poorly controlled eczema and needs a moderate strength topical steroid. This question tests knowledge of the strength of different topical steroids. This can be important as the level of systemic absorption can become significant with higher dose topical steroid creams and also stronger topical treatments should not be applied to sensitive skin due to the potential of skin thinning.

Discuss (6)    Improve

Next question

# Eczema: topical steroids

Use the weakest steroid cream which controls patient's symptoms

The table below shows topical steroids by potency

| Mild | Moderate | Potent | Very potent |
|---|---|---|---|
| Hydrocortisone 0.5-2.5% | Betamethasone valerate 0.025% (Betnovate RD)<br><br>Clobetasone butyrate 0.05% (Eumovate) | Fluticasone propionate 0.05% (Cutivate)<br><br>Betamethasone valerate 0.1% (Betnovate) | Clobetasol propionate 0.05% (Dermovate) |

Finger tip rule

- 1 finger tip unit (FTU) = 0.5 g, sufficient to treat a skin area about twice that of the flat of an adult hand

Topical steroid doses for eczema in adults

| Area of skin | Fingertip units per dose |
|---|---|
| Hand and fingers (front and back) | 1.0 |
| A foot (all over) | 2.0 |
| Front of chest and abdomen | 7.0 |
| Back and buttocks | 7.0 |
| Face and neck | 2.5 |
| An entire arm and hand | 4.0 |
| An entire leg and foot | 8.0 |

The BNF makes recommendation on the quantity of topical steroids that should be prescribed for an adult for a single daily application for 2 weeks:

| Area | Amount |
|---|---|
| Face and neck | 15 to 30 g |
| Both hands | 15 to 30 g |
| Scalp | 15 to 30 g |
| Both arms | 30 to 60 g |
| Both legs | 100 g |
| Trunk | 100 g |
| Groin and genitalia | 15 to 30 g |

+ Q 123

Next question >

## Textbooks

High-yield textbook

Extended textbook

## Links

Clinical Knowledge Summaries 8 10

Atopic eczema

British Association of Dermatologists 7 8

Atopic eczema guidelines

Suggest link | Report broken link

Score: **14%**

| | |
|---|---|
| 1 | ✗ |
| 2 | ✗ |
| 3 | ✓ |
| 4 | ✗ |
| 5 | ✗ |
| **6** | ✗ |
| 7 | ✗ |
| 8 | ✗ |
| 9 | ✗ |
| 10 | ✗ |
| 11 | ✓ |
| 12 | ✗ |
| 13 | ✓ |
| 14 | ✗ |
| 15 | ✗ |
| 16 | ✗ |
| 17 | ✗ |
| 18 | ✗ |
| 19 | ✗ |
| 20 | ✗ |
| 21 | ✗ |
| 22 | ✗ |
| 23 | ✗ |
| 24 | ✗ |
| 25 | ✗ |
| 26 | ✓ |
| 27 | ✗ |
| 28 | ✗ |

29 ✗
30 ✗
31 ✗
32 ✓
33 ✗
34 ✗
35 ✗
36 ✗
37 ✗
38 ✗
39 ✗
40 ✗
41 ✗
42 ✗
43 ✗
44 ✓
45 ✗
46 ✗
47 ✓
48 ✗
49 ✗
50 ✗

All contents of this site are © 2024 Passmedicine Limited
Back to top

A 45-year-old man presents to his GP with a 4-week history of worsening nail changes. He works as a banker and is finding that the appearance of his nails is affecting his confidence. He also describes occasional pain in his wrists and fingers but says this is managed well with over-the-counter analgesia. His past medical history includes coeliac disease and hypothyroidism for which he takes levothyroxine.

On examination, his observations are within normal limits. There are no visible skin or mucosal changes. His nails are examined, as shown below.

© Image used on license from DermNet NZ

What is the most likely diagnosis?

- Onychomycosis
- Parakeratosis pustulosa
- Paronychia
- Psoriasis
- Yellow nail syndrome

Submit answer

Reference ranges

Score: **0%**

| | |
|---|---|
| 1 | - |
| 2 | - |
| 3 | - |
| 4 | - |
| 5 | - |
| 6 | - |
| **7** | - |

All contents of this site are © 2024 Passmedicine Limited

A 45-year-old man presents to his GP with a 4-week history of worsening nail changes. He works as a banker and is finding that the appearance of his nails is affecting his confidence. He also describes occasional pain in his wrists and fingers but says this is managed well with over-the-counter analgesia. His past medical history includes coeliac disease and hypothyroidism for which he takes levothyroxine.

On examination, his observations are within normal limits. There are no visible skin or mucosal changes. His nails are examined, as shown below.

© Image used on license from DermNet NZ

What is the most likely diagnosis?

| | |
|---|---|
| Onychomycosis | 23% |
| Parakeratosis pustulosa | 3% |
| Paronychia | 4% |
| Psoriasis | 49% |
| Yellow nail syndrome | 21% |

This patient's nails show signs of onycholysis (lifting of the nail bed) and pitting (indentations to the surface of the nails) which are suggestive of nail psoriasis. Nail psoriasis is commonly associated with chronic plaque psoriasis and is a risk factor for the development of psoriatic arthritis. The clinical history of wrist and finger pain further supports the diagnosis of developing

psoriatic arthropathy. Other nail features of psoriasis (although not seen here) include splinter haemorrhages, leukonychia, and nail crumbling.

Onychomycosis is otherwise known as a fungal nail infection. Common organisms include dermatophytes such as *Trichophyton rubrum* and *Candida albicans*. Signs of onychomycosis include distal and lateral onycholysis, subungual hyperkeratosis (scaling under the nail), and nail destruction. Not all nails are necessarily affected by onychomycosis and involvement of all nails should raise suspicion of an alternative diagnosis. This patient also complains of wrist and finger pain and has evidence of nail pitting, making psoriasis the more likely diagnosis.

Parakeratosis pustulosa is most commonly seen in younger children and involves the destruction or crumbling of a finger or toenail along with erythema and scaling of the surrounding skin. Similarly to this patient, onycholysis and nail pitting are possible nail features. However, the involvement of all nails with no surrounding skin changes and the older age of the patient makes parakeratosis pustulosa unlikely.

Paronychia is the inflammation of the skin surrounding a finger or toenail secondary to infection with *Staphylococcus aureus* or *Streptococcus pyogenes*. In acute paronychia, usually, only one finger or toe is affected and the nail is less commonly involved compared to chronic disease (i.e. > 6 weeks).

Yellow nail syndrome refers to the thickening and yellow discolouration of nails secondary to halted nail growth. It is associated with multiple conditions including chronic sinus infections, bronchiectasis, and pleural effusions.

Discuss (1) Improve

Next question

## Psoriasis and psoriatic arthropathy: nail changes

Psoriatic nail changes affect both fingers and toes and do not reflect the severity of psoriasis but there is an association with psoriatic arthropathy - around 80-90% of patients with psoriatic arthropathy have nail changes.

Nail changes that may be seen in psoriasis

- pitting
- onycholysis (separation of the nail from the nail bed)
- subungual hyperkeratosis
- loss of the nail

123

Next question

## Textbooks

High-yield textbook

Extended textbook

Score: **14%**

| | |
|---|---|
| 1 | ✗ |
| 2 | ✗ |
| 3 | ✓ |
| 4 | ✗ |
| 5 | ✗ |
| 6 | ✗ |
| **7** | ✗ |
| 8 | ✗ |
| 9 | ✗ |
| 10 | ✗ |

| | |
|---|---|
| 11 | ✓ |
| 12 | ✗ |
| 13 | ✓ |
| 14 | ✗ |
| 15 | ✗ |
| 16 | ✗ |
| 17 | ✗ |
| 18 | ✗ |
| 19 | ✗ |
| 20 | ✗ |
| 21 | ✗ |
| 22 | ✗ |
| 23 | ✗ |
| 24 | ✗ |
| 25 | ✗ |
| 26 | ✓ |
| 27 | ✗ |
| 28 | ✗ |
| 29 | ✗ |
| 30 | ✗ |
| 31 | ✗ |
| 32 | ✓ |
| 33 | ✗ |
| 34 | ✗ |
| 35 | ✗ |
| 36 | ✗ |
| 37 | ✗ |
| 38 | ✗ |
| 39 | ✗ |
| 40 | ✗ |
| 41 | ✗ |
| 42 | ✗ |
| 43 | ✗ |
| 44 | ✓ |
| 45 | ✗ |
| 46 | ✗ |

| | |
|---|---|
| 47 | ✓ |
| 48 | ✗ |
| 49 | ✗ |
| 50 | ✗ |

All contents of this site are © 2024 Passmedicine Limited

Back to top

A 35-year-old man asks you to review a lesion on his right arm. This has been present for the past six months but has not changed significantly over that period.

© Image used on license from DermNet NZ

What is the most likely diagnosis?

- Spitz naevus
- Dermatofibroma
- Nodular basal cell carcinoma
- Viral wart
- Dermoid cyst

Submit answer

Reference ranges

Score: **0%**

| | |
|---|---|
| 1 | - |
| 2 | - |
| 3 | - |
| 4 | - |
| 5 | - |
| 6 | - |
| 7 | - |
| **8** | - |

All contents of this site are © 2024 Passmedicine Limited

A 35-year-old man asks you to review a lesion on his right arm. This has been present for the past six months but has not changed significantly over that period.

© Image used on license from DermNet NZ

What is the most likely diagnosis?

| | |
|---|---|
| Spitz naevus | 5% |
| Dermatofibroma | 77% |
| Nodular basal cell carcinoma | 3% |
| Viral wart | 2% |
| Dermoid cyst | 13% |

The correct answer is **Dermatofibroma**. Dermatofibromas are common benign cutaneous nodules of unknown aetiology. This lesion, as seen in the image, is a firm papule or nodule that appears dermal yet is firmly adherent to the epidermis. The colour can vary from skin-coloured to red-brown. It is often asymptomatic but can be tender or itchy, particularly if traumatised. The characteristic 'dimple sign' (a central depression when the lesion is laterally compressed) is usually present.

The first incorrect option is a **Spitz naevus**. Although Spitz naevi may appear similar to

dermatofibromas on visual inspection, they are typically seen in children and teenagers rather than adults. They often have a more rapid onset (weeks to months) compared with the six-month history provided in this case. Furthermore, Spitz naevi tend to change significantly over time, unlike the stable nature of the lesion described here.

The second incorrect option is a **Nodular basal cell carcinoma**. While these lesions may also appear similar to dermatofibromas visually, they are typically characterised by more aggressive growth patterns and features such as telangiectasia (tiny blood vessels), ulceration or bleeding which were not described in this case.

The third incorrect option is a **Viral wart**. Viral warts caused by human papillomavirus (*HPV*) are typically keratotic and rough-surfaced lesions that grow rapidly over weeks to months. They may also have black dots representing thrombosed capillaries ('wart seeds'). None of these features were mentioned in this case.

Lastly, a **Dermoid cyst** was an incorrect choice because dermoid cysts are congenital lesions that present early in life and grow slowly over years rather than months. They can be fluctuant or doughy to touch unlike the firm lesion described here.

Discuss (6) | Improve

Next question

## Dermatofibroma

Dermatofibromas (also known as histiocytomas) are common benign fibrous skin lesions. They are caused by the abnormal growth of dermal dendritic histiocyte cells, often following a precipitating injury. Common areas include the arms and legs.

Features
- solitary firm papule or nodule, typically on a limb
- typically around 5-10mm in size
- overlying skin dimples on pinching the lesion

123

Next question

## Textbooks

High-yield textbook

Extended textbook

Score: **14%**

| | |
|---|---|
| 1 | ✗ |
| 2 | ✗ |
| 3 | ✓ |
| 4 | ✗ |
| 5 | ✗ |
| 6 | ✗ |
| 7 | ✗ |
| **8** | ✗ |
| 9 | ✗ |
| 10 | ✗ |
| 11 | ✓ |
| 12 | ✗ |
| 13 | ✓ |
| 14 | ✗ |
| 15 | ✗ |

| | |
|---|---|
| 16 | ✗ |
| 17 | ✗ |
| 18 | ✗ |
| 19 | ✗ |
| 20 | ✗ |
| 21 | ✗ |
| 22 | ✗ |
| 23 | ✗ |
| 24 | ✗ |
| 25 | ✗ |
| 26 | ✓ |
| 27 | ✗ |
| 28 | ✗ |
| 29 | ✗ |
| 30 | ✗ |
| 31 | ✗ |
| 32 | ✓ |
| 33 | ✗ |
| 34 | ✗ |
| 35 | ✗ |
| 36 | ✗ |
| 37 | ✗ |
| 38 | ✗ |
| 39 | ✗ |
| 40 | ✗ |
| 41 | ✗ |
| 42 | ✗ |
| 43 | ✗ |
| 44 | ✓ |
| 45 | ✗ |
| 46 | ✗ |
| 47 | ✓ |
| 48 | ✗ |
| 49 | ✗ |
| 50 | ✗ |

All contents of this site are © 2024 Passmedicine Limited

A 58-year-old man is referred to the clinic with chronic diarrhoea and episodes of facial flushing. A computed tomography scan of his chest and abdomen reveals that he has a neuroendocrine carcinoma of the appendix, causing carcinoid syndrome.

He refuses treatment and presents six months later having been referred by a neurologist as having early onset dementia and a rapidly evolving photosensitive rash on his trunk and upper arms.

Which of the following is the most likely diagnosis?

- Systemic lupus erythematosus
- Herpes zoster infection
- Pellagra
- Wernicke-Korsakoff syndrome
- Porphyria

Submit answer

Reference ranges

Score: **0%**

1 -
2 -
3 -
4 -
5 -
6 -

| | |
|---|---|
| 7 | - |
| 8 | - |
| **9** | - |

All contents of this site are © 2024 Passmedicine Limited

A 58-year-old man is referred to the clinic with chronic diarrhoea and episodes of facial flushing. A computed tomography scan of his chest and abdomen reveals that he has a neuroendocrine carcinoma of the appendix, causing carcinoid syndrome.

He refuses treatment and presents six months later having been referred by a neurologist as having early onset dementia and a rapidly evolving photosensitive rash on his trunk and upper arms.

Which of the following is the most likely diagnosis?

| | |
|---|---|
| Systemic lupus erythematosus | 2% |
| Herpes zoster infection | 1% |
| Pellagra | 85% |
| Wernicke-Korsakoff syndrome | 1% |
| Porphyria | 12% |

Niacin (B3) deficiency is characterised by dermatitis, diarrhoea and dementia, a condition known as pellagra

Important for me Less important

The most likely diagnosis, in this case, is pellagra, a vitamin deficiency disease most frequently caused by a chronic lack of niacin (vitamin B3). In carcinoid syndrome, neuroendocrine tumours along the GI tract use tryptophan as the source for serotonin production, which limits the available tryptophan for niacin synthesis.

Discuss (1) Improve

Next question

## Pellagra

Pellagra is a caused by nicotinic acid (niacin) deficiency. The classical features are the 3 D's - dermatitis, diarrhoea and dementia.

Pellagra may occur as a consequence of isoniazid therapy (isoniazid inhibits the conversion of tryptophan to niacin) and it is more common in alcoholics.

Features

- dermatitis (brown scaly rash on sun-exposed sites - termed Casal's necklace if around neck)
- diarrhoea
- dementia, depression
- death if not treated

123

Next question

## Textbooks

High-yield textbook

Extended textbook

## Links

DermNet NZ 8 2

Pellagra

Suggest link Report broken link

Score: **14%**

| | |
|---|---|
| 1 | ✗ |
| 2 | ✗ |
| 3 | ✓ |
| 4 | ✗ |
| 5 | ✗ |
| 6 | ✗ |
| 7 | ✗ |
| 8 | ✗ |
| **9** | ✗ |
| 10 | ✗ |
| 11 | ✓ |
| 12 | ✗ |
| 13 | ✓ |
| 14 | ✗ |
| 15 | ✗ |
| 16 | ✗ |
| 17 | ✗ |
| 18 | ✗ |
| 19 | ✗ |
| 20 | ✗ |
| 21 | ✗ |
| 22 | ✗ |
| 23 | ✗ |
| 24 | ✗ |
| 25 | ✗ |
| 26 | ✓ |
| 27 | ✗ |
| 28 | ✗ |
| 29 | ✗ |
| 30 | ✗ |
| 31 | ✗ |
| 32 | ✓ |
| 33 | ✗ |
| 34 | ✗ |

35 ✗
36 ✗
37 ✗
38 ✗
39 ✗
40 ✗
41 ✗
42 ✗
43 ✗
44 ✓
45 ✗
46 ✗
47 ✓
48 ✗
49 ✗
50 ✗

All contents of this site are © 2024 Passmedicine Limited

An 80-year-old woman presents due a 'sore' on the medial aspect of her right eye:

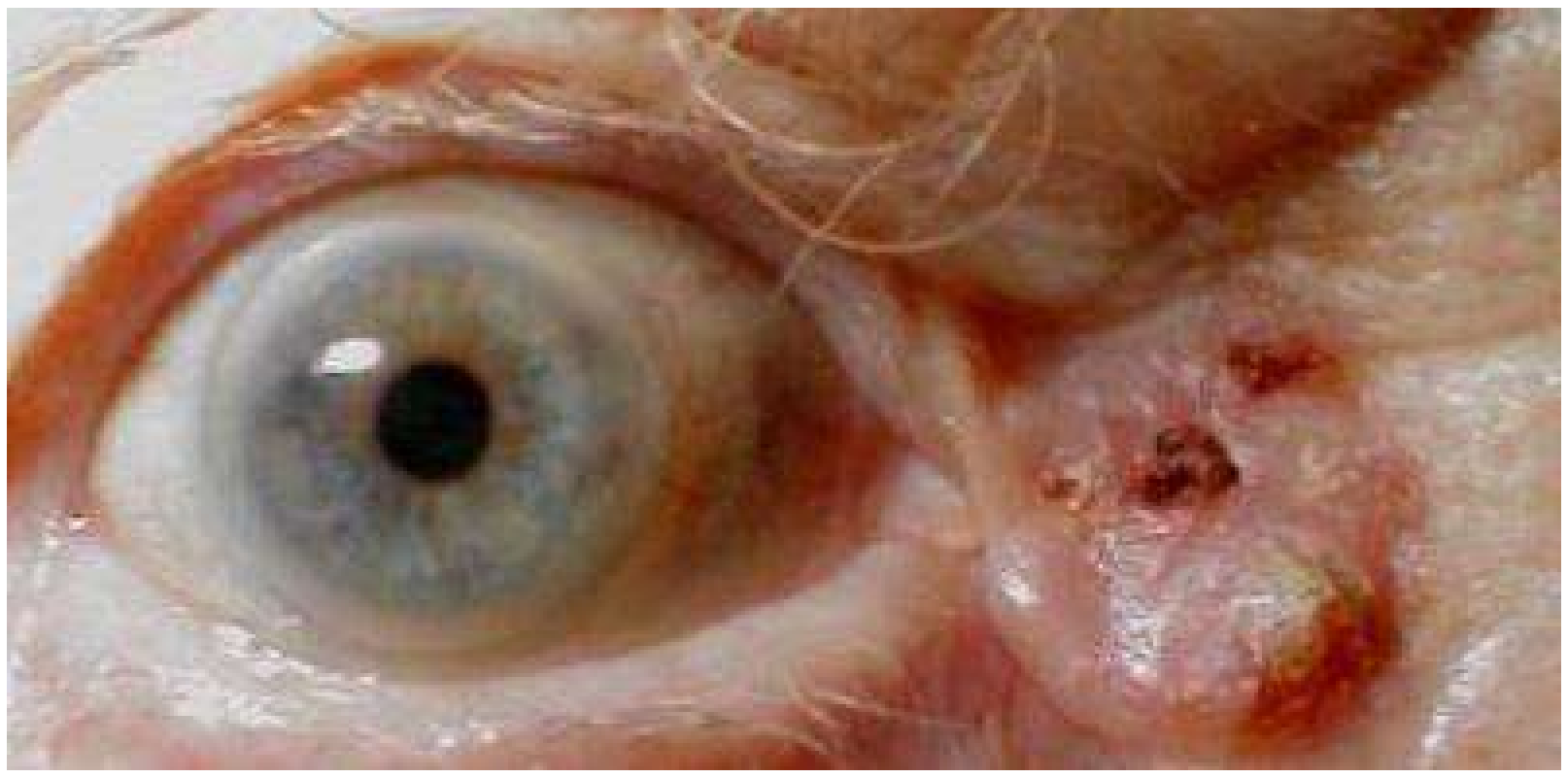

What is the most likely diagnosis?

- Basal cell carcinoma
- Squamous cell carcinoma
- Chalazion
- Stye
- Indurated dacryocystitis

Submit answer

Reference ranges

Score: **0%**

1 -
2 -
3 -

| | |
|---|---|
| 4 | - |
| 5 | - |
| 6 | - |
| 7 | - |
| 8 | - |
| 9 | - |
| **10** | - |

All contents of this site are © 2024 Passmedicine Limited

An 80-year-old woman presents due a 'sore' on the medial aspect of her right eye:

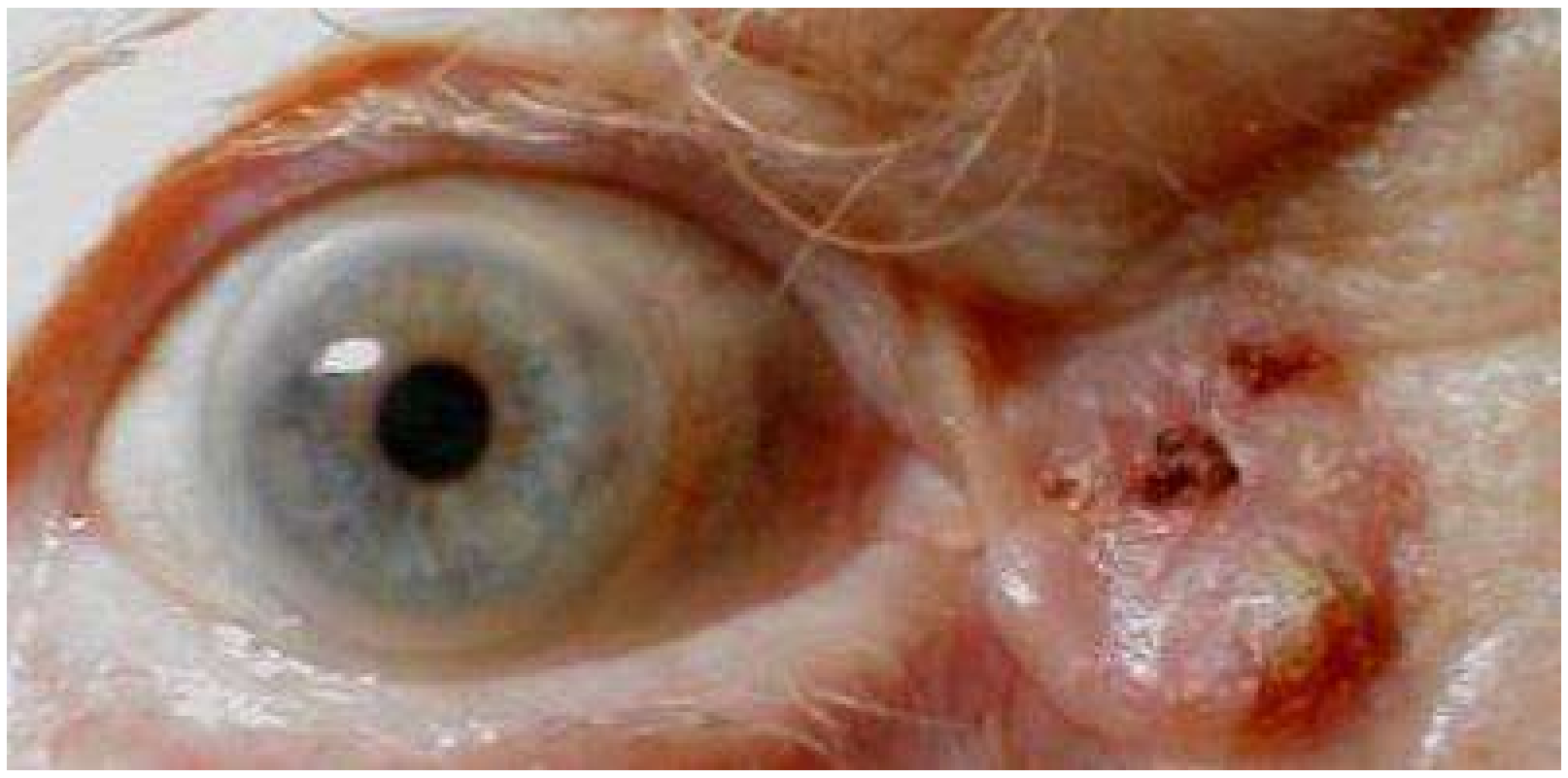

What is the most likely diagnosis?

| | |
|---|---|
| Basal cell carcinoma | 85% |
| Squamous cell carcinoma | 11% |
| Chalazion | 1% |
| Stye | 0% |
| Indurated dacryocystitis | 3% |

The rolled, pearly edges with telangiectasia on the inferior border of the lesion make basal cell carcinoma the most likely diagnosis.

Discuss (4) Improve

Next question

## Basal cell carcinoma

Basal cell carcinoma (BCC) is one of the three main types of skin cancer. Lesions are also known as rodent ulcers and are characterised by slow-growth and local invasion. Metastases are extremely rare. BCC is the most common type of cancer in the Western world.

Features

- many types of BCC are described. The most common type is nodular BCC, which is described here
- sun-exposed sites, especially the head and neck account for the majority of lesions
- initially a pearly, flesh-coloured papule with telangiectasia
- may later ulcerate leaving a central 'crater'

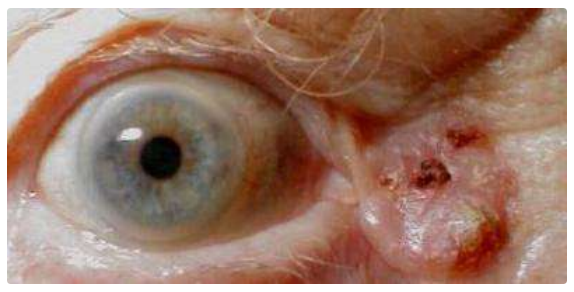

Referral

- generally, if a BCC is suspected, a routine referral should be made

Management options:

- surgical removal
- curettage
- cryotherapy
- topical cream: imiquimod, fluorouracil
- radiotherapy

+ Q 123

Next question >

## Textbooks

High-yield textbook

Extended textbook

## Links

DermNet NZ 21 7

Basal cell carcinoma

Suggest link Report broken link

## Media

Skin cancers

Osmosis - YouTube 4 2

Report broken media

Score: **14%**

1 ✗
2 ✗
3 ✓
4 ✗
5 ✗
6 ✗
7 ✗
8 ✗
9 ✗

| | |
|---|---|
| **10** | ✗ |
| 11 | ✓ |
| 12 | ✗ |
| 13 | ✓ |
| 14 | ✗ |
| 15 | ✗ |
| 16 | ✗ |
| 17 | ✗ |
| 18 | ✗ |
| 19 | ✗ |
| 20 | ✗ |
| 21 | ✗ |
| 22 | ✗ |
| 23 | ✗ |
| 24 | ✗ |
| 25 | ✗ |
| 26 | ✓ |
| 27 | ✗ |
| 28 | ✗ |
| 29 | ✗ |
| 30 | ✗ |
| 31 | ✗ |
| 32 | ✓ |
| 33 | ✗ |
| 34 | ✗ |
| 35 | ✗ |
| 36 | ✗ |
| 37 | ✗ |
| 38 | ✗ |
| 39 | ✗ |
| 40 | ✗ |
| 41 | ✗ |
| 42 | ✗ |
| 43 | ✗ |
| 44 | ✓ |
| 45 | ✗ |

| | |
|---|---|
| 46 | ✗ |
| 47 | ✓ |
| 48 | ✗ |
| 49 | ✗ |
| 50 | ✗ |

All contents of this site are © 2024 Passmedicine Limited

Back to top

An elderly man complains about the appearance of his nose:

© Image used on license from DermNet NZ

What is the most likely diagnosis?

- Sarcoidosis
- Basal cell carcinoma
- Systemic lupus erythematosus
- Alcohol excess
- Acne rosacea

Submit answer

Reference ranges

Score: **0%**

| | |
|---|---|
| 1 | - |
| 2 | - |
| 3 | - |
| 4 | - |
| 5 | - |
| 6 | - |
| 7 | - |
| 8 | - |
| 9 | - |
| 10 | - |
| **11** | - |

All contents of this site are © 2024 Passmedicine Limited

An elderly man complains about the appearance of his nose:

© Image used on license from DermNet NZ

What is the most likely diagnosis?

- Sarcoidosis 4%
- Basal cell carcinoma 5%
- Systemic lupus erythematosus 1%
- Alcohol excess 3%
- Acne rosacea 87%

Rosacea features:

- nose, cheeks and forehead
- flushing, erythema, telangiectasia → papules and pustules

Important for me Less important

This man has a rhinophyma, a complication of acne rosacea.

Discuss (1) Improve

Next question

# Rosacea

Rosacea (sometimes referred to as acne rosacea) is a chronic skin disease of unknown aetiology.

Features

- typically affects nose, cheeks and forehead
- flushing is often first symptom
- telangiectasia are common
- later develops into persistent erythema with papules and pustules
- rhinophyma
- ocular involvement: blepharitis
- sunlight may exacerbate symptoms

Management

- simple measures
  - recommend daily application of a high-factor sunscreen
  - camouflage creams may help conceal redness
- predominant erythema/flushing
  - topical brimonidine gel may be considered for patients with predominant flushing but limited telangiectasia
  - brimonidine is a topical alpha-adrenergic agonist
  - this can be used on an 'as required basis' to temporarily reduce redness
  - it typically reduces redness within 30 minutes, reaching peak action at 3-6 hours, after which the redness returns to the baseline
- mild-to-moderate papules and/or pustules
  - topical ivermectin is first-line
  - alternatives include: topical metronidazole or topical azelaic acid
- moderate-to-severe papules and/or pustules
  - combination of topical ivermectin + oral doxycycline

Referral should be considered if

- symptoms have not improved with optimal management in primary care
  - laser therapy may be appropriate for patients with prominent telangiectasia
- patients with a rhinophyma

123

Next question

## Textbooks

High-yield textbook

Extended textbook

## Links

DermNet NZ 11 17

Rhinophyma

BNF 10 11

Acne rosacea

Dermnet NZ 23 13

Acne rosacea

Clinical Knowledge Summaries 19 10

Acne rosacea guidelines

Primary Care Dermatology Society

27 9

Rosacea review

Suggest link

Report broken link

Score: **14%**

| | |
|---|---|
| 1 | ✗ |
| 2 | ✗ |
| 3 | ✓ |
| 4 | ✗ |
| 5 | ✗ |
| 6 | ✗ |
| 7 | ✗ |
| 8 | ✗ |
| 9 | ✗ |
| 10 | ✗ |
| **11** | ✓ |
| 12 | ✗ |
| 13 | ✓ |
| 14 | ✗ |
| 15 | ✗ |
| 16 | ✗ |
| 17 | ✗ |
| 18 | ✗ |
| 19 | ✗ |
| 20 | ✗ |
| 21 | ✗ |
| 22 | ✗ |
| 23 | ✗ |
| 24 | ✗ |
| 25 | ✗ |

| | |
|---|---|
| 26 | ✓ |
| 27 | ✗ |
| 28 | ✗ |
| 29 | ✗ |
| 30 | ✗ |
| 31 | ✗ |
| 32 | ✓ |
| 33 | ✗ |
| 34 | ✗ |
| 35 | ✗ |
| 36 | ✗ |
| 37 | ✗ |
| 38 | ✗ |
| 39 | ✗ |
| 40 | ✗ |
| 41 | ✗ |
| 42 | ✗ |
| 43 | ✗ |
| 44 | ✓ |
| 45 | ✗ |
| 46 | ✗ |
| 47 | ✓ |
| 48 | ✗ |
| 49 | ✗ |
| 50 | ✗ |

All contents of this site are © 2024 Passmedicine Limited

A 72-year-old woman is diagnosed with a number of erythematous, rough lesions on the back of her hands. A diagnosis of actinic keratoses is made. What is the most appropriate management?

- Reassurance
- Urgent referral to a dermatologist
- Topical fluorouracil cream
- Review in 3 months
- Topical betnovate

Submit answer

Reference ranges

Score: **0%**

1 -
2 -
3 -
4 -
5 -
6 -
7 -
8 -
9 -
10 -
11 -
**12** -

All contents of this site are © 2024 Passmedicine Limited

A 72-year-old woman is diagnosed with a number of erythematous, rough lesions on the back of her hands. A diagnosis of actinic keratoses is made. What is the most appropriate management?

| | |
|---|---|
| Reassurance | 10% |
| Urgent referral to a dermatologist | 11% |
| Topical fluorouracil cream | 72% |
| Review in 3 months | 4% |
| Topical betnovate | 3% |

The correct answer is **Topical fluorouracil cream**. Actinic keratoses (AKs) are rough, scaly patches on the skin that are caused by excessive exposure to the sun. They can potentially develop into squamous cell carcinoma, a type of skin cancer. Therefore, treatment is recommended to prevent this progression. In the UK, according to NICE guidelines, topical fluorouracil cream is considered first-line therapy for multiple AKs. This medication works by interfering with the DNA in skin cells, preventing their growth and causing them to die.

The first option, **Reassurance**, is incorrect because although actinic keratoses are not malignant themselves, they have the potential to progress into squamous cell carcinoma. Hence it's important to treat them rather than simply reassuring the patient.

The second option, **Urgent referral to a dermatologist**, isn't necessary unless there's suspicion of malignant transformation or if initial treatments fail - neither of which we're told is applicable in this case scenario.

**Review in 3 months** without any treatment intervention may allow for unnecessary progression of the lesions and hence is not an appropriate management strategy.

Finally, **Topical betnovate**, a corticosteroid cream, is also not a suitable treatment for actinic keratoses as it doesn't target the abnormal proliferation of keratinocytes seen in these lesions. Instead, it's primarily used for conditions involving inflammation and itching such as eczema and dermatitis.

Discuss (1) Improve

Next question

# Actinic keratoses

Actinic, or solar, keratoses (AK) is a common premalignant skin lesion that develops as a consequence of chronic sun exposure

Features
- small, crusty or scaly, lesions
- may be pink, red, brown or the same colour as the skin
- typically on sun-exposed areas e.g. temples of head
- multiple lesions may be present

Management options include
- prevention of further risk: e.g. sun avoidance, sun cream
- fluorouracil cream: typically a 2 to 3 week course. The skin will become red and inflamed - sometimes topical hydrocortisone is given following fluorouracil to help settle the inflammation
- topical diclofenac: may be used for mild AKs. Moderate efficacy but much fewer side-effects
- topical imiquimod: trials have shown good efficacy
- cryotherapy
- curettage and cautery

123

Next question

## Textbooks

High-yield textbook

Extended textbook

## Links

British Association of Dermatologists 9 9

2017 Actinic keratoses guidelines

DermNet NZ 27 11

Actinic keratoses

Primary Care Dermatology Society 14 5

Actinic keratosis

Suggest link

Report broken link

Score: **14%**

1 ✗
2 ✗
3 ✓
4 ✗
5 ✗
6 ✗
7 ✗
8 ✗
9 ✗

| | |
|---|---|
| 10 | ✗ |
| 11 | ✓ |
| **12** | ✗ |
| 13 | ✓ |
| 14 | ✗ |
| 15 | ✗ |
| 16 | ✗ |
| 17 | ✗ |
| 18 | ✗ |
| 19 | ✗ |
| 20 | ✗ |
| 21 | ✗ |
| 22 | ✗ |
| 23 | ✗ |
| 24 | ✗ |
| 25 | ✗ |
| 26 | ✓ |
| 27 | ✗ |
| 28 | ✗ |
| 29 | ✗ |
| 30 | ✗ |
| 31 | ✗ |
| 32 | ✓ |
| 33 | ✗ |
| 34 | ✗ |
| 35 | ✗ |
| 36 | ✗ |
| 37 | ✗ |
| 38 | ✗ |
| 39 | ✗ |
| 40 | ✗ |
| 41 | ✗ |
| 42 | ✗ |
| 43 | ✗ |
| 44 | ✓ |
| 45 | ✗ |

| | |
|---|---|
| 46 | ✗ |
| 47 | ✓ |
| 48 | ✗ |
| 49 | ✗ |
| 50 | ✗ |

All contents of this site are © 2024 Passmedicine Limited

A 68-year-old man presents with blistering lesions on his skin. He reports he has suffered from mouth ulcers recently for which his GP prescribed chlorhexidine mouthwash. However, this has not been of any benefit and the ulcers are now affecting his ability to eat and drink. He reports over the last few days, large blisters have appeared across his torso and back.

His past medical history includes hypertension and angina. He currently takes ramipril, simvastatin and GTN spray when needed.

On examination, you find his mouth is erythematous with multiple superficial blisters; some have ulcerated and the patient reports they have been slow to heal. He has flaccid bullae across his torso and upper back, which appear to be filled with clear fluid. The bullae are fragile, with a thin outer layer. There are some areas where the blisters have ruptured, leaving exposed eroded skin, with some crusting around the edges.

Dermatology comes to review and they perform a punch biopsy, but advise you to start treatment whilst the results are awaited.

Given the likely diagnosis, what is the most appropriate first-line treatment?

- Azathioprine
- Mycophenolate mofetil
- Topical emollients
- Topical potent corticosteroids
- Oral corticosteroids

Submit answer

Reference ranges

Score: **0%**

| | |
|---|---|
| 1 | - |
| 2 | - |
| 3 | - |
| 4 | - |
| 5 | - |
| 6 | - |
| 7 | - |
| 8 | - |
| 9 | - |
| 10 | - |
| 11 | - |
| 12 | - |
| **13** | - |

All contents of this site are © 2024 Passmedicine Limited

Back to top

A 68-year-old man presents with blistering lesions on his skin. He reports he has suffered from mouth ulcers recently for which his GP prescribed chlorhexidine mouthwash. However, this has not been of any benefit and the ulcers are now affecting his ability to eat and drink. He reports over the last few days, large blisters have appeared across his torso and back.

His past medical history includes hypertension and angina. He currently takes ramipril, simvastatin and GTN spray when needed.

On examination, you find his mouth is erythematous with multiple superficial blisters; some have ulcerated and the patient reports they have been slow to heal. He has flaccid bullae across his torso and upper back, which appear to be filled with clear fluid. The bullae are fragile, with a thin outer layer. There are some areas where the blisters have ruptured, leaving exposed eroded skin, with some crusting around the edges.

Dermatology comes to review and they perform a punch biopsy, but advise you to start treatment whilst the results are awaited.

Given the likely diagnosis, what is the most appropriate first-line treatment?

| | |
|---|---|
| Azathioprine | 1% |
| Mycophenolate mofetil | 3% |
| Topical emollients | 2% |
| Topical potent corticosteroids | 11% |
| Oral corticosteroids | 83% |

Systemic glucocorticoids are the first-line treatment in pemphigus vulgaris

Important for me Less important

This patient has presented with bullous skin lesions with mucosal involvement therefore the diagnosis is pemphigus vulgaris. The first-line treatment for this is oral corticosteroids.

Azathioprine and mycophenolate mofetil are steroid-sparing agents that can be used longer-term to control the disease, but would not be initiated in the acute phase.

Topical emollients are useful for dry skin, eczema, psoriasis and lots of other skin conditions. However, they will not be useful in the management of bullous skin disease.

Topical potent corticosteroids are not appropriate treatment in pemphigus vulgaris due to the widespread nature of the disease, including mucosal involvement. Oral steroids are of greater benefit.

Discuss (3) Improve

Next question

## Pemphigus vulgaris

Pemphigus vulgaris is an autoimmune disease caused by antibodies directed against desmoglein 3, a cadherin-type epithelial cell adhesion molecule. It is more common in the Ashkenazi Jewish population.

Features

- mucosal ulceration is common and often the presenting symptom. Oral involvement is seen in 50-70% of patients
- skin blistering - flaccid, easily ruptured vesicles and bullae. Lesions are typically painful but not itchy. These may develop months after the initial mucosal symptoms. Nikolsky's describes the spread of bullae following application of horizontal, tangential pressure to the skin
- acantholysis on biopsy

Management

- steroids are first-line
- immunosuppressants

AI + Q 123

Next question >

## Textbooks

High-yield textbook

Extended textbook

## Links

British Association of Dermatologists 7 2

2017 Guidelines for the management of pemphigus vulgaris

DermNet NZ 9 2

Pemphigus vulgaris

Suggest link Report broken link

## Media

Pemphigus vulgaris

Osmosis - YouTube 3 0

Report broken media

Score: **14%**

| | |
|---|---|
| 1 | ✗ |
| 2 | ✗ |
| 3 | ✓ |
| 4 | ✗ |
| 5 | ✗ |
| 6 | ✗ |
| 7 | ✗ |
| 8 | ✗ |
| 9 | ✗ |
| 10 | ✗ |
| 11 | ✓ |
| 12 | ✗ |
| **13** | ✓ |
| 14 | ✗ |
| 15 | ✗ |
| 16 | ✗ |
| 17 | ✗ |
| 18 | ✗ |
| 19 | ✗ |
| 20 | ✗ |
| 21 | ✗ |
| 22 | ✗ |
| 23 | ✗ |
| 24 | ✗ |
| 25 | ✗ |
| 26 | ✓ |
| 27 | ✗ |
| 28 | ✗ |
| 29 | ✗ |
| 30 | ✗ |
| 31 | ✗ |
| 32 | ✓ |
| 33 | ✗ |
| 34 | ✗ |

| | |
|---|---|
| 35 | ✗ |
| 36 | ✗ |
| 37 | ✗ |
| 38 | ✗ |
| 39 | ✗ |
| 40 | ✗ |
| 41 | ✗ |
| 42 | ✗ |
| 43 | ✗ |
| 44 | ✓ |
| 45 | ✗ |
| 46 | ✗ |
| 47 | ✓ |
| 48 | ✗ |
| 49 | ✗ |
| 50 | ✗ |

All contents of this site are © 2024 Passmedicine Limited

Back to top

A 38-year-old patient is referred to the dermatology clinic due to persistent pruritus. She has a long-standing history of eczema and is using topical corticosteroids and emollients as prescribed. On examination, you note erythematous, excoriated patches of eczema on the flexural surfaces of the legs. The patient complains of intense itching and seeks additional relief.

What non-pharmacological method is most appropriate for controlling pruritus in this patient?

- Bandaging lesions
- Low humidity environment
- Multiple baths a day
- Oral antihistamines
- Use of hard water

Submit answer

Reference ranges

Score: **0%**

1 -
2 -
3 -
4 -
5 -
6 -
7 -
8 -
9 -

| | |
|---|---|
| 10 | - |
| 11 | - |
| 12 | - |
| 13 | - |
| **14** | - |

All contents of this site are © 2024 Passmedicine Limited

A 38-year-old patient is referred to the dermatology clinic due to persistent pruritus. She has a long-standing history of eczema and is using topical corticosteroids and emollients as prescribed. On examination, you note erythematous, excoriated patches of eczema on the flexural surfaces of the legs. The patient complains of intense itching and seeks additional relief.

What non-pharmacological method is most appropriate for controlling pruritus in this patient?

| | |
|---|---|
| Bandaging lesions | 56% |
| Low humidity environment | 21% |
| Multiple baths a day | 3% |
| Oral antihistamines | 17% |
| Use of hard water | 3% |

Bandaging can help control itching in eczema to prevent further scratching

Important for me    Less important

**Bandaging lesions** is the correct answer. Bandaging eczematous lesions can provide significant relief from itching as it protects the skin from further scratching, thereby interrupting the itch-scratch cycle. It also helps to maintain moisture and enhance the penetration of topical medications. Dressings can also be worn overnight to prevent involuntary scratching during sleep.

**Low humidity environment** is incorrect. Low-humidity environments have been recognised to aggravate eczema as they dry the skin, which can lead to itching. Maintaining skin hydration is an essential cornerstone of managing eczema, and this is done with the help of emollients and moisturisers applied multiple times during the day.

**Multiple baths a day** is incorrect. Excessive bathing or washing can cause flares of eczema and increase pruritus, as it can dry the skin and expose it to chemicals in the water that can irritate it. Daily bathing/showering should be accompanied by using a mild cleanser during the bath, followed immediately by applying an emollient to prevent the skin from drying.

**Oral antihistamines** is incorrect. Oral antihistamines, especially the first-generation antihistamines, which have an additional sedative effect, are commonly used to relieve pruritis in

patients with eczema. However, they are a pharmacological method to control pruritus, which makes them the wrong answer in the given context.

**Use of hard water** is incorrect. It has been reported that areas with hard water have a higher prevalence of eczema in the population. It is postulated that the minerals in the hard water cause the deposition of soap compounds like sodium lauryl sulfate on the skin, which can cause skin irritation and itching.

Discuss (1) | Improve

Next question

# Eczema: management ★

## Management

Avoidance of triggers and skin care education

- Key components include avoiding known irritants, allergens, and providing guidance on gentle skin care routines.

Emollients

- Integral to all treatment plans, regardless of eczema severity.
- Advise on liberal and regular use, even when the skin is clear, to maintain skin hydration and barrier function.
- Selection of emollient should be based on patient preference to improve adherence
  - Creams are generally preferred by most people - adherence is key so
  - Ointments provide the strongest emollient effect and may be more effective. However, they are greasy and so may be more suitable for use at night.

Topical therapies

- Topical corticosteroids
  - Vital for managing flare-ups, with potency tailored to the severity and lesion location
  - Example treatments recommended by NICE:
  - Mild eczema: hydrocortisone 1%
  - Moderate eczema: betamethasone valerate 0.025% or clobetasone butyrate 0.05%
  - Severe eczema: betamethasone valerate 0.1%
- Topical calcineurin inhibitors
  - Suitable for sensitive skin regions; include agents like tacrolimus and pimecrolimus.
- Topical antimicrobials

    - Used when there is clinical evidence of secondary infection.

Systemic therapies

- Indicated for severe or unresponsive cases.
- Oral corticosteroids:
    - Employed cautiously for acute severe exacerbations.
- Immunosuppressants:
    - Ciclosporin, methotrexate, or azathioprine are reserved for chronic, severe eczema.
- Biologic therapies:
    - Dupilumab is an advanced option for cases unresponsive to conventional therapy.

Phototherapy

- Considered for extensive eczema

## Prognosis

Prognostic markers associated with severe disease include:

- onset at age 3-6 months
- severe disease in childhood
- associated asthma or hay fever
- small family size
- high IgE serum levels

AI + Q 123

Next question ›

Textbooks

High-yield textbook

Extended textbook

## Links

British Association of Dermatologists 👍 1 👎 1

Atopic eczema guidelines

Clinical Knowledge Summaries 👍 0 👎 0

Atopic eczema

Suggest link

Report broken link

## Media

Eczema

Osmosis - YouTube 👍 2 👎 0

Report broken media

Score: **14%**

| | |
|---|---|
| 1 | ✗ |
| 2 | ✗ |
| 3 | ✓ |
| 4 | ✗ |
| 5 | ✗ |
| 6 | ✗ |
| 7 | ✗ |
| 8 | ✗ |
| 9 | ✗ |
| 10 | ✗ |
| 11 | ✓ |

| | |
|---|---|
| 12 | ✗ |
| 13 | ✓ |
| **14** | ✗ |
| 15 | ✗ |
| 16 | ✗ |
| 17 | ✗ |
| 18 | ✗ |
| 19 | ✗ |
| 20 | ✗ |
| 21 | ✗ |
| 22 | ✗ |
| 23 | ✗ |
| 24 | ✗ |
| 25 | ✗ |
| 26 | ✓ |
| 27 | ✗ |
| 28 | ✗ |
| 29 | ✗ |
| 30 | ✗ |
| 31 | ✗ |
| 32 | ✓ |
| 33 | ✗ |
| 34 | ✗ |
| 35 | ✗ |
| 36 | ✗ |
| 37 | ✗ |
| 38 | ✗ |
| 39 | ✗ |
| 40 | ✗ |
| 41 | ✗ |
| 42 | ✗ |
| 43 | ✗ |
| 44 | ✓ |
| 45 | ✗ |
| 46 | ✗ |
| 47 | ✓ |

48 ✕

49 ✕

50 ✕

All contents of this site are © 2024 Passmedicine Limited

A woman who is 30 weeks pregnant asks you about an itchy rash on her abdomen:

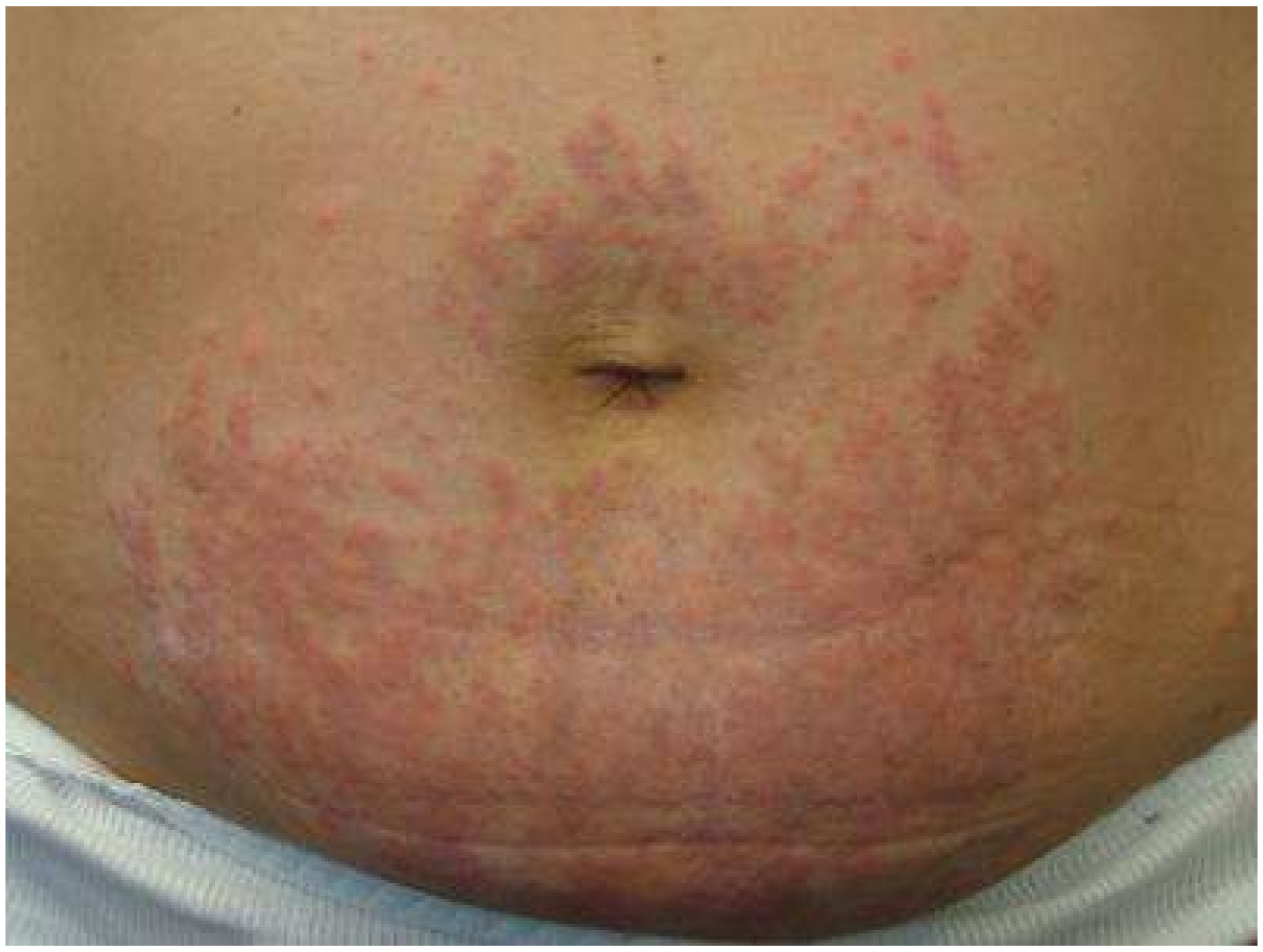

© Image used on license from DermNet NZ

What is the most likely diagnosis?

- Pre-eclampsia
- Polymorphic eruption of pregnancy
- Primary herpes simplex infection
- Pemphigoid gestationis
- Pompholyx

Submit answer

Reference ranges

Score: **0%**

| | |
|---|---|
| 1 | - |
| 2 | - |
| 3 | - |
| 4 | - |
| 5 | - |
| 6 | - |
| 7 | - |
| 8 | - |
| 9 | - |
| 10 | - |
| 11 | - |
| 12 | - |
| 13 | - |
| 14 | - |
| **15** | - |

All contents of this site are © 2024 Passmedicine Limited

Back to top

A woman who is 30 weeks pregnant asks you about an itchy rash on her abdomen:

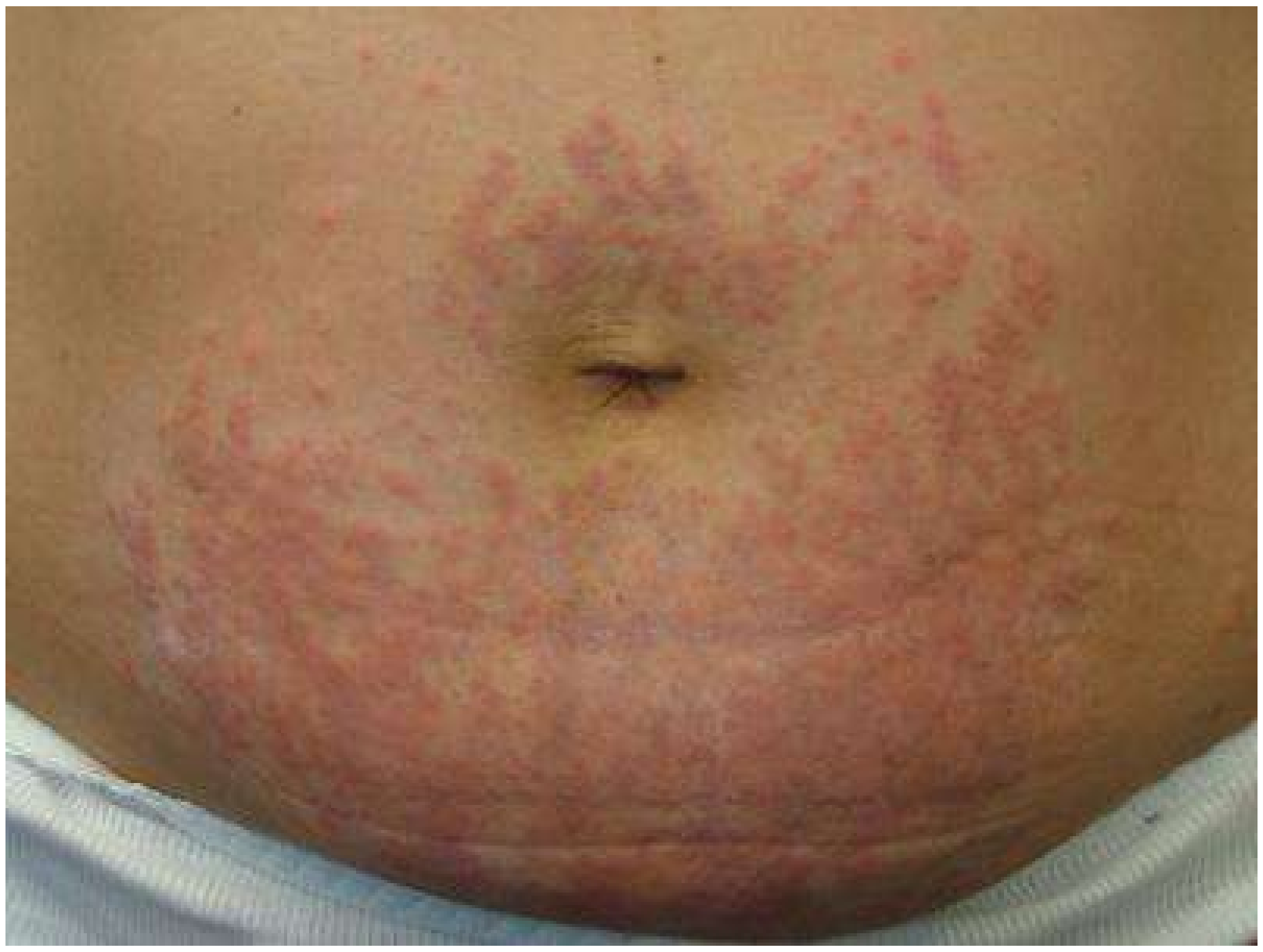

© Image used on license from DermNet NZ

What is the most likely diagnosis?

| | |
|---|---|
| Pre-eclampsia | 0% |
| Polymorphic eruption of pregnancy | 83% |
| Primary herpes simplex infection | 0% |
| Pemphigoid gestationis | 15% |
| Pompholyx | 1% |

The correct answer is **Polymorphic eruption of pregnancy**. This condition, also known as PEP or pruritic urticarial papules and plaques of pregnancy (PUPPP), typically presents in the third trimester. It is characterised by an itchy rash that usually starts on the abdomen, particularly around stretch marks, and can spread to the rest of the body except for the face. The rash consists of small red bumps and hives, and sometimes larger patches of raised skin. The exact cause is unknown, but it may be related to stretching of the skin.

**Pre-eclampsia** is incorrect because this condition does not typically present with a rash. Pre-eclampsia is a serious disorder of pregnancy characterised by high blood pressure and signs of

damage to another organ system, most often the liver and kidneys. Symptoms often include severe headaches, visual disturbances, upper abdominal pain, swelling in your face or hands, and shortness of breath.

**Primary herpes simplex infection** during pregnancy could potentially occur but would be unusual to only affect the abdomen and would likely present with painful vesicles rather than an itchy rash. Herpes simplex virus (HSV) infections during pregnancy can lead to neonatal herpes, which can be deadly.

**Pemphigoid gestationis**, also known as gestational pemphigoid, is an autoimmune blistering disorder that occurs during pregnancy. This option is incorrect because this condition typically presents with blisters rather than a rash. It usually begins with itchy bumps or hives that quickly develop into large blisters over large areas of your body.

**Pompholyx**, also known as dyshidrotic eczema, causes tiny blisters to erupt across the fingers, palms of the hands and sometimes the soles of your feet. It's extremely itchy but doesn't tend to affect other parts of the body so wouldn't explain a rash on a pregnant woman's abdomen.

Discuss (1) | Improve

Next question

## Skin disorders associated with pregnancy

Atopic eruption of pregnancy

- is the commonest skin disorder found in pregnancy
- it typically presents as an eczematous, itchy red rash.
- no specific treatment is needed

Polymorphic eruption of pregnancy

- pruritic condition associated with last trimester
- lesions often first appear in abdominal striae
- management depends on severity: emollients, mild potency topical steroids and oral steroids may be used

© Image used on license from DermNet NZ

Polymorphic eruption of pregnancy

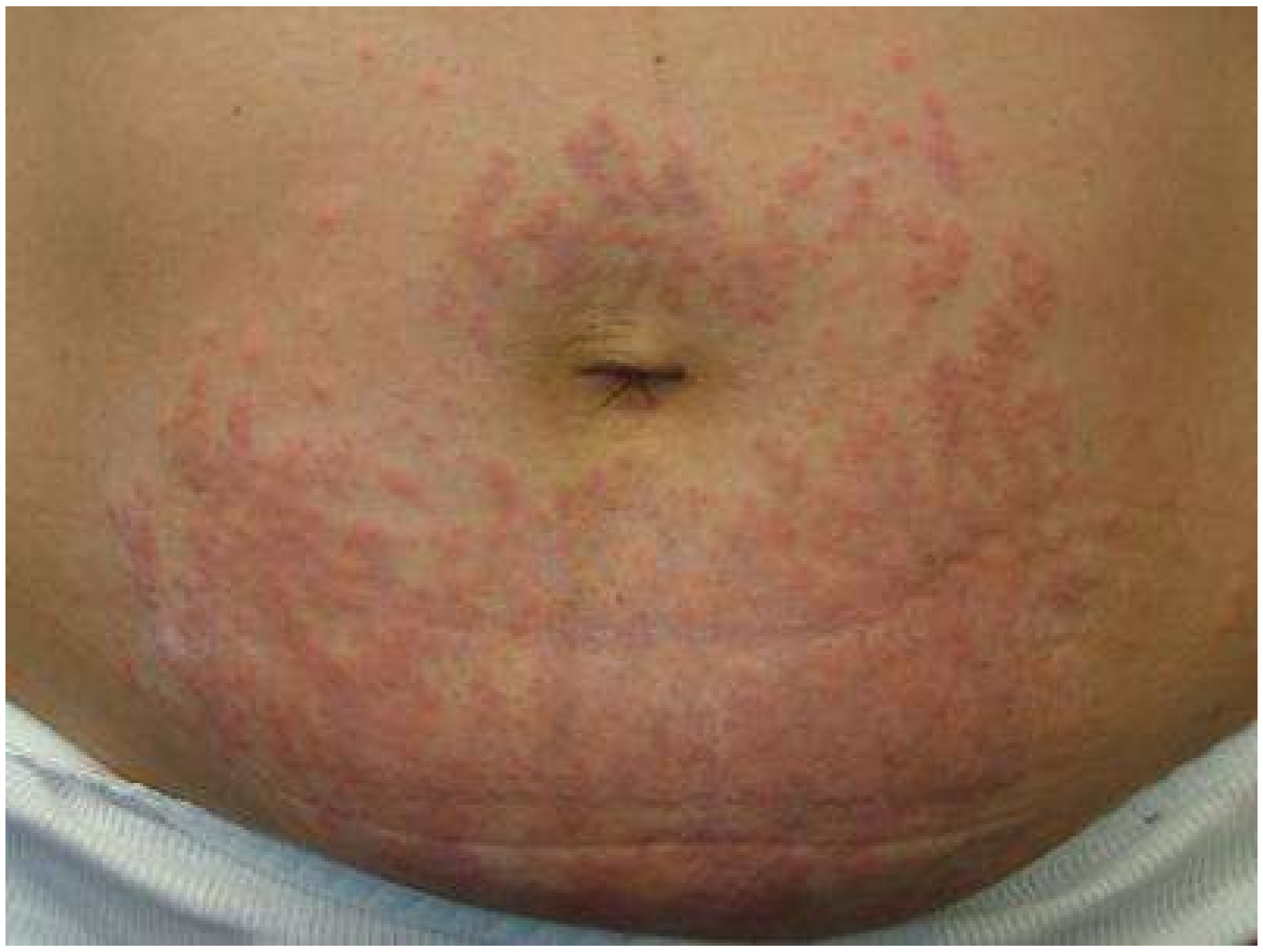

© Image used on license from DermNet NZ

Polymorphic eruption of pregnancy

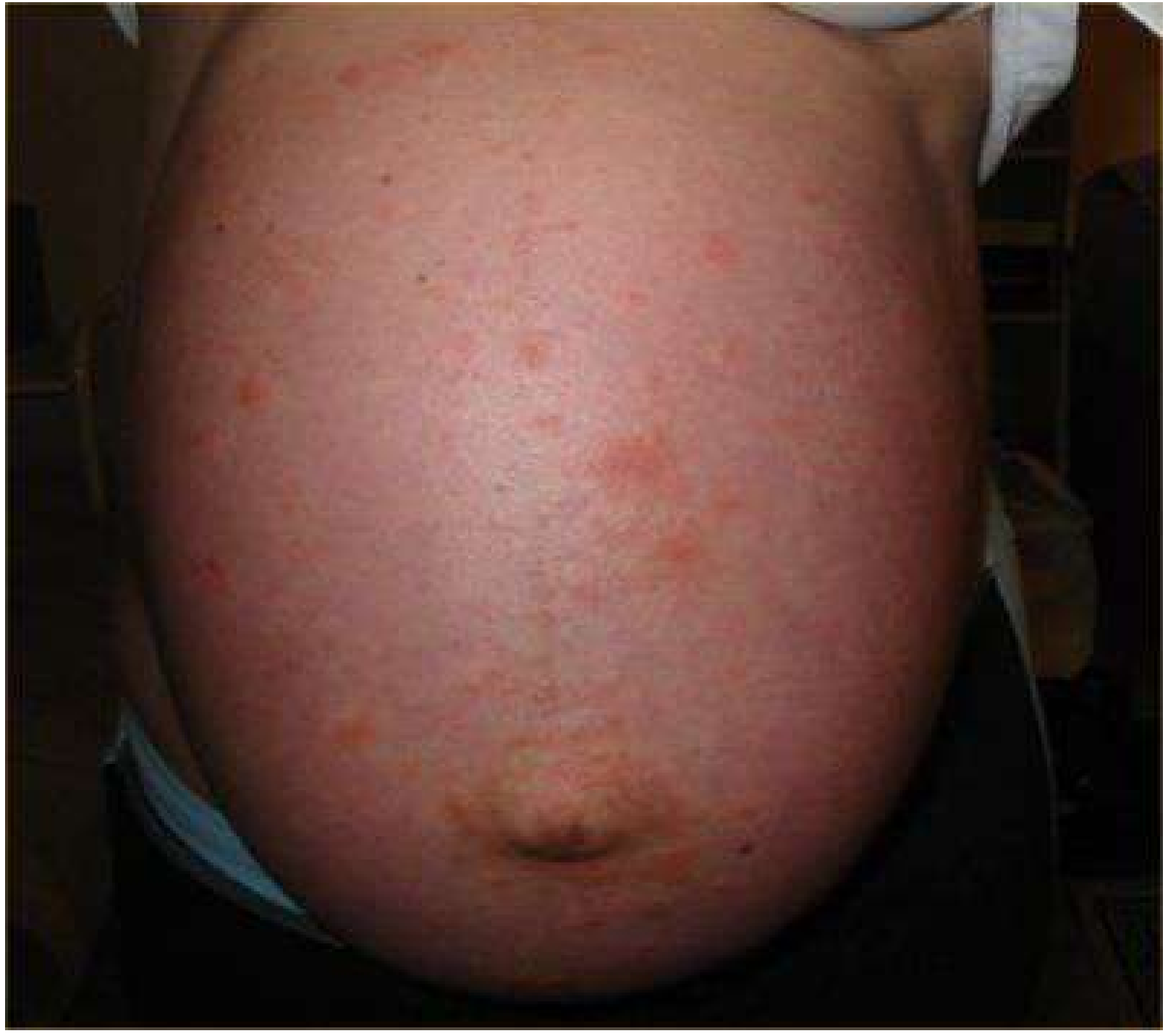

Polymorphic eruption of pregnancy

Pemphigoid gestationis

- pruritic blistering lesions
- often develop in peri-umbilical region, later spreading to the trunk, back, buttocks and arms
- usually presents 2nd or 3rd trimester and is rarely seen in the first pregnancy
- oral corticosteroids are usually required

© Image used on license from DermNet NZ

Pemphigoid gestationis

© Image used on license from DermNet NZ

Pemphigoid gestationis

123

Next question

## Textbooks

High-yield textbook

Extended textbook

## Links

DermNet NZ 13 5

Pemphigoid gestationis

DermNet NZ 11 4

Polymorphic eruption of pregnancy

Suggest link | Report broken link

Score: **14%**

| | |
|---|---|
| 1 | ✗ |
| 2 | ✗ |
| 3 | ✓ |
| 4 | ✗ |
| 5 | ✗ |
| 6 | ✗ |
| 7 | ✗ |
| 8 | ✗ |
| 9 | ✗ |
| 10 | ✗ |
| 11 | ✓ |
| 12 | ✗ |
| 13 | ✓ |
| 14 | ✗ |
| **15** | ✗ |
| 16 | ✗ |
| 17 | ✗ |
| 18 | ✗ |
| 19 | ✗ |
| 20 | ✗ |
| 21 | ✗ |
| 22 | ✗ |
| 23 | ✗ |
| 24 | ✗ |
| 25 | ✗ |
| 26 | ✓ |
| 27 | ✗ |
| 28 | ✗ |

| | |
|---|---|
| 29 | ✗ |
| 30 | ✗ |
| 31 | ✗ |
| 32 | ✓ |
| 33 | ✗ |
| 34 | ✗ |
| 35 | ✗ |
| 36 | ✗ |
| 37 | ✗ |
| 38 | ✗ |
| 39 | ✗ |
| 40 | ✗ |
| 41 | ✗ |
| 42 | ✗ |
| 43 | ✗ |
| 44 | ✓ |
| 45 | ✗ |
| 46 | ✗ |
| 47 | ✓ |
| 48 | ✗ |
| 49 | ✗ |
| 50 | ✗ |

All contents of this site are © 2024 Passmedicine Limited

Back to top

A 65-year-old man presents after developing an intensely itchy 'rash' or the dorsum of his left hand. This has now been present for around 6 weeks. He also points out a similar lesion on the dorsum of the right wrist which has appeared in the past week. His past medical history includes type 2 diabetes mellitus and depression. From reviewing his medication history it seems that citalopram has recently been changed to sertraline around 8 weeks ago due to a poor response. The lesion is shown below:

© Image used on license from DermNet NZ

What is the most likely diagnosis?

- Discoid eczema
- Contact dermatitis
- Psoriasis
- Allergic reaction to sertaline
- Lichen planus

Submit answer

Reference ranges

Score: **0%**

1 -
2 -
3 -
4 -
5 -
6 -
7 -
8 -
9 -
10 -
11 -
12 -
13 -
14 -
15 -
**16** -

All contents of this site are © 2024 Passmedicine Limited

A 65-year-old man presents after developing an intensely itchy 'rash' or the dorsum of his left hand. This has now been present for around 6 weeks. He also points out a similar lesion on the dorsum of the right wrist which has appeared in the past week. His past medical history includes type 2 diabetes mellitus and depression. From reviewing his medication history it seems that citalopram has recently been changed to sertraline around 8 weeks ago due to a poor response. The lesion is shown below:

© Image used on license from DermNet NZ

What is the most likely diagnosis?

| | |
|---|---|
| Discoid eczema | 73% |
| Contact dermatitis | 3% |
| Psoriasis | 8% |
| Allergic reaction to sertaline | 7% |
| Lichen planus | 9% |

This lesion is typical of discoid eczema. Lesions are typically well defined, intensely pruritic and

located on the peripheries. Discoid, or nummular, eczema shows a bimodal distribution, being more common in the 20's (predominately females) and the 60's (predominately males).

These lesions are not consistent with an allergic reaction. If the option of a fixed drug eruption had been given the differential would have been much harder as the appearance is much more similar. Fixed drug eruptions however tend to occur within 24 hours of starting the drug and disappear after 10 days.

The location of the lesions is not consistent with contact dermatitis.

Discuss (4) Improve

Next question

## Discoid eczema

Discoid eczema is sometimes referred to as nummular eczema, meaning coin-shaped.

Features

- typically present as round or oval plaques on the extremities
- the lesions are extremely itchy
- central clearing may occur giving a similar appearance to tinea corporis

© Image used on license from DermNet NZ

Image showing discoid eczema

© Image used on license from DermNet NZ

Image showing discoid eczema

© Image used on license from DermNet NZ

Image showing discoid eczema

Management is similar to normal eczema, although co-existent bacterial infection is common and may require treatment.

AI + Q 123

Next question

**Textbooks**

High-yield textbook

Extended textbook

Score: **14%**

| | |
|---|---|
| 1 | ✗ |
| 2 | ✗ |
| 3 | ✓ |
| 4 | ✗ |
| 5 | ✗ |
| 6 | ✗ |
| 7 | ✗ |
| 8 | ✗ |
| 9 | ✗ |
| 10 | ✗ |
| 11 | ✓ |
| 12 | ✗ |
| 13 | ✓ |
| 14 | ✗ |
| 15 | ✗ |
| **16** | ✗ |
| 17 | ✗ |

18 ✗
19 ✗
20 ✗
21 ✗
22 ✗
23 ✗
24 ✗
25 ✗
26 ✓
27 ✗
28 ✗
29 ✗
30 ✗
31 ✗
32 ✓
33 ✗
34 ✗
35 ✗
36 ✗
37 ✗
38 ✗
39 ✗
40 ✗
41 ✗
42 ✗
43 ✗
44 ✓
45 ✗
46 ✗
47 ✓
48 ✗
49 ✗
50 ✗

All contents of this site are © 2024 Passmedicine Limited
Back to top

Please look at the image below:

© Image used on license from DermNet NZ

The lesion has been getting bigger for the past few weeks. There is no history of trauma. What is the most likely diagnosis?

- Basal cell carcinoma
- Seborrhoeic keratosis
- Bowen's disease
- Tinea corporis
- Nummular eczema

Submit answer

Reference ranges

Score: **0%**

| | |
|---|---|
| 1 | - |
| 2 | - |
| 3 | - |
| 4 | - |
| 5 | - |
| 6 | - |
| 7 | - |
| 8 | - |
| 9 | - |
| 10 | - |
| 11 | - |
| 12 | - |
| 13 | - |
| 14 | - |
| 15 | - |
| 16 | - |
| **17** | - |

All contents of this site are © 2024 Passmedicine Limited

Please look at the image below:

© Image used on license from DermNet NZ

The lesion has been getting bigger for the past few weeks. There is no history of trauma. What is the most likely diagnosis?

| | |
|---|---|
| Basal cell carcinoma | 10% |
| Seborrhoeic keratosis | 5% |
| Bowen's disease | 63% |
| Tinea corporis | 3% |
| Nummular eczema | 20% |

Discuss (6) Improve

Next question

# Bowen's disease

Bowen's disease is a type of precancerous dermatosis that is a precursor to squamous cell carcinoma. It is more common in elderly patients. There is around a 5-10% chance of developing invasive skin cancer if left untreated.

Features

- red, scaly patches
  - often 10-15 mm in size
  - slow-growing
  - often occur on sun-exposed areas such as the head (e.g. temples) and neck, lower limbs

Management options:

- may sometimes be diagnosed and managed in primary care if clear diagnosis or repeat episode
- topical 5-fluorouracil
  - typically used twice daily for 4 weeks
  - often results in significant inflammation/erythema. Topical steroids are often given to control this
- cryotherapy
- excision

AI + Q 123

Next question

## Textbooks

High-yield textbook

Extended textbook

**Links**

DermNet NZ 9 9

Bowen's disease

Suggest link Report broken link

Score: **14%**

| | |
|---|---|
| 1 | ✗ |
| 2 | ✗ |
| 3 | ✓ |
| 4 | ✗ |
| 5 | ✗ |
| 6 | ✗ |
| 7 | ✗ |
| 8 | ✗ |
| 9 | ✗ |
| 10 | ✗ |
| 11 | ✓ |
| 12 | ✗ |
| 13 | ✓ |
| 14 | ✗ |
| 15 | ✗ |
| 16 | ✗ |
| **17** | ✗ |
| 18 | ✗ |
| 19 | ✗ |
| 20 | ✗ |

| | |
|---|---|
| 21 | ✗ |
| 22 | ✗ |
| 23 | ✗ |
| 24 | ✗ |
| 25 | ✗ |
| 26 | ✓ |
| 27 | ✗ |
| 28 | ✗ |
| 29 | ✗ |
| 30 | ✗ |
| 31 | ✗ |
| 32 | ✓ |
| 33 | ✗ |
| 34 | ✗ |
| 35 | ✗ |
| 36 | ✗ |
| 37 | ✗ |
| 38 | ✗ |
| 39 | ✗ |
| 40 | ✗ |
| 41 | ✗ |
| 42 | ✗ |
| 43 | ✗ |
| 44 | ✓ |
| 45 | ✗ |
| 46 | ✗ |
| 47 | ✓ |
| 48 | ✗ |
| 49 | ✗ |
| 50 | ✗ |

All contents of this site are © 2024 Passmedicine Limited

A 23-year-old man presents to his General Practitioner with a 3-day history of a widespread rash across his body. He denies fever, pain or itch but is very concerned as the rash is unsightly and is affecting his confidence. Other than recovering from a sore throat and coryzal symptoms over the past week, there is no other past medical history of note and he has no known allergies. He is a teaching assistant in a nursery school.

His rash is examined, as shown below:

© Image used on license from DermNet NZ

What is the most likely diagnosis?

- Disseminated varicella zoster
- Guttate psoriasis
- Pityriasis rosea
- Pityriasis versicolor
- Tinea corporis

Submit answer

Reference ranges

Score: **0%**

| | |
|---|---|
| 1 | - |
| 2 | - |
| 3 | - |
| 4 | - |
| 5 | - |
| 6 | - |
| 7 | - |
| 8 | - |
| 9 | - |
| 10 | - |
| 11 | - |
| 12 | - |
| 13 | - |
| 14 | - |
| 15 | - |
| 16 | - |
| 17 | - |
| **18** | - |

All contents of this site are © 2024 Passmedicine Limited

Back to top

A 23-year-old man presents to his General Practitioner with a 3-day history of a widespread rash across his body. He denies fever, pain or itch but is very concerned as the rash is unsightly and is affecting his confidence. Other than recovering from a sore throat and coryzal symptoms over the past week, there is no other past medical history of note and he has no known allergies. He is a teaching assistant in a nursery school.

His rash is examined, as shown below:

© Image used on license from DermNet NZ

What is the most likely diagnosis?

- Disseminated varicella zoster 3%
- Guttate psoriasis 64%
- Pityriasis rosea 28%
- Pityriasis versicolor 4%
- Tinea corporis 1%

**Guttate psoriasis** is correct. This patient has multiple pinky-red scaly lesions predominantly over his trunk. They are numerous in number and relatively small in size (<1cm) in keeping with guttate psoriasis. These lesions can typically have a tear-drop shape to them. Guttate psoriasis is most

common in children and young adults and often follows an upper respiratory tract infection with *Streptococcus* species (which may be more likely in an occupational setting with young children).

**Disseminated varicella zoster** is incorrect. Chickenpox causes a macular, papular and vesicular rash with crusting of lesions over time. In cases of disseminated chickenpox, there is often cerebral involvement and thrombocytopenia, causing purpura. This is not seen in this scenario.

**Pityriasis rosea** is incorrect. This is a self-limiting rash with no clear cause. The onset of the rash typically begins with a 'herald patch' found on the torso, followed by a widespread salmon-pink or red rash consisting of small (2-5cm) plaques with a peripheral scale. There is no history of a herald patch in this scenario making the diagnosis less likely.

**Pityriasis versicolor** is incorrect. This is a skin infection caused by the *Malassezia* species of yeast. Features of pityriasis versicolor include asymptomatic hyper- or hypopigmentation or pink-coloured skin lesions. It is more common in hot climates where perspiration is frequent.

**Tinea corporis** is incorrect. This is a superficial fungal infection that causes a solitary erythematous and scaly circular lesion on the skin surface. In contrast, this patient has multiple lesions, making tinea corporis incorrect.

Discuss | Improve

Next question

## Guttate psoriasis

Guttate psoriasis is more common in children and adolescents. It may be precipitated by a streptococcal infection 2-4 weeks prior to the lesions appearing.

Features

- tear drop papules on the trunk and limbs
  - *gutta* is Latin for drop
  - pink, scaly patches or plques of psoriasis
- tends to be acute onset over days

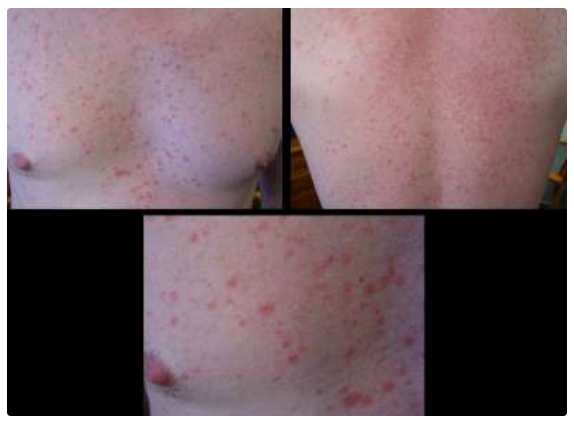

Management

- most cases resolve spontaneously within 2-3 months
- there is no firm evidence to support the use of antibiotics to eradicate streptococcal infection
- topical agents as per psoriasis
- UVB phototherapy
- tonsillectomy may be necessary with recurrent episodes

## Differentiating guttate psoriasis and pityriasis rosea

| | Guttate psoriasis | Pityriasis rosea |
|---|---|---|
| **Prodrome** | Classically preceded by a streptococcal sore throat 2-4 weeks | Many patients report recent respiratory tract infections but this is not common in questions |
| **Appearance** | 'Tear drop', scaly papules on the trunk and limbs | Herald patch followed 1-2 weeks later by multiple erythematous, slightly raised oval lesions with a fine scale confined to the outer aspects of the lesions.<br><br>May follow a characteristic distribution with the longitudinal diameters of the oval lesions running parallel to the line of Langer. This may produce a 'fir-tree' appearance |
| **Treatment / natural history** | Most cases resolve spontaneously within 2-3 months<br>Topical agents as per psoriasis<br>UVB phototherapy | Self-limiting, resolves after around 6 weeks |

123

Next question

## Textbooks

High-yield textbook

Extended textbook

## Links

Clinical Knowledge Summaries 12 7

Guttate psoriasis guidelines

Dermnet NZ 11 3

Guttate psoriasis

Suggest link Report broken link

## Media

Psoriasis

Osmosis - YouTube 2 0

Report broken media

Score: **14%**

| | |
|---|---|
| 1 | ✗ |
| 2 | ✗ |
| 3 | ✓ |
| 4 | ✗ |
| 5 | ✗ |
| 6 | ✗ |
| 7 | ✗ |
| 8 | ✗ |
| 9 | ✗ |
| 10 | ✗ |
| 11 | ✓ |
| 12 | ✗ |
| 13 | ✓ |
| 14 | ✗ |
| 15 | ✗ |
| 16 | ✗ |
| 17 | ✗ |
| **18** | ✗ |
| 19 | ✗ |
| 20 | ✗ |
| 21 | ✗ |
| 22 | ✗ |
| 23 | ✗ |
| 24 | ✗ |
| 25 | ✗ |
| 26 | ✓ |
| 27 | ✗ |
| 28 | ✗ |
| 29 | ✗ |
| 30 | ✗ |
| 31 | ✗ |
| 32 | ✓ |

| | |
|---|---|
| 33 | ✗ |
| 34 | ✗ |
| 35 | ✗ |
| 36 | ✗ |
| 37 | ✗ |
| 38 | ✗ |
| 39 | ✗ |
| 40 | ✗ |
| 41 | ✗ |
| 42 | ✗ |
| 43 | ✗ |
| 44 | ✓ |
| 45 | ✗ |
| 46 | ✗ |
| 47 | ✓ |
| 48 | ✗ |
| 49 | ✗ |
| 50 | ✗ |

All contents of this site are © 2024 Passmedicine Limited

Back to top

A 23-year-old woman who is 10 weeks pregnant presents with a rapidly growing lesion on her finger. This has grown from the size of a 'pin-prick' when it first appeared 4 weeks ago.

© Image used on license from DermNet NZ

What is the most likely diagnosis?

- Viral wart
- Orf
- Pyogenic granuloma
- Capillary haemangioma
- Squamous cell carcinoma

Submit answer

Reference ranges

Score: **0%**

| | |
|---|---|
| 1 | - |
| 2 | - |
| 3 | - |
| 4 | - |
| 5 | - |
| 6 | - |
| 7 | - |
| 8 | - |
| 9 | - |
| 10 | - |
| 11 | - |
| 12 | - |
| 13 | - |
| 14 | - |
| 15 | - |
| 16 | - |
| 17 | - |
| 18 | - |
| **19** | - |

All contents of this site are © 2024 Passmedicine Limited

Back to top

A 23-year-old woman who is 10 weeks pregnant presents with a rapidly growing lesion on her finger. This has grown from the size of a 'pin-prick' when it first appeared 4 weeks ago.

© Image used on license from DermNet NZ

What is the most likely diagnosis?

| | |
|---|---|
| Viral wart | 7% |
| Orf | 17% |
| Pyogenic granuloma | 64% |
| Capillary haemangioma | 4% |
| Squamous cell carcinoma | 7% |

The most likely diagnosis in this case is a **Pyogenic granuloma**. Pyogenic granulomas are benign, vascular skin lesions that grow rapidly over weeks or months. They can occur at any age but are more common in children and young adults, particularly pregnant women due to hormonal changes. The lesion often appears as a small, red, raised bump that may bleed easily. In this case, the rapid growth of the lesion and the patient's pregnancy status make pyogenic granuloma the most likely diagnosis.

A **Viral wart** is less likely because these typically grow slowly over time rather than rapidly.

Moreover, they usually have a rough surface whereas the lesion in question appears smooth.

**Orf** is an infectious disease caused by a parapoxvirus affecting sheep and goats. Humans can contract it through direct contact with infected animals or contaminated objects. However, it usually presents as one or few lesions on hands or fingers with surrounding erythema and regional lymphadenopathy which does not seem to be the case here.

A **Capillary haemangioma**, also known as strawberry naevus, commonly occurs in infants and usually regresses spontaneously by childhood. It would be rare for it to first appear in an adult woman.

Finally, **Squamous cell carcinoma** (SCC) is unlikely given the patient's age - SCC typically occurs in older individuals who have had significant sun exposure over their lifetime. Furthermore, SCCs generally grow slowly over time rather than rapidly.

Discuss (4) Improve

Next question

## Pyogenic granuloma

Pyogenic granuloma is a relatively common benign skin lesion. The name is confusing as they are neither true granulomas nor pyogenic in nature. There are multiple alternative names but perhaps 'eruptive haemangioma' is the most useful.

The cause of pyogenic granuloma is not known but a number of factors are linked:
- trauma
- pregnancy
- more common in women and young adults

Features
- most common sites are head/neck, upper trunk and hands. Lesions in the oral mucosa are common in pregnancy
- initially small red/brown spot
- rapidly progress within days to weeks forming raised, red/brown lesions which are often spherical in shape
- the lesions may bleed profusely or ulcerate

Management

- lesions associated with pregnancy often resolve spontaneously post-partum
- other lesions usually persist. Removal methods include curettage and cauterisation, cryotherapy, excision

123

Next question

**Textbooks**

High-yield textbook

Extended textbook

**Links**

DermNet NZ 8 3

Pyogenic granuloma

Suggest link Report broken link

Score: **14%**

| | |
|---|---|
| 1 | ✗ |
| 2 | ✗ |
| 3 | ✓ |
| 4 | ✗ |
| 5 | ✗ |
| 6 | ✗ |
| 7 | ✗ |
| 8 | ✗ |
| 9 | ✗ |
| 10 | ✗ |
| 11 | ✓ |
| 12 | ✗ |
| 13 | ✓ |
| 14 | ✗ |
| 15 | ✗ |
| 16 | ✗ |
| 17 | ✗ |
| 18 | ✗ |
| **19** | ✗ |
| 20 | ✗ |
| 21 | ✗ |
| 22 | ✗ |
| 23 | ✗ |
| 24 | ✗ |
| 25 | ✗ |
| 26 | ✓ |
| 27 | ✗ |
| 28 | ✗ |
| 29 | ✗ |
| 30 | ✗ |
| 31 | ✗ |
| 32 | ✓ |
| 33 | ✗ |
| 34 | ✗ |

| | |
|---|---|
| 35 | ✗ |
| 36 | ✗ |
| 37 | ✗ |
| 38 | ✗ |
| 39 | ✗ |
| 40 | ✗ |
| 41 | ✗ |
| 42 | ✗ |
| 43 | ✗ |
| 44 | ✓ |
| 45 | ✗ |
| 46 | ✗ |
| 47 | ✓ |
| 48 | ✗ |
| 49 | ✗ |
| 50 | ✗ |

All contents of this site are © 2024 Passmedicine Limited
Back to top

A 54-year-old man presents with a lesion on his forearm. This has been slowly developing over the past 2-3 months and has bled on one occasion. His past medical history includes Alport syndrome for which he had a renal transplant ten years ago. He currently takes ciclosporin as immunosuppression. He also takes ramipril and amlodipine for hypertension. The lesion is shown below:

© Image used on license from DermNet NZ

What is the most likely diagnosis?

- Squamous cell carcinoma
- Basal cell carcinoma
- Pyogenic granuloma
- Haemangioma
- Pyoderma gangrenosum

Submit answer

Reference ranges

Score: **0%**

| | |
|---|---|
| 1 | - |
| 2 | - |
| 3 | - |
| 4 | - |
| 5 | - |
| 6 | - |
| 7 | - |
| 8 | - |
| 9 | - |
| 10 | - |
| 11 | - |
| 12 | - |
| 13 | - |
| 14 | - |
| 15 | - |
| 16 | - |
| 17 | - |
| 18 | - |
| 19 | - |
| **20** | - |

All contents of this site are © 2024 Passmedicine Limited

Back to top

A 54-year-old man presents with a lesion on his forearm. This has been slowly developing over the past 2-3 months and has bled on one occasion. His past medical history includes Alport syndrome for which he had a renal transplant ten years ago. He currently takes ciclosporin as immunosuppression. He also takes ramipril and amlodipine for hypertension. The lesion is shown below:

© Image used on license from DermNet NZ

What is the most likely diagnosis?

| | |
|---|---|
| Squamous cell carcinoma | 56% |
| Basal cell carcinoma | 6% |
| Pyogenic granuloma | 29% |
| Haemangioma | 3% |
| Pyoderma gangrenosum | 7% |

The clue here is immunosuppression. Patients on ciclosporin and other immunosuppressants have a much higher risk of squamous cell carcinoma.

| | | | |
|---|---|---|---|
| 👍 | 👎 | Discuss (5) | Improve |

Next question >

# Squamous cell carcinoma of the skin ★

Squamous cell carcinoma is a common variant of skin cancer. Metastases are rare but may occur in 2-5% of patients.

Risk factors include:

- excessive exposure to sunlight / psoralen UVA therapy
- actinic keratoses and Bowen's disease
- immunosuppression e.g. following renal transplant, HIV
- smoking
- long-standing leg ulcers (Marjolin's ulcer)
- genetic conditions e.g. xeroderma pigmentosum, oculocutaneous albinism

Features

- typically on sun-exposed sites such as the head and neck or dorsum of the hands and arms
- rapidly expanding painless, ulcerate nodules
- may have a cauliflower-like appearance
- there may be areas of bleeding

## Image gallery

## Treatment

Surgical excision with 4mm margins if lesion <20mm in diameter. If tumour >20mm then margins should be 6mm. Mohs micrographic surgery may be used in high-risk patients and in cosmetically important sites.

## Prognosis

| Good Prognosis | Poor prognosis |
|---|---|
| Well differentiated tumours | Poorly differentiated tumours |
| <20mm diameter | >20mm in diameter |
| <2mm deep | >4mm deep |
| No associated diseases | Immunosupression for whatever reason |

+ Q 123

Next question >

Textbooks

High-yield textbook

Extended textbook

Links

DermNet NZ 28 4

Squamous cell carcinoma

Suggest link Report broken link

**Media**

Skin cancers

Osmosis - YouTube 4 1

Report broken media

Score: **14%**

| | |
|---|---|
| 1 | ✗ |
| 2 | ✗ |
| 3 | ✓ |
| 4 | ✗ |
| 5 | ✗ |
| 6 | ✗ |
| 7 | ✗ |
| 8 | ✗ |
| 9 | ✗ |
| 10 | ✗ |
| 11 | ✓ |
| 12 | ✗ |
| 13 | ✓ |
| 14 | ✗ |
| 15 | ✗ |
| 16 | ✗ |
| 17 | ✗ |
| 18 | ✗ |
| 19 | ✗ |
| **20** | ✗ |
| 21 | ✗ |

| | |
|---|---|
| 22 | ✗ |
| 23 | ✗ |
| 24 | ✗ |
| 25 | ✗ |
| 26 | ✓ |
| 27 | ✗ |
| 28 | ✗ |
| 29 | ✗ |
| 30 | ✗ |
| 31 | ✗ |
| 32 | ✓ |
| 33 | ✗ |
| 34 | ✗ |
| 35 | ✗ |
| 36 | ✗ |
| 37 | ✗ |
| 38 | ✗ |
| 39 | ✗ |
| 40 | ✗ |
| 41 | ✗ |
| 42 | ✗ |
| 43 | ✗ |
| 44 | ✓ |
| 45 | ✗ |
| 46 | ✗ |
| 47 | ✓ |
| 48 | ✗ |
| 49 | ✗ |
| 50 | ✗ |

All contents of this site are © 2024 Passmedicine Limited

Back to top

A 50-year-old man who has had a cough for the past week develops a rash. It initially appeared on his arms but has now spread to the torso:

© Image used on license from DermNet NZ

What is the most likely underlying diagnosis?

- Goodpasture's syndrome
- Adenovirus
- *Mycoplasma pneumoniae*
- *Legionella pneumophilia*
- Rhinovirus

Submit answer

Reference ranges

Score: **0%**

| | |
|---|---|
| 1 | - |
| 2 | - |
| 3 | - |
| 4 | - |
| 5 | - |
| 6 | - |
| 7 | - |
| 8 | - |
| 9 | - |
| 10 | - |
| 11 | - |
| 12 | - |
| 13 | - |
| 14 | - |
| 15 | - |
| 16 | - |
| 17 | - |
| 18 | - |
| 19 | - |
| 20 | - |
| **21** | - |

All contents of this site are © 2024 Passmedicine Limited

Back to top

A 50-year-old man who has had a cough for the past week develops a rash. It initially appeared on his arms but has now spread to the torso:

© Image used on license from DermNet NZ

What is the most likely underlying diagnosis?

- Goodpasture's syndrome — 3%
- Adenovirus — 9%
- *Mycoplasma pneumoniae* — 84%
- *Legionella pneumophilia* — 2%
- Rhinovirus — 2%

This patient has developed erythema multiforme (EM), a known complication of Mycoplasma infection. *Mycoplasma pneumoniae* is the second most common trigger of EM after the herpes simplex virus.

Discuss (2) Improve

Next question

# Erythema multiforme ★

Erythema multiforme is a hypersensitivity reaction that is most commonly triggered by infections. It may be divided into minor and major forms.

Previously it was thought that Stevens-Johnson syndrome (SJS) was a severe form of erythema multiforme. They are now however considered as separate entities.

Features

- target lesions
- initially seen on the back of the hands / feet before spreading to the torso
- upper limbs are more commonly affected than the lower limbs
- pruritus is occasionally seen and is usually mild

Causes

- viruses: herpes simplex virus (the most common cause), Orf*
- idiopathic
- bacteria: *Mycoplasma*, *Streptococcus*
- drugs: penicillin, sulphonamides, carbamazepine, allopurinol, NSAIDs, oral contraceptive pill, nevirapine
- connective tissue disease e.g. Systemic lupus erythematosus
- sarcoidosis
- malignancy

## Erythema multiforme major

The more severe form, erythema multiforme major is associated with mucosal involvement.

*Orf is a skin disease of sheep and goats caused by a parapox virus

123

Next question

## Textbooks

High-yield textbook

Extended textbook

## Links

DermNet NZ 18 10

Erythema multiforme

Suggest link Report broken link

## Media

Erythema multiforme

Osmosis - YouTube 1 0

Report broken media

Score: **14%**

| | |
|---|---|
| 1 | ✗ |
| 2 | ✗ |
| 3 | ✓ |
| 4 | ✗ |
| 5 | ✗ |
| 6 | ✗ |
| 7 | ✗ |
| 8 | ✗ |
| 9 | ✗ |
| 10 | ✗ |
| 11 | ✓ |
| 12 | ✗ |
| 13 | ✓ |
| 14 | ✗ |
| 15 | ✗ |
| 16 | ✗ |
| 17 | ✗ |
| 18 | ✗ |
| 19 | ✗ |
| 20 | ✗ |
| **21** | ✗ |
| 22 | ✗ |
| 23 | ✗ |

| | |
|---|---|
| 24 | ✗ |
| 25 | ✗ |
| 26 | ✓ |
| 27 | ✗ |
| 28 | ✗ |
| 29 | ✗ |
| 30 | ✗ |
| 31 | ✗ |
| 32 | ✓ |
| 33 | ✗ |
| 34 | ✗ |
| 35 | ✗ |
| 36 | ✗ |
| 37 | ✗ |
| 38 | ✗ |
| 39 | ✗ |
| 40 | ✗ |
| 41 | ✗ |
| 42 | ✗ |
| 43 | ✗ |
| 44 | ✓ |
| 45 | ✗ |
| 46 | ✗ |
| 47 | ✓ |
| 48 | ✗ |
| 49 | ✗ |
| 50 | ✗ |

All contents of this site are © 2024 Passmedicine Limited

Back to top

A 67-year-old gentleman is reviewed in the medical clinic. He was diagnosed by his GP with scabies two weeks ago, but despite treatment he has ongoing itching. He was diagnosed following a GP visit to his house which was found to be unkempt. He was treated with permethrin 5% with the aid of his daughter, who has confirmed that his whole body was treated in two sessions, one week apart, and that his clothes were washed at high temperature at both occasions, as well as his bed sheets.

He has a past medical history of heart failure, ischaemic heart disease and dementia. He lives on his own with the assistance of his daughters. He normally takes bisoprolol, aspirin, ramipril and simvastatin. On examination, there are burrows with track marks on his fingers. What is the most appropriate plan?

- Investigate for immunosuppression
- Repeat treatment with permethrin 5%
- Treat with malathion 0.5%
- No further treatment needed
- Skin biopsy

Submit answer

Reference ranges

Score: **0%**

1 -
2 -
3 -
4 -

| | |
|---|---|
| 5 | - |
| 6 | - |
| 7 | - |
| 8 | - |
| 9 | - |
| 10 | - |
| 11 | - |
| 12 | - |
| 13 | - |
| 14 | - |
| 15 | - |
| 16 | - |
| 17 | - |
| 18 | - |
| 19 | - |
| 20 | - |
| 21 | - |
| **22** | - |

All contents of this site are © 2024 Passmedicine Limited

A 67-year-old gentleman is reviewed in the medical clinic. He was diagnosed by his GP with scabies two weeks ago, but despite treatment he has ongoing itching. He was diagnosed following a GP visit to his house which was found to be unkempt. He was treated with permethrin 5% with the aid of his daughter, who has confirmed that his whole body was treated in two sessions, one week apart, and that his clothes were washed at high temperature at both occasions, as well as his bed sheets.

He has a past medical history of heart failure, ischaemic heart disease and dementia. He lives on his own with the assistance of his daughters. He normally takes bisoprolol, aspirin, ramipril and simvastatin. On examination, there are burrows with track marks on his fingers. What is the most appropriate plan?

| | |
|---|---|
| Investigate for immunosuppression | 12% |
| Repeat treatment with permethrin 5% | 16% |
| Treat with malathion 0.5% | 45% |
| No further treatment needed | 25% |
| Skin biopsy | 2% |

In scabies treatment failure, if application was applied appropriately, then treat with difference insecticide, e.g. malathion 0.5% or permethrin 5%

Important for me Less important

This is a patient with scabies who has failed treatment despite correct treatment. Whilst patients with may have pruritus until six weeks following treatment completion, there should not be any burrows. For such patients they should be treated with malathion 0.5% if they have been treated correctly with permethrin 5%. If they were treated with malathion 0.9% then they should be treated with permethrin 5%. Skin biopsy is not needed, and immunosuppression is unlikely; only if evidence crusted scabies should this be done, or if extremely wide-spread.

Discuss (5) Improve

Next question

# Scabies

Scabies is caused by the mite *Sarcoptes scabiei* and is spread by prolonged skin contact. It typically affects children and young adults.

The scabies mite burrows into the skin, laying its eggs in the stratum corneum. The intense pruritus associated with scabies is due to a delayed-type IV hypersensitivity reaction to mites/eggs which occurs about 30 days after the initial infection.

Features

- widespread pruritus
- linear burrows on the side of fingers, interdigital webs and flexor aspects of the wrist
- in infants, the face and scalp may also be affected
- secondary features are seen due to scratching: excoriation, infection

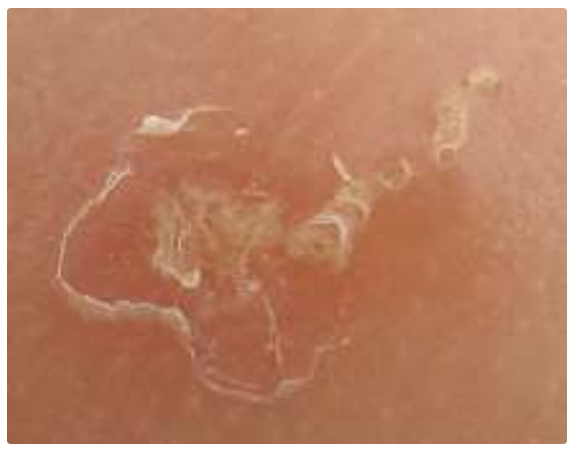

Management

- permethrin 5% is first-line
- malathion 0.5% is second-line
- give appropriate guidance on use (see below)
- pruritus persists for up to 4-6 weeks post eradication

Patient guidance on treatment

- avoid close physical contact with others until treatment is complete
- all household and close physical contacts should be treated at the same time, even if asymptomatic
- launder, iron or tumble dry clothing, bedding, towels, etc., on the first day of treatment to kill off mites.

The BNF advises to apply the insecticide to all areas, including the face and scalp, contrary to the manufacturer's recommendation. Patients should be given the following instructions:

- apply the insecticide cream or liquid to cool, dry skin
- pay close attention to areas between fingers and toes, under nails, armpit area, creases of the skin such as at the wrist and elbow
- allow to dry and leave on the skin for 8-12 hours for permethrin, or for 24 hours for malathion, before washing off
- reapply if insecticide is removed during the treatment period, e.g. If wash hands, change nappy, etc
- repeat treatment 7 days later

## Crusted (Norwegian) scabies

Crusted scabies is seen in patients with suppressed immunity, especially HIV.

© Image used on license from DermNet NZ

The crusted skin will be teeming with hundreds of thousands of organisms.

Ivermectin is the treatment of choice and isolation is essential

+ Q 123

Next question >

## Textbooks

High-yield textbook

Extended textbook

## Links

Clinical Knowledge Summaries 19 14

Scabies guidelines

Suggest link Report broken link

Score: **14%**

| | |
|---|---|
| 1 | ✗ |
| 2 | ✗ |
| 3 | ✓ |
| 4 | ✗ |
| 5 | ✗ |
| 6 | ✗ |
| 7 | ✗ |
| 8 | ✗ |
| 9 | ✗ |
| 10 | ✗ |
| 11 | ✓ |
| 12 | ✗ |
| 13 | ✓ |
| 14 | ✗ |
| 15 | ✗ |
| 16 | ✗ |
| 17 | ✗ |
| 18 | ✗ |

| | |
|---|---|
| 19 | ✗ |
| 20 | ✗ |
| 21 | ✗ |
| **22** | ✗ |
| 23 | ✗ |
| 24 | ✗ |
| 25 | ✗ |
| 26 | ✓ |
| 27 | ✗ |
| 28 | ✗ |
| 29 | ✗ |
| 30 | ✗ |
| 31 | ✗ |
| 32 | ✓ |
| 33 | ✗ |
| 34 | ✗ |
| 35 | ✗ |
| 36 | ✗ |
| 37 | ✗ |
| 38 | ✗ |
| 39 | ✗ |
| 40 | ✗ |
| 41 | ✗ |
| 42 | ✗ |
| 43 | ✗ |
| 44 | ✓ |
| 45 | ✗ |
| 46 | ✗ |
| 47 | ✓ |
| 48 | ✗ |
| 49 | ✗ |
| 50 | ✗ |

All contents of this site are © 2024 Passmedicine Limited

Back to top

A 60-year-old man asks you to have a look at a 'sore' on his right ear.

© Image used on license from DermNet NZ and with the kind permission of Prof Raimo Suhonen

It has been present for around 6 months and is not painful. What is the most likely diagnosis?

- Fungal otitis externa
- Actinic keratosis
- Pyogenic granuloma
- Basal cell carcinoma
- Chondrodermatitis nodularis helicis

Submit answer

Reference ranges

Score: **0%**

| | |
|---|---|
| 1 | - |
| 2 | - |
| 3 | - |
| 4 | - |
| 5 | - |
| 6 | - |
| 7 | - |
| 8 | - |
| 9 | - |
| 10 | - |
| 11 | - |
| 12 | - |
| 13 | - |
| 14 | - |
| 15 | - |
| 16 | - |
| 17 | - |
| 18 | - |
| 19 | - |
| 20 | - |
| 21 | - |
| 22 | - |
| **23** | - |

All contents of this site are © 2024 Passmedicine Limited

A 60-year-old man asks you to have a look at a 'sore' on his right ear.

© Image used on license from DermNet NZ and with the kind permission of Prof Raimo Suhonen

It has been present for around 6 months and is not painful. What is the most likely diagnosis?

| | |
|---|---|
| Fungal otitis externa | 2% |
| Actinic keratosis | 24% |
| Pyogenic granuloma | 3% |
| Basal cell carcinoma | 6% |
| Chondrodermatitis nodularis helicis | 64% |

Chondrodermatitis nodularis helicis is usually painful.

Discuss (6) Improve

Next question

# Actinic keratoses

Actinic, or solar, keratoses (AK) is a common premalignant skin lesion that develops as a consequence of chronic sun exposure

Features

- small, crusty or scaly, lesions
- may be pink, red, brown or the same colour as the skin
- typically on sun-exposed areas e.g. temples of head
- multiple lesions may be present

Management options include

- prevention of further risk: e.g. sun avoidance, sun cream
- fluorouracil cream: typically a 2 to 3 week course. The skin will become red and inflamed - sometimes topical hydrocortisone is given following fluorouracil to help settle the inflammation
- topical diclofenac: may be used for mild AKs. Moderate efficacy but much fewer side-effects
- topical imiquimod: trials have shown good efficacy
- cryotherapy
- curettage and cautery

+ Q 123

Next question >

**Textbooks**

High-yield textbook

Extended textbook

## Links

British Association of Dermatologists 👍 9 👎 9

2017 Actinic keratoses guidelines

DermNet NZ 👍 27 👎 11

Actinic keratoses

Primary Care Dermatology Society 👍 14 👎 5

Actinic keratosis

Suggest link | Report broken link

Score: **14%**

1 ✗
2 ✗
3 ✓
4 ✗
5 ✗
6 ✗
7 ✗
8 ✗
9 ✗
10 ✗
11 ✓
12 ✗
13 ✓

| | |
|---|---|
| 14 | ✗ |
| 15 | ✗ |
| 16 | ✗ |
| 17 | ✗ |
| 18 | ✗ |
| 19 | ✗ |
| 20 | ✗ |
| 21 | ✗ |
| 22 | ✗ |
| **23** | ✗ |
| 24 | ✗ |
| 25 | ✗ |
| 26 | ✓ |
| 27 | ✗ |
| 28 | ✗ |
| 29 | ✗ |
| 30 | ✗ |
| 31 | ✗ |
| 32 | ✓ |
| 33 | ✗ |
| 34 | ✗ |
| 35 | ✗ |
| 36 | ✗ |
| 37 | ✗ |
| 38 | ✗ |
| 39 | ✗ |
| 40 | ✗ |
| 41 | ✗ |
| 42 | ✗ |
| 43 | ✗ |
| 44 | ✓ |
| 45 | ✗ |
| 46 | ✗ |
| 47 | ✓ |
| 48 | ✗ |
| 49 | ✗ |

50 ✗

All contents of this site are © 2024 Passmedicine Limited

A 31-year-old man presents with an itchy rash that has been present for several weeks, across both the elbows and knees. He mentions general fatigue but is otherwise well in himself.

On examination, the rash appears as shown below:

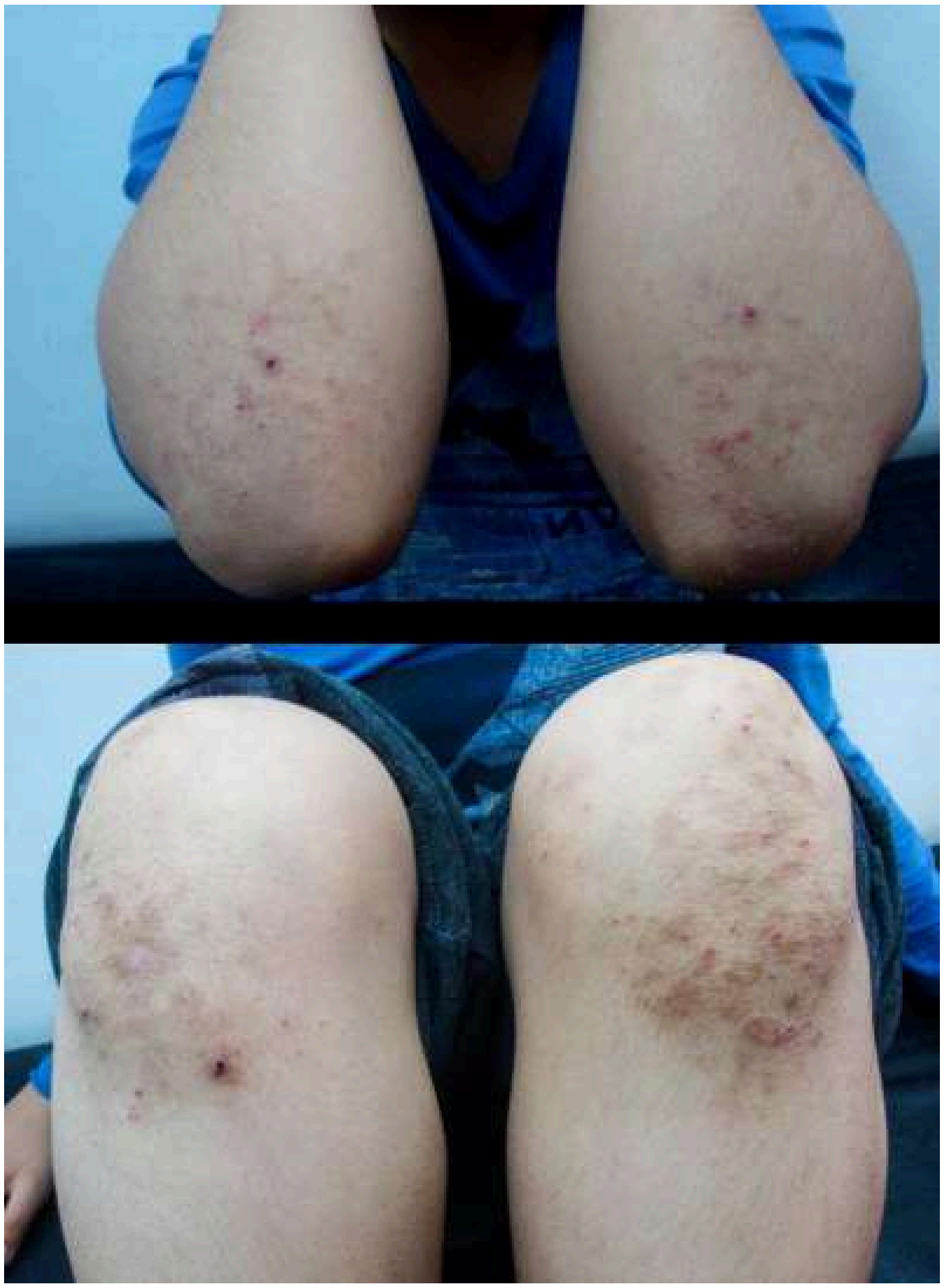

© Image used on license from DermNet NZ

Blood tests are also performed:

| | | |
|---|---|---|
| Hb | 118 g/L | Male: (135-180)<br>Female: (115 - 160) |
| Platelets | 267 * $10^9$/L | (150 - 400) |
| WBC | 5.6 * $10^9$/L | (4.0 - 11.0) |
| $Na^+$ | 137 mmol/L | (135 - 145) |

| | | |
|---|---|---|
| $K^+$ | 3.8 mmol/L | (3.5 - 5.0) |
| Urea | 5.8 mmol/L | (2.0 - 7.0) |
| Creatinine | 62 µmol/L | (55 - 120) |
| CRP | 4 mg/L | (< 5) |

Given the likely diagnosis, which of the following is the most appropriate first-line treatment?

- Oral dapsone
- Oral prednisolone
- Topical calcipotriol
- Topical clobetasol
- Topical tacrolimus

Submit answer

Reference ranges

Score: **0%**

1 -
2 -
3 -
4 -
5 -
6 -
7 -
8 -
9 -
10 -
11 -
12 -

| | |
|---|---|
| 13 | - |
| 14 | - |
| 15 | - |
| 16 | - |
| 17 | - |
| 18 | - |
| 19 | - |
| 20 | - |
| 21 | - |
| 22 | - |
| 23 | - |
| **24** | - |

All contents of this site are © 2024 Passmedicine Limited

Back to top

A 31-year-old man presents with an itchy rash that has been present for several weeks, across both the elbows and knees. He mentions general fatigue but is otherwise well in himself.

On examination, the rash appears as shown below:

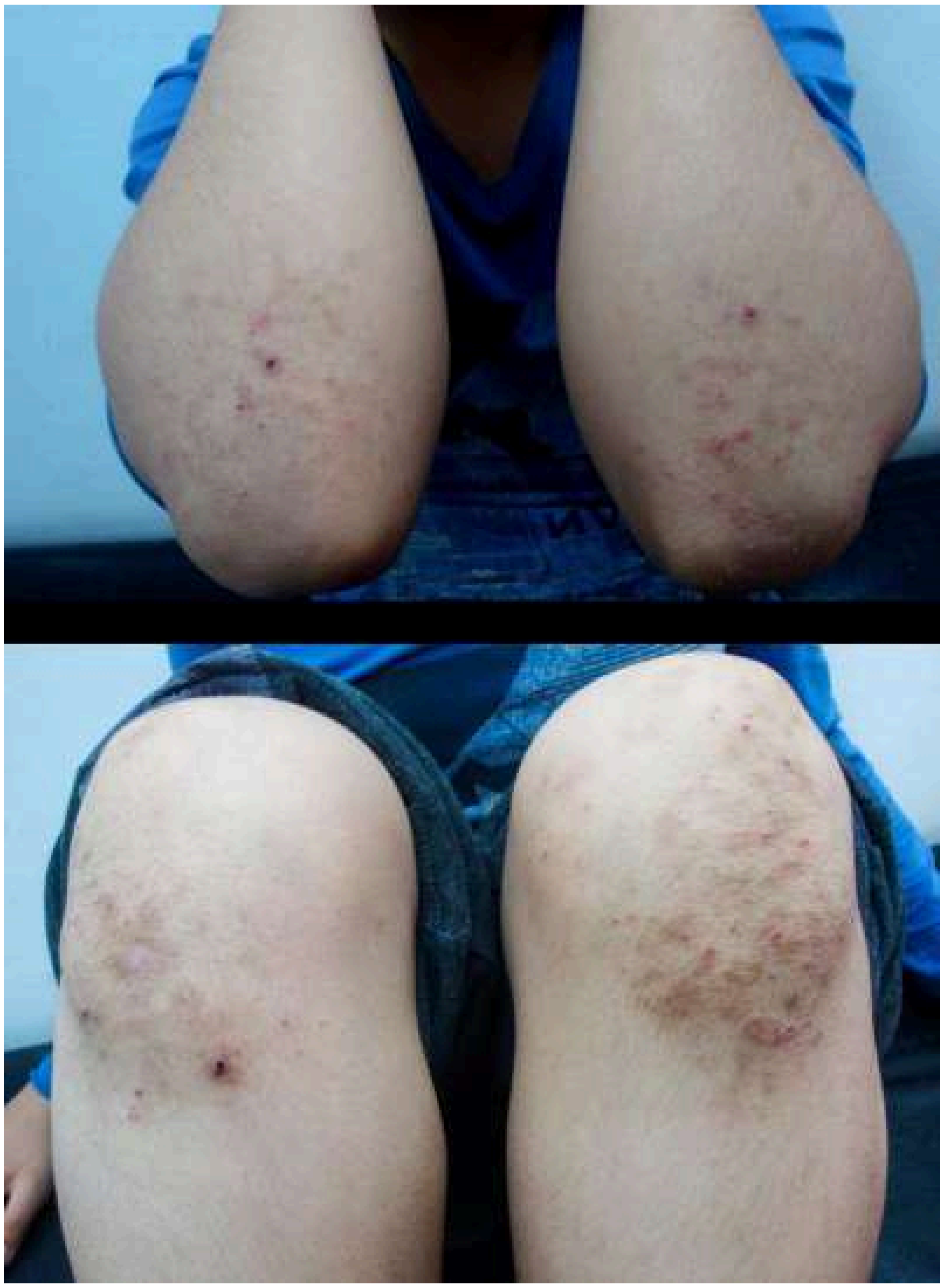

© Image used on license from DermNet NZ

Blood tests are also performed:

| | | |
|---|---|---|
| Hb | 118 g/L | Male: (135-180)<br>Female: (115 - 160) |
| Platelets | 267 * $10^9$/L | (150 - 400) |
| WBC | 5.6 * $10^9$/L | (4.0 - 11.0) |
| $Na^+$ | 137 mmol/L | (135 - 145) |

| | | |
|---|---|---|
| $K^+$ | 3.8 mmol/L | (3.5 - 5.0) |
| Urea | 5.8 mmol/L | (2.0 - 7.0) |
| Creatinine | 62 μmol/L | (55 - 120) |
| CRP | 4 mg/L | (< 5) |

Given the likely diagnosis, which of the following is the most appropriate first-line treatment?

| | |
|---|---|
| Oral dapsone | 76% |
| Oral prednisolone | 4% |
| Topical calcipotriol | 7% |
| Topical clobetasol | 11% |
| Topical tacrolimus | 2% |

The diagnosis is that of dermatitis herpetiformis. The photo shows a bilateral, symmetrical, papulovesicular rash across the elbows and knees. This is consistent with dermatitis herpetiformis, which usually overlies extensor surfaces. The lesions appear excoriated due to pruritus. Dermatitis herpetiformis is strongly associated with coeliac disease, which is likely in this case, particularly given the concomitant anaemia and fatigue. Initial management involves the use of oral dapsone.

If initial measures were to fail, oral prednisolone may be used. However, for first-line management, oral dapsone is usually used for dermatitis herpetiformis.

Topical calcipotriol is a vitamin D analogue commonly used in the management of psoriasis. The images here do not clearly demonstrate psoriatic plaques, which would have a scaly appearance - rather, the papulovesicular rash is more suggestive of dermatitis herpetiformis.

Topical clobetasol is a second-line option for dermatitis herpetiformis. First-line, oral dapsone remains the most appropriate option.

Topical tacrolimus is a steroid-sparing agent sometimes used for steroid-resistant eczema, especially for children and on sensitive areas such as the face. It also plays a role in the management of other conditions such as bullous pemphigoid. It is not routinely used in dermatitis herpetiformis.

Discuss (1) Improve

Next question ›

# Dermatitis herpetiformis

Dermatitis herpetiformis is an autoimmune blistering skin disorder associated with coeliac disease. It is caused by deposition of IgA in the dermis. More than 90% of patients exhibit small bowel biopsy findings consistent with some degree of gluten-sensitive enteropathy.

Features
- itchy, vesicular skin lesions on the extensor surfaces (e.g. elbows, knees, buttocks)

Diagnosis
- skin biopsy: direct immunofluorescence shows deposition of IgA in a granular pattern in the upper dermis

Management
- gluten-free diet
- dapsone

AI + Q 123

Next question ›

## Textbooks

High-yield textbook

Extended textbook

## Links

DermNet NZ 34 6

Dermatitis herpetiformis

Suggest link Report broken link

Score: **14%**

| | |
|---|---|
| 1 | ✗ |
| 2 | ✗ |
| 3 | ✓ |
| 4 | ✗ |
| 5 | ✗ |
| 6 | ✗ |
| 7 | ✗ |
| 8 | ✗ |
| 9 | ✗ |
| 10 | ✗ |
| 11 | ✓ |
| 12 | ✗ |
| 13 | ✓ |
| 14 | ✗ |
| 15 | ✗ |
| 16 | ✗ |
| 17 | ✗ |
| 18 | ✗ |
| 19 | ✗ |

| | |
|---|---|
| 20 | ✗ |
| 21 | ✗ |
| 22 | ✗ |
| 23 | ✗ |
| **24** | ✗ |
| 25 | ✗ |
| 26 | ✓ |
| 27 | ✗ |
| 28 | ✗ |
| 29 | ✗ |
| 30 | ✗ |
| 31 | ✗ |
| 32 | ✓ |
| 33 | ✗ |
| 34 | ✗ |
| 35 | ✗ |
| 36 | ✗ |
| 37 | ✗ |
| 38 | ✗ |
| 39 | ✗ |
| 40 | ✗ |
| 41 | ✗ |
| 42 | ✗ |
| 43 | ✗ |
| 44 | ✓ |
| 45 | ✗ |
| 46 | ✗ |
| 47 | ✓ |
| 48 | ✗ |
| 49 | ✗ |
| 50 | ✗ |

All contents of this site are © 2024 Passmedicine Limited

Back to top

A 60-year-old man with a history of renal transplant presents to the dermatology clinic.

He has a 7mm scaly nodular lesion on his left left forearm with an inflamed red base. This appears similar to two squamous cell skin carcinomas he has had excised in the past. The lesion is not painful and he has no lymphadenopathy.

He continues to take tacrolimus, though his dose was lowered following his last squamous cell carcinoma excision. He also suffers from hypertension which is well controlled on ramipril.

His blood tests are as follows:

| | | | |
|---|---|---|---|
| Hb | 120 g/l | $Na^+$ | 136 mmol/l |
| Platelets | 308 * $10^9$/l | $K^+$ | 4.9 mmol/l |
| WBC | 6 * $10^9$/l | Urea | 5 mmol/l |
| Neuts | 4 * $10^9$/l | Creatinine | 98 µmol/l |

What is the most appropriate management?

- Curettage and acitretin
- Radiotherapy and acitretin
- Surgery alone
- Surgery and acitretin
- Systemic chemotherapy

Submit answer

Reference ranges

Score: **0%**

| | |
|---|---|
| 1 | - |
| 2 | - |
| 3 | - |
| 4 | - |
| 5 | - |
| 6 | - |
| 7 | - |
| 8 | - |
| 9 | - |
| 10 | - |
| 11 | - |
| 12 | - |
| 13 | - |
| 14 | - |
| 15 | - |
| 16 | - |
| 17 | - |
| 18 | - |
| 19 | - |
| 20 | - |
| 21 | - |
| 22 | - |
| 23 | - |
| 24 | - |
| **25** | - |

All contents of this site are © 2024 Passmedicine Limited

A 60-year-old man with a history of renal transplant presents to the dermatology clinic.

He has a 7mm scaly nodular lesion on his left left forearm with an inflamed red base. This appears similar to two squamous cell skin carcinomas he has had excised in the past. The lesion is not painful and he has no lymphadenopathy.

He continues to take tacrolimus, though his dose was lowered following his last squamous cell carcinoma excision. He also suffers from hypertension which is well controlled on ramipril.

His blood tests are as follows:

| | | | |
|---|---|---|---|
| Hb | 120 g/l | $Na^+$ | 136 mmol/l |
| Platelets | 308 * $10^9$/l | $K^+$ | 4.9 mmol/l |
| WBC | 6 * $10^9$/l | Urea | 5 mmol/l |
| Neuts | 4 * $10^9$/l | Creatinine | 98 µmol/l |

What is the most appropriate management?

- Curettage and acitretin 13%
- Radiotherapy and acitretin 4%
- Surgery alone 34%
- Surgery and acitretin 46%
- Systemic chemotherapy 3%

This man has a high risk squamous cell carcinoma (SCC) of the skin given that he is on immunosuppression. He also has a history of previous SCC. Given these factors, surgery is indicated and systemic retinoids, such as acitretin, should be considered to prevent further SCCs.

Curettage is acceptable management for a low risk SCCs. Radiotherapy would be considered post-operatively if there were inadequate tumour margins or evidence of invasion at surgery but is not an appropriate a primary curative therapy in this case. Studies to date have not shown sufficient evidence for systemic chemotherapy for SCC.

In patients on immunosuppression with recurrent SCC, reduction of immunosuppression should be considered and discussion at a multidisciplinary team meeting is warranted.

Reference: Scottish Intercollegiate Guidelines Network. 2014. SIGN 140. Management of primary cutaneous squamous cell carcinoma.

Discuss (5) Improve

Next question

## Squamous cell carcinoma of the skin

Squamous cell carcinoma is a common variant of skin cancer. Metastases are rare but may occur in 2-5% of patients.

Risk factors include:
- excessive exposure to sunlight / psoralen UVA therapy
- actinic keratoses and Bowen's disease
- immunosuppression e.g. following renal transplant, HIV
- smoking
- long-standing leg ulcers (Marjolin's ulcer)
- genetic conditions e.g. xeroderma pigmentosum, oculocutaneous albinism

Features
- typically on sun-exposed sites such as the head and neck or dorsum of the hands and arms
- rapidly expanding painless, ulcerate nodules
- may have a cauliflower-like appearance
- there may be areas of bleeding

## Image gallery

## Treatment

Surgical excision with 4mm margins if lesion <20mm in diameter. If tumour >20mm then margins should be 6mm. Mohs micrographic surgery may be used in high-risk patients and in cosmetically important sites.

## Prognosis

| **Good Prognosis** | **Poor prognosis** |
|---|---|
| Well differentiated tumours | Poorly differentiated tumours |
| <20mm diameter | >20mm in diameter |
| <2mm deep | >4mm deep |
| No associated diseases | Immunosupression for whatever reason |

+ Q 123

Next question >

**Textbooks**

High-yield textbook

Extended textbook

## Links

DermNet NZ 28 4

Squamous cell carcinoma

Suggest link Report broken link

## Media

Skin cancers

Osmosis - YouTube 4 1

Report broken media

Score: **14%**

1 ✗
2 ✗
3 ✓
4 ✗
5 ✗
6 ✗
7 ✗
8 ✗
9 ✗
10 ✗
11 ✓
12 ✗
13 ✓
14 ✗
15 ✗

| | |
|---|---|
| 16 | ✗ |
| 17 | ✗ |
| 18 | ✗ |
| 19 | ✗ |
| 20 | ✗ |
| 21 | ✗ |
| 22 | ✗ |
| 23 | ✗ |
| 24 | ✗ |
| **25** | ✗ |
| 26 | ✓ |
| 27 | ✗ |
| 28 | ✗ |
| 29 | ✗ |
| 30 | ✗ |
| 31 | ✗ |
| 32 | ✓ |
| 33 | ✗ |
| 34 | ✗ |
| 35 | ✗ |
| 36 | ✗ |
| 37 | ✗ |
| 38 | ✗ |
| 39 | ✗ |
| 40 | ✗ |
| 41 | ✗ |
| 42 | ✗ |
| 43 | ✗ |
| 44 | ✓ |
| 45 | ✗ |
| 46 | ✗ |
| 47 | ✓ |
| 48 | ✗ |
| 49 | ✗ |
| 50 | ✗ |

All contents of this site are © 2024 Passmedicine Limited 

A 41-year-old woman shows you a rash on her legs:

© Image used on license from DermNet NZ

What is the most likely cause of such a rash?

- Domestic abuse
- Excessive ultraviolet light
- Drug reaction
- Infrared radiation
- Syphilis

Submit answer

Reference ranges

Score: **0%**

| | |
|---|---|
| 1 | - |
| 2 | - |
| 3 | - |
| 4 | - |
| 5 | - |
| 6 | - |
| 7 | - |
| 8 | - |
| 9 | - |
| 10 | - |
| 11 | - |
| 12 | - |
| 13 | - |
| 14 | - |
| 15 | - |
| 16 | - |
| 17 | - |
| 18 | - |
| 19 | - |
| 20 | - |
| 21 | - |
| 22 | - |
| 23 | - |
| 24 | - |
| 25 | - |
| **26** | - |

All contents of this site are © 2024 Passmedicine Limited

A 41-year-old woman shows you a rash on her legs:

© Image used on license from DermNet NZ

What is the most likely cause of such a rash?

| | |
|---|---|
| Domestic abuse | 2% |
| Excessive ultraviolet light | 21% |
| Drug reaction | 15% |
| Infrared radiation | 59% |
| Syphilis | 4% |

This patient has erythema ab igne, a skin reaction caused by excessive infrared radiation.

Discuss (7) Improve

Next question

# Erythema ab igne

Erythema ab igne is a skin disorder caused by over exposure to infrared radiation. Characteristic features include reticulated, erythematous patches with hyperpigmentation and telangiectasia. A typical history would be an elderly women who always sits next to an open fire.

If the cause is not treated then patients may go on to develop squamous cell skin cancer.

© Image used on license from DermNet NZ

Erythema ab igne

© Image used on license from DermNet NZ

Erythema ab igne

AI + Q 123

Next question >

## Textbooks

High-yield textbook

Extended textbook

## Links

DermNet NZ 7 5

Erythema ab igne

Suggest link

Report broken link

Score: **14%**

| | |
|---|---|
| 1 | ✗ |
| 2 | ✗ |
| 3 | ✓ |
| 4 | ✗ |
| 5 | ✗ |
| 6 | ✗ |
| 7 | ✗ |
| 8 | ✗ |
| 9 | ✗ |
| 10 | ✗ |
| 11 | ✓ |
| 12 | ✗ |
| 13 | ✓ |
| 14 | ✗ |
| 15 | ✗ |
| 16 | ✗ |
| 17 | ✗ |
| 18 | ✗ |
| 19 | ✗ |
| 20 | ✗ |
| 21 | ✗ |
| 22 | ✗ |
| 23 | ✗ |
| 24 | ✗ |
| 25 | ✗ |
| **26** | ✓ |
| 27 | ✗ |
| 28 | ✗ |
| 29 | ✗ |
| 30 | ✗ |
| 31 | ✗ |
| 32 | ✓ |

| | |
|---|---|
| 33 | ✗ |
| 34 | ✗ |
| 35 | ✗ |
| 36 | ✗ |
| 37 | ✗ |
| 38 | ✗ |
| 39 | ✗ |
| 40 | ✗ |
| 41 | ✗ |
| 42 | ✗ |
| 43 | ✗ |
| 44 | ✓ |
| 45 | ✗ |
| 46 | ✗ |
| 47 | ✓ |
| 48 | ✗ |
| 49 | ✗ |
| 50 | ✗ |

All contents of this site are © 2024 Passmedicine Limited

Back to top

A 79-year-old woman presents with an itchy, blistering rash. Examination of her mouth is unremarkable.

© Image used on license from DermNet NZ and with the kind permission of Prof Raimo Suhonen

What is the most likely diagnosis?

- Dermatitis herpetiformis
- Drug reaction to lisinopril
- Bullous pemphigoid
- Pemphigus vulgaris
- Epidermolysis bullosa

Submit answer

Reference ranges

Score: **0%**

| | |
|---|---|
| 1 | - |
| 2 | - |
| 3 | - |
| 4 | - |
| 5 | - |
| 6 | - |
| 7 | - |
| 8 | - |
| 9 | - |
| 10 | - |
| 11 | - |
| 12 | - |
| 13 | - |
| 14 | - |
| 15 | - |
| 16 | - |
| 17 | - |
| 18 | - |
| 19 | - |
| 20 | - |
| 21 | - |
| 22 | - |
| 23 | - |
| 24 | - |
| 25 | - |
| 26 | - |
| **27** | - |

All contents of this site are © 2024 Passmedicine Limited

A 79-year-old woman presents with an itchy, blistering rash. Examination of her mouth is unremarkable.

© Image used on license from DermNet NZ and with the kind permission of Prof Raimo Suhonen

What is the most likely diagnosis?

| | |
|---|---|
| Dermatitis herpetiformis | 0% |
| Drug reaction to lisinopril | 1% |
| Bullous pemphigoid | 85% |
| Pemphigus vulgaris | 12% |
| Epidermolysis bullosa | 2% |

Blisters/bullae

- no mucosal involvement (in exams at least*): bullous pemphigoid
- mucosal involvement: pemphigus vulgaris

Important for me Less important

The correct answer to this question is **Bullous pemphigoid**. Bullous pemphigoid is a blistering skin condition that typically occurs in elderly patients, and the presentation of an itchy, blistering rash in a 79-year-old woman is highly suggestive of this diagnosis. The blisters in bullous pemphigoid are usually large and filled with clear fluid, appearing on normal or red skin. They do not typically affect mucosal surfaces, which aligns with the unremarkable examination of the patient's mouth.

The first incorrect option is **dermatitis herpetiformis**. Dermatitis herpetiformis also presents with an itchy, blistering rash, but it is most commonly associated with coeliac disease and tends to present at a younger age than bullous pemphigoid. Additionally, dermatitis herpetiformis often affects extensor surfaces like elbows and knees, whereas the image provided does not suggest this distribution.

The second incorrect option is a **drug reaction to lisinopril**. While drug reactions can certainly cause rashes and even blisters in some cases, they would typically be more widespread and may be accompanied by other symptoms such as fever or involvement of other organ systems. There is no information given suggesting that this patient has recently started taking lisinopril or any other new medications.

**Pemphigus vulgaris**, the third incorrect option, is another blistering skin condition which could potentially present similarly to bullous pemphigoid. However, pemphigus vulgaris typically involves mucosal surfaces initially or exclusively - often starting in the mouth - which does not fit with this patient's unremarkable oral examination.

Finally, **epidermolysis bullosa** is incorrect because it's a group of rare inherited conditions causing fragile skin that blisters easily from minor injuries or friction. This condition usually becomes apparent at birth or soon afterwards.

Discuss (1) | Improve

Next question

## Bullous pemphigoid

Bullous pemphigoid is an autoimmune condition causing sub-epidermal blistering of the skin. This is secondary to the development of antibodies against hemidesmosomal proteins BP180 and BP230.

Bullous pemphigoid is more common in elderly patients. Features include

- itchy, tense blisters typically around flexures

- the blisters usually heal without scarring
- there is stereotypically no mucosal involvement (i.e. the mouth is spared)
  - in reality around 10-50% of patients have a degree of mucosal involvement. It would, however, be unusual for an exam question to mention mucosal involvement as it is seen as a classic differentiating feature between pemphigoid and pemphigus.

Skin biopsy
- immunofluorescence shows IgG and C3 at the dermoepidermal junction

Management
- referral to a dermatologist for biopsy and confirmation of diagnosis
- oral corticosteroids are the mainstay of treatment
- topical corticosteroids, immunosuppressants and antibiotics are also used

AI + Q 123

Next question >

## Textbooks

High-yield textbook

Extended textbook

## Links

British Association of Dermatologists 8 11

Bullous pemphigoid guidelines

DermNet NZ 15 9

Bullous pemphigoid

Suggest link Report broken link

## Media

Bullous pemphigoid

Osmosis - YouTube 5 1

Report broken media

Score: **14%**

1 ✗
2 ✗
3 ✓
4 ✗
5 ✗
6 ✗
7 ✗
8 ✗
9 ✗
10 ✗
11 ✓
12 ✗
13 ✓

| | |
|---|---|
| 14 | ✗ |
| 15 | ✗ |
| 16 | ✗ |
| 17 | ✗ |
| 18 | ✗ |
| 19 | ✗ |
| 20 | ✗ |
| 21 | ✗ |
| 22 | ✗ |
| 23 | ✗ |
| 24 | ✗ |
| 25 | ✗ |
| 26 | ✓ |
| **27** | ✗ |
| 28 | ✗ |
| 29 | ✗ |
| 30 | ✗ |
| 31 | ✗ |
| 32 | ✓ |
| 33 | ✗ |
| 34 | ✗ |
| 35 | ✗ |
| 36 | ✗ |
| 37 | ✗ |
| 38 | ✗ |
| 39 | ✗ |
| 40 | ✗ |
| 41 | ✗ |
| 42 | ✗ |
| 43 | ✗ |
| 44 | ✓ |
| 45 | ✗ |
| 46 | ✗ |
| 47 | ✓ |
| 48 | ✗ |
| 49 | ✗ |

50 ✕

All contents of this site are © 2024 Passmedicine Limited

Back to top

A 30-year-old man is investigated for recurrent nose bleeds and iron deficiency anaemia. You notice a number of erythematous lesions on his skin:

© Image used on license from DermNet NZ

What is the most likely underlying diagnosis?

- Peutz-Jeghers syndrome
- Alcohol excess
- Hereditary haemorrhagic telangiectasia
- Haemophilia A
- Idiopathic thrombocytopenic purpura

Submit answer

Reference ranges

Score: **0%**

| | |
|---|---|
| 1 | - |
| 2 | - |
| 3 | - |
| 4 | - |
| 5 | - |
| 6 | - |
| 7 | - |
| 8 | - |
| 9 | - |
| 10 | - |
| 11 | - |
| 12 | - |
| 13 | - |
| 14 | - |
| 15 | - |
| 16 | - |
| 17 | - |
| 18 | - |
| 19 | - |
| 20 | - |
| 21 | - |
| 22 | - |
| 23 | - |
| 24 | - |
| 25 | - |
| 26 | - |
| 27 | - |
| **28** | - |

All contents of this site are © 2024 Passmedicine Limited

Back to top

A 30-year-old man is investigated for recurrent nose bleeds and iron deficiency anaemia. You notice a number of erythematous lesions on his skin:

© Image used on license from DermNet NZ

What is the most likely underlying diagnosis?

| | |
|---|---|
| Peutz-Jeghers syndrome | 7% |
| Alcohol excess | 1% |
| Hereditary haemorrhagic telangiectasia | 89% |
| Haemophilia A | 0% |
| Idiopathic thrombocytopenic purpura | 3% |

The correct answer is **Hereditary haemorrhagic telangiectasia**. This condition, also known as Osler-Weber-Rendu syndrome, is a genetic disorder characterised by abnormal blood vessel formation in the skin, mucous membranes, and often in organs such as the lungs, liver, and brain. The erythematous lesions seen on the skin of this patient are likely telangiectasias - small dilated blood vessels near the surface of the skin. Recurrent nosebleeds (epistaxis) and iron deficiency anaemia due to chronic bleeding are common manifestations of this condition.

**Peutz-Jeghers syndrome** is an autosomal dominant genetic disorder characterised by the

development of non-cancerous growths called hamartomatous polyps in the gastrointestinal tract and a characteristic pigmentation around the mouth, lips, eyes and genitalia. It does not typically present with recurrent nosebleeds or erythematous skin lesions.

**Alcohol excess** can cause numerous health issues including liver disease and coagulopathy which might lead to easy bruising and bleeding. However, it would not cause erythematous skin lesions as seen in this case. Furthermore, alcohol-related nosebleeds would usually be associated with other signs of alcohol misuse or its complications.

**Haemophilia A** is an X-linked recessive disorder characterised by a deficiency in factor VIII leading to prolonged bleeding times. Although patients with haemophilia may experience frequent nosebleeds due to impaired coagulation, they do not develop telangiectasias or similar skin lesions.

Lastly, **Idiopathic thrombocytopenic purpura (ITP)** is an autoimmune disorder causing platelet destruction which leads to a low platelet count (thrombocytopenia). Patients with ITP typically present with petechiae and purpura but not telangiectasia as seen in this case. Nosebleeds could occur due to thrombocytopenia but ITP wouldn't explain the specific type of skin lesion observed here.

Discuss (5) Improve

Next question

## Hereditary haemorrhagic telangiectasia

Also known as Osler-Weber-Rendu syndrome, hereditary haemorrhagic telangiectasia (HHT) is an autosomal dominant condition characterised by (as the name suggests) multiple telangiectasia over the skin and mucous membranes. Twenty percent of cases occur spontaneously without prior family history.

There are 4 main diagnostic criteria. If the patient has 2 then they are said to have a possible diagnosis of HHT. If they meet 3 or more of the criteria they are said to have a definite diagnosis of HHT:

- epistaxis : spontaneous, recurrent nosebleeds
- telangiectases: multiple at characteristic sites (lips, oral cavity, fingers, nose)
- visceral lesions: for example gastrointestinal telangiectasia (with or without bleeding), pulmonary arteriovenous malformations (AVM), hepatic AVM, cerebral AVM, spinal AVM
- family history: a first-degree relative with HHT

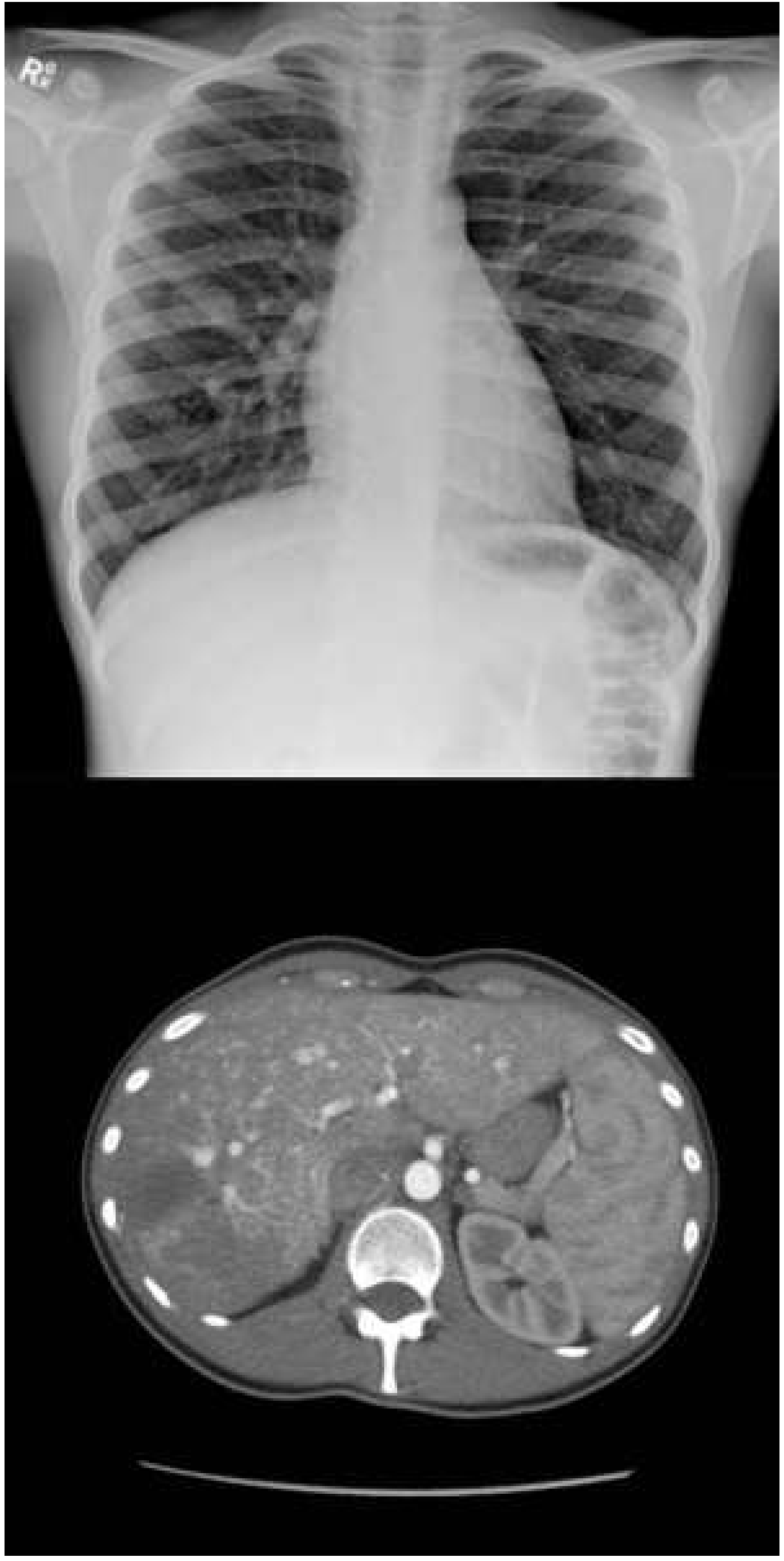

© Image used on license from Radiopaedia

The chest x-ray shows multiple pulmonary nodules representing arteriovenous malformations, the largest in the right mid-zone. The CT scan shows multiple hepatic arteriovenous malformations

AI + Q 123

Next question >

B I A

## Textbooks

High-yield textbook

Extended textbook

## Links

DermNet NZ 5 6

Hereditary haemorrhagic telangiectasia

Postgraduate Medical Journal 5 1

Review of HHT

Suggest link

Report broken link

Score: **14%**

| | |
|---|---|
| 1 | ✗ |
| 2 | ✗ |
| 3 | ✓ |
| 4 | ✗ |
| 5 | ✗ |
| 6 | ✗ |
| 7 | ✗ |
| 8 | ✗ |
| 9 | ✗ |
| 10 | ✗ |
| 11 | ✓ |
| 12 | ✗ |
| 13 | ✓ |
| 14 | ✗ |
| 15 | ✗ |
| 16 | ✗ |

| | |
|---|---|
| 17 | ✗ |
| 18 | ✗ |
| 19 | ✗ |
| 20 | ✗ |
| 21 | ✗ |
| 22 | ✗ |
| 23 | ✗ |
| 24 | ✗ |
| 25 | ✗ |
| 26 | ✓ |
| 27 | ✗ |
| **28** | ✗ |
| 29 | ✗ |
| 30 | ✗ |
| 31 | ✗ |
| 32 | ✓ |
| 33 | ✗ |
| 34 | ✗ |
| 35 | ✗ |
| 36 | ✗ |
| 37 | ✗ |
| 38 | ✗ |
| 39 | ✗ |
| 40 | ✗ |
| 41 | ✗ |
| 42 | ✗ |
| 43 | ✗ |
| 44 | ✓ |
| 45 | ✗ |
| 46 | ✗ |
| 47 | ✓ |
| 48 | ✗ |
| 49 | ✗ |
| 50 | ✗ |

All contents of this site are © 2024 Passmedicine Limited

PassMedicine



A woman who is 31 weeks pregnant presents with a rash on her abdomen and thighs:

© Image used on license from DermNet NZ

The rash is very itchy and she is having difficulty sleeping at night. What is the most likely diagnosis?

- Primary herpes simplex infection
- Pityriasis rosea
- Polymorphic eruption of pregnancy
- Pemphigoid gestationis
- Pompholyx

Submit answer

Reference ranges

Score: **0%**

| | |
|---|---|
| 1 | - |
| 2 | - |
| 3 | - |
| 4 | - |
| 5 | - |
| 6 | - |
| 7 | - |
| 8 | - |
| 9 | - |
| 10 | - |
| 11 | - |
| 12 | - |
| 13 | - |
| 14 | - |
| 15 | - |
| 16 | - |
| 17 | - |
| 18 | - |
| 19 | - |
| 20 | - |
| 21 | - |
| 22 | - |
| 23 | - |
| 24 | - |
| 25 | - |
| 26 | - |
| 27 | - |
| 28 | - |
| **29** | - |

All contents of this site are © 2024 Passmedicine Limited

A woman who is 31 weeks pregnant presents with a rash on her abdomen and thighs:

© Image used on license from DermNet NZ

The rash is very itchy and she is having difficulty sleeping at night. What is the most likely diagnosis?

| | |
|---|---|
| Primary herpes simplex infection | 0% |
| Pityriasis rosea | 1% |
| Polymorphic eruption of pregnancy | 89% |
| Pemphigoid gestationis | 9% |
| Pompholyx | 1% |

The correct answer is **Polymorphic eruption of pregnancy**. Polymorphic eruption of pregnancy (PEP), also known as pruritic urticarial papules and plaques of pregnancy (PUPPP), is a benign dermatological condition that occurs in late pregnancy. It typically presents with intensely itchy, polymorphic lesions including erythematous papules, vesicles or plaques. The rash often starts on the abdomen, particularly within stretch marks (striae), and can spread to the thighs and buttocks but rarely involves the face or mucous membranes. This presentation matches the patient's symptoms and her stage of pregnancy.

**Primary herpes simplex infection** would typically present with painful grouped vesicles on an erythematous base, which may then ulcerate. Primary infections can be associated with systemic symptoms such as fever and malaise. Herpes simplex is not confined to late stages of pregnancy and does not specifically target areas with striae.

**Pityriasis rosea** usually starts with a single 'herald patch', followed by a 'Christmas-tree' distribution of smaller patches along skin cleavage lines, predominantly on the trunk. It is not related to pregnancy nor does it preferentially affect areas with striae.

**Pemphigoid gestationis**, previously known as herpes gestationis, is a rare autoimmune blistering disorder associated with pregnancy. It usually begins in the second or third trimester or immediately postpartum. Lesions often start around the umbilicus before spreading to other parts of the body but unlike PEP, pemphigoid gestationis frequently involves the palms, soles and mucous membranes.

Lastly, **pompholyx**, also known as dyshidrotic eczema, primarily affects hands and feet causing itchy vesicles; therefore it wouldn't explain this patient's rash location.

Discuss (2) Improve

Next question

## Skin disorders associated with pregnancy

Atopic eruption of pregnancy

- is the commonest skin disorder found in pregnancy
- it typically presents as an eczematous, itchy red rash.
- no specific treatment is needed

Polymorphic eruption of pregnancy

- pruritic condition associated with last trimester
- lesions often first appear in abdominal striae
- management depends on severity: emollients, mild potency topical steroids and oral steroids may be used

© Image used on license from DermNet NZ

Polymorphic eruption of pregnancy

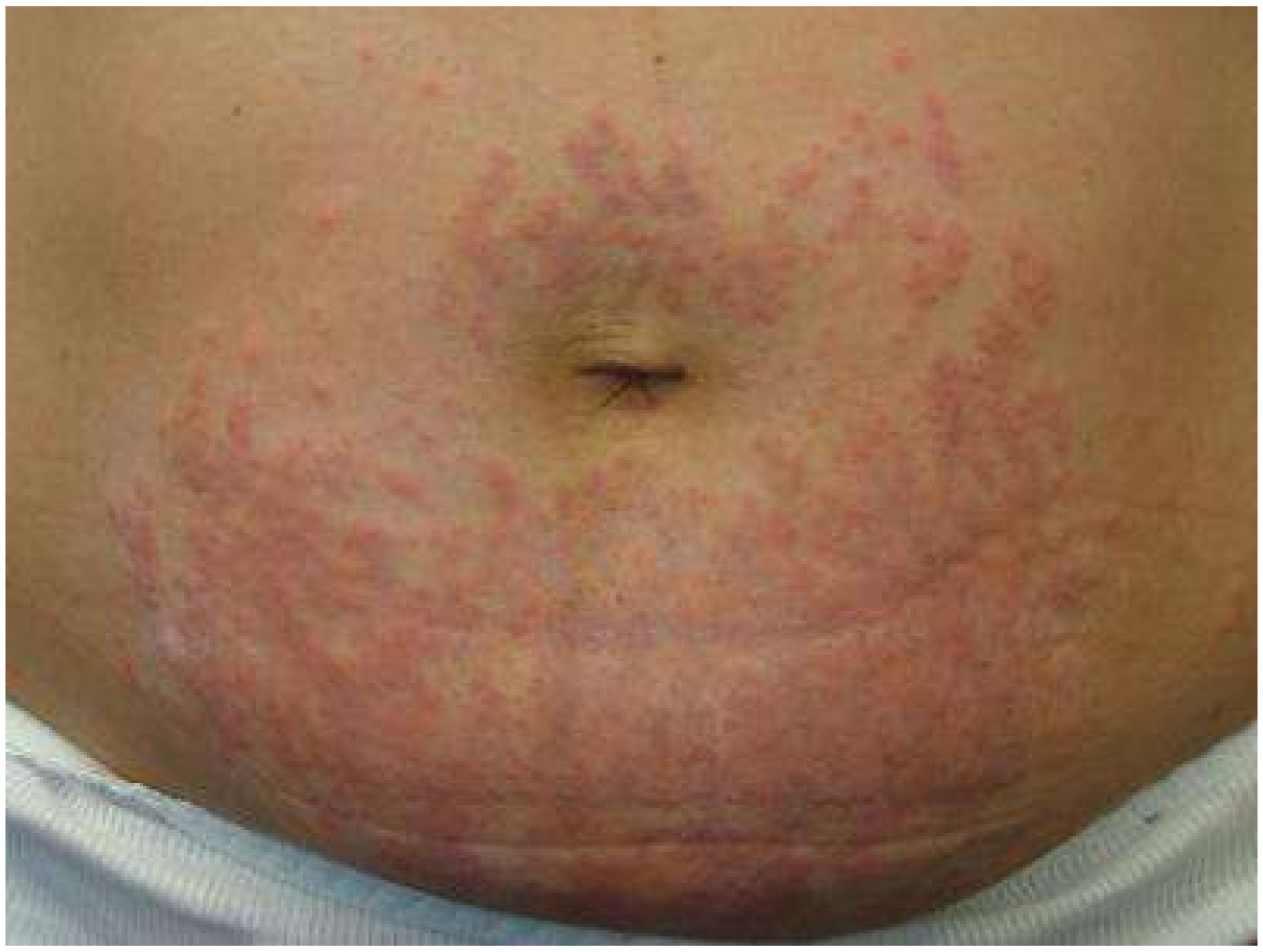

© Image used on license from DermNet NZ

Polymorphic eruption of pregnancy

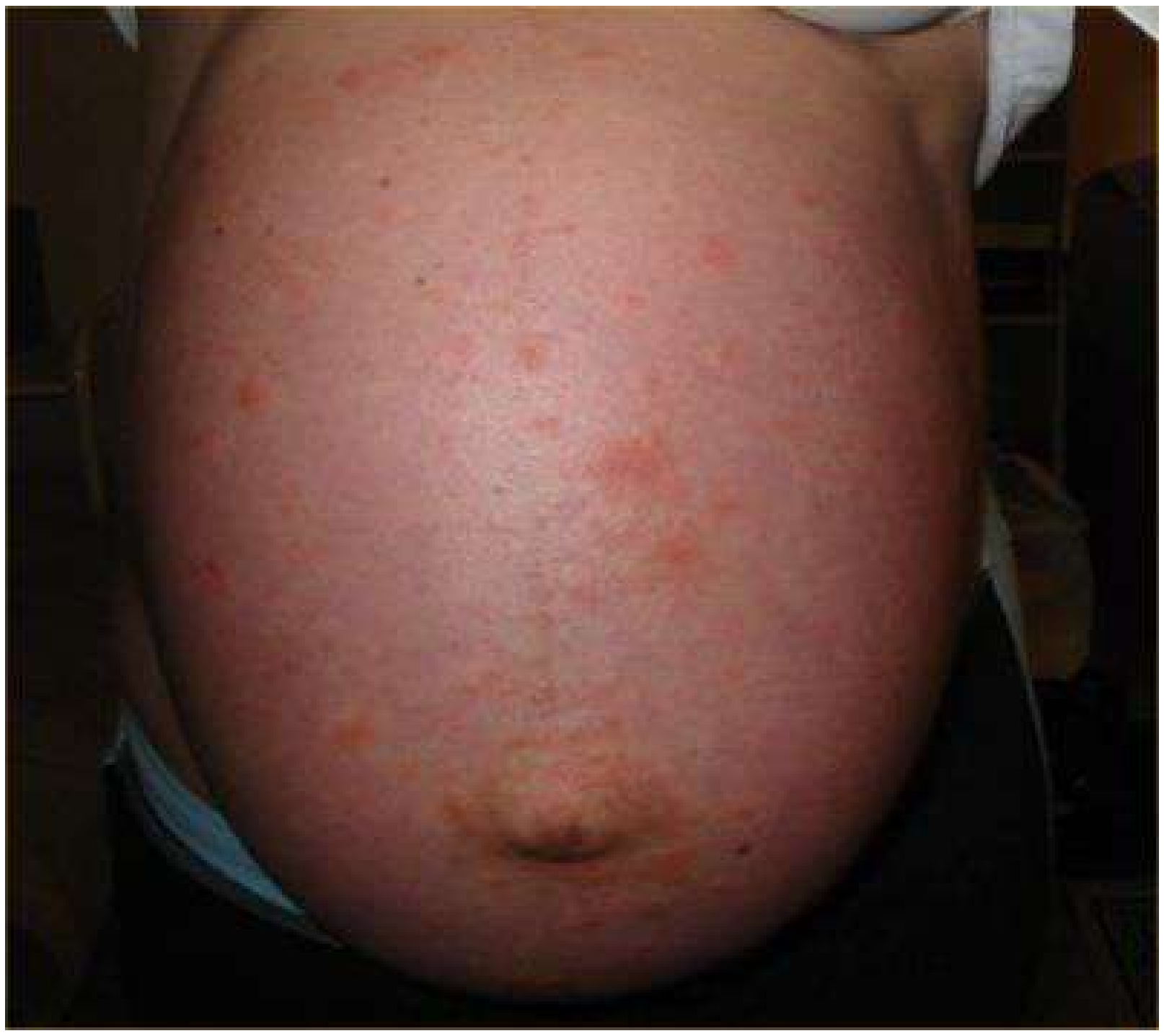

Polymorphic eruption of pregnancy

Pemphigoid gestationis

- pruritic blistering lesions
- often develop in peri-umbilical region, later spreading to the trunk, back, buttocks and arms
- usually presents 2nd or 3rd trimester and is rarely seen in the first pregnancy
- oral corticosteroids are usually required

© Image used on license from DermNet NZ

Pemphigoid gestationis

© Image used on license from DermNet NZ

Pemphigoid gestationis

123

Next question

## Textbooks

High-yield textbook

Extended textbook

## Links

DermNet NZ 13 5

Pemphigoid gestationis

DermNet NZ 11 4

Polymorphic eruption of pregnancy

Suggest link | Report broken link

Score: **14%**

| | |
|---|---|
| 1 | ✗ |
| 2 | ✗ |
| 3 | ✓ |
| 4 | ✗ |
| 5 | ✗ |
| 6 | ✗ |
| 7 | ✗ |
| 8 | ✗ |
| 9 | ✗ |
| 10 | ✗ |
| 11 | ✓ |
| 12 | ✗ |
| 13 | ✓ |
| 14 | ✗ |
| 15 | ✗ |
| 16 | ✗ |
| 17 | ✗ |
| 18 | ✗ |
| 19 | ✗ |
| 20 | ✗ |
| 21 | ✗ |
| 22 | ✗ |
| 23 | ✗ |
| 24 | ✗ |
| 25 | ✗ |
| 26 | ✓ |
| 27 | ✗ |
| 28 | ✗ |

| | |
|---|---|
| **29** | ✗ |
| 30 | ✗ |
| 31 | ✗ |
| 32 | ✓ |
| 33 | ✗ |
| 34 | ✗ |
| 35 | ✗ |
| 36 | ✗ |
| 37 | ✗ |
| 38 | ✗ |
| 39 | ✗ |
| 40 | ✗ |
| 41 | ✗ |
| 42 | ✗ |
| 43 | ✗ |
| 44 | ✓ |
| 45 | ✗ |
| 46 | ✗ |
| 47 | ✓ |
| 48 | ✗ |
| 49 | ✗ |
| 50 | ✗ |

All contents of this site are © 2024 Passmedicine Limited

A 52-year-old male was referred to the outpatients dermatology clinic with a four-month history of a persistent rash. He described the rash as a very itchy blistering rash occurring on the popliteal fossa as well as his buttocks. He had been prescribed levocetirizine 5mg OD as well as a four-week course of Eumovate BD (moderately-potent corticosteroid) and Diprobase (emollient) QDS but despite the treatment his symptoms had worsened. He had a past medical history comprising refractory eczema, gout, angina, hypertension and diabetes mellitus type 2 for which he was prescribed allopurinol 100mg OD, aspirin 75mg OD, simvastatin 40mg OD, ramipril 5mg OD and metformin M/R 1g BD. Regarding his eczema, this is presently in a state of remission, having been treated with azathioprine six months ago. Other than the rash he was otherwise well though he mentioned he had a history of abdominal bloating and diarrhoea which was diagnosed as irritable bowel syndrome several years ago.

On examination, he was systemically well with a blood pressure of 142/76 mmHg. Examination of the cardiovascular, respiratory and gastrointestinal systems was unremarkable. Examination of his skin revealed the presence of multiple bullae and papules on the extensor surface of his knees and buttocks, with excoriation.

Which of the following is the most likely diagnosis?

- Bullous pemphigoid disease
- Linear IgA bullous dermatosis
- Dermatitis herpetiformis
- Transient acantholytic dermatosis
- Eczema

Submit answer

Reference ranges

Score: **0%**

| | |
|---|---|
| 1 | - |
| 2 | - |
| 3 | - |
| 4 | - |
| 5 | - |
| 6 | - |
| 7 | - |
| 8 | - |
| 9 | - |
| 10 | - |
| 11 | - |
| 12 | - |
| 13 | - |
| 14 | - |
| 15 | - |
| 16 | - |
| 17 | - |
| 18 | - |
| 19 | - |
| 20 | - |
| 21 | - |
| 22 | - |
| 23 | - |
| 24 | - |
| 25 | - |
| 26 | - |
| 27 | - |
| 28 | - |
| 29 | - |
| **30** | - |

All contents of this site are © 2024 Passmedicine Limited

A 52-year-old male was referred to the outpatients dermatology clinic with a four-month history of a persistent rash. He described the rash as a very itchy blistering rash occurring on the popliteal fossa as well as his buttocks. He had been prescribed levocetirizine 5mg OD as well as a four-week course of Eumovate BD (moderately-potent corticosteroid) and Diprobase (emollient) QDS but despite the treatment his symptoms had worsened. He had a past medical history comprising refractory eczema, gout, angina, hypertension and diabetes mellitus type 2 for which he was prescribed allopurinol 100mg OD, aspirin 75mg OD, simvastatin 40mg OD, ramipril 5mg OD and metformin M/R 1g BD. Regarding his eczema, this is presently in a state of remission, having been treated with azathioprine six months ago. Other than the rash he was otherwise well though he mentioned he had a history of abdominal bloating and diarrhoea which was diagnosed as irritable bowel syndrome several years ago.

On examination, he was systemically well with a blood pressure of 142/76 mmHg. Examination of the cardiovascular, respiratory and gastrointestinal systems was unremarkable. Examination of his skin revealed the presence of multiple bullae and papules on the extensor surface of his knees and buttocks, with excoriation.

Which of the following is the most likely diagnosis?

- Bullous pemphigoid disease 18%
- Linear IgA bullous dermatosis 12%
- Dermatitis herpetiformis 68%
- Transient acantholytic dermatosis 2%
- Eczema 1%

This rash tends to present as an intensely itchy bullous rash comprising of blisters and papules on extensor surfaces, though can also occur on any other part of the body. This disease is strongly associated with uncontrolled coeliac disease, and the clue in this question is the presence of abdominal bloating and diarrhoea (red herring being diagnosed with irritable bowel syndrome, a common mistake to make in clinical practice!).

Discuss (6) | Improve

Next question >

# Dermatitis herpetiformis

Dermatitis herpetiformis is an autoimmune blistering skin disorder associated with coeliac disease. It is caused by deposition of IgA in the dermis. More than 90% of patients exhibit small bowel biopsy findings consistent with some degree of gluten-sensitive enteropathy.

Features
- itchy, vesicular skin lesions on the extensor surfaces (e.g. elbows, knees, buttocks)

Diagnosis
- skin biopsy: direct immunofluorescence shows deposition of IgA in a granular pattern in the upper dermis

Management
- gluten-free diet
- dapsone

AI + Q 123

Next question >

### Textbooks

High-yield textbook

Extended textbook

### Links

DermNet NZ

Dermatitis herpetiformis

34 6

Suggest link

Report broken link

Score: **14%**

| | |
|---|---|
| 1 | ✗ |
| 2 | ✗ |
| 3 | ✓ |
| 4 | ✗ |
| 5 | ✗ |
| 6 | ✗ |
| 7 | ✗ |
| 8 | ✗ |
| 9 | ✗ |
| 10 | ✗ |
| 11 | ✓ |
| 12 | ✗ |
| 13 | ✓ |
| 14 | ✗ |
| 15 | ✗ |
| 16 | ✗ |
| 17 | ✗ |
| 18 | ✗ |
| 19 | ✗ |

| | |
|---|---|
| 20 | ✗ |
| 21 | ✗ |
| 22 | ✗ |
| 23 | ✗ |
| 24 | ✗ |
| 25 | ✗ |
| 26 | ✓ |
| 27 | ✗ |
| 28 | ✗ |
| 29 | ✗ |
| **30** | ✗ |
| 31 | ✗ |
| 32 | ✓ |
| 33 | ✗ |
| 34 | ✗ |
| 35 | ✗ |
| 36 | ✗ |
| 37 | ✗ |
| 38 | ✗ |
| 39 | ✗ |
| 40 | ✗ |
| 41 | ✗ |
| 42 | ✗ |
| 43 | ✗ |
| 44 | ✓ |
| 45 | ✗ |
| 46 | ✗ |
| 47 | ✓ |
| 48 | ✗ |
| 49 | ✗ |
| 50 | ✗ |

All contents of this site are © 2024 Passmedicine Limited

You review a 27-year-old man who is under the care of the dermatology department.

© Image used on license from DermNet NZ

Which one of the following conditions is most associated with this skin disorder?

- Addison's disease
- Asthma
- Iron-deficiency anaemia
- Toxic multinodular goitre
- Type 2 diabetes mellitus

Submit answer

Reference ranges

Score: **0%**

| | |
|---|---|
| 1 | - |
| 2 | - |
| 3 | - |
| 4 | - |
| 5 | - |
| 6 | - |
| 7 | - |
| 8 | - |
| 9 | - |
| 10 | - |
| 11 | - |
| 12 | - |
| 13 | - |
| 14 | - |
| 15 | - |
| 16 | - |
| 17 | - |
| 18 | - |
| 19 | - |
| 20 | - |
| 21 | - |
| 22 | - |
| 23 | - |
| 24 | - |
| 25 | - |
| 26 | - |
| 27 | - |
| 28 | - |
| 29 | - |
| 30 | - |
| **31** | - |

All contents of this site are © 2024 Passmedicine Limited

Back to top

You review a 27-year-old man who is under the care of the dermatology department.

© Image used on license from DermNet NZ

Which one of the following conditions is most associated with this skin disorder?

| | |
|---|---|
| Addison's disease | 84% |
| Asthma | 2% |
| Iron-deficiency anaemia | 3% |
| Toxic multinodular goitre | 6% |
| Type 2 diabetes mellitus | 5% |

Vitiligo is associated with other autoimmune conditions such as Addison's disease, type 1 diabetes mellitus and autoimmune thyroid disorders.

# Vitiligo

Vitiligo is an autoimmune condition which results in the loss of melanocytes and consequent depigmentation of the skin. It is thought to affect around 1% of the population and symptoms typically develop by the age of 20-30 years.

Associated conditions

- type 1 diabetes mellitus
- Addison's disease
- autoimmune thyroid disorders
- pernicious anaemia
- alopecia areata

Features

- well-demarcated patches of depigmented skin
- the peripheries tend to be most affected
- trauma may precipitate new lesions (Koebner phenomenon)

Management

- sunblock for affected areas of skin
- camouflage make-up
- topical corticosteroids may reverse the changes if applied early
- there may also be a role for topical tacrolimus and phototherapy, although caution needs to be exercised with light-skinned patients

123

Next question

## Textbooks

High-yield textbook

Extended textbook

## Links

DermNet NZ 8 3

Vitiligo

Suggest link

Report broken link

## Media

Vitiligo

Osmosis - YouTube 0 1

Report broken media

Score: **14%**

1 ✗
2 ✗
3 ✓
4 ✗
5 ✗
6 ✗
7 ✗

| | |
|---|---|
| 8 | ✗ |
| 9 | ✗ |
| 10 | ✗ |
| 11 | ✓ |
| 12 | ✗ |
| 13 | ✓ |
| 14 | ✗ |
| 15 | ✗ |
| 16 | ✗ |
| 17 | ✗ |
| 18 | ✗ |
| 19 | ✗ |
| 20 | ✗ |
| 21 | ✗ |
| 22 | ✗ |
| 23 | ✗ |
| 24 | ✗ |
| 25 | ✗ |
| 26 | ✓ |
| 27 | ✗ |
| 28 | ✗ |
| 29 | ✗ |
| 30 | ✗ |
| **31** | ✗ |
| 32 | ✓ |
| 33 | ✗ |
| 34 | ✗ |
| 35 | ✗ |
| 36 | ✗ |
| 37 | ✗ |
| 38 | ✗ |
| 39 | ✗ |
| 40 | ✗ |
| 41 | ✗ |
| 42 | ✗ |
| 43 | ✗ |

| | |
|---|---|
| 44 | ✓ |
| 45 | ✗ |
| 46 | ✗ |
| 47 | ✓ |
| 48 | ✗ |
| 49 | ✗ |
| 50 | ✗ |

All contents of this site are © 2024 Passmedicine Limited

Back to top

A 47-year-old lady presented with shortness of breath and a nosebleed. She had been experiencing heavy nosebleeds over the past fifteen years and had twice required cauterization. On this admission she felt very tired, with shortness of breath and chest pain on minimal exertion.

Aside from nosebleeds she had a past medical history of hypertension and hypothyroidism. She had recently consulted a cosmetic surgeon privately as she had spider veins over her lips which she wished to have removed.

She lived with her husband who had been diagnosed with multiple sclerosis and her 18-year-old son who had learning difficulties and epilepsy. She reported that her mother and sister also experienced frequent nosebleeds.

On examination there was conjunctival pallor. The lung fields were clear on auscultation and both heart sounds were present with a systolic murmur audible over the aortic region. The abdomen was soft and non-tender with no palpable masses or organomegaly. On inspection of the skin there was a bruise in the left antecubital fossa and no rashes.

What is the most likely unifying diagnosis?

- Von Willebrand disease
- Wegeners granulomatosis
- Von Hippel Lindau disease
- Idiopathic Thrombocytopaenic Purpura
- Hereditary haemorrhagic telangiectasia

Submit answer

Reference ranges

Score: **0%**

| | |
|---|---|
| 1 | - |
| 2 | - |
| 3 | - |
| 4 | - |
| 5 | - |
| 6 | - |
| 7 | - |
| 8 | - |
| 9 | - |
| 10 | - |
| 11 | - |
| 12 | - |
| 13 | - |
| 14 | - |
| 15 | - |
| 16 | - |
| 17 | - |
| 18 | - |
| 19 | - |
| 20 | - |
| 21 | - |
| 22 | - |
| 23 | - |
| 24 | - |
| 25 | - |
| 26 | - |
| 27 | - |
| 28 | - |
| 29 | - |
| 30 | - |
| 31 | - |
| **32** | - |

All contents of this site are © 2024 Passmedicine Limited

A 47-year-old lady presented with shortness of breath and a nosebleed. She had been experiencing heavy nosebleeds over the past fifteen years and had twice required cauterization. On this admission she felt very tired, with shortness of breath and chest pain on minimal exertion.

Aside from nosebleeds she had a past medical history of hypertension and hypothyroidism. She had recently consulted a cosmetic surgeon privately as she had spider veins over her lips which she wished to have removed.

She lived with her husband who had been diagnosed with multiple sclerosis and her 18-year-old son who had learning difficulties and epilepsy. She reported that her mother and sister also experienced frequent nosebleeds.

On examination there was conjunctival pallor. The lung fields were clear on auscultation and both heart sounds were present with a systolic murmur audible over the aortic region. The abdomen was soft and non-tender with no palpable masses or organomegaly. On inspection of the skin there was a bruise in the left antecubital fossa and no rashes.

What is the most likely unifying diagnosis?

| | |
|---|---|
| Von Willebrand disease | 2% |
| Wegeners granulomatosis | 1% |
| Von Hippel Lindau disease | 5% |
| Idiopathic Thrombocytopaenic Purpura | 1% |
| Hereditary haemorrhagic telangiectasia | 90% |

Hereditary haemorrhagic telangiectasia (HHT), also known as Osler Weber Rendu syndrome, is an autosomal dominant disorder leading to abnormal blood vessel formation in the skin, mucous membranes, liver, lungs and brain. In this case, both the patients mother, sister and son are also affected indicating a likely autosomal dominant inheritance. Telangiectasia, such as the ones on this patients lips, are found on mucosal surfaces and in the gastrointestinal tract. These can cause nosebleeds and this is the most common presentation of HHT. Nosebleeds and bleeding from telangiectasia in the gastrointestinal tract can lead to an iron deficiency anaemia which explains the shortness of breath, pallor, chest pain and flow murmur in this case. Other manifestations of

HHT occur secondary to the formation of arteriovenous malformations (AVMs) and include haemoptysis, portal hypertension and oesophageal varices, congestive cardiac failure, headache, intracerebral haemorrhage and seizures. Treatment is largely symptomatic and anaemia is treated with transfusions and iron replacement.

Von Willebrand disease can present with nosebleeds and may be inherited in an autosomal dominant fashion. However, this diagnosis would not account for the severe symptomatic anaemia, telangiectasia or the neurological features in this patients son. Other features of von Willebrands disease include bleeding gums and purpura.

Wegeners granulomatosis is a form of vasculitis that can cause nosebleeds. It is not a genetic condition and other clinical manifestations include haemoptysis, rapidly progressive glomerulonephritis, arthritis and a purpuric rash.

Von Hippel Lindau disease is a rare autosomal dominant condition which is associated with many tumour types including haemangioblastomas, neuroendocrine tumours and renal cell carcinoma. It can present with walking difficulties, headaches and hypertension in addition to other symptoms and signs however nosebleeds are not a commonly recognised feature of this disease.

Idiopathic Thrombocytopaenic Purpura (ITP) is an autoimmune condition which can present with easy bruising, purpura and nosebleeds. In patients with ITP there is usually no family history and the condition does not cause telangiectasia.

Discuss (3) Improve

Next question

## Hereditary haemorrhagic telangiectasia

Also known as Osler-Weber-Rendu syndrome, hereditary haemorrhagic telangiectasia (HHT) is an autosomal dominant condition characterised by (as the name suggests) multiple telangiectasia over the skin and mucous membranes. Twenty percent of cases occur spontaneously without prior family history.

There are 4 main diagnostic criteria. If the patient has 2 then they are said to have a possible diagnosis of HHT. If they meet 3 or more of the criteria they are said to have a definite diagnosis of HHT:

- epistaxis : spontaneous, recurrent nosebleeds
- telangiectases: multiple at characteristic sites (lips, oral cavity, fingers, nose)

- visceral lesions: for example gastrointestinal telangiectasia (with or without bleeding), pulmonary arteriovenous malformations (AVM), hepatic AVM, cerebral AVM, spinal AVM
- family history: a first-degree relative with HHT

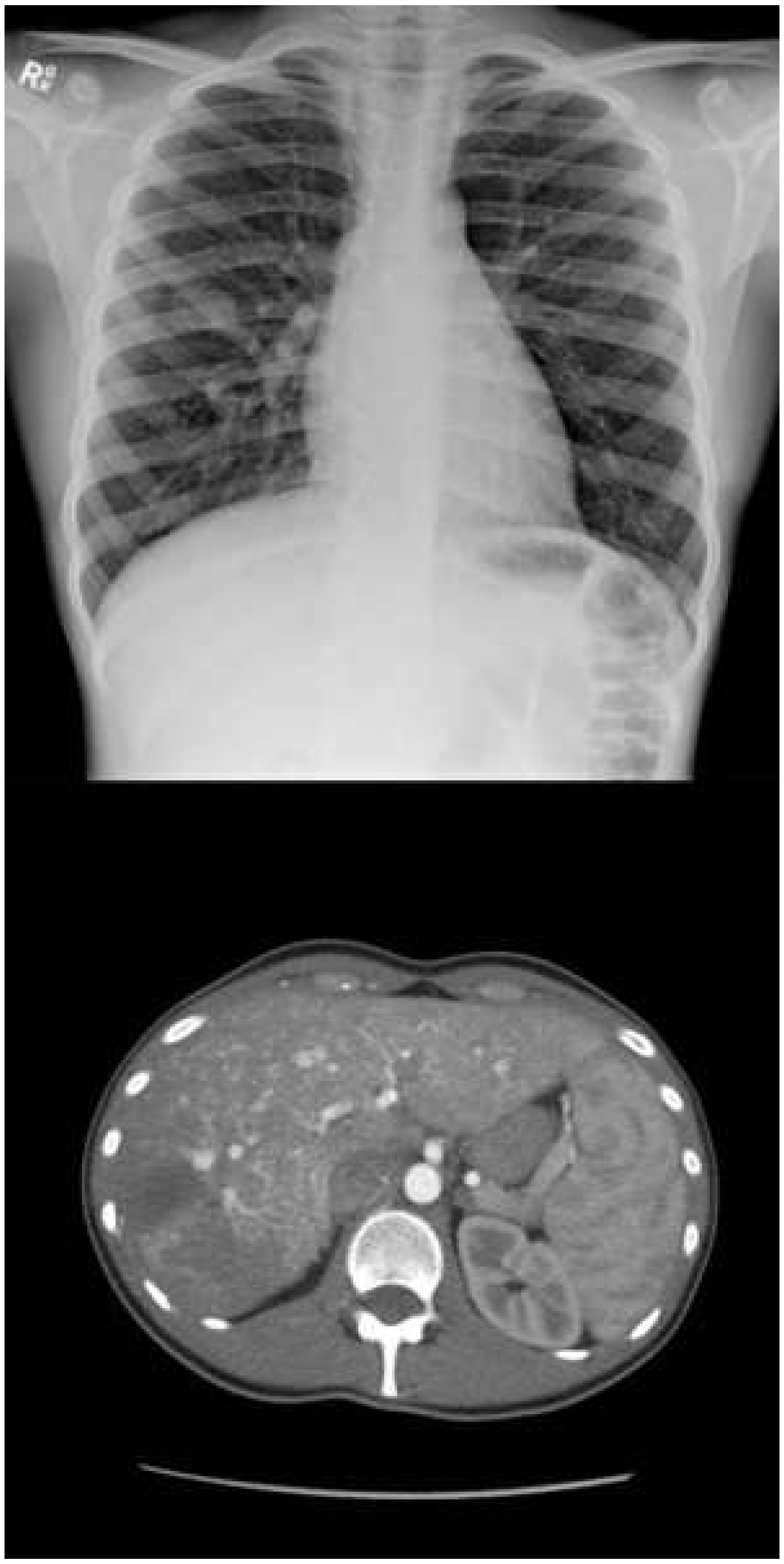

© Image used on license from Radiopaedia

The chest x-ray shows multiple pulmonary nodules representing arteriovenous malformations, the largest in the right mid-zone. The CT scan shows multiple hepatic arteriovenous malformations

+ Q 123

Next question >

## Textbooks

High-yield textbook

Extended textbook

## Links

DermNet NZ — 👍 5 👎 6

Hereditary haemorrhagic telangiectasia

Postgraduate Medical Journal — 👍 5 👎 1

Review of HHT

Suggest link | Report broken link

Score: **14%**

| | |
|---|---|
| 1 | ✗ |
| 2 | ✗ |
| 3 | ✓ |
| 4 | ✗ |
| 5 | ✗ |
| 6 | ✗ |
| 7 | ✗ |
| 8 | ✗ |
| 9 | ✗ |
| 10 | ✗ |
| 11 | ✓ |
| 12 | ✗ |
| 13 | ✓ |

| | |
|---|---|
| 14 | ✗ |
| 15 | ✗ |
| 16 | ✗ |
| 17 | ✗ |
| 18 | ✗ |
| 19 | ✗ |
| 20 | ✗ |
| 21 | ✗ |
| 22 | ✗ |
| 23 | ✗ |
| 24 | ✗ |
| 25 | ✗ |
| 26 | ✓ |
| 27 | ✗ |
| 28 | ✗ |
| 29 | ✗ |
| 30 | ✗ |
| 31 | ✗ |
| **32** | ✓ |
| 33 | ✗ |
| 34 | ✗ |
| 35 | ✗ |
| 36 | ✗ |
| 37 | ✗ |
| 38 | ✗ |
| 39 | ✗ |
| 40 | ✗ |
| 41 | ✗ |
| 42 | ✗ |
| 43 | ✗ |
| 44 | ✓ |
| 45 | ✗ |
| 46 | ✗ |
| 47 | ✓ |
| 48 | ✗ |
| 49 | ✗ |

50 ✕

All contents of this site are © 2024 Passmedicine Limited

Back to top

A 33-year-old woman with a history of psoriasis presents with a 'rash' in both axillae.

© Image used on license from DermNet NZ

What is the most appropriate first-line treatment?

- Miconazole twice a day
- Dithranol once a day
- Calcipotriol twice a day
- Eumovate (clobetasone butyrate) once a day
- Calcipotriol + beclomethasone once a day

Submit answer

Reference ranges

Score: **0%**

| | |
|---|---|
| 1 | - |
| 2 | - |
| 3 | - |
| 4 | - |
| 5 | - |
| 6 | - |
| 7 | - |
| 8 | - |
| 9 | - |
| 10 | - |
| 11 | - |
| 12 | - |
| 13 | - |
| 14 | - |
| 15 | - |
| 16 | - |
| 17 | - |
| 18 | - |
| 19 | - |
| 20 | - |
| 21 | - |
| 22 | - |
| 23 | - |
| 24 | - |
| 25 | - |
| 26 | - |
| 27 | - |
| 28 | - |
| 29 | - |
| 30 | - |
| 31 | - |
| 32 | - |
| **33** | - |

All contents of this site are © 2024 Passmedicine Limited
Back to top

A 33-year-old woman with a history of psoriasis presents with a 'rash' in both axillae.

© Image used on license from DermNet NZ

What is the most appropriate first-line treatment?

- Miconazole twice a day 11%
- Dithranol once a day 3%
- Calcipotriol twice a day 13%
- Eumovate (clobetasone butyrate) once a day 31%
- Calcipotriol + beclomethasone once a day 41%

This patient has flexural psoriasis - a mild or moderately potent steroid should be used.

Discuss (1) Improve

Next question

# Psoriasis: management

NICE released guidelines in 2012 on the management of psoriasis and psoriatic arthropathy. Please see the link for more details.

## Chronic plaque psoriasis management

NICE recommend a step-wise approach for chronic plaque psoriasis

- regular emollients may help to reduce scale loss and reduce pruritus
- first-line: NICE recommend:
  - a potent corticosteroid applied once daily plus vitamin D analogue applied once daily
  - should be applied separately, one in the morning and the other in the evening)
  - for up to 4 weeks as initial treatment
- second-line: if no improvement after 8 weeks then offer:
  - a vitamin D analogue twice daily
- third-line: if no improvement after 8-12 weeks then offer either:
  - a potent corticosteroid applied twice daily for up to 4 weeks, or
  - a coal tar preparation applied once or twice daily
- short-acting dithranol can also be used

**Secondary care management**

Phototherapy

- narrowband ultraviolet B light is now the treatment of choice. If possible this should be given 3 times a week
- photochemotherapy is also used - psoralen + ultraviolet A light (PUVA)
- adverse effects: skin ageing, squamous cell cancer (not melanoma)

Systemic therapy

- oral methotrexate is used first-line. It is particularly useful if there is associated joint disease
- ciclosporin
- systemic retinoids

- biological agents: infliximab, etanercept and adalimumab
- ustekinumab (IL-12 and IL-23 blocker) is showing promise in early trials

## Scalp psoriasis management

Outline

- NICE recommend the use of potent topical corticosteroids used once daily for 4 weeks
- if no improvement after 4 weeks then either use a different formulation of the potent corticosteroid (for example, a shampoo or mousse) and/or a topical agents to remove adherent scale (for example, agents containing salicylic acid, emollients and oils) before application of the potent corticosteroid

## Face, flexural and genital psoriasis management

Outline

- NICE recommend offering a mild or moderate potency corticosteroid applied once or twice daily for a maximum of 2 weeks

## Notes on medication

Using topical steroids in psoriasis

- as we know topical corticosteroid therapy may lead to skin atrophy, striae and rebound symptoms
  - the scalp, face and flexures are particularly prone to steroid atrophy so topical steroids should not be used for more than 1-2 weeks/month
- systemic side-effects may be seen when potent corticosteroids are used on large areas e.g. > 10% of the body surface area
- NICE recommend that we aim for a 4-week break before starting another course of topical corticosteroids
- they also recommend using potent corticosteroids for no longer than 8 weeks at a time and very potent corticosteroids for no longer than 4 weeks at a time

Vitamin D analogues

- examples of vitamin D analogues include calcipotriol (Dovonex), calcitriol and tacalcitol
- they work by ↓ cell division and differentiation → ↓ epidermal proliferation
- adverse effects are uncommon
- unlike corticosteroids they may be used long-term
- unlike coal tar and dithranol they do not smell or stain
- they tend to reduce the scale and thickness of plaques but not the erythema

- they should be avoided in pregnancy
- the maximum weekly amount for adults is 100g

© Image used on license from DermNet NZ

A 'before and after' image showing the effect of 6 weeks of calcipotriol therapy on a large plaque. Note how the scale has improved but the erythema remains

Dithranol

- inhibits DNA synthesis
- wash off after 30 mins
- adverse effects include burning, staining

Coal tar

- mechanism of action not fully understood - probably inhibit DNA synthesis

123

Next question

## Textbooks

High-yield textbook

Extended textbook

## Links

SIGN 14 13

2010 Psoriasis guidelines

British Association of Dermatologists 14 11

2017 Guidelines for biologic therapy for psoriasis

NICE 21 16

2012 Psoriasis guidelines

Suggest link

Report broken link

## Media

Psoriasis

Osmosis - YouTube 1 1

Report broken media

Score: **14%**

| | |
|---|---|
| 1 | ✗ |
| 2 | ✗ |
| 3 | ✓ |
| 4 | ✗ |
| 5 | ✗ |
| 6 | ✗ |
| 7 | ✗ |
| 8 | ✗ |
| 9 | ✗ |
| 10 | ✗ |
| 11 | ✓ |
| 12 | ✗ |
| 13 | ✓ |
| 14 | ✗ |
| 15 | ✗ |
| 16 | ✗ |
| 17 | ✗ |
| 18 | ✗ |
| 19 | ✗ |
| 20 | ✗ |
| 21 | ✗ |
| 22 | ✗ |
| 23 | ✗ |
| 24 | ✗ |
| 25 | ✗ |
| 26 | ✓ |
| 27 | ✗ |
| 28 | ✗ |
| 29 | ✗ |
| 30 | ✗ |
| 31 | ✗ |
| 32 | ✓ |
| **33** | ✗ |
| 34 | ✗ |

| | |
|---|---|
| 35 | ✗ |
| 36 | ✗ |
| 37 | ✗ |
| 38 | ✗ |
| 39 | ✗ |
| 40 | ✗ |
| 41 | ✗ |
| 42 | ✗ |
| 43 | ✗ |
| 44 | ✓ |
| 45 | ✗ |
| 46 | ✗ |
| 47 | ✓ |
| 48 | ✗ |
| 49 | ✗ |
| 50 | ✗ |

All contents of this site are © 2024 Passmedicine Limited

You review an 82-year-old woman who has developed 'sores' on her legs. For the past two years she has had dry, itchy skin around her ankles but over the past few weeks the skin has started to break down.

© Image used on license from DermNet NZ

What is the most likely diagnosis?

- Necrobiosis lipoidica diabeticorum
- Pyoderma gangrenosum
- Arterial ulcers
- Venous ulcers
- Pretibial myxoedema

Submit answer

Reference ranges

Score: **0%**

| | |
|---|---|
| 1 | - |
| 2 | - |
| 3 | - |
| 4 | - |
| 5 | - |
| 6 | - |
| 7 | - |
| 8 | - |
| 9 | - |
| 10 | - |
| 11 | - |
| 12 | - |
| 13 | - |
| 14 | - |
| 15 | - |
| 16 | - |
| 17 | - |
| 18 | - |
| 19 | - |
| 20 | - |
| 21 | - |
| 22 | - |
| 23 | - |
| 24 | - |
| 25 | - |
| 26 | - |
| 27 | - |
| 28 | - |
| 29 | - |

| | |
|---|---|
| 30 | - |
| 31 | - |
| 32 | - |
| 33 | - |
| **34** | - |

All contents of this site are © 2024 Passmedicine Limited

You review an 82-year-old woman who has developed 'sores' on her legs. For the past two years she has had dry, itchy skin around her ankles but over the past few weeks the skin has started to break down.

© Image used on license from DermNet NZ

What is the most likely diagnosis?

- Necrobiosis lipoidica diabeticorum 28%
- Pyoderma gangrenosum 21%
- Arterial ulcers 9%
- Venous ulcers 39%
- Pretibial myxoedema 2%

The dry, skin represents varicose eczema. Arterial ulcers tend to have a more 'punched-out' appearance.

Discuss (5) | Improve

Next question

## Venous ulceration

Venous ulceration is typically seen above the medial malleolus

Investigations

- ankle-brachial pressure index (ABPI) is important in non-healing ulcers to assess for poor arterial flow which could impair healing
- a 'normal' ABPI may be regarded as between 0.9 - 1.2. Values below 0.9 indicate arterial disease. Interestingly, values above 1.3 may also indicate arterial disease, in the form of false-negative results secondary to arterial calcification (e.g. In diabetics)

Management

- compression bandaging, usually four layer (only treatment shown to be of real benefit)
- oral pentoxifylline, a peripheral vasodilator, improves healing rate
- small evidence base supporting use of flavinoids
- little evidence to suggest benefit from hydrocolloid dressings, topical growth factors, ultrasound therapy and intermittent pneumatic compression

AI + Q 123

Next question

**Textbooks**

High-yield textbook

Extended textbook

## Media

Understanding Chronic Venous Insufficiency

Zero To Finals - YouTube 👍 3 👎 0

Varicose veins & chronic venous insufficiency (CVI)

Osmosis - YouTube 👍 1 👎 2

Report broken media

Score: **14%**

1 ✗
2 ✗
3 ✓
4 ✗
5 ✗
6 ✗
7 ✗
8 ✗
9 ✗
10 ✗

| | |
|---|---|
| 11 | ✓ |
| 12 | ✗ |
| 13 | ✓ |
| 14 | ✗ |
| 15 | ✗ |
| 16 | ✗ |
| 17 | ✗ |
| 18 | ✗ |
| 19 | ✗ |
| 20 | ✗ |
| 21 | ✗ |
| 22 | ✗ |
| 23 | ✗ |
| 24 | ✗ |
| 25 | ✗ |
| 26 | ✓ |
| 27 | ✗ |
| 28 | ✗ |
| 29 | ✗ |
| 30 | ✗ |
| 31 | ✗ |
| 32 | ✓ |
| 33 | ✗ |
| **34** | ✗ |
| 35 | ✗ |
| 36 | ✗ |
| 37 | ✗ |
| 38 | ✗ |
| 39 | ✗ |
| 40 | ✗ |
| 41 | ✗ |
| 42 | ✗ |
| 43 | ✗ |
| 44 | ✓ |
| 45 | ✗ |
| 46 | ✗ |

| | |
|---|---|
| 47 | ✓ |
| 48 | ✗ |
| 49 | ✗ |
| 50 | ✗ |

All contents of this site are © 2024 Passmedicine Limited

Back to top

A 45-year-old man has been referred to the dermatology clinic to seek treatment for a long-term skin condition. He is an asylum seeker who has recently arrived in the UK and has never previously been able to access healthcare regarding his skin. He has not yet been started on any treatment. Approximately 20% of his total body surface area is affected by the condition.

His skin is examined, as shown below:

© Image used on license from DermNet NZ

What other condition is this patient most likely to have in addition to his skin disorder?

- Grave's disease
- Inflammatory bowel disease
- Melanoma
- Microcytic anaemia
- Systemic lupus erythematosus

Submit answer

Reference ranges

Score: **0%**

| | |
|---|---|
| 1 | - |
| 2 | - |
| 3 | - |
| 4 | - |
| 5 | - |
| 6 | - |
| 7 | - |
| 8 | - |
| 9 | - |
| 10 | - |
| 11 | - |
| 12 | - |
| 13 | - |
| 14 | - |
| 15 | - |
| 16 | - |
| 17 | - |
| 18 | - |
| 19 | - |
| 20 | - |
| 21 | - |
| 22 | - |
| 23 | - |
| 24 | - |
| 25 | - |
| 26 | - |
| 27 | - |
| 28 | - |
| 29 | - |
| 30 | - |
| 31 | - |
| 32 | - |
| 33 | - |
| 34 | - |

| | |
|---|---|
| **35** | - |

All contents of this site are © 2024 Passmedicine Limited

Back to top

A 45-year-old man has been referred to the dermatology clinic to seek treatment for a long-term skin condition. He is an asylum seeker who has recently arrived in the UK and has never previously been able to access healthcare regarding his skin. He has not yet been started on any treatment. Approximately 20% of his total body surface area is affected by the condition.

His skin is examined, as shown below:

© Image used on license from DermNet NZ

What other condition is this patient most likely to have in addition to his skin disorder?

- Grave's disease 74%
- Inflammatory bowel disease 12%
- Melanoma 3%
- Microcytic anaemia 6%
- Systemic lupus erythematosus 6%

The image shows a clear area of skin depigmentation with irregular borders, affecting the patient's back, shoulders and neck. This is a typical presentation of vitiligo, which is an autoimmune condition resulting from the destruction of melanocytes. Vitiligo can be challenging to treat, but treatment options are available that can help to restore pigment in depigmented skin and prevent

further depigmentation from occurring in other areas.

The correct answer is **Grave's disease**. As vitiligo is an autoimmune disease, it has a number of associations with other autoimmune conditions. The most common association is with autoimmune thyroid disease, which is found in 15% of adults with vitiligo.

**Microcytic anaemia** is incorrect. Vitiligo can be associated with pernicious anaemia, but this would cause B12 deficiency which typically causes a macrocytosis rather than microcytosis.

**Systemic lupus erythematosus** is incorrect. There is an association between systemic lupus erythematosus (SLE) and vitiligo, but this is much less common than thyroid disorders. Other conditions which can be associated with vitiligo include rheumatoid arthritis, Addison's disease, pernicious anaemia, alopecia areata, psoriasis and lichen sclerosis.

**Inflammatory bowel disease** is incorrect. There is a possible link between vitiligo and inflammatory bowel disease, although this requires further research and is less well established than the association between vitiligo and the conditions above.

**Melanoma** is incorrect. Surprisingly patients with vitiligo are at lower risk than the general population from skin malignancies, including squamous cell carcinoma, basal cell carcinoma and melanoma, even though the depigmented areas of skin are prone to sun damage. The mechanism for this lower risk is not completely understood and is an ongoing area of research.

Discuss (3) Improve

Next question

# Vitiligo

Vitiligo is an autoimmune condition which results in the loss of melanocytes and consequent depigmentation of the skin. It is thought to affect around 1% of the population and symptoms typically develop by the age of 20-30 years.

Associated conditions
- type 1 diabetes mellitus
- Addison's disease
- autoimmune thyroid disorders
- pernicious anaemia
- alopecia areata

Features

- well-demarcated patches of depigmented skin
- the peripheries tend to be most affected
- trauma may precipitate new lesions (Koebner phenomenon)

Management

- sunblock for affected areas of skin
- camouflage make-up
- topical corticosteroids may reverse the changes if applied early
- there may also be a role for topical tacrolimus and phototherapy, although caution needs to be exercised with light-skinned patients

123

Next question

**Textbooks**

High-yield textbook

Extended textbook

**Links**

DermNet NZ 8 3

Vitiligo

Suggest link | Report broken link

## Media

Vitiligo

Osmosis - YouTube 👍 0 👎 1

Report broken media

Score: **14%**

| | |
|---|---|
| 1 | ✗ |
| 2 | ✗ |
| 3 | ✓ |
| 4 | ✗ |
| 5 | ✗ |
| 6 | ✗ |
| 7 | ✗ |
| 8 | ✗ |
| 9 | ✗ |
| 10 | ✗ |
| 11 | ✓ |
| 12 | ✗ |
| 13 | ✓ |
| 14 | ✗ |
| 15 | ✗ |
| 16 | ✗ |
| 17 | ✗ |
| 18 | ✗ |

| | |
|---|---|
| 19 | ✗ |
| 20 | ✗ |
| 21 | ✗ |
| 22 | ✗ |
| 23 | ✗ |
| 24 | ✗ |
| 25 | ✗ |
| 26 | ✓ |
| 27 | ✗ |
| 28 | ✗ |
| 29 | ✗ |
| 30 | ✗ |
| 31 | ✗ |
| 32 | ✓ |
| 33 | ✗ |
| 34 | ✗ |
| **35** | ✗ |
| 36 | ✗ |
| 37 | ✗ |
| 38 | ✗ |
| 39 | ✗ |
| 40 | ✗ |
| 41 | ✗ |
| 42 | ✗ |
| 43 | ✗ |
| 44 | ✓ |
| 45 | ✗ |
| 46 | ✗ |
| 47 | ✓ |
| 48 | ✗ |
| 49 | ✗ |
| 50 | ✗ |

All contents of this site are © 2024 Passmedicine Limited

A 78-year-old woman presents with a number of blistering lesions on her torso. Around one week prior to the skin lesions developing she noticed widespread mouth ulceration:

© Image used on license from DermNet NZ

What is the most likely diagnosis?

- Epidermolysis bullosa
- Pemphigus vulgaris
- Bullous pemphigoid
- Stevens-Johnson Syndrome
- Staphylococcal scalded skin syndrome

Submit answer

Reference ranges

Score: **0%**

| | |
|---|---|
| 1 | - |
| 2 | - |
| 3 | - |
| 4 | - |
| 5 | - |
| 6 | - |
| 7 | - |
| 8 | - |
| 9 | - |
| 10 | - |
| 11 | - |
| 12 | - |
| 13 | - |
| 14 | - |
| 15 | - |
| 16 | - |
| 17 | - |
| 18 | - |
| 19 | - |
| 20 | - |
| 21 | - |
| 22 | - |
| 23 | - |
| 24 | - |
| 25 | - |
| 26 | - |
| 27 | - |
| 28 | - |
| 29 | - |

30 -
31 -
32 -
33 -
34 -
35 -
**36** -

All contents of this site are © 2024 Passmedicine Limited Back to top

A 78-year-old woman presents with a number of blistering lesions on her torso. Around one week prior to the skin lesions developing she noticed widespread mouth ulceration:

© Image used on license from DermNet NZ

What is the most likely diagnosis?

| | |
|---|---|
| Epidermolysis bullosa | 2% |
| Pemphigus vulgaris | 74% |
| Bullous pemphigoid | 7% |
| Stevens-Johnson Syndrome | 14% |
| Staphylococcal scalded skin syndrome | 3% |

The correct answer is **Pemphigus vulgaris**. This condition is an autoimmune blistering disorder that often initially presents with oral lesions, which may precede the onset of skin blisters by weeks to months. The image demonstrates flaccid bullae and erosions, which are characteristic of pemphigus vulgaris. In this condition, autoantibodies target desmoglein 3, a protein in the desmosomes that connect keratinocytes in the epidermis. This results in intraepidermal blistering.

**Epidermolysis bullosa** is incorrect because it typically begins in infancy or early childhood with blistering that occurs following minor trauma to the skin. It's a group of rare inherited skin disorders characterised by blister formation in response to mechanical trauma.

The diagnosis of **Bullous pemphigoid** is also incorrect. Bullous pemphigoid generally affects patients over the age of 60 and usually starts with pruritus, followed by the development of tense bullae. Oral involvement is less common than in pemphigus vulgaris and when present, usually follows rather than precedes cutaneous involvement.

**Stevens-Johnson Syndrome** (SJS) can be ruled out as well. SJS is usually drug-induced and involves not only the skin but also the mucous membranes such as eyes and genitals along with systemic symptoms like fever and malaise. The rash usually starts as erythematous macules which progress to form blisters and then slough off leading to painful erosions.

Lastly, **Staphylococcal scalded skin syndrome** (SSSS) is unlikely due to the patient's age and presentation. SSSS typically affects neonates and children under 5 years old, presenting with widespread erythema, exfoliation, and purulent conjunctivitis without mucosal involvement. It's caused by exfoliative toxins produced by certain strains of *Staphylococcus aureus*.

Discuss (3) | Improve

Next question >

## Pemphigus vulgaris

Pemphigus vulgaris is an autoimmune disease caused by antibodies directed against desmoglein 3, a cadherin-type epithelial cell adhesion molecule. It is more common in the Ashkenazi Jewish population.

Features

- mucosal ulceration is common and often the presenting symptom. Oral involvement is seen in 50-70% of patients
- skin blistering - flaccid, easily ruptured vesicles and bullae. Lesions are typically painful but not itchy. These may develop months after the initial mucosal symptoms. Nikolsky's describes the

spread of bullae following application of horizontal, tangential pressure to the skin
- acantholysis on biopsy

Management
- steroids are first-line
- immunosuppressants

123

Next question >

### Textbooks

High-yield textbook

Extended textbook

### Links

British Association of Dermatologists 7 2

2017 Guidelines for the management of pemphigus vulgaris

DermNet NZ 9 2

Pemphigus vulgaris

Suggest link | Report broken link

## Media

Pemphigus vulgaris

Osmosis - YouTube 3 0

Report broken media

Score: **14%**

| | |
|---|---|
| 1 | ✗ |
| 2 | ✗ |
| 3 | ✓ |
| 4 | ✗ |
| 5 | ✗ |
| 6 | ✗ |
| 7 | ✗ |
| 8 | ✗ |
| 9 | ✗ |
| 10 | ✗ |
| 11 | ✓ |
| 12 | ✗ |
| 13 | ✓ |
| 14 | ✗ |
| 15 | ✗ |
| 16 | ✗ |
| 17 | ✗ |
| 18 | ✗ |
| 19 | ✗ |

| | |
|---|---|
| 20 | ✗ |
| 21 | ✗ |
| 22 | ✗ |
| 23 | ✗ |
| 24 | ✗ |
| 25 | ✗ |
| 26 | ✓ |
| 27 | ✗ |
| 28 | ✗ |
| 29 | ✗ |
| 30 | ✗ |
| 31 | ✗ |
| 32 | ✓ |
| 33 | ✗ |
| 34 | ✗ |
| 35 | ✗ |
| **36** | ✗ |
| 37 | ✗ |
| 38 | ✗ |
| 39 | ✗ |
| 40 | ✗ |
| 41 | ✗ |
| 42 | ✗ |
| 43 | ✗ |
| 44 | ✓ |
| 45 | ✗ |
| 46 | ✗ |
| 47 | ✓ |
| 48 | ✗ |
| 49 | ✗ |
| 50 | ✗ |

All contents of this site are © 2024 Passmedicine Limited

Back to top

A 19-year-old man develops multiple tear-drop papules on his trunk and limbs. He is otherwise well. A diagnosis of guttate psoriasis is suspected. What is the most appropriate management?

- Oral penicillin for 14 days
- Reassurance + topical treatment if lesions are symptomatic
- Oral penicillin for 14 days + topical treatment if lesions are symptomatic
- Referral to secondary care
- Oral corticosteroids

Submit answer

Reference ranges

Score: **0%**

1 -
2 -
3 -
4 -
5 -
6 -
7 -
8 -
9 -
10 -
11 -
12 -
13 -

14 -
15 -
16 -
17 -
18 -
19 -
20 -
21 -
22 -
23 -
24 -
25 -
26 -
27 -
28 -
29 -
30 -
31 -
32 -
33 -
34 -
35 -
36 -
**37** -

All contents of this site are © 2024 Passmedicine Limited
Back to top

A 19-year-old man develops multiple tear-drop papules on his trunk and limbs. He is otherwise well. A diagnosis of guttate psoriasis is suspected. What is the most appropriate management?

| | |
|---|---|
| Oral penicillin for 14 days | 1% |
| Reassurance + topical treatment if lesions are symptomatic | 80% |
| Oral penicillin for 14 days + topical treatment if lesions are symptomatic | 8% |
| Referral to secondary care | 3% |
| Oral corticosteroids | 8% |

The British Association of Dermatologists state in their psoriasis guidelines that 'evidence does not support a therapeutic benefit from antibiotic therapy'.

Discuss Improve

Next question

## Guttate psoriasis

Guttate psoriasis is more common in children and adolescents. It may be precipitated by a streptococcal infection 2-4 weeks prior to the lesions appearing.

Features

- tear drop papules on the trunk and limbs
  - *gutta* is Latin for drop
  - pink, scaly patches or plques of psoriasis
- tends to be acute onset over days

Management
- most cases resolve spontaneously within 2-3 months
- there is no firm evidence to support the use of antibiotics to eradicate streptococcal infection
- topical agents as per psoriasis
- UVB phototherapy
- tonsillectomy may be necessary with recurrent episodes

## Differentiating guttate psoriasis and pityriasis rosea

| | **Guttate psoriasis** | **Pityriasis rosea** |
|---|---|---|
| **Prodrome** | Classically preceded by a streptococcal sore throat 2-4 weeks | Many patients report recent respiratory tract infections but this is not common in questions |
| **Appearance** | 'Tear drop', scaly papules on the trunk and limbs | Herald patch followed 1-2 weeks later by multiple erythematous, slightly raised oval lesions with a fine scale confined to the outer aspects of the lesions.<br><br>May follow a characteristic distribution with the longitudinal diameters of the oval lesions running parallel to the line of Langer. This may produce a 'fir-tree' appearance |
| **Treatment / natural history** | Most cases resolve spontaneously within 2-3 months<br>Topical agents as per psoriasis<br>UVB phototherapy | Self-limiting, resolves after around 6 weeks |

AI + Q 123

Next question

## Textbooks

High-yield textbook

Extended textbook

## Links

Clinical Knowledge Summaries 12 7

Guttate psoriasis guidelines

Dermnet NZ 11 3

Guttate psoriasis

Suggest link Report broken link

## Media

Psoriasis

Osmosis - YouTube 2 0

Report broken media

Score: **14%**

| | |
|---|---|
| 1 | ✗ |
| 2 | ✗ |
| 3 | ✓ |
| 4 | ✗ |
| 5 | ✗ |
| 6 | ✗ |
| 7 | ✗ |
| 8 | ✗ |
| 9 | ✗ |
| 10 | ✗ |
| 11 | ✓ |
| 12 | ✗ |
| 13 | ✓ |
| 14 | ✗ |
| 15 | ✗ |
| 16 | ✗ |
| 17 | ✗ |
| 18 | ✗ |
| 19 | ✗ |
| 20 | ✗ |
| 21 | ✗ |
| 22 | ✗ |
| 23 | ✗ |
| 24 | ✗ |
| 25 | ✗ |
| 26 | ✓ |
| 27 | ✗ |
| 28 | ✗ |
| 29 | ✗ |
| 30 | ✗ |
| 31 | ✗ |
| 32 | ✓ |

| | |
|---|---|
| 33 | ✗ |
| 34 | ✗ |
| 35 | ✗ |
| 36 | ✗ |
| **37** | ✗ |
| 38 | ✗ |
| 39 | ✗ |
| 40 | ✗ |
| 41 | ✗ |
| 42 | ✗ |
| 43 | ✗ |
| 44 | ✓ |
| 45 | ✗ |
| 46 | ✗ |
| 47 | ✓ |
| 48 | ✗ |
| 49 | ✗ |
| 50 | ✗ |

All contents of this site are © 2024 Passmedicine Limited

Back to top

A 40-year-old man presents to the dermatology clinic with a 2-week history of an evolving, painful rash. He reported that the lesions initially began inside his mouth before spreading to the rest of his body. Other than a brief coryzal illness before the onset of the rash, he has no past medical history of note and takes no regular medications.

On examination, he has a temperature of 37.8ºC with a heart rate of 96bpm and blood pressure of 117/61mmHg. His rash is examined, as shown below:

© Image used on license from DermNet NZ

What is the most likely diagnosis?

- Bullous pemphigoid
- Pemphigus vulgaris
- Steven Johnson syndrome
- Toxic epidermal necrolysis
- Toxic shock syndrome

Submit answer

Reference ranges

Score: **0%**

1 -
2 -
3 -
4 -
5 -
6 -
7 -
8 -
9 -
10 -
11 -
12 -
13 -
14 -
15 -
16 -
17 -
18 -
19 -
20 -

21 -
22 -
23 -
24 -
25 -
26 -
27 -
28 -
29 -
30 -
31 -
32 -
33 -
34 -
35 -
36 -
37 -
**38** -

All contents of this site are © 2024 Passmedicine Limited Back to top

A 40-year-old man presents to the dermatology clinic with a 2-week history of an evolving, painful rash. He reported that the lesions initially began inside his mouth before spreading to the rest of his body. Other than a brief coryzal illness before the onset of the rash, he has no past medical history of note and takes no regular medications.

On examination, he has a temperature of 37.8ºC with a heart rate of 96bpm and blood pressure of 117/61mmHg. His rash is examined, as shown below:

© Image used on license from DermNet NZ

What is the most likely diagnosis?

| | |
|---|---|
| Bullous pemphigoid | 3% |
| Pemphigus vulgaris | 75% |
| Steven Johnson syndrome | 12% |
| Toxic epidermal necrolysis | 7% |
| Toxic shock syndrome | 2% |

**Pemphigus vulgaris** is correct. This patient has multiple flaccid blistering lesions, a portion of which have burst. These blisters are filled with a clear fluid that, once ruptured, causes itchy, erythematous and painful erosions. Pemphigus vulgaris is an autoimmune disease that causes skin blistering that often ruptures. Unlike bullous pemphigoid, mucosal ulceration is a common presenting feature in pemphigus vulgaris and can precede the spread of other lesions on the body. Approximately 50-70% of patients have oro-mucosal involvement in pemphigus vulgaris with widespread superficial blistering and erosions and ulceration.

**Bullous pemphigoid** is incorrect. Unlike pemphigus vulgaris, bullous pemphigoid causes tense blisters that are less likely to rupture. The condition is also more common in the elderly population, particularly elderly women.

**Steven Johnson syndrome** (SJS) is classically a drug reaction secondary to anti-epileptics, antibiotics and anti-inflammatory medications. Symptoms include flu-like symptoms, widespread blistering and mucosal involvement. Although there is some overlap with this patient's symptoms, there is no history of recent drug administration.

**Toxic epidermal necrolysis** (TEN) is incorrect. This is a severe form of SJS where > 30% of the total body surface area of the skin is affected. Similarly to SJS, TEN is caused by a drug reaction, which is not described in this scenario.

**Toxic shock syndrome** is incorrect. This is a severe illness secondary to exotoxin-producing bacteria such as *Staphylococcus aureus*. It causes systemic upset and a diffuse macular erythematous rash with skin-shedding. However, blistering is uncommon.

Discuss Improve

Next question

## Pemphigus vulgaris

Pemphigus vulgaris is an autoimmune disease caused by antibodies directed against desmoglein 3, a cadherin-type epithelial cell adhesion molecule. It is more common in the Ashkenazi Jewish population.

Features

- mucosal ulceration is common and often the presenting symptom. Oral involvement is seen in 50-70% of patients
- skin blistering - flaccid, easily ruptured vesicles and bullae. Lesions are typically painful but not itchy. These may develop months after the initial mucosal symptoms. Nikolsky's describes the spread of bullae following application of horizontal, tangential pressure to the skin
- acantholysis on biopsy

Management

- steroids are first-line
- immunosuppressants

123

Next question ›

**Textbooks**

High-yield textbook

Extended textbook

## Links

British Association of Dermatologists 7 2

2017 Guidelines for the management of pemphigus vulgaris

DermNet NZ 9 2

Pemphigus vulgaris

Suggest link Report broken link

## Media

Pemphigus vulgaris

Osmosis - YouTube 3 0

Report broken media

Score: **14%**

1 ✗
2 ✗
3 ✓
4 ✗
5 ✗
6 ✗
7 ✗
8 ✗
9 ✗
10 ✗
11 ✓

| | |
|---|---|
| 12 | ✗ |
| 13 | ✓ |
| 14 | ✗ |
| 15 | ✗ |
| 16 | ✗ |
| 17 | ✗ |
| 18 | ✗ |
| 19 | ✗ |
| 20 | ✗ |
| 21 | ✗ |
| 22 | ✗ |
| 23 | ✗ |
| 24 | ✗ |
| 25 | ✗ |
| 26 | ✓ |
| 27 | ✗ |
| 28 | ✗ |
| 29 | ✗ |
| 30 | ✗ |
| 31 | ✗ |
| 32 | ✓ |
| 33 | ✗ |
| 34 | ✗ |
| 35 | ✗ |
| 36 | ✗ |
| 37 | ✗ |
| **38** | ✗ |
| 39 | ✗ |
| 40 | ✗ |
| 41 | ✗ |
| 42 | ✗ |
| 43 | ✗ |
| 44 | ✓ |
| 45 | ✗ |
| 46 | ✗ |
| 47 | ✓ |

48 ✕

49 ✕

50 ✕

All contents of this site are © 2024 Passmedicine Limited

A 44-year-old woman presents to the dermatology clinic with a 5-week history of skin irritation. She reports that the skin on the back of her neck feels thick and rough to the touch and is occasionally itchy. She used a hand mirror to visualise the skin and was concerned that the colour seems to have changed compared to normal.

On examination, her observations are recorded within normal limits. Her neck is examined, as shown below:

© Image used on license from DermNet NZ

Given the likely diagnosis, what is the most appropriate investigation to consider?

- ANA panel
- IgA tissue transglutaminases
- Random cortisol
- Random glucose level
- Skin biopsy

Submit answer

Reference ranges

Score: **0%**

1 -
2 -
3 -
4 -
5 -
6 -
7 -
8 -
9 -
10 -
11 -
12 -
13 -
14 -
15 -
16 -
17 -
18 -
19 -
20 -
21 -
22 -
23 -
24 -
25 -
26 -
27 -
28 -
29 -

30 -
31 -
32 -
33 -
34 -
35 -
36 -
37 -
38 -
**39** -

All contents of this site are © 2024 Passmedicine Limited Back to top

A 44-year-old woman presents to the dermatology clinic with a 5-week history of skin irritation. She reports that the skin on the back of her neck feels thick and rough to the touch and is occasionally itchy. She used a hand mirror to visualise the skin and was concerned that the colour seems to have changed compared to normal.

On examination, her observations are recorded within normal limits. Her neck is examined, as shown below:

© Image used on license from DermNet NZ

Given the likely diagnosis, what is the most appropriate investigation to consider?

| | |
|---|---|
| ANA panel | 1% |
| IgA tissue transglutaminases | 4% |
| Random cortisol | 16% |
| Random glucose level | 75% |
| Skin biopsy | 4% |

**Random glucose level** is correct. This patient has a diagnosis of acanthosis nigricans

characterised by hyperkeratosis and hyperpigmentation of the skin, predominantly affecting the flexural skin folds such as the axillae, back of the neck and groin. The skin may have a velvety texture secondary to papillomatous overgrowth of the epidermis (which can be visualised in this patient). Common underlying causes include metabolic diseases such as obesity, type 2 diabetes mellitus and polycystic ovarian syndrome. Therefore, an important initial investigation includes checking random or fasting glucose levels to check for the presence of diabetes mellitus.

**ANA panel** is incorrect. This is used in the diagnosis of autoimmune diseases such as rheumatic disease and vasculitis. However, it has no role in the diagnosis of acanthosis nigricans as it is not associated with underlying rheumatological disease.

**IgA tissue transglutaminase** is incorrect. This is used to diagnose coeliac disease that is associated with a vesicular, erythematous and itchy rash seen on the extensor surfaces of the skin.

**Random cortisol** is incorrect. This is used in the diagnosis of primary hypoadrenalism (e.g. Addison's disease). Addison's disease is associated with the appearance of tanned skin due to excess ACTH production causing stimulation of melanocytes. However, it is not used to diagnose acanthosis nigricans.

**Skin biopsy** is incorrect. It is not used in the diagnosis of acanthosis nigricans.

Discuss (1) | Improve

Next question ›

## Acanthosis nigricans

Describes symmetrical, brown, velvety plaques that are often found on the neck, axilla and groin.

Causes

- type 2 diabetes mellitus
- gastrointestinal cancer
- obesity
- polycystic ovarian syndrome
- acromegaly
- Cushing's disease
- hypothyroidism
- familial
- Prader-Willi syndrome
- drugs
    - combined oral contraceptive pill

- nicotinic acid

Pathophysiology

- insulin resistance → hyperinsulinemia → stimulation of keratinocytes and dermal fibroblast proliferation via interaction with insulin-like growth factor receptor-1 (IGFR1)

AI + Q 123

Next question >

## Textbooks

High-yield textbook

Extended textbook

## Links

DermNet NZ 54 21

Acanthosis nigricans

Suggest link Report broken link

Score: **14%**

| | |
|---|---|
| 1 | ✗ |
| 2 | ✗ |
| 3 | ✓ |
| 4 | ✗ |
| 5 | ✗ |
| 6 | ✗ |
| 7 | ✗ |
| 8 | ✗ |
| 9 | ✗ |
| 10 | ✗ |
| 11 | ✓ |
| 12 | ✗ |
| 13 | ✓ |
| 14 | ✗ |
| 15 | ✗ |
| 16 | ✗ |
| 17 | ✗ |
| 18 | ✗ |
| 19 | ✗ |
| 20 | ✗ |
| 21 | ✗ |
| 22 | ✗ |
| 23 | ✗ |
| 24 | ✗ |
| 25 | ✗ |
| 26 | ✓ |
| 27 | ✗ |
| 28 | ✗ |
| 29 | ✗ |
| 30 | ✗ |
| 31 | ✗ |
| 32 | ✓ |
| 33 | ✗ |

| | |
|---|---|
| 34 | ✗ |
| 35 | ✗ |
| 36 | ✗ |
| 37 | ✗ |
| 38 | ✗ |
| **39** | ✗ |
| 40 | ✗ |
| 41 | ✗ |
| 42 | ✗ |
| 43 | ✗ |
| 44 | ✓ |
| 45 | ✗ |
| 46 | ✗ |
| 47 | ✓ |
| 48 | ✗ |
| 49 | ✗ |
| 50 | ✗ |

All contents of this site are © 2024 Passmedicine Limited

A 53-year-old man presents complaining of an itchy scalp and dandruff. On examination he is noted to have the following lesions on his scalp, along with similar lesions behind his ears and around his nose.

© Image used on license from DermNet NZ

He has tried 'Head and Shoulders' and 'Neutrogen T-gel' but with poor results. Which one of the following is the most appropriate treatment for his scalp?

- Topical hydrocortisone
- Topical dermovate
- Topical selenium sulphide
- Oral terbinafine
- Topical ketoconazole

Submit answer

Reference ranges

Score: **0%**

| | |
|---|---|
| 1 | - |
| 2 | - |
| 3 | - |
| 4 | - |
| 5 | - |
| 6 | - |
| 7 | - |
| 8 | - |
| 9 | - |
| 10 | - |
| 11 | - |
| 12 | - |
| 13 | - |
| 14 | - |
| 15 | - |
| 16 | - |
| 17 | - |
| 18 | - |
| 19 | - |
| 20 | - |
| 21 | - |
| 22 | - |
| 23 | - |
| 24 | - |
| 25 | - |
| 26 | - |
| 27 | - |
| 28 | - |
| 29 | - |
| 30 | - |
| 31 | - |
| 32 | - |
| 33 | - |
| 34 | - |
| 35 | - |
| 36 | - |
| 37 | - |
| 38 | - |

| | |
|---|---|
| 39 | - |
| **40** | - |

All contents of this site are © 2024 Passmedicine Limited

A 53-year-old man presents complaining of an itchy scalp and dandruff. On examination he is noted to have the following lesions on his scalp, along with similar lesions behind his ears and around his nose.

© Image used on license from DermNet NZ

He has tried 'Head and Shoulders' and 'Neutrogen T-gel' but with poor results. Which one of the following is the most appropriate treatment for his scalp?

| | |
|---|---|
| Topical hydrocortisone | 8% |
| Topical dermovate | 6% |
| Topical selenium sulphide | 12% |
| Oral terbinafine | 4% |
| Topical ketoconazole | 71% |

Seborrhoeic dermatitis - first-line treatment is topical ketoconazole

Important for me Less important

The most appropriate treatment for this patient's scalp is **topical ketoconazole**. The clinical presentation of an itchy scalp, dandruff, and eczema on the scalp, behind the ears, and around the

nose suggests a diagnosis of seborrhoeic dermatitis. Seborrhoeic dermatitis is a common inflammatory skin condition that mainly affects areas rich in sebaceous glands such as the scalp, face, and upper trunk. It is thought to be related to an overgrowth of yeast-like fungi from the genus *Malassezia*, which are part of the normal skin flora.

Topical ketoconazole is an antifungal medication that targets *Malassezia* species and helps reduce inflammation in seborrhoeic dermatitis. It can be applied as a shampoo or cream depending on the affected area. In this case, since the patient has already tried other shampoos without success and his symptoms involve both his scalp and face, topical ketoconazole would be suitable to manage his condition.

**Topical hydrocortisone** may provide some relief from itching and inflammation associated with seborrhoeic dermatitis; however, it does not target the underlying fungal overgrowth contributing to the condition. Additionally, long-term use of topical corticosteroids on facial skin can cause thinning of the skin and other side effects.

**Topical dermovate**, which contains clobetasol propionate (a potent corticosteroid), may also help reduce inflammation but carries similar risks as hydrocortisone regarding long-term use on facial skin. Moreover, it does not address the fungal component of seborrhoeic dermatitis.

**Topical selenium sulphide** is another antifungal agent that may be used in treating seborrhoeic dermatitis. However, it is not as effective as ketoconazole and can cause skin irritation, making it a less suitable option for this patient who has already tried other shampoos without success.

**Oral terbinafine** is an antifungal medication that is primarily used to treat dermatophyte infections such as tinea pedis (athlete's foot), tinea corporis (ringworm), and tinea capitis (scalp ringworm). It is not typically prescribed for seborrhoeic dermatitis, as its efficacy against *Malassezia* species is limited compared to topical ketoconazole. Additionally, oral antifungal therapy carries a risk of systemic side effects and potential drug interactions, making it a less desirable option in this case.

Discuss | Improve

Next question

## Seborrhoeic dermatitis in adults

Seborrhoeic dermatitis in adults is a chronic dermatitis thought to be caused by an inflammatory reaction related to a proliferation of a normal skin inhabitant, a fungus called *Malassezia furfur* (formerly known as *Pityrosporum ovale*). It is common, affecting around 2% of the general population.

Features

- eczematous lesions on the sebum-rich areas: scalp (may cause dandruff), periorbital, auricular and nasolabial folds
- otitis externa and blepharitis may develop

Associated conditions include

- HIV
- Parkinson's disease

Scalp disease management

- the first-line treatment is ketoconazole 2% shampoo
- over the counter preparations containing zinc pyrithione ('Head & Shoulders') and tar ('Neutrogena T/Gel') may be used if ketoconazole is not appropriate or acceptable to the person
- selenium sulphide and topical corticosteroid may also be useful

Face and body management

- topical antifungals: e.g. ketoconazole
- topical steroids: best used for short periods
- difficult to treat - recurrences are common

123

Next question

**Textbooks**

High-yield textbook

Extended textbook

## Links

Clinical Knowledge Summaries 20 11

Seborrhoeic dermatitis guidelines

DermNet NZ 24 4

Overview and pictures of seborrhoeic dermatitis

Suggest link

Report broken link

Score: **14%**

| | |
|---|---|
| 1 | ✗ |
| 2 | ✗ |
| 3 | ✓ |
| 4 | ✗ |
| 5 | ✗ |
| 6 | ✗ |
| 7 | ✗ |
| 8 | ✗ |
| 9 | ✗ |
| 10 | ✗ |
| 11 | ✓ |
| 12 | ✗ |
| 13 | ✓ |
| 14 | ✗ |
| 15 | ✗ |
| 16 | ✗ |

| | |
|---|---|
| 17 | ✗ |
| 18 | ✗ |
| 19 | ✗ |
| 20 | ✗ |
| 21 | ✗ |
| 22 | ✗ |
| 23 | ✗ |
| 24 | ✗ |
| 25 | ✗ |
| 26 | ✓ |
| 27 | ✗ |
| 28 | ✗ |
| 29 | ✗ |
| 30 | ✗ |
| 31 | ✗ |
| 32 | ✓ |
| 33 | ✗ |
| 34 | ✗ |
| 35 | ✗ |
| 36 | ✗ |
| 37 | ✗ |
| 38 | ✗ |
| 39 | ✗ |
| **40** | ✗ |
| 41 | ✗ |
| 42 | ✗ |
| 43 | ✗ |
| 44 | ✓ |
| 45 | ✗ |
| 46 | ✗ |
| 47 | ✓ |
| 48 | ✗ |
| 49 | ✗ |
| 50 | ✗ |

All contents of this site are © 2024 Passmedicine Limited

A 29-year-old woman presents with a rash over the shins for the past week, as shown below:

© Image used on license from DermNet NZ

She describes the lesions as tender. She is otherwise well. She has a past medical history of asthma, recurrent acne vulgaris, chronic knee pain following a sports injury and epilepsy. Her medications include salbutamol and beclometasone inhalers, montelukast, oxytetracycline, a combined oral contraceptive pill, naproxen and lamotrigine.

Given the likely diagnosis, which of the following is the most likely cause?

- Combined oral contraceptive pill
- Lamotrigine
- Montelukast
- Naproxen
- Oxytetracycline

Submit answer

Reference ranges

Score: **0%**

| | |
|---|---|
| 1 | - |
| 2 | - |
| 3 | - |
| 4 | - |
| 5 | - |
| 6 | - |
| 7 | - |
| 8 | - |
| 9 | - |
| 10 | - |
| 11 | - |
| 12 | - |
| 13 | - |
| 14 | - |
| 15 | - |
| 16 | - |
| 17 | - |
| 18 | - |
| 19 | - |
| 20 | - |
| 21 | - |
| 22 | - |
| 23 | - |
| 24 | - |
| 25 | - |
| 26 | - |
| 27 | - |
| 28 | - |
| 29 | - |
| 30 | - |
| 31 | - |
| 32 | - |
| 33 | - |
| 34 | - |

| | |
|---|---|
| 35 | - |
| 36 | - |
| 37 | - |
| 38 | - |
| 39 | - |
| 40 | - |
| **41** | - |

All contents of this site are © 2024 Passmedicine Limited
Back to top

A 29-year-old woman presents with a rash over the shins for the past week, as shown below:

© Image used on license from DermNet NZ

She describes the lesions as tender. She is otherwise well. She has a past medical history of asthma, recurrent acne vulgaris, chronic knee pain following a sports injury and epilepsy. Her medications include salbutamol and beclometasone inhalers, montelukast, oxytetracycline, a combined oral contraceptive pill, naproxen and lamotrigine.

Given the likely diagnosis, which of the following is the most likely cause?

| | |
|---|---|
| Combined oral contraceptive pill | 85% |
| Lamotrigine | 5% |
| Montelukast | 2% |
| Naproxen | 3% |
| Oxytetracycline | 5% |

The diagnosis here is that of erythema nodosum - tender, nodular inflammation of subcutaneous fat, typically over the shins. The image above depicts this well - multiple red lesions are visible, appearing slightly raised and obviously inflamed, across both shins. They are generally oval or round in shape and no ulcers can be seen in the photo, in keeping with erythema nodosum, which

does not ulcerate. It normally resolves within 6 weeks and heals without scarring. There are a number of associations, including infections, sarcoidosis, inflammatory bowel disease, Behcet's, and various medications. Of the drugs listed above, the most likely cause is the combined oral contraceptive pill, which is well documented as causing erythema nodosum.

Very rarely, lamotrigine is associated with erythema multiforme and Stevens-Johnson syndrome, which are much more severe, widespread cutaneous disorders than erythema nodosum and can be life-threatening if they progress. It is not associated with erythema nodosum.

Montelukast is used for control of this patient's asthma, as the next step-up after a low-dose steroid inhaler; it is not linked to erythema nodosum.

Naproxen is presumably being used for her knee pain. It is not linked to the development of erythema nodosum and is, in fact, mentioned in various case reports as being effective in the management of pain arising from the condition.

Oxytetracycline is an antibiotic, being used here for acne vulgaris. Whilst penicillins and sulphonamides are linked to erythema nodosum, tetracyclines are not.



## Erythema nodosum

Overview

- inflammation of subcutaneous fat
- typically causes tender, erythematous, nodular lesions
- usually occurs over shins, may also occur elsewhere (e.g. forearms, thighs)
- usually resolves within 6 weeks
- lesions heal without scarring

Causes

- infection
    - streptococci
    - tuberculosis
    - brucellosis
- systemic disease
    - sarcoidosis
    - inflammatory bowel disease

    - Behcet's
- malignancy/lymphoma
- drugs
    - penicillins
    - sulphonamides
    - combined oral contraceptive pill
- pregnancy

\+ Q 123

Next question >

## Textbooks

High-yield textbook

Extended textbook

## Links

DermNet NZ

Erythema nodosum

30 14

Suggest link | Report broken link

Score: **14%**

| | |
|---|---|
| 1 | ✗ |
| 2 | ✗ |
| 3 | ✓ |
| 4 | ✗ |
| 5 | ✗ |
| 6 | ✗ |
| 7 | ✗ |
| 8 | ✗ |
| 9 | ✗ |
| 10 | ✗ |
| 11 | ✓ |
| 12 | ✗ |
| 13 | ✓ |
| 14 | ✗ |
| 15 | ✗ |
| 16 | ✗ |
| 17 | ✗ |
| 18 | ✗ |
| 19 | ✗ |
| 20 | ✗ |
| 21 | ✗ |
| 22 | ✗ |
| 23 | ✗ |
| 24 | ✗ |
| 25 | ✗ |
| 26 | ✓ |

| | |
|---|---|
| 27 | ✗ |
| 28 | ✗ |
| 29 | ✗ |
| 30 | ✗ |
| 31 | ✗ |
| 32 | ✓ |
| 33 | ✗ |
| 34 | ✗ |
| 35 | ✗ |
| 36 | ✗ |
| 37 | ✗ |
| 38 | ✗ |
| 39 | ✗ |
| 40 | ✗ |
| **41** | ✗ |
| 42 | ✗ |
| 43 | ✗ |
| 44 | ✓ |
| 45 | ✗ |
| 46 | ✗ |
| 47 | ✓ |
| 48 | ✗ |
| 49 | ✗ |
| 50 | ✗ |

All contents of this site are © 2024 Passmedicine Limited

Back to top

A 43-year-old woman comes for review. A few months ago she developed redness around her nose and cheeks. This is worse after drinking alcohol. She is concerned as one of her work colleagues asked her if she had a drink problem despite her drinking 10 units per week.

© Image used on license from DermNet NZ

What is the most likely diagnosis?

- Mitral stenosis
- Seborrhoeic dermatitis
- Alcohol-related skin changes
- Acne rosacea
- Systemic lupus erythematosus

Submit answer

Reference ranges

Score: **0%**

| | |
|---|---|
| 1 | - |
| 2 | - |
| 3 | - |
| 4 | - |
| 5 | - |
| 6 | - |
| 7 | - |
| 8 | - |
| 9 | - |
| 10 | - |
| 11 | - |
| 12 | - |
| 13 | - |
| 14 | - |
| 15 | - |
| 16 | - |
| 17 | - |
| 18 | - |
| 19 | - |
| 20 | - |
| 21 | - |
| 22 | - |
| 23 | - |
| 24 | - |
| 25 | - |
| 26 | - |
| 27 | - |
| 28 | - |
| 29 | - |
| 30 | - |
| 31 | - |
| 32 | - |
| 33 | - |
| 34 | - |
| 35 | - |
| 36 | - |
| 37 | - |
| 38 | - |

| | |
|---|---|
| 39 | - |
| 40 | - |
| 41 | - |
| **42** | - |

All contents of this site are © 2024 Passmedicine Limited

A 43-year-old woman comes for review. A few months ago she developed redness around her nose and cheeks. This is worse after drinking alcohol. She is concerned as one of her work colleagues asked her if she had a drink problem despite her drinking 10 units per week.

© Image used on license from DermNet NZ

What is the most likely diagnosis?

- Mitral stenosis 1%
- Seborrhoeic dermatitis 2%
- Alcohol-related skin changes 2%
- Acne rosacea 86%
- Systemic lupus erythematosus 9%

Rosacea features:

- nose, cheeks and forehead
- flushing, erythema, telangiectasia → papules and pustules

Important for me Less important

This is a typical history of acne rosacea.

Discuss (1) Improve

Next question

## Rosacea

Rosacea (sometimes referred to as acne rosacea) is a chronic skin disease of unknown aetiology.

Features
- typically affects nose, cheeks and forehead
- flushing is often first symptom
- telangiectasia are common
- later develops into persistent erythema with papules and pustules
- rhinophyma
- ocular involvement: blepharitis
- sunlight may exacerbate symptoms

Management
- simple measures
  - recommend daily application of a high-factor sunscreen
  - camouflage creams may help conceal redness
- predominant erythema/flushing
  - topical brimonidine gel may be considered for patients with predominant flushing but limited telangiectasia
  - brimonidine is a topical alpha-adrenergic agonist
  - this can be used on an 'as required basis' to temporarily reduce redness
  - it typically reduces redness within 30 minutes, reaching peak action at 3-6 hours, after which the redness returns to the baseline
- mild-to-moderate papules and/or pustules
  - topical ivermectin is first-line
  - alternatives include: topical metronidazole or topical azelaic acid

- moderate-to-severe papules and/or pustules
    - combination of topical ivermectin + oral doxycycline

Referral should be considered if

- symptoms have not improved with optimal management in primary care
    - laser therapy may be appropriate for patients with prominent telangiectasia
- patients with a rhinophyma

+ Q 123

Next question >

## Textbooks

High-yield textbook

Extended textbook

## Links

DermNet NZ 11 17

Rhinophyma

BNF 10 11

Acne rosacea

Dermnet NZ 23 13

Acne rosacea

Clinical Knowledge Summaries

19 10

Acne rosacea guidelines

Primary Care Dermatology Society 27 9

Rosacea review

Suggest link Report broken link

Score: **14%**

| | |
|---|---|
| 1 | ✗ |
| 2 | ✗ |
| 3 | ✓ |
| 4 | ✗ |
| 5 | ✗ |
| 6 | ✗ |
| 7 | ✗ |
| 8 | ✗ |
| 9 | ✗ |
| 10 | ✗ |
| 11 | ✓ |
| 12 | ✗ |
| 13 | ✓ |
| 14 | ✗ |
| 15 | ✗ |
| 16 | ✗ |
| 17 | ✗ |
| 18 | ✗ |
| 19 | ✗ |
| 20 | ✗ |
| 21 | ✗ |
| 22 | ✗ |
| 23 | ✗ |

| | |
|---|---|
| 24 | ✗ |
| 25 | ✗ |
| 26 | ✓ |
| 27 | ✗ |
| 28 | ✗ |
| 29 | ✗ |
| 30 | ✗ |
| 31 | ✗ |
| 32 | ✓ |
| 33 | ✗ |
| 34 | ✗ |
| 35 | ✗ |
| 36 | ✗ |
| 37 | ✗ |
| 38 | ✗ |
| 39 | ✗ |
| 40 | ✗ |
| 41 | ✗ |
| **42** | ✗ |
| 43 | ✗ |
| 44 | ✓ |
| 45 | ✗ |
| 46 | ✗ |
| 47 | ✓ |
| 48 | ✗ |
| 49 | ✗ |
| 50 | ✗ |

All contents of this site are © 2024 Passmedicine Limited

Back to top

A 34-year-old man attends a dermatology clinic with a rash that isn't improving, the rash is pictured below:

© Image used on license from DermNet NZ

He has recently moved to the area but, for the past 3 months, has been using a clobetasol propionate cream in the morning and calcipotriol in the evening, as recommended by his previous dermatologist.

What would be the most appropriate next treatment step?

- Coal tar applications
- Increase calcipotriol to twice a day
- Increase clobetasol propionate cream to twice daily
- Oral prednisolone
- Switch to potent topical steroids

Submit answer

Reference ranges

Score: **0%**

| | |
|---|---|
| 1 | - |
| 2 | - |
| 3 | - |
| 4 | - |
| 5 | - |
| 6 | - |
| 7 | - |
| 8 | - |
| 9 | - |
| 10 | - |
| 11 | - |
| 12 | - |
| 13 | - |
| 14 | - |
| 15 | - |
| 16 | - |
| 17 | - |
| 18 | - |
| 19 | - |
| 20 | - |
| 21 | - |
| 22 | - |
| 23 | - |
| 24 | - |
| 25 | - |
| 26 | - |
| 27 | - |
| 28 | - |
| 29 | - |
| 30 | - |
| 31 | - |
| 32 | - |
| 33 | - |
| 34 | - |

| | |
|---|---|
| 35 | - |
| 36 | - |
| 37 | - |
| 38 | - |
| 39 | - |
| 40 | - |
| 41 | - |
| 42 | - |
| **43** | - |

All contents of this site are © 2024 Passmedicine Limited

A 34-year-old man attends a dermatology clinic with a rash that isn't improving, the rash is pictured below:

© Image used on license from DermNet NZ

He has recently moved to the area but, for the past 3 months, has been using a clobetasol propionate cream in the morning and calcipotriol in the evening, as recommended by his previous dermatologist.

What would be the most appropriate next treatment step?

| | |
|---|---|
| Coal tar applications | 12% |
| Increase calcipotriol to twice a day | 44% |
| Increase clobetasol propionate cream to twice daily | 19% |
| Oral prednisolone | 7% |
| Switch to potent topical steroids | 18% |

The picture shows the classic extensor surface plaques of psoriasis.

This patient has been using once-a-day calcipotriol for over 8 weeks without resolution of his psoriasis. It is therefore appropriate to escalate his treatment further.

**Increase calcipotriol to twice a day** is the correct answer. It would be appropriate to increase the frequency of applications and re-review in 8 weeks.

**Increase clobetasol propionate cream to twice daily** is incorrect. This is the third-line option and should be considered if the psoriasis rash is not improving after increasing calcipotriol to twice a day.

**Coal tar applications** is incorrect. This could be considered if twice daily calcipotriol has failed, however, many patients prefer topical steroids as coal tar applications can be messy.

**Oral prednisolone** is incorrect. This is not the next step in treatment escalation according to NICE guidelines.

**Switch to potent topical steroids** is incorrect. Clobetasol propionate is already a potent steroid. There is no evidence to suggest that switching to an alternative potent topical steroid is an appropriate option as a second-line treatment for psoriasis.

Discuss (2) | Improve

Next question >

## Psoriasis: management

NICE released guidelines in 2012 on the management of psoriasis and psoriatic arthropathy. Please see the link for more details.

### Chronic plaque psoriasis management

NICE recommend a step-wise approach for chronic plaque psoriasis

- regular emollients may help to reduce scale loss and reduce pruritus
- first-line: NICE recommend:
    - a potent corticosteroid applied once daily plus vitamin D analogue applied once daily
    - should be applied separately, one in the morning and the other in the evening)
    - for up to 4 weeks as initial treatment
- second-line: if no improvement after 8 weeks then offer:
    - a vitamin D analogue twice daily
- third-line: if no improvement after 8-12 weeks then offer either:
    - a potent corticosteroid applied twice daily for up to 4 weeks, or

    - a coal tar preparation applied once or twice daily
- short-acting dithranol can also be used

**Secondary care management**

Phototherapy
- narrowband ultraviolet B light is now the treatment of choice. If possible this should be given 3 times a week
- photochemotherapy is also used - psoralen + ultraviolet A light (PUVA)
- adverse effects: skin ageing, squamous cell cancer (not melanoma)

Systemic therapy
- oral methotrexate is used first-line. It is particularly useful if there is associated joint disease
- ciclosporin
- systemic retinoids
- biological agents: infliximab, etanercept and adalimumab
- ustekinumab (IL-12 and IL-23 blocker) is showing promise in early trials

## Scalp psoriasis management

Outline
- NICE recommend the use of potent topical corticosteroids used once daily for 4 weeks
- if no improvement after 4 weeks then either use a different formulation of the potent corticosteroid (for example, a shampoo or mousse) and/or a topical agents to remove adherent scale (for example, agents containing salicylic acid, emollients and oils) before application of the potent corticosteroid

## Face, flexural and genital psoriasis management

Outline
- NICE recommend offering a mild or moderate potency corticosteroid applied once or twice daily for a maximum of 2 weeks

## Notes on medication

Using topical steroids in psoriasis

- as we know topical corticosteroid therapy may lead to skin atrophy, striae and rebound symptoms
    - the scalp, face and flexures are particularly prone to steroid atrophy so topical steroids should not be used for more than 1-2 weeks/month
- systemic side-effects may be seen when potent corticosteroids are used on large areas e.g. > 10% of the body surface area
- NICE recommend that we aim for a 4-week break before starting another course of topical corticosteroids
- they also recommend using potent corticosteroids for no longer than 8 weeks at a time and very potent corticosteroids for no longer than 4 weeks at a time

Vitamin D analogues

- examples of vitamin D analogues include calcipotriol (Dovonex), calcitriol and tacalcitol
- they work by ↓ cell division and differentiation → ↓ epidermal proliferation
- adverse effects are uncommon
- unlike corticosteroids they may be used long-term
- unlike coal tar and dithranol they do not smell or stain
- they tend to reduce the scale and thickness of plaques but not the erythema
- they should be avoided in pregnancy
- the maximum weekly amount for adults is 100g

© Image used on license from DermNet NZ

A 'before and after' image showing the effect of 6 weeks of calcipotriol therapy on a large plaque. Note how the scale has improved but the erythema remains

Dithranol

- inhibits DNA synthesis
- wash off after 30 mins
- adverse effects include burning, staining

Coal tar

- mechanism of action not fully understood - probably inhibit DNA synthesis

123

Next question

## Textbooks

High-yield textbook

Extended textbook

## Links

SIGN 14 13

2010 Psoriasis guidelines

British Association of Dermatologists 14 11

2017 Guidelines for biologic therapy for psoriasis

NICE 21 16

2012 Psoriasis guidelines

Suggest link

Report broken link

## Media

Psoriasis

Osmosis - YouTube 1 1

Report broken media

Score: **14%**

1 ✗

2 ✗

| | |
|---|---|
| 3 | ✓ |
| 4 | ✗ |
| 5 | ✗ |
| 6 | ✗ |
| 7 | ✗ |
| 8 | ✗ |
| 9 | ✗ |
| 10 | ✗ |
| 11 | ✓ |
| 12 | ✗ |
| 13 | ✓ |
| 14 | ✗ |
| 15 | ✗ |
| 16 | ✗ |
| 17 | ✗ |
| 18 | ✗ |
| 19 | ✗ |
| 20 | ✗ |
| 21 | ✗ |
| 22 | ✗ |
| 23 | ✗ |
| 24 | ✗ |
| 25 | ✗ |
| 26 | ✓ |
| 27 | ✗ |
| 28 | ✗ |
| 29 | ✗ |
| 30 | ✗ |
| 31 | ✗ |
| 32 | ✓ |
| 33 | ✗ |
| 34 | ✗ |
| 35 | ✗ |
| 36 | ✗ |
| 37 | ✗ |
| 38 | ✗ |

39 ✗
40 ✗
41 ✗
42 ✗
**43** ✗
44 ✓
45 ✗
46 ✗
47 ✓
48 ✗
49 ✗
50 ✗

All contents of this site are © 2024 Passmedicine Limited

Back to top

A 27-year-old man is referred to clinic with an intensely pruritic rash on both his forearms and buttocks.

The rash started around one month ago as papules and vesicles that were very itchy. Once scratched they would quickly crust over. Older lesions would leave pale and dark patches after the crusting had healed over. He had tried multiple emollients and creams including over the counter hydrocortisone cream which had not helped.

He has a history of intermittent abdominal bloating, nausea and diarrhoea which he diagnosed as irritable bowel syndrome (IBS) after reading about it on the internet. Despite trying to adjust his diet, his symptoms are ongoing. He is otherwise fit and well.

Of note in his family history, his mother has a history of hypothyroidism and diabetes.

He currently manages his IBS with diet and takes no regular medication.

On examination he is thin but well. Physical observations are all within normal ranges. There are multiple crops of vesicles and papules over the extensor aspects of both his forearms and over his buttocks with evidence of excoriation, erythema and crusting.

Cardiorespiratory, abdominal and neurological examinations are all unremarkable.

Bloods come back as:

| | |
|---|---|
| Na+ | 140 mmol/L |
| K+ | 3.7 mmol/L |
| Urea | 4.0 mmol/L |
| Creatinine | 68 µmol/L |
| Hb | 98.0 g/dL |
| MCV | 94 fL |
| WBC | 6.5x10^9/L |
| Platelets | 200x10^9/L |
| Serum folate | 1.1 mcg/L |
| Serum B12 | 160 ng/L |
| Ferritin | 10 g/L |

In view of the likely diagnosis, what is the most appropriate initial treatment?

- Reassurance
- Oral steroids
- Potent topical steroids
- Oral acyclovir
- Dapsone

Submit answer

Reference ranges

Score: **0%**

1 -
2 -
3 -
4 -
5 -
6 -
7 -
8 -
9 -
10 -
11 -
12 -
13 -
14 -
15 -
16 -
17 -

18 -
19 -
20 -
21 -
22 -
23 -
24 -
25 -
26 -
27 -
28 -
29 -
30 -
31 -
32 -
33 -
34 -
35 -
36 -
37 -
38 -
39 -
40 -
41 -
42 -
43 -
**44** -

All contents of this site are © 2024 Passmedicine Limited
Back to top

A 27-year-old man is referred to clinic with an intensely pruritic rash on both his forearms and buttocks.

The rash started around one month ago as papules and vesicles that were very itchy. Once scratched they would quickly crust over. Older lesions would leave pale and dark patches after the crusting had healed over. He had tried multiple emollients and creams including over the counter hydrocortisone cream which had not helped.

He has a history of intermittent abdominal bloating, nausea and diarrhoea which he diagnosed as irritable bowel syndrome (IBS) after reading about it on the internet. Despite trying to adjust his diet, his symptoms are ongoing. He is otherwise fit and well.

Of note in his family history, his mother has a history of hypothyroidism and diabetes.

He currently manages his IBS with diet and takes no regular medication.

On examination he is thin but well. Physical observations are all within normal ranges. There are multiple crops of vesicles and papules over the extensor aspects of both his forearms and over his buttocks with evidence of excoriation, erythema and crusting.

Cardiorespiratory, abdominal and neurological examinations are all unremarkable.

Bloods come back as:

| | |
|---|---|
| Na+ | 140 mmol/L |
| K+ | 3.7 mmol/L |
| Urea | 4.0 mmol/L |
| Creatinine | 68 µmol/L |
| Hb | 98.0 g/dL |
| MCV | 94 fL |
| WBC | 6.5x10^9/L |
| Platelets | 200x10^9/L |
| Serum folate | 1.1 mcg/L |
| Serum B12 | 160 ng/L |
| Ferritin | 10 g/L |

In view of the likely diagnosis, what is the most appropriate initial treatment?

| | |
|---|---|
| Reassurance | 4% |
| Oral steroids | 5% |
| Potent topical steroids | 7% |
| Oral acyclovir | 1% |
| Dapsone | 83% |

Dermatitis herpetiformis is typically treated with a gluten-free diet and topical dapsone
Important for me Less important

This patient has a rash suggestive of dermatitis herpetiformis characterised by highly pruritic vesicles and papules on extensor surfaces and buttocks. The self-diagnosis of IBS is likely to be incorrect. In view of the low folate and low ferritin (suggestive of malabsorption) an underlying diagnosis of coeliac disease is most likely here.

Dermatitis herpetiformis responds very well to dapsone with relief of itch within a few days. Oral and potent steroids are used second line in patient intolerant or with contraindications to dapsone.

Aciclovir can be used in severe forms of herpes zoster which doesn't fit with this clinical picture.

Reassurance is wrong as this condition is unlikely to get better without treatment.

In the long term this patient would need further investigation to confirm the diagnosis of coeliac disease and start a gluten-free diet.

Discuss (3) Improve

Next question

## Dermatitis herpetiformis

Dermatitis herpetiformis is an autoimmune blistering skin disorder associated with coeliac disease. It is caused by deposition of IgA in the dermis. More than 90% of patients exhibit small bowel biopsy findings consistent with some degree of gluten-sensitive enteropathy.

Features

- itchy, vesicular skin lesions on the extensor surfaces (e.g. elbows, knees, buttocks)

Diagnosis

- skin biopsy: direct immunofluorescence shows deposition of IgA in a granular pattern in the upper dermis

Management

- gluten-free diet
- dapsone

123

Next question

Textbooks

High-yield textbook

Extended textbook

**Links**

DermNet NZ 👍 34 👎 6

Dermatitis herpetiformis

Suggest link    Report broken link

Score: **14%**

| | |
|---|---|
| 1 | ✗ |
| 2 | ✗ |
| 3 | ✓ |
| 4 | ✗ |
| 5 | ✗ |
| 6 | ✗ |
| 7 | ✗ |
| 8 | ✗ |
| 9 | ✗ |
| 10 | ✗ |
| 11 | ✓ |
| 12 | ✗ |
| 13 | ✓ |
| 14 | ✗ |
| 15 | ✗ |
| 16 | ✗ |
| 17 | ✗ |
| 18 | ✗ |
| 19 | ✗ |
| 20 | ✗ |
| 21 | ✗ |
| 22 | ✗ |
| 23 | ✗ |
| 24 | ✗ |
| 25 | ✗ |

| | |
|---|---|
| 26 | ✓ |
| 27 | ✗ |
| 28 | ✗ |
| 29 | ✗ |
| 30 | ✗ |
| 31 | ✗ |
| 32 | ✓ |
| 33 | ✗ |
| 34 | ✗ |
| 35 | ✗ |
| 36 | ✗ |
| 37 | ✗ |
| 38 | ✗ |
| 39 | ✗ |
| 40 | ✗ |
| 41 | ✗ |
| 42 | ✗ |
| 43 | ✗ |
| **44** | ✓ |
| 45 | ✗ |
| 46 | ✗ |
| 47 | ✓ |
| 48 | ✗ |
| 49 | ✗ |
| 50 | ✗ |

All contents of this site are © 2024 Passmedicine Limited

Back to top

A 25-year-old Caucasian male presents with his first ever episode of witnessed generalised seizure, with witnessed jerking of his right arm and leg, lasting for 4 minutes terminated by benzodiazepines administered by paramedics. There is no other past medical history and documentation of head injuries. His past medical history includes recurrent epistaxes since childhood and current treatment for a left calf deep vein thrombosis provoked following two recent long-haul flights from Australia. A thrombophilia screen has subsequently been negative. Family history is unavailable.

On examination, the patient is confused postictally and is uncooperative with the examination. You note that his pupils are equal and reactive, he is moving all 4 limbs with no obvious focal neurology. There appears to be no visual or sensory neglect. A urinary toxicology screen is negative.

His blood tests and arterial blood gas are as follows:

| | |
|---|---|
| Hb | 175 g/l |
| MCV | 87 fl |
| Platelets | 223 * $10^9$/l |
| WBC | 9.2 * $10^9$/l |
| Urea | 6.6 mmol/l |
| Creatinine | 64 µmol/l |
| CRP | 24 mg/l |

| | |
|---|---|
| pH | 7.32 |
| PaO2 | 9.1 kPa |
| PaCO2 | 4.2 kPa |
| Lactate | 4.2 mmol/l |
| Bicarbonate | 16 mmol/l |

With sedation, the patient undergoes a CT head, which demonstrates an arterio-venous fistula in his right parietal lobe.

The patient remains an inpatient while discussed for management with neurosurgeons and returns to baseline with no focal neurological deficits. At 48 hours after admission, he develops sudden onset left face, arm and leg weakness and loss of sensation, with flaccid tone, downgoing plantars.

A repeat CT head confirms a right middle cerebral artery ischaemic stroke.

What is the unifying diagnosis?

- Malignancy of unclear primary
- Haemorrhagic hereditary telangiectasia
- Saddle pulmonary embolus
- Polycythaemia rubra vera
- Paroxysmal nocturnal haemoglobinuria

Submit answer

Reference ranges

Score: **0%**

1 -
2 -
3 -
4 -
5 -
6 -
7 -
8 -
9 -
10 -
11 -
12 -
13 -
14 -
15 -
16 -

17 -
18 -
19 -
20 -
21 -
22 -
23 -
24 -
25 -
26 -
27 -
28 -
29 -
30 -
31 -
32 -
33 -
34 -
35 -
36 -
37 -
38 -
39 -
40 -
41 -
42 -
43 -
44 -
**45** -

All contents of this site are © 2024 Passmedicine Limited
Back to top

A 25-year-old Caucasian male presents with his first ever episode of witnessed generalised seizure, with witnessed jerking of his right arm and leg, lasting for 4 minutes terminated by benzodiazepines administered by paramedics. There is no other past medical history and documentation of head injuries. His past medical history includes recurrent epistaxes since childhood and current treatment for a left calf deep vein thrombosis provoked following two recent long-haul flights from Australia. A thrombophilia screen has subsequently been negative. Family history is unavailable.

On examination, the patient is confused postictally and is uncooperative with the examination. You note that his pupils are equal and reactive, he is moving all 4 limbs with no obvious focal neurology. There appears to be no visual or sensory neglect. A urinary toxicology screen is negative.

His blood tests and arterial blood gas are as follows:

| | |
|---|---|
| Hb | 175 g/l |
| MCV | 87 fl |
| Platelets | 223 * $10^9$/l |
| WBC | 9.2 * $10^9$/l |
| Urea | 6.6 mmol/l |
| Creatinine | 64 µmol/l |
| CRP | 24 mg/l |

| | |
|---|---|
| pH | 7.32 |
| PaO2 | 9.1 kPa |
| PaCO2 | 4.2 kPa |
| Lactate | 4.2 mmol/l |
| Bicarbonate | 16 mmol/l |

With sedation, the patient undergoes a CT head, which demonstrates an arterio-venous fistula in his right parietal lobe.

The patient remains an inpatient while discussed for management with neurosurgeons and returns to baseline with no focal neurological deficits. At 48 hours after admission, he develops sudden onset left face, arm and leg weakness and loss of sensation, with flaccid tone, downgoing plantars.

A repeat CT head confirms a right middle cerebral artery ischaemic stroke.

What is the unifying diagnosis?

| | |
|---|---|
| Malignancy of unclear primary | 1% |
| Haemorrhagic hereditary telangiectasia | 76% |
| Saddle pulmonary embolus | 2% |
| Polycythaemia rubra vera | 16% |
| Paroxysmal nocturnal haemoglobinuria | 5% |

This is a difficult question: the patient has an intracerebral arterio-venous fistula and likely at least another in his pulmonary vasculature, resulting in a chronic hypoxaemia (note normal bicarbonate and secondary polycythaemia), ruling out an acute pulmonary embolus and likely resulting in a paradoxical stroke. Primary polycythaemia rubra vera should not result in hypoxaemia. There does not appear to be an underlying prothrombotic element: his current DVT is uncommon but appears provoked with a negative thrombophilia. There is little to suggest malignancy.

A previous history of epistaxis is also suggestive of haemorrhagic hereditary telangiectasia (HHT), which appears to be the most common and earliest clinical feature. Diagnosis is clinched by the consensus Curacao criteria, requiring the following 4 features to be investigated in this case: spontaneous or recurrent epistaxis, multiple cutaneous telangiectasia (a full dermatological examination is essential), visceral involvement (in this case, pulmonary and cerebral AVMs) and a first-degree relative with HHT (family history is required). Meeting at least 3 features produces a definite diagnosis while 2 of 4 features suggests 'suspected' diagnosis.

Discuss (15) | Improve

Next question

## Hereditary haemorrhagic telangiectasia

Also known as Osler-Weber-Rendu syndrome, hereditary haemorrhagic telangiectasia (HHT) is an autosomal dominant condition characterised by (as the name suggests) multiple telangiectasia over the skin and mucous membranes. Twenty percent of cases occur spontaneously without prior family history.

There are 4 main diagnostic criteria. If the patient has 2 then they are said to have a possible diagnosis of HHT. If they meet 3 or more of the criteria they are said to have a definite diagnosis of HHT:

- epistaxis : spontaneous, recurrent nosebleeds
- telangiectases: multiple at characteristic sites (lips, oral cavity, fingers, nose)
- visceral lesions: for example gastrointestinal telangiectasia (with or without bleeding), pulmonary arteriovenous malformations (AVM), hepatic AVM, cerebral AVM, spinal AVM
- family history: a first-degree relative with HHT

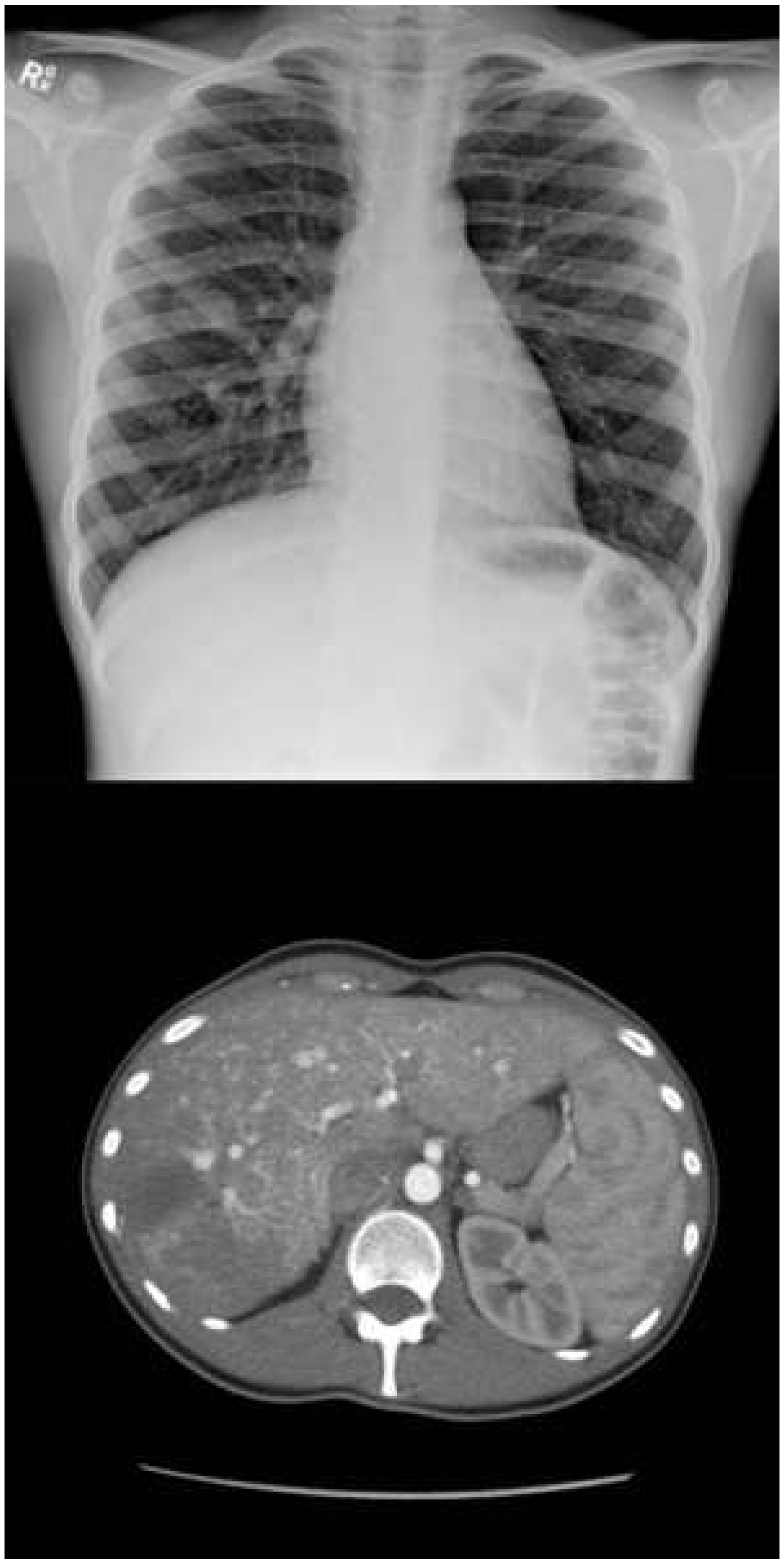

© Image used on license from Radiopaedia

The chest x-ray shows multiple pulmonary nodules representing arteriovenous malformations, the largest in the right mid-zone. The CT scan shows multiple hepatic arteriovenous malformations

+ Q 123

Next question >

## Textbooks

High-yield textbook

Extended textbook

## Links

DermNet NZ 5 6

Hereditary haemorrhagic telangiectasia

Postgraduate Medical Journal 5 1

Review of HHT

Suggest link Report broken link

Score: **14%**

1 ✗
2 ✗
3 ✓
4 ✗
5 ✗
6 ✗
7 ✗
8 ✗
9 ✗

| | |
|---|---|
| 10 | ✗ |
| 11 | ✓ |
| 12 | ✗ |
| 13 | ✓ |
| 14 | ✗ |
| 15 | ✗ |
| 16 | ✗ |
| 17 | ✗ |
| 18 | ✗ |
| 19 | ✗ |
| 20 | ✗ |
| 21 | ✗ |
| 22 | ✗ |
| 23 | ✗ |
| 24 | ✗ |
| 25 | ✗ |
| 26 | ✓ |
| 27 | ✗ |
| 28 | ✗ |
| 29 | ✗ |
| 30 | ✗ |
| 31 | ✗ |
| 32 | ✓ |
| 33 | ✗ |
| 34 | ✗ |
| 35 | ✗ |
| 36 | ✗ |
| 37 | ✗ |
| 38 | ✗ |
| 39 | ✗ |
| 40 | ✗ |
| 41 | ✗ |
| 42 | ✗ |
| 43 | ✗ |
| 44 | ✓ |
| **45** | ✗ |

| | |
|---|---|
| 46 | ✗ |
| 47 | ✓ |
| 48 | ✗ |
| 49 | ✗ |
| 50 | ✗ |

All contents of this site are © 2024 Passmedicine Limited

A 2-year-old girl develops a rash on her legs. The following day she is brought to the Emergency Department by which time the rash has spread to the rest of her body.

© Image used on license from DermNet NZ

What is the most likely diagnosis?

- Erythema multiforme
- Erythema chronica migrans
- Erythema nodosum
- Urticaria
- Dermatitis artefacta

Submit answer

Reference ranges

Score: **0%**

1 -
2 -
3 -
4 -
5 -
6 -
7 -
8 -
9 -
10 -
11 -
12 -
13 -
14 -
15 -
16 -
17 -
18 -
19 -
20 -
21 -
22 -
23 -
24 -
25 -
26 -
27 -
28 -
29 -
30 -
31 -
32 -
33 -
34 -
35 -
36 -
37 -

| | |
|---|---|
| 38 | - |
| 39 | - |
| 40 | - |
| 41 | - |
| 42 | - |
| 43 | - |
| 44 | - |
| 45 | - |
| **46** | - |

All contents of this site are © 2024 Passmedicine Limited

A 2-year-old girl develops a rash on her legs. The following day she is brought to the Emergency Department by which time the rash has spread to the rest of her body.

© Image used on license from DermNet NZ

What is the most likely diagnosis?

| | |
|---|---|
| Erythema multiforme | 86% |
| Erythema chronica migrans | 4% |
| Erythema nodosum | 2% |
| Urticaria | 8% |
| Dermatitis artefacta | 1% |

The classic 'target' lesions of erythema multiforme can be seen clearly on this image.

Discuss (2) Improve

Next question

# Erythema multiforme

Erythema multiforme is a hypersensitivity reaction that is most commonly triggered by infections. It may be divided into minor and major forms.

Previously it was thought that Stevens-Johnson syndrome (SJS) was a severe form of erythema multiforme. They are now however considered as separate entities.

Features

- target lesions
- initially seen on the back of the hands / feet before spreading to the torso
- upper limbs are more commonly affected than the lower limbs
- pruritus is occasionally seen and is usually mild

Causes

- viruses: herpes simplex virus (the most common cause), Orf*
- idiopathic
- bacteria: *Mycoplasma*, *Streptococcus*
- drugs: penicillin, sulphonamides, carbamazepine, allopurinol, NSAIDs, oral contraceptive pill, nevirapine
- connective tissue disease e.g. Systemic lupus erythematosus
- sarcoidosis
- malignancy

## Erythema multiforme major

The more severe form, erythema multiforme major is associated with mucosal involvement.

*Orf is a skin disease of sheep and goats caused by a parapox virus

123

Next question

## Textbooks

High-yield textbook

Extended textbook

## Links

DermNet NZ 18 10

Erythema multiforme

Suggest link Report broken link

## Media

Erythema multiforme

Osmosis - YouTube 1 0

Report broken media

Score: **14%**

| | |
|---|---|
| 1 | ✗ |
| 2 | ✗ |
| 3 | ✓ |
| 4 | ✗ |
| 5 | ✗ |
| 6 | ✗ |
| 7 | ✗ |
| 8 | ✗ |
| 9 | ✗ |
| 10 | ✗ |
| 11 | ✓ |
| 12 | ✗ |
| 13 | ✓ |
| 14 | ✗ |
| 15 | ✗ |
| 16 | ✗ |
| 17 | ✗ |
| 18 | ✗ |
| 19 | ✗ |
| 20 | ✗ |
| 21 | ✗ |
| 22 | ✗ |
| 23 | ✗ |

| | |
|---|---|
| 24 | ✗ |
| 25 | ✗ |
| 26 | ✓ |
| 27 | ✗ |
| 28 | ✗ |
| 29 | ✗ |
| 30 | ✗ |
| 31 | ✗ |
| 32 | ✓ |
| 33 | ✗ |
| 34 | ✗ |
| 35 | ✗ |
| 36 | ✗ |
| 37 | ✗ |
| 38 | ✗ |
| 39 | ✗ |
| 40 | ✗ |
| 41 | ✗ |
| 42 | ✗ |
| 43 | ✗ |
| 44 | ✓ |
| 45 | ✗ |
| **46** | ✗ |
| 47 | ✓ |
| 48 | ✗ |
| 49 | ✗ |
| 50 | ✗ |

All contents of this site are © 2024 Passmedicine Limited

Back to top

A woman who is 24 weeks pregnant presents with a rash:

© Image used on license from DermNet NZ

What is the most likely diagnosis?

- Pityriasis rosea
- Pompholyx
- Primary herpes simplex infection
- Polymorphic eruption of pregnancy
- Pemphigoid gestationis

Submit answer

Reference ranges

Score: **0%**

| | |
|---|---|
| 1 | - |
| 2 | - |
| 3 | - |
| 4 | - |
| 5 | - |
| 6 | - |
| 7 | - |
| 8 | - |
| 9 | - |
| 10 | - |
| 11 | - |
| 12 | - |
| 13 | - |
| 14 | - |
| 15 | - |
| 16 | - |
| 17 | - |
| 18 | - |
| 19 | - |
| 20 | - |
| 21 | - |
| 22 | - |
| 23 | - |
| 24 | - |
| 25 | - |
| 26 | - |
| 27 | - |
| 28 | - |
| 29 | - |
| 30 | - |
| 31 | - |
| 32 | - |
| 33 | - |
| 34 | - |
| 35 | - |
| 36 | - |
| 37 | - |
| 38 | - |

39 -
40 -
41 -
42 -
43 -
44 -
45 -
46 -
**47** -

All contents of this site are © 2024 Passmedicine Limited

A woman who is 24 weeks pregnant presents with a rash:

© Image used on license from DermNet NZ

What is the most likely diagnosis?

| | |
|---|---|
| Pityriasis rosea | 2% |
| Pompholyx | 2% |
| Primary herpes simplex infection | 2% |
| Polymorphic eruption of pregnancy | 38% |
| Pemphigoid gestationis | 56% |

The blistering lesions are clearly visible on this image.

Discuss (1) Improve

Next question

# Skin disorders associated with pregnancy

Atopic eruption of pregnancy

- is the commonest skin disorder found in pregnancy
- it typically presents as an eczematous, itchy red rash.
- no specific treatment is needed

Polymorphic eruption of pregnancy

- pruritic condition associated with last trimester
- lesions often first appear in abdominal striae
- management depends on severity: emollients, mild potency topical steroids and oral steroids may be used

© Image used on license from DermNet NZ

Polymorphic eruption of pregnancy

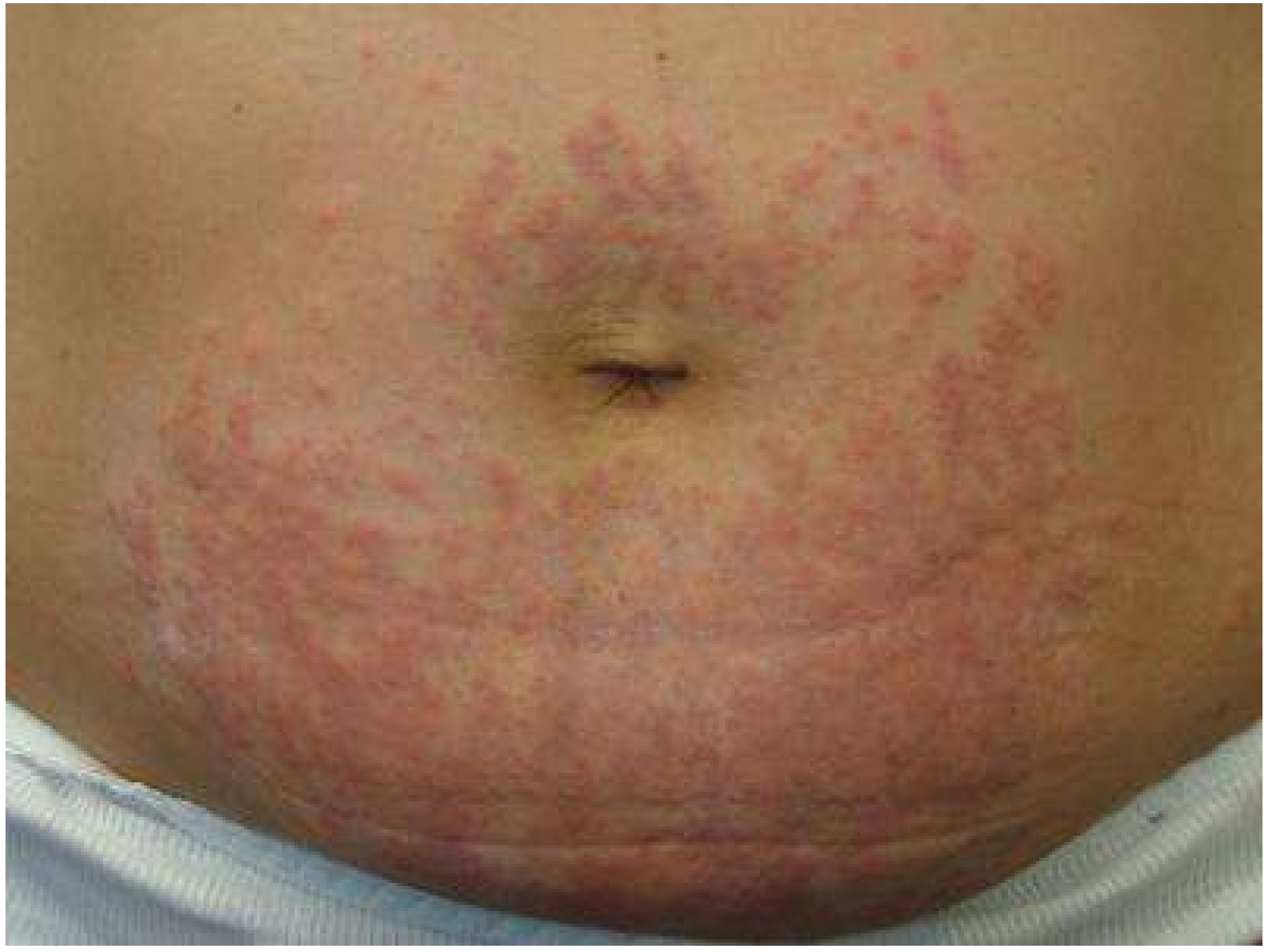

© Image used on license from DermNet NZ

Polymorphic eruption of pregnancy

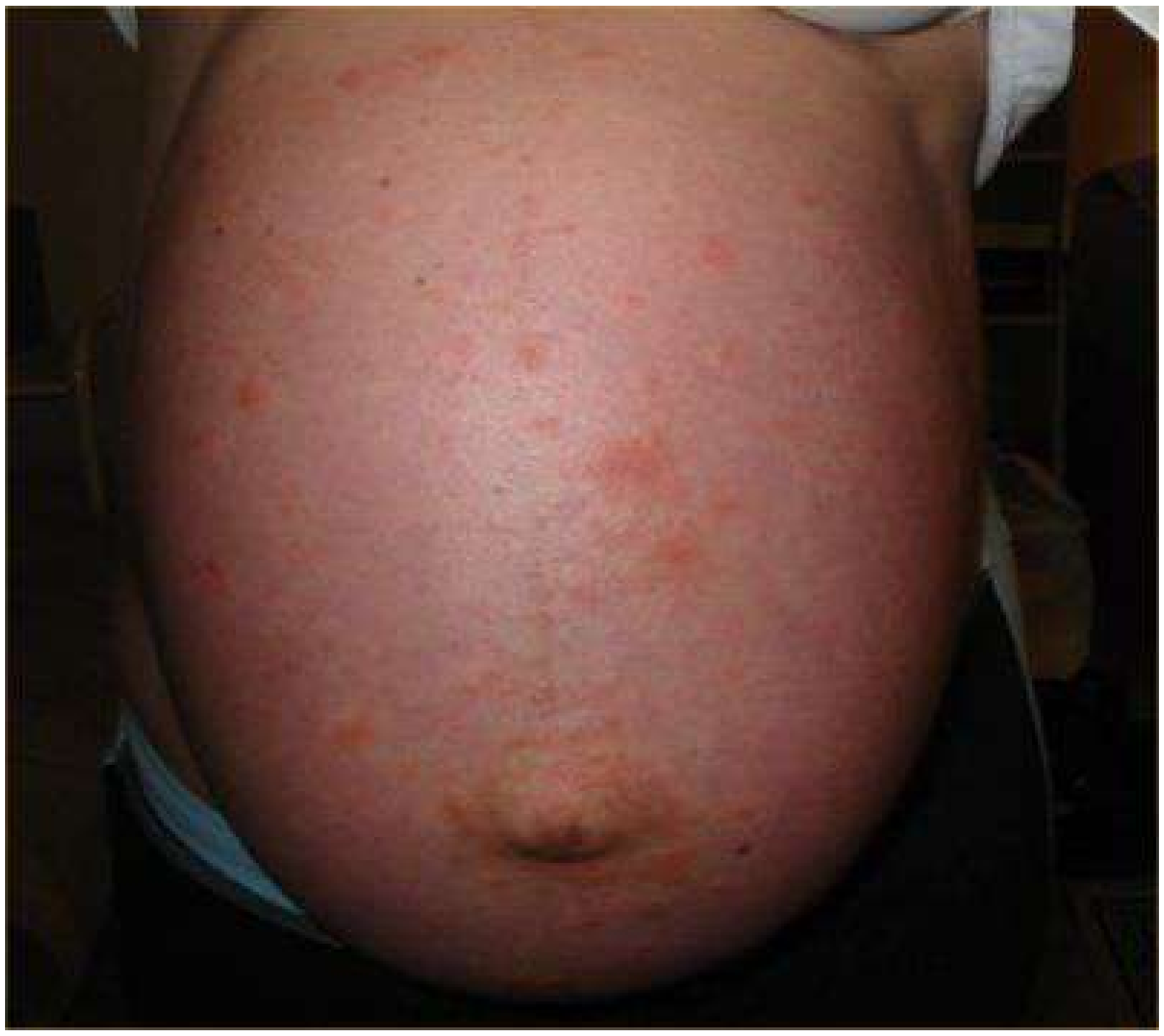

Polymorphic eruption of pregnancy

Pemphigoid gestationis

- pruritic blistering lesions
- often develop in peri-umbilical region, later spreading to the trunk, back, buttocks and arms
- usually presents 2nd or 3rd trimester and is rarely seen in the first pregnancy
- oral corticosteroids are usually required

© Image used on license from DermNet NZ

Pemphigoid gestationis

© Image used on license from DermNet NZ

Pemphigoid gestationis

123

Next question

## Textbooks

High-yield textbook

Extended textbook

## Links

DermNet NZ 👍 13 👎 5

Pemphigoid gestationis

DermNet NZ 👍 11 👎 4

Polymorphic eruption of pregnancy

Suggest link Report broken link

Score: **14%**

1 ✗
2 ✗
3 ✓
4 ✗
5 ✗
6 ✗
7 ✗
8 ✗
9 ✗
10 ✗
11 ✓
12 ✗
13 ✓
14 ✗
15 ✗

| | |
|---|---|
| 16 | ✗ |
| 17 | ✗ |
| 18 | ✗ |
| 19 | ✗ |
| 20 | ✗ |
| 21 | ✗ |
| 22 | ✗ |
| 23 | ✗ |
| 24 | ✗ |
| 25 | ✗ |
| 26 | ✓ |
| 27 | ✗ |
| 28 | ✗ |
| 29 | ✗ |
| 30 | ✗ |
| 31 | ✗ |
| 32 | ✓ |
| 33 | ✗ |
| 34 | ✗ |
| 35 | ✗ |
| 36 | ✗ |
| 37 | ✗ |
| 38 | ✗ |
| 39 | ✗ |
| 40 | ✗ |
| 41 | ✗ |
| 42 | ✗ |
| 43 | ✗ |
| 44 | ✓ |
| 45 | ✗ |
| 46 | ✗ |
| **47** | ✓ |
| 48 | ✗ |
| 49 | ✗ |
| 50 | ✗ |

All contents of this site are © 2024 Passmedicine Limited 

A 34-year-old who has recently returned from a business trip to New York presents with a one-day history of a painful rash on his neck:

What is the most appropriate management?

- Topical fusidic acid
- Topical clotrimazole + hydrocortisone
- Oral aciclovir + prednisolone
- Oral aciclovir
- Send blood for antibodies to *Borrelia burgdorferi*

Submit answer

Reference ranges

Score: **0%**

| | |
|---|---|
| 1 | - |
| 2 | - |
| 3 | - |
| 4 | - |
| 5 | - |
| 6 | - |
| 7 | - |
| 8 | - |
| 9 | - |
| 10 | - |
| 11 | - |
| 12 | - |
| 13 | - |
| 14 | - |
| 15 | - |
| 16 | - |
| 17 | - |
| 18 | - |
| 19 | - |
| 20 | - |
| 21 | - |
| 22 | - |
| 23 | - |
| 24 | - |
| 25 | - |
| 26 | - |
| 27 | - |
| 28 | - |
| 29 | - |
| 30 | - |
| 31 | - |
| 32 | - |
| 33 | - |
| 34 | - |

| | |
|---|---|
| 35 | - |
| 36 | - |
| 37 | - |
| 38 | - |
| 39 | - |
| 40 | - |
| 41 | - |
| 42 | - |
| 43 | - |
| 44 | - |
| 45 | - |
| 46 | - |
| 47 | - |
| **48** | - |

All contents of this site are © 2024 Passmedicine Limited
Back to top

A 34-year-old who has recently returned from a business trip to New York presents with a one-day history of a painful rash on his neck:

What is the most appropriate management?

- Topical fusidic acid 11%
- Topical clotrimazole + hydrocortisone 6%
- Oral aciclovir + prednisolone 17%
- Oral aciclovir 62%
- Send blood for antibodies to *Borrelia burgdorferi* 4%

One of the main clues in the question is the combination of a rash with pain. Other than shingles, there are not many conditions which cause both.

Whilst there is some evidence that systemic steroids speed up the healing of shingles, consensus guidelines do not advocate their use as adverse effects probably outweigh potential benefits.

# Varicella-zoster vaccination

Varicella-zoster is the herpes virus that causes chickenpox. Shingles is an acute, unilateral, painful blistering rash caused by reactivation of the varicella-zoster virus (VZV).

There are two types of varicella-zoster vaccine:
- a vaccine that stops you from developing primary varicella infection (chickenpox)
- a vaccine that reduces the incidence of herpes zoster (shingles) caused by reactivation of VZV

## Vaccination against primary varicella infection (chickenpox)

This is a live attenuated vaccine. Examples include *Varilrix* and *Varivax*.

Example indications include:
- healthcare workers who are not already immune to VZV
- contacts of immunocompromised patients (e.g. child whose parent is undergoing chemotherapy)

## The 'shingles vaccine'

In 2013 the NHS introduced a vaccine to boost the immunity of elderly people against herpes zoster. Some important points about the vaccine:
- offered to all patients aged 70-79 years*
- is live-attenuated and given sub-cutaneously
- examples include *Zostavax*

As it is a live-attenuated vaccine the main contraindications are immunosuppression.

Side-effects
- injection site reactions
- less than 1 in 10,000 individuals will develop chickenpox

*there is also a catch up campaign. The following is taken from the NHS vaccination website:

*Anyone aged 70 can have the shingles vaccine on the NHS. You become eligible for the vaccine from the first day of September after your 70th birthday.*

*From September 1 2015, the shingles vaccine will be offered routinely to people aged 70 and, as a catch up, to those aged 78. You become eligible for the vaccine on the first day of September 2015 after you've turned 70 or 78.*

*In addition, anyone who was eligible for immunisation in the previous two years of the programme but missed out on their vaccinations remains eligible until their 80th birthday. This includes:*

- *people aged 71 and 72 on 1 September 2015*
- *people aged 79*

*The shingles vaccine is not available on the NHS to anyone aged 80 and over because it seems to be less effective in this age group.*

+ Q 123

Next question

## Textbooks

High-yield textbook

Extended textbook

## Links

Clinical Knowledge Summaries 7 6

Shingles guidelines

Suggest link Report broken link

## Media

Varicella zoster virus

Osmosis - YouTube 1 0

Report broken media

Score: **14%**

1 ✗
2 ✗
3 ✓
4 ✗
5 ✗
6 ✗
7 ✗
8 ✗
9 ✗
10 ✗
11 ✓
12 ✗
13 ✓
14 ✗
15 ✗
16 ✗
17 ✗

| | |
|---|---|
| 18 | ✗ |
| 19 | ✗ |
| 20 | ✗ |
| 21 | ✗ |
| 22 | ✗ |
| 23 | ✗ |
| 24 | ✗ |
| 25 | ✗ |
| 26 | ✓ |
| 27 | ✗ |
| 28 | ✗ |
| 29 | ✗ |
| 30 | ✗ |
| 31 | ✗ |
| 32 | ✓ |
| 33 | ✗ |
| 34 | ✗ |
| 35 | ✗ |
| 36 | ✗ |
| 37 | ✗ |
| 38 | ✗ |
| 39 | ✗ |
| 40 | ✗ |
| 41 | ✗ |
| 42 | ✗ |
| 43 | ✗ |
| 44 | ✓ |
| 45 | ✗ |
| 46 | ✗ |
| 47 | ✓ |
| **48** | ✗ |
| 49 | ✗ |
| 50 | ✗ |

All contents of this site are © 2024 Passmedicine Limited

Back to top

A 34-year-old man presents with a three week history of an intensely itchy rash just below his knees. On examination he has a symmetrical vesicular rash as shown below and also some early lesions on the back of his arms.

© Image used on license from DermNet NZ and with the kind permission of Prof Raimo Suhonen

Which one of the following antibodies is most likely to be positive?

- Anti-mitochondrial antibody
- Anti-tissue transglutaminase antibody
- Anti-nuclear antibody
- Anti-neutrophil cytoplasmic antibody
- Anti-Jo-1 antibody

Submit answer

Reference ranges

Score: **0%**

| | |
|---|---|
| 1 | - |
| 2 | - |
| 3 | - |
| 4 | - |
| 5 | - |
| 6 | - |
| 7 | - |
| 8 | - |
| 9 | - |
| 10 | - |
| 11 | - |
| 12 | - |
| 13 | - |
| 14 | - |
| 15 | - |
| 16 | - |
| 17 | - |
| 18 | - |
| 19 | - |
| 20 | - |
| 21 | - |
| 22 | - |
| 23 | - |
| 24 | - |
| 25 | - |
| 26 | - |
| 27 | - |
| 28 | - |
| 29 | - |
| 30 | - |
| 31 | - |
| 32 | - |
| 33 | - |
| 34 | - |
| 35 | - |
| 36 | - |
| 37 | - |
| 38 | - |

39 -
40 -
41 -
42 -
43 -
44 -
45 -
46 -
47 -
48 -
49 -

All contents of this site are © 2024 Passmedicine Limited

A 34-year-old man presents with a three week history of an intensely itchy rash just below his knees. On examination he has a symmetrical vesicular rash as shown below and also some early lesions on the back of his arms.

© Image used on license from DermNet NZ and with the kind permission of Prof Raimo Suhonen

Which one of the following antibodies is most likely to be positive?

- Anti-mitochondrial antibody 1%
- Anti-tissue transglutaminase antibody 94%
- Anti-nuclear antibody 3%
- Anti-neutrophil cytoplasmic antibody 1%
- Anti-Jo-1 antibody 1%

The correct answer in this case is **Anti-tissue transglutaminase antibody**. This patient's presentation of an intensely itchy, symmetrical vesicular rash on the knees and back of arms is highly suggestive of dermatitis herpetiformis. Dermatitis herpetiformis is an autoimmune skin condition associated with coeliac disease, and it often presents as a pruritic, blistering rash on extensor surfaces such as the elbows, knees, and buttocks. The presence of anti-tissue transglutaminase antibodies confirms the diagnosis as these antibodies are commonly found in

patients with coeliac disease.

**Anti-mitochondrial antibody** is incorrect because these antibodies are typically associated with primary biliary cholangitis (PBC), a chronic liver disease characterised by destruction of intrahepatic bile ducts. PBC usually presents with fatigue, pruritus, and jaundice rather than a vesicular rash.

**Anti-nuclear antibody** (ANA) is also incorrect because ANAs are generally associated with systemic autoimmune diseases such as systemic lupus erythematosus (SLE) or Sjogren's syndrome. Although these conditions can present with skin manifestations like rashes, they do not typically present with the characteristic vesicular rash seen in dermatitis herpetiformis.

**Anti-neutrophil cytoplasmic antibody** (ANCA) is not correct either because ANCAs are primarily associated with vasculitides like granulomatosis with polyangiitis (GPA), microscopic polyangiitis (MPA), and eosinophilic granulomatosis with polyangiitis (EGPA). These conditions can have cutaneous manifestations like purpura or nodules but not the specific vesicular rash seen in this patient.

Lastly, **Anti-Jo-1 antibody** is incorrect because Anti-Jo-1 antibodies are associated with idiopathic inflammatory myopathies, particularly polymyositis and dermatomyositis. While dermatomyositis does present with skin manifestations like a heliotrope rash or Gottron's papules, these are distinct from the vesicular rash seen in dermatitis herpetiformis.

In summary, the presence of **Anti-tissue transglutaminase antibody** is most likely in this patient due to the characteristic presentation of dermatitis herpetiformis, which is associated with coeliac disease.

Discuss | Improve

Next question >

## Dermatitis herpetiformis

Dermatitis herpetiformis is an autoimmune blistering skin disorder associated with coeliac disease. It is caused by deposition of IgA in the dermis. More than 90% of patients exhibit small bowel biopsy findings consistent with some degree of gluten-sensitive enteropathy.

Features

- itchy, vesicular skin lesions on the extensor surfaces (e.g. elbows, knees, buttocks)

Diagnosis

- skin biopsy: direct immunofluorescence shows deposition of IgA in a granular pattern in the upper dermis

Management

- gluten-free diet
- dapsone

123

Next question >

## Textbooks

High-yield textbook

Extended textbook

## Links

DermNet NZ 34 6

Dermatitis herpetiformis

Suggest link Report broken link

Score: **14%**

| | |
|---|---|
| 1 | ✗ |
| 2 | ✗ |
| 3 | ✓ |
| 4 | ✗ |
| 5 | ✗ |
| 6 | ✗ |
| 7 | ✗ |
| 8 | ✗ |
| 9 | ✗ |
| 10 | ✗ |
| 11 | ✓ |
| 12 | ✗ |
| 13 | ✓ |
| 14 | ✗ |
| 15 | ✗ |
| 16 | ✗ |
| 17 | ✗ |
| 18 | ✗ |
| 19 | ✗ |
| 20 | ✗ |
| 21 | ✗ |
| 22 | ✗ |
| 23 | ✗ |
| 24 | ✗ |
| 25 | ✗ |
| 26 | ✓ |
| 27 | ✗ |
| 28 | ✗ |
| 29 | ✗ |
| 30 | ✗ |
| 31 | ✗ |
| 32 | ✓ |

| | |
|---|---|
| 33 | ✗ |
| 34 | ✗ |
| 35 | ✗ |
| 36 | ✗ |
| 37 | ✗ |
| 38 | ✗ |
| 39 | ✗ |
| 40 | ✗ |
| 41 | ✗ |
| 42 | ✗ |
| 43 | ✗ |
| 44 | ✓ |
| 45 | ✗ |
| 46 | ✗ |
| 47 | ✓ |
| 48 | ✗ |
| **49** | ✗ |
| 50 | ✗ |

All contents of this site are © 2024 Passmedicine Limited

A 25-year-old man presents with a rash predominantly affecting his back. The rest of his skin is unaffected.

The rash is not painful, although is very itchy. He had a similar occurrence last week but the rash resolved spontaneously within the same day. He denies any shortness of breath, and there is no swelling surrounding his mouth. He has not tried any new foods or started any new medicines. There is no past medical history of note, no regular medicines, and no recent illness.

His observations are as follows:

- Respiratory rate: 12 /min
- Saturations: 98% on room air
- Heart rate: 64bpm
- Blood pressure: 122/74mmHg
- Temperature: 37.2 deg C

© Image used on license from DermNet NZ

Given the likely diagnosis, which is the most appropriate next step in management?

- Diphenhydramine
- Epinephrine
- Fexofenadine

- Omalizumab
- Prednisolone

Submit answer

Reference ranges

Score: **0%**

1 -
2 -
3 -
4 -
5 -
6 -
7 -
8 -
9 -
10 -
11 -
12 -
13 -
14 -
15 -
16 -
17 -
18 -
19 -
20 -
21 -
22 -
23 -
24 -
25 -
26 -

27 -
28 -
29 -
30 -
31 -
32 -
33 -
34 -
35 -
36 -
37 -
38 -
39 -
40 -
41 -
42 -
43 -
44 -
45 -
46 -
47 -
48 -
49 -
**50** -

All contents of this site are © 2024 Passmedicine Limited
Back to top

A 25-year-old man presents with a rash predominantly affecting his back. The rest of his skin is unaffected.

The rash is not painful, although is very itchy. He had a similar occurrence last week but the rash resolved spontaneously within the same day. He denies any shortness of breath, and there is no swelling surrounding his mouth. He has not tried any new foods or started any new medicines. There is no past medical history of note, no regular medicines, and no recent illness.

His observations are as follows:

- Respiratory rate: 12 /min
- Saturations: 98% on room air
- Heart rate: 64bpm
- Blood pressure: 122/74mmHg
- Temperature: 37.2 deg C

© Image used on license from DermNet NZ

Given the likely diagnosis, which is the most appropriate next step in management?

- Diphenhydramine 25%
- Epinephrine 1%
- Fexofenadine 46%

Omalizumab 2%

Prednisolone 26%

The picture here shows the superficial irregular raised swellings/plaques surrounded by erythema that are characteristic of urticaria.

Urticaria can be classed based on its duration as acute (≤6 weeks) or chronic (>6 weeks). It can also be further subdivided as either spontaneous (with no definite trigger involved) or inducible (specific definite trigger involved). This man is presenting with acute spontaneous urticaria without signs of anaphylaxis or angioedema.

Acute urticaria is generally self-limiting. As such, it usually does not require a diagnostic workup apart from enquiring about possible trigger factors. Acute urticarias that may require further diagnostic workup would include those likely due to a type I food allergy or drug hypersensitivity. In these instances, allergy tests and patient education would play a role, enabling patients to avoid re-exposure to causative factors.

Here, there is no suggestion this is the case and so initial management is symptom-based. The predominant symptom is pruritus, so the focus is on short-term management of this.

**Fexofenadine** is the most appropriate of the given options as it is a second-generation anti-histamine and so is non-sedating.

**Diphenhydramine** is a first-generation anti-histamine, and so is sedative and to be avoided in the first instance. It could be considered in addition to the above if there is an inadequate response to the first-line antihistamine treatment, and itch is interfering with sleep.

**Omalizumab** is a monoclonal anti-immunoglobulin E antibody that is used in the treatment of chronic idiopathic urticaria, however would not be the first line in this instance.

**Prednisolone** as a short course could be given if symptoms were considered particularly severe, in addition to the non-sedating oral antihistamine. This patient has only a relatively small area of skin involved.

Finally, whilst anaphylaxis is something that should always be ruled out with urticaria, the above patient does not have any other features to suggest this and so **epinephrine** is not indicated here.

Discuss Improve

Next question

# Urticaria

Urticaria describes a local or generalised superficial swelling of the skin. The most common cause of urticaria is allergy although non-allergic causes are seen.

Features
- pale, pink raised skin. Variously described as 'hives', 'wheals', 'nettle rash'
- pruritic

Management
- non-sedating antihistamines (e.g. loratadine or cetirizine) are first-line
  - this should be continued for up to 6 weeks following an episode of acute urticaria
- a sedating antihistamine (e.g. chlorphenamine) may be considered for night-time use (in addition to day-time non-sedating antihistamine) for troublesome sleep symptoms
- prednisolone is used for severe or resistant episodes

+ Q 123

Next question >

**Textbooks**

High-yield textbook

Extended textbook

## Links

Royal College of Physicians 10 8

2012 The urticarias: pathophysiology and management

Clinical Knowledge Summaries 1 0

Urticaria

Suggest link Report broken link

Score: **14%**

| | |
|---|---|
| 1 | ✗ |
| 2 | ✗ |
| 3 | ✓ |
| 4 | ✗ |
| 5 | ✗ |
| 6 | ✗ |
| 7 | ✗ |
| 8 | ✗ |
| 9 | ✗ |
| 10 | ✗ |
| 11 | ✓ |
| 12 | ✗ |
| 13 | ✓ |
| 14 | ✗ |
| 15 | ✗ |
| 16 | ✗ |
| 17 | ✗ |
| 18 | ✗ |
| 19 | ✗ |

| | |
|---|---|
| 20 | ✗ |
| 21 | ✗ |
| 22 | ✗ |
| 23 | ✗ |
| 24 | ✗ |
| 25 | ✗ |
| 26 | ✓ |
| 27 | ✗ |
| 28 | ✗ |
| 29 | ✗ |
| 30 | ✗ |
| 31 | ✗ |
| 32 | ✓ |
| 33 | ✗ |
| 34 | ✗ |
| 35 | ✗ |
| 36 | ✗ |
| 37 | ✗ |
| 38 | ✗ |
| 39 | ✗ |
| 40 | ✗ |
| 41 | ✗ |
| 42 | ✗ |
| 43 | ✗ |
| 44 | ✓ |
| 45 | ✗ |
| 46 | ✗ |
| 47 | ✓ |
| 48 | ✗ |
| 49 | ✗ |
| **50** | ✗ |

All contents of this site are © 2024 Passmedicine Limited

Back to top

An 85-year-old man complains of a persistent 'scab' on his right ear. This has been present for the past year and causes some discomfort if he lays on his right side at night. It is mildly pruritic. His past medical history includes having an actinic keratosis removed from his left temple two years ago. A number of seborrhoeic keratoses are also noted across his body.

© Image used on license from DermNet NZ

What is the most likely diagnosis?

- Marjorin's ulcer
- Squamous cell carcinoma
- Basal cell carcinoma
- Chondrodermatitis nodularis helicis

Keratoacanthoma

Submit answer

Reference ranges

Score: **14%**

| | |
|---|---|
| 1 | ✗ |
| 2 | ✗ |
| 3 | ✓ |
| 4 | ✗ |
| 5 | ✗ |
| 6 | ✗ |
| 7 | ✗ |
| 8 | ✗ |
| 9 | ✗ |
| 10 | ✗ |
| 11 | ✓ |
| 12 | ✗ |
| 13 | ✓ |
| 14 | ✗ |
| 15 | ✗ |
| 16 | ✗ |
| 17 | ✗ |
| 18 | ✗ |
| 19 | ✗ |
| 20 | ✗ |
| 21 | ✗ |
| 22 | ✗ |
| 23 | ✗ |
| 24 | ✗ |
| 25 | ✗ |

| | |
|---|---|
| 26 | ✓ |
| 27 | ✗ |
| 28 | ✗ |
| 29 | ✗ |
| 30 | ✗ |
| 31 | ✗ |
| 32 | ✓ |
| 33 | ✗ |
| 34 | ✗ |
| 35 | ✗ |
| 36 | ✗ |
| 37 | ✗ |
| 38 | ✗ |
| 39 | ✗ |
| 40 | ✗ |
| 41 | ✗ |
| 42 | ✗ |
| 43 | ✗ |
| 44 | ✓ |
| 45 | ✗ |
| 46 | ✗ |
| 47 | ✓ |
| 48 | ✗ |
| 49 | ✗ |
| 50 | ✗ |
| **51** | - |

All contents of this site are © 2024 Passmedicine Limited

Back to top

An 85-year-old man complains of a persistent 'scab' on his right ear. This has been present for the past year and causes some discomfort if he lays on his right side at night. It is mildly pruritic. His past medical history includes having an actinic keratosis removed from his left temple two years ago. A number of seborrhoeic keratoses are also noted across his body.

© Image used on license from DermNet NZ

What is the most likely diagnosis?

| | |
|---|---|
| Marjorin's ulcer | 3% |
| Squamous cell carcinoma | 61% |
| Basal cell carcinoma | 17% |
| Chondrodermatitis nodularis helicis | 18% |

Keratoacanthoma 2%

The main differential diagnosis here is chondrodermatitis nodularis helicis, however, this has a very different typical appearance - much more well defined with regular features. A typical lesion is shown below:

© Image used on license from DermNet NZ

Typical appearance of chondrodermatitis nodularis helicis

Discuss (5) Improve

Next question

## Squamous cell carcinoma of the skin

Squamous cell carcinoma is a common variant of skin cancer. Metastases are rare but may occur in 2-5% of patients.

Risk factors include:

- excessive exposure to sunlight / psoralen UVA therapy
- actinic keratoses and Bowen's disease
- immunosuppression e.g. following renal transplant, HIV
- smoking
- long-standing leg ulcers (Marjolin's ulcer)
- genetic conditions e.g. xeroderma pigmentosum, oculocutaneous albinism

Features

- typically on sun-exposed sites such as the head and neck or dorsum of the hands and arms
- rapidly expanding painless, ulcerate nodules
- may have a cauliflower-like appearance
- there may be areas of bleeding

## Image gallery

## Treatment

Surgical excision with 4mm margins if lesion <20mm in diameter. If tumour >20mm then margins should be 6mm. Mohs micrographic surgery may be used in high-risk patients and in cosmetically important sites.

## Prognosis

| Good Prognosis | Poor prognosis |
|---|---|
| Well differentiated tumours | Poorly differentiated tumours |
| <20mm diameter | >20mm in diameter |
| <2mm deep | >4mm deep |
| No associated diseases | Immunosupression for whatever reason |

Next question >

## Textbooks

High-yield textbook

Extended textbook

## Links

DermNet NZ 28 4

Squamous cell carcinoma

Suggest link Report broken link

## Media

Skin cancers

Osmosis - YouTube 4 1

Report broken media

Score: **17%**

1 ✗

| | |
|---|---|
| 2 | ✗ |
| 3 | ✓ |
| 4 | ✗ |
| 5 | ✗ |
| 6 | ✗ |
| 7 | ✗ |
| 8 | ✗ |
| 9 | ✗ |
| 10 | ✗ |
| 11 | ✓ |
| 12 | ✗ |
| 13 | ✓ |
| 14 | ✗ |
| 15 | ✗ |
| 16 | ✗ |
| 17 | ✗ |
| 18 | ✗ |
| 19 | ✗ |
| 20 | ✗ |
| 21 | ✗ |
| 22 | ✗ |
| 23 | ✗ |
| 24 | ✗ |
| 25 | ✗ |
| 26 | ✓ |
| 27 | ✗ |
| 28 | ✗ |
| 29 | ✗ |
| 30 | ✗ |
| 31 | ✗ |
| 32 | ✓ |
| 33 | ✗ |
| 34 | ✗ |
| 35 | ✗ |
| 36 | ✗ |
| 37 | ✗ |

| | |
|---|---|
| 38 | ✗ |
| 39 | ✗ |
| 40 | ✗ |
| 41 | ✗ |
| 42 | ✗ |
| 43 | ✗ |
| 44 | ✓ |
| 45 | ✗ |
| 46 | ✗ |
| 47 | ✓ |
| 48 | ✗ |
| 49 | ✗ |
| 50 | ✗ |
| **51** | ✗ |
| 52 | ✗ |
| 53 | ✗ |
| 54 | ✗ |
| 55 | ✗ |
| 56 | ✗ |
| 57 | ✗ |
| 58 | ✗ |
| 59 | ✗ |
| 60 | ✗ |
| 61 | ✗ |
| 62 | ✓ |
| 63 | ✗ |
| 64 | ✗ |
| 65 | ✓ |
| 66 | ✗ |
| 67 | ✗ |
| 68 | ✗ |
| 69 | ✓ |
| 70 | ✓ |
| 71 | ✗ |
| 72 | ✗ |
| 73 | ✗ |

| | |
|---|---|
| 74 | ✓ |
| 75 | ✗ |
| 76 | ✗ |
| 77 | ✗ |
| 78 | ✗ |
| 79 | - |
| 80 | ✓ |
| 81 | ✗ |
| 82 | ✗ |
| 83 | ✗ |
| 84 | ✗ |
| 85 | ✗ |
| 86 | ✗ |
| 87 | ✗ |
| 88 | ✓ |
| 89 | ✓ |
| 90 | ✗ |
| 91 | ✗ |
| 92 | ✗ |
| 93 | ✗ |
| 94 | ✓ |
| 95 | ✗ |
| 96 | ✗ |
| 97 | ✗ |
| 98 | ✗ |
| 99 | ✓ |
| 100 | ✗ |
| 101 | ✗ |

All contents of this site are © 2024 Passmedicine Limited

Back to top

A 48-year-old male presents with a solitary skin nodule on his forearm which he first noticed a few weeks ago. He reports he was bitten by some form of insect prior to noticing the skin nodule.

On questioning, he describes the site as original very itchy with some tenderness after the bite but by the time he noticed the skin lesion, the area was and has remained, non-painful with only a mild itch.

© Image used on license from DermNet NZ

He is otherwise well with no systemic symptoms.

What is the most likely diagnosis?

- Basal-cell carcinoma
- Dermatofibroma
- Prurigo nodularis
- Leiomyoma
- Keratoacanthoma

Submit answer

Reference ranges

Score: **14%**

| | |
|---|---|
| 1 | ✗ |
| 2 | ✗ |
| 3 | ✓ |
| 4 | ✗ |
| 5 | ✗ |
| 6 | ✗ |
| 7 | ✗ |
| 8 | ✗ |
| 9 | ✗ |
| 10 | ✗ |
| 11 | ✓ |
| 12 | ✗ |
| 13 | ✓ |
| 14 | ✗ |
| 15 | ✗ |
| 16 | ✗ |
| 17 | ✗ |
| 18 | ✗ |
| 19 | ✗ |
| 20 | ✗ |
| 21 | ✗ |
| 22 | ✗ |
| 23 | ✗ |
| 24 | ✗ |
| 25 | ✗ |
| 26 | ✓ |
| 27 | ✗ |
| 28 | ✗ |
| 29 | ✗ |
| 30 | ✗ |
| 31 | ✗ |
| 32 | ✓ |
| 33 | ✗ |
| 34 | ✗ |

| | |
|---|---|
| 35 | ✗ |
| 36 | ✗ |
| 37 | ✗ |
| 38 | ✗ |
| 39 | ✗ |
| 40 | ✗ |
| 41 | ✗ |
| 42 | ✗ |
| 43 | ✗ |
| 44 | ✓ |
| 45 | ✗ |
| 46 | ✗ |
| 47 | ✓ |
| 48 | ✗ |
| 49 | ✗ |
| 50 | ✗ |
| 51 | - |
| **52** | - |

All contents of this site are © 2024 Passmedicine Limited

A 48-year-old male presents with a solitary skin nodule on his forearm which he first noticed a few weeks ago. He reports he was bitten by some form of insect prior to noticing the skin nodule.

On questioning, he describes the site as original very itchy with some tenderness after the bite but by the time he noticed the skin lesion, the area was and has remained, non-painful with only a mild itch.

© Image used on license from DermNet NZ

He is otherwise well with no systemic symptoms.

What is the most likely diagnosis?

| | |
|---|---|
| Basal-cell carcinoma | 2% |
| Dermatofibroma | 69% |
| Prurigo nodularis | 20% |
| Leiomyoma | 1% |
| Keratoacanthoma | 8% |

This patient has presented with a dermatofibroma, also called a histiocytoma. These are fibrous solitary, slow-growing papules caused by abnormal growth of dermal dendritic histiocyte cells. As seen in the picture they are raised and normal brown in colour. Although they can be itchy they are rarely painful and are associated with 'dimple sign', where applying lateral pressure produces a central depression. They can occur anywhere but are commonly seen on the arms and leg as they are often precipitated by an injury such as an insect bite (as with this patient) or a thorn prick.

Basal-cell carcinomas (BCC) are the most common form of skin cancer and often appear over several months, in sun-exposed areas. They are normally painless, slightly raised/macular areas of skin with a shiny, vascular appearance. BCC are rarely symmetrical and are unrelated to previous skin trauma.

Prurigo nodularis, also known as nodular prurigo, is a dermatological condition characterised by multiple, pruritic nodules commonly affecting the legs and arms. Unlike in dermatofibroma, itching only develops after the nodules have formed and increases in intensity as the condition progresses. Due to their pruritic nature patients commonly present with multiple excoriated lesions due to scratching and symptoms may only be alleviated by steroid use.

A leiomyoma, also known as a fibroid, is a smooth muscle tumour that is most commonly benign, only progressing to cancer in extremely rare cases (0.1%). As they arise in the smooth muscle they are seen within organs, commonly the uterus, small bowel, or oesophagus. Cutaneous leiomyomas are rare but when they do occur they are seen as multiple, freely movable nodules seen with overlying reddish skin.

A keratoacanthoma is a common, normally benign skin lesion that is thought to originate from the hair follicle. They are often dome-shaped and symmetrical, similar to a dermatofibroma however keratoacanthomas are surrounded by a smooth wall of inflamed skin and have a characteristic cap made of keratin scales and debris. The exact cause of keratoacanthomas is unclear but they are believed to be linked to ultraviolet light, chemical carcinogens and immunosuppression.

Discuss | Improve

Next question >

## Dermatofibroma

Dermatofibromas (also known as histiocytomas) are common benign fibrous skin lesions. They are caused by the abnormal growth of dermal dendritic histiocyte cells, often following a precipitating injury. Common areas include the arms and legs.

Features

- solitary firm papule or nodule, typically on a limb
- typically around 5-10mm in size
- overlying skin dimples on pinching the lesion

123

Next question

Textbooks

High-yield textbook

Extended textbook

Score: **17%**

| | |
|---|---|
| 1 | ✗ |
| 2 | ✗ |
| 3 | ✓ |
| 4 | ✗ |
| 5 | ✗ |
| 6 | ✗ |
| 7 | ✗ |
| 8 | ✗ |
| 9 | ✗ |
| 10 | ✗ |

| | |
|---|---|
| 11 | ✓ |
| 12 | ✗ |
| 13 | ✓ |
| 14 | ✗ |
| 15 | ✗ |
| 16 | ✗ |
| 17 | ✗ |
| 18 | ✗ |
| 19 | ✗ |
| 20 | ✗ |
| 21 | ✗ |
| 22 | ✗ |
| 23 | ✗ |
| 24 | ✗ |
| 25 | ✗ |
| 26 | ✓ |
| 27 | ✗ |
| 28 | ✗ |
| 29 | ✗ |
| 30 | ✗ |
| 31 | ✗ |
| 32 | ✓ |
| 33 | ✗ |
| 34 | ✗ |
| 35 | ✗ |
| 36 | ✗ |
| 37 | ✗ |
| 38 | ✗ |
| 39 | ✗ |
| 40 | ✗ |
| 41 | ✗ |
| 42 | ✗ |
| 43 | ✗ |
| 44 | ✓ |
| 45 | ✗ |
| 46 | ✗ |

| | |
|---|---|
| 47 | ✓ |
| 48 | ✗ |
| 49 | ✗ |
| 50 | ✗ |
| 51 | ✗ |
| **52** | ✗ |
| 53 | ✗ |
| 54 | ✗ |
| 55 | ✗ |
| 56 | ✗ |
| 57 | ✗ |
| 58 | ✗ |
| 59 | ✗ |
| 60 | ✗ |
| 61 | ✗ |
| 62 | ✓ |
| 63 | ✗ |
| 64 | ✗ |
| 65 | ✓ |
| 66 | ✗ |
| 67 | ✗ |
| 68 | ✗ |
| 69 | ✓ |
| 70 | ✓ |
| 71 | ✗ |
| 72 | ✗ |
| 73 | ✗ |
| 74 | ✓ |
| 75 | ✗ |
| 76 | ✗ |
| 77 | ✗ |
| 78 | ✗ |
| 79 | - |
| 80 | ✓ |
| 81 | ✗ |
| 82 | ✗ |

| | |
|---|---|
| 83 | ✗ |
| 84 | ✗ |
| 85 | ✗ |
| 86 | ✗ |
| 87 | ✗ |
| 88 | ✓ |
| 89 | ✓ |
| 90 | ✗ |
| 91 | ✗ |
| 92 | ✗ |
| 93 | ✗ |
| 94 | ✓ |
| 95 | ✗ |
| 96 | ✗ |
| 97 | ✗ |
| 98 | ✗ |
| 99 | ✓ |
| 100 | ✗ |
| 101 | ✗ |

All contents of this site are © 2024 Passmedicine Limited

A 19-year-old man presents to the dermatology clinic with his parents. He has a background of learning difficulties and eczema. His parents have noticed that he has had difficulty in controlling his eczema with topical emollients. He has previously had several episodes of infections of his eczema, but it is free of infection currently. On examination, his flexural folds are erythematous with clear discharge. There are no pungent odours. He has been using E45 cream three times a day with the assistance of his parents. His parents wonder what else could be done to help control his eczema?

- Change E45 to a urea containing emollient
- Long-term prophylactic antibiotics
- Oral steroids
- Bandaging after emollient use
- Topical immunosuppressant therapy

Submit answer

Reference ranges

Score: **14%**

| | |
|---|---|
| 1 | ✗ |
| 2 | ✗ |
| 3 | ✓ |
| 4 | ✗ |
| 5 | ✗ |
| 6 | ✗ |
| 7 | ✗ |

8 ✗
9 ✗
10 ✗
11 ✓
12 ✗
13 ✓
14 ✗
15 ✗
16 ✗
17 ✗
18 ✗
19 ✗
20 ✗
21 ✗
22 ✗
23 ✗
24 ✗
25 ✗
26 ✓
27 ✗
28 ✗
29 ✗
30 ✗
31 ✗
32 ✓
33 ✗
34 ✗
35 ✗
36 ✗
37 ✗
38 ✗
39 ✗
40 ✗
41 ✗
42 ✗
43 ✗

| | |
|---|---|
| 44 | ✓ |
| 45 | ✗ |
| 46 | ✗ |
| 47 | ✓ |
| 48 | ✗ |
| 49 | ✗ |
| 50 | ✗ |
| 51 | - |
| 52 | - |
| **53** | - |

All contents of this site are © 2024 Passmedicine Limited

Back to top

A 19-year-old man presents to the dermatology clinic with his parents. He has a background of learning difficulties and eczema. His parents have noticed that he has had difficulty in controlling his eczema with topical emollients. He has previously had several episodes of infections of his eczema, but it is free of infection currently. On examination, his flexural folds are erythematous with clear discharge. There are no pungent odours. He has been using E45 cream three times a day with the assistance of his parents. His parents wonder what else could be done to help control his eczema?

- Change E45 to a urea containing emollient — 34%
- Long-term prophylactic antibiotics — 1%
- Oral steroids — 9%
- Bandaging after emollient use — 38%
- Topical immunosuppressant therapy — 17%

Bandaging can help control itching in eczema to prevent further scratching

Important for me Less important

The most appropriate action is the use of bandaging. Bandaging in eczema can be used in non-infected patients for weeping or lichenified skin in combination with emollients and, if needed, topical corticosteroids. This patient's weeping skin could be helped by bandaging to help absorb the discharge and enhance the emollient effect.

Oral steroids and topical immunosuppressant therapy are only used in severe cases or when topical treatment has failed. Using a urea-containing topical agent can help with itching and moisturising effect, but can provoke further inflammation and would, therefore, be inappropriate for this patient. Long-term antibiotics are not used for eczema.

# Eczema: management

## Management

Avoidance of triggers and skin care education

- Key components include avoiding known irritants, allergens, and providing guidance on gentle skin care routines.

Emollients

- Integral to all treatment plans, regardless of eczema severity.
- Advise on liberal and regular use, even when the skin is clear, to maintain skin hydration and barrier function.
- Selection of emollient should be based on patient preference to improve adherence
  - Creams are generally preferred by most people - adherence is key so
  - Ointments provide the strongest emollient effect and may be more effective. However, they are greasy and so may be more suitable for use at night.

Topical therapies

- Topical corticosteroids
  - Vital for managing flare-ups, with potency tailored to the severity and lesion location
  - Example treatments recommended by NICE:
  - Mild eczema: hydrocortisone 1%
  - Moderate eczema: betamethasone valerate 0.025% or clobetasone butyrate 0.05%
  - Severe eczema: betamethasone valerate 0.1%
- Topical calcineurin inhibitors
  - Suitable for sensitive skin regions; include agents like tacrolimus and pimecrolimus.
- Topical antimicrobials
  - Used when there is clinical evidence of secondary infection.

Systemic therapies

- Indicated for severe or unresponsive cases.
- Oral corticosteroids:
  - Employed cautiously for acute severe exacerbations.
- Immunosuppressants:
  - Ciclosporin, methotrexate, or azathioprine are reserved for chronic, severe eczema.
- Biologic therapies:
  - Dupilumab is an advanced option for cases unresponsive to conventional therapy.

Phototherapy

- Considered for extensive eczema

## Prognosis

Prognostic markers associated with severe disease include:

- onset at age 3-6 months
- severe disease in childhood
- associated asthma or hay fever
- small family size
- high IgE serum levels

AI + Q 123

Next question >

### Textbooks

High-yield textbook

Extended textbook

### Links

British Association of Dermatologists 1 1

Atopic eczema guidelines

Clinical Knowledge Summaries 0 0

Atopic eczema

Suggest link Report broken link

## Media

Eczema

Osmosis - YouTube 2 0

Report broken media

Score: **17%**

| | |
|---|---|
| 1 | ✗ |
| 2 | ✗ |
| 3 | ✓ |
| 4 | ✗ |
| 5 | ✗ |
| 6 | ✗ |
| 7 | ✗ |
| 8 | ✗ |
| 9 | ✗ |
| 10 | ✗ |
| 11 | ✓ |
| 12 | ✗ |
| 13 | ✓ |
| 14 | ✗ |
| 15 | ✗ |
| 16 | ✗ |
| 17 | ✗ |
| 18 | ✗ |
| 19 | ✗ |
| 20 | ✗ |
| 21 | ✗ |
| 22 | ✗ |

| | |
|---|---|
| 23 | ✗ |
| 24 | ✗ |
| 25 | ✗ |
| 26 | ✓ |
| 27 | ✗ |
| 28 | ✗ |
| 29 | ✗ |
| 30 | ✗ |
| 31 | ✗ |
| 32 | ✓ |
| 33 | ✗ |
| 34 | ✗ |
| 35 | ✗ |
| 36 | ✗ |
| 37 | ✗ |
| 38 | ✗ |
| 39 | ✗ |
| 40 | ✗ |
| 41 | ✗ |
| 42 | ✗ |
| 43 | ✗ |
| 44 | ✓ |
| 45 | ✗ |
| 46 | ✗ |
| 47 | ✓ |
| 48 | ✗ |
| 49 | ✗ |
| 50 | ✗ |
| 51 | ✗ |
| 52 | ✗ |
| **53** | ✗ |
| 54 | ✗ |
| 55 | ✗ |
| 56 | ✗ |
| 57 | ✗ |
| 58 | ✗ |

| | |
|---|---|
| 59 | ✗ |
| 60 | ✗ |
| 61 | ✗ |
| 62 | ✓ |
| 63 | ✗ |
| 64 | ✗ |
| 65 | ✓ |
| 66 | ✗ |
| 67 | ✗ |
| 68 | ✗ |
| 69 | ✓ |
| 70 | ✓ |
| 71 | ✗ |
| 72 | ✗ |
| 73 | ✗ |
| 74 | ✓ |
| 75 | ✗ |
| 76 | ✗ |
| 77 | ✗ |
| 78 | ✗ |
| 79 | - |
| 80 | ✓ |
| 81 | ✗ |
| 82 | ✗ |
| 83 | ✗ |
| 84 | ✗ |
| 85 | ✗ |
| 86 | ✗ |
| 87 | ✗ |
| 88 | ✓ |
| 89 | ✓ |
| 90 | ✗ |
| 91 | ✗ |
| 92 | ✗ |
| 93 | ✗ |
| 94 | ✓ |

| | |
|---|---|
| 95 | ✗ |
| 96 | ✗ |
| 97 | ✗ |
| 98 | ✗ |
| 99 | ✓ |
| 100 | ✗ |
| 101 | ✗ |

All contents of this site are © 2024 Passmedicine Limited

A 28-year-old woman with a history of psoriasis presents with dandruff and an itchy scalp. She has tried using 'Head & Shoulders' with limited effect. A photograph of her scalp problems is shown below:

© Image used on license from DermNet NZ

What is the most appropriate first-line treatment?

- A coal tar based shampoo
- A ketoconazole based shampoo
- Topical beclomethasone
- Topical calcipotriol
- Topical calcipotriol + beclomethasone

Submit answer

Reference ranges

Score: **14%**

| | |
|---|---|
| 1 | ✗ |
| 2 | ✗ |
| 3 | ✓ |
| 4 | ✗ |
| 5 | ✗ |
| 6 | ✗ |
| 7 | ✗ |
| 8 | ✗ |
| 9 | ✗ |
| 10 | ✗ |
| 11 | ✓ |
| 12 | ✗ |
| 13 | ✓ |
| 14 | ✗ |
| 15 | ✗ |
| 16 | ✗ |
| 17 | ✗ |
| 18 | ✗ |
| 19 | ✗ |
| 20 | ✗ |
| 21 | ✗ |
| 22 | ✗ |
| 23 | ✗ |
| 24 | ✗ |
| 25 | ✗ |
| 26 | ✓ |
| 27 | ✗ |
| 28 | ✗ |
| 29 | ✗ |
| 30 | ✗ |
| 31 | ✗ |
| 32 | ✓ |

| | |
|---|---|
| 33 | ✗ |
| 34 | ✗ |
| 35 | ✗ |
| 36 | ✗ |
| 37 | ✗ |
| 38 | ✗ |
| 39 | ✗ |
| 40 | ✗ |
| 41 | ✗ |
| 42 | ✗ |
| 43 | ✗ |
| 44 | ✓ |
| 45 | ✗ |
| 46 | ✗ |
| 47 | ✓ |
| 48 | ✗ |
| 49 | ✗ |
| 50 | ✗ |
| 51 | - |
| 52 | - |
| 53 | - |
| **54** | - |

All contents of this site are © 2024 Passmedicine Limited

A 28-year-old woman with a history of psoriasis presents with dandruff and an itchy scalp. She has tried using 'Head & Shoulders' with limited effect. A photograph of her scalp problems is shown below:

© Image used on license from DermNet NZ

What is the most appropriate first-line treatment?

- A coal tar based shampoo 15%
- A ketoconazole based shampoo 37%
- Topical beclomethasone 17%
- Topical calcipotriol 5%
- Topical calcipotriol + beclomethasone 27%

Scalp psoriasis - first-line treatment is topical potent corticosteroids

Important for me Less important

Discuss (3) Improve

Next question

# Psoriasis: management

NICE released guidelines in 2012 on the management of psoriasis and psoriatic arthropathy. Please see the link for more details.

## Chronic plaque psoriasis management

NICE recommend a step-wise approach for chronic plaque psoriasis

- regular emollients may help to reduce scale loss and reduce pruritus
- first-line: NICE recommend:
  - a potent corticosteroid applied once daily plus vitamin D analogue applied once daily
  - should be applied separately, one in the morning and the other in the evening)
  - for up to 4 weeks as initial treatment
- second-line: if no improvement after 8 weeks then offer:
  - a vitamin D analogue twice daily
- third-line: if no improvement after 8-12 weeks then offer either:
  - a potent corticosteroid applied twice daily for up to 4 weeks, or
  - a coal tar preparation applied once or twice daily
- short-acting dithranol can also be used

**Secondary care management**

Phototherapy

- narrowband ultraviolet B light is now the treatment of choice. If possible this should be given 3 times a week
- photochemotherapy is also used - psoralen + ultraviolet A light (PUVA)
- adverse effects: skin ageing, squamous cell cancer (not melanoma)

Systemic therapy

- oral methotrexate is used first-line. It is particularly useful if there is associated joint disease
- ciclosporin
- systemic retinoids
- biological agents: infliximab, etanercept and adalimumab
- ustekinumab (IL-12 and IL-23 blocker) is showing promise in early trials

## Scalp psoriasis management

Outline

- NICE recommend the use of potent topical corticosteroids used once daily for 4 weeks
- if no improvement after 4 weeks then either use a different formulation of the potent corticosteroid (for example, a shampoo or mousse) and/or a topical agents to remove adherent scale (for example, agents containing salicylic acid, emollients and oils) before application of the potent corticosteroid

## Face, flexural and genital psoriasis management

Outline

- NICE recommend offering a mild or moderate potency corticosteroid applied once or twice daily for a maximum of 2 weeks

## Notes on medication

Using topical steroids in psoriasis

- as we know topical corticosteroid therapy may lead to skin atrophy, striae and rebound symptoms
    - the scalp, face and flexures are particularly prone to steroid atrophy so topical steroids should not be used for more than 1-2 weeks/month
- systemic side-effects may be seen when potent corticosteroids are used on large areas e.g. > 10% of the body surface area
- NICE recommend that we aim for a 4-week break before starting another course of topical corticosteroids
- they also recommend using potent corticosteroids for no longer than 8 weeks at a time and very potent corticosteroids for no longer than 4 weeks at a time

Vitamin D analogues

- examples of vitamin D analogues include calcipotriol (Dovonex), calcitriol and tacalcitol

- they work by ↓ cell division and differentiation → ↓ epidermal proliferation
- adverse effects are uncommon
- unlike corticosteroids they may be used long-term
- unlike coal tar and dithranol they do not smell or stain
- they tend to reduce the scale and thickness of plaques but not the erythema
- they should be avoided in pregnancy
- the maximum weekly amount for adults is 100g

© Image used on license from DermNet NZ

A 'before and after' image showing the effect of 6 weeks of calcipotriol therapy on a large plaque. Note how the scale has improved but the erythema remains

Dithranol

- inhibits DNA synthesis
- wash off after 30 mins
- adverse effects include burning, staining

Coal tar

- mechanism of action not fully understood - probably inhibit DNA synthesis

123

Next question

## Textbooks

High-yield textbook

Extended textbook

## Links

SIGN 14 13

2010 Psoriasis guidelines

British Association of Dermatologists 14 11

2017 Guidelines for biologic therapy for psoriasis

NICE 21 16

2012 Psoriasis guidelines

Suggest link Report broken link

## Media

Psoriasis

Osmosis - YouTube 1 1

Report broken media

Score: **17%**

| | |
|---|---|
| 1 | ✗ |
| 2 | ✗ |
| 3 | ✓ |
| 4 | ✗ |
| 5 | ✗ |
| 6 | ✗ |
| 7 | ✗ |
| 8 | ✗ |
| 9 | ✗ |
| 10 | ✗ |
| 11 | ✓ |
| 12 | ✗ |
| 13 | ✓ |
| 14 | ✗ |
| 15 | ✗ |
| 16 | ✗ |
| 17 | ✗ |
| 18 | ✗ |
| 19 | ✗ |
| 20 | ✗ |
| 21 | ✗ |
| 22 | ✗ |
| 23 | ✗ |
| 24 | ✗ |
| 25 | ✗ |
| 26 | ✓ |
| 27 | ✗ |
| 28 | ✗ |
| 29 | ✗ |
| 30 | ✗ |

| | |
|---|---|
| 31 | ✗ |
| 32 | ✓ |
| 33 | ✗ |
| 34 | ✗ |
| 35 | ✗ |
| 36 | ✗ |
| 37 | ✗ |
| 38 | ✗ |
| 39 | ✗ |
| 40 | ✗ |
| 41 | ✗ |
| 42 | ✗ |
| 43 | ✗ |
| 44 | ✓ |
| 45 | ✗ |
| 46 | ✗ |
| 47 | ✓ |
| 48 | ✗ |
| 49 | ✗ |
| 50 | ✗ |
| 51 | ✗ |
| 52 | ✗ |
| 53 | ✗ |
| **54** | ✗ |
| 55 | ✗ |
| 56 | ✗ |
| 57 | ✗ |
| 58 | ✗ |
| 59 | ✗ |
| 60 | ✗ |
| 61 | ✗ |
| 62 | ✓ |
| 63 | ✗ |
| 64 | ✗ |
| 65 | ✓ |
| 66 | ✗ |

| | |
|---|---|
| 67 | ✗ |
| 68 | ✗ |
| 69 | ✓ |
| 70 | ✓ |
| 71 | ✗ |
| 72 | ✗ |
| 73 | ✗ |
| 74 | ✓ |
| 75 | ✗ |
| 76 | ✗ |
| 77 | ✗ |
| 78 | ✗ |
| 79 | - |
| 80 | ✓ |
| 81 | ✗ |
| 82 | ✗ |
| 83 | ✗ |
| 84 | ✗ |
| 85 | ✗ |
| 86 | ✗ |
| 87 | ✗ |
| 88 | ✓ |
| 89 | ✓ |
| 90 | ✗ |
| 91 | ✗ |
| 92 | ✗ |
| 93 | ✗ |
| 94 | ✓ |
| 95 | ✗ |
| 96 | ✗ |
| 97 | ✗ |
| 98 | ✗ |
| 99 | ✓ |
| 100 | ✗ |
| 101 | ✗ |

All contents of this site are © 2024 Passmedicine Limited

A 44-year-old woman visits her general practitioner with a 48-hour history of a new, erythematous rash on her neck. She described initially noticing lesions on the backs of her hands the day before. The rash is mildly itchy but not painful. There is no past medical history of note other than taking a course of antibiotics for a lower respiratory tract infection, diagnosed 4 days earlier.

Her rash is examined, as pictured below:

© Image used on license from DermNet NZ

What is the most likely diagnosis?

- Dermatitis herpetiformis
- Erythema multiforme
- Guttate psoriasis
- Pityriasis rosea
- Tinea corporis

Submit answer

Reference ranges

Score: **14%**

| | |
|---|---|
| 1 | ✗ |
| 2 | ✗ |
| 3 | ✓ |
| 4 | ✗ |
| 5 | ✗ |
| 6 | ✗ |
| 7 | ✗ |
| 8 | ✗ |
| 9 | ✗ |
| 10 | ✗ |
| 11 | ✓ |
| 12 | ✗ |
| 13 | ✓ |
| 14 | ✗ |
| 15 | ✗ |
| 16 | ✗ |
| 17 | ✗ |
| 18 | ✗ |
| 19 | ✗ |
| 20 | ✗ |
| 21 | ✗ |
| 22 | ✗ |
| 23 | ✗ |
| 24 | ✗ |
| 25 | ✗ |
| 26 | ✓ |

| | |
|---|---|
| 27 | ✗ |
| 28 | ✗ |
| 29 | ✗ |
| 30 | ✗ |
| 31 | ✗ |
| 32 | ✓ |
| 33 | ✗ |
| 34 | ✗ |
| 35 | ✗ |
| 36 | ✗ |
| 37 | ✗ |
| 38 | ✗ |
| 39 | ✗ |
| 40 | ✗ |
| 41 | ✗ |
| 42 | ✗ |
| 43 | ✗ |
| 44 | ✓ |
| 45 | ✗ |
| 46 | ✗ |
| 47 | ✓ |
| 48 | ✗ |
| 49 | ✗ |
| 50 | ✗ |
| 51 | - |
| 52 | - |
| 53 | - |
| 54 | - |
| **55** | - |

All contents of this site are © 2024 Passmedicine Limited

A 44-year-old woman visits her general practitioner with a 48-hour history of a new, erythematous rash on her neck. She described initially noticing lesions on the backs of her hands the day before. The rash is mildly itchy but not painful. There is no past medical history of note other than taking a course of antibiotics for a lower respiratory tract infection, diagnosed 4 days earlier.

Her rash is examined, as pictured below:

© Image used on license from DermNet NZ

What is the most likely diagnosis?

| | |
|---|---|
| Dermatitis herpetiformis | 2% |
| Erythema multiforme | 62% |
| Guttate psoriasis | 13% |
| Pityriasis rosea | 10% |
| Tinea corporis | 14% |

This patient has multiple, round erythematous lesions on her neck. On closer inspection, the lesions appear as the classical target lesions with an outermost erythematous ring and paler centre. This is in keeping with a diagnosis of erythema multiforme. Erythema multiforme is an acute, self-limiting skin eruption most commonly secondary to an infective trigger (e.g. herpes simplex virus or *Mycoplasma pneumoniae*). The rash appears abruptly and affects the upper limbs most often before spreading down towards the trunk. The ongoing lower respiratory tract infection points toward an infection with *Mycoplasma pneumoniae*, the second most common infective cause of erythema multiforme.

Dermatitis herpetiformis is an itchy vesicular rash commonly associated with coeliac disease. It typically has a symmetrical distribution appearing on the elbows, knees, shoulders and buttocks. The rash seen in the above image is not symmetrical, nor does it appear vesicular. Furthermore, the absence of a history of autoimmune disease or coeliac disease makes dermatitis herpetiformis unlikely.

Guttate psoriasis is a subtype of psoriasis that commonly occurs after a streptococcal infection and is characterised by multiple small scaly plaques on the trunk and limbs. The onset of guttate psoriasis can be rapid and occur within days of initial infection. Although this patient has had a recent bacterial infection, the appearance of this rash is not scaly, but instead, shows target lesions in keeping with erythema multiforme.

Pityriasis rosea is a viral rash that is characterised by an initial herald patch followed by multiple red plaques developing over the trunk. The rash is usually asymptomatic with the only symptoms present being of an underlying viral infection (e.g. cough and coryza). There is no history of a herald patch in this question and the location and appearance of the lesions are not in keeping with pityriasis rosea.

Tinea corporis or ringworm is a fungal skin infection capable of affecting most parts of the body. The rash initially presents as a single well-demarcated, erythematous circular patch with a raised edge and central hypopigmentation. Itching is a prominent clinical feature. it does not classically cause multiple defined lesions as shown in this picture and tends to have a slower onset of development.

Discuss Improve

Next question

## Erythema multiforme

Erythema multiforme is a hypersensitivity reaction that is most commonly triggered by infections. It may be divided into minor and major forms.

Previously it was thought that Stevens-Johnson syndrome (SJS) was a severe form of erythema multiforme. They are now however considered as separate entities.

Features
- target lesions
- initially seen on the back of the hands / feet before spreading to the torso
- upper limbs are more commonly affected than the lower limbs
- pruritus is occasionally seen and is usually mild

Causes
- viruses: herpes simplex virus (the most common cause), Orf*
- idiopathic
- bacteria: *Mycoplasma*, *Streptococcus*
- drugs: penicillin, sulphonamides, carbamazepine, allopurinol, NSAIDs, oral contraceptive pill, nevirapine
- connective tissue disease e.g. Systemic lupus erythematosus
- sarcoidosis
- malignancy

## Erythema multiforme major

The more severe form, erythema multiforme major is associated with mucosal involvement.

*Orf is a skin disease of sheep and goats caused by a parapox virus

AI + Q 123

Next question

## Textbooks

High-yield textbook

Extended textbook

## Links

DermNet NZ 18 10

Erythema multiforme

Suggest link Report broken link

## Media

Erythema multiforme

Osmosis - YouTube

1 0

Report broken media

Score: **17%**

| | |
|---|---|
| 1 | ✗ |
| 2 | ✗ |
| 3 | ✓ |
| 4 | ✗ |
| 5 | ✗ |
| 6 | ✗ |
| 7 | ✗ |
| 8 | ✗ |
| 9 | ✗ |
| 10 | ✗ |
| 11 | ✓ |
| 12 | ✗ |
| 13 | ✓ |
| 14 | ✗ |
| 15 | ✗ |
| 16 | ✗ |
| 17 | ✗ |
| 18 | ✗ |
| 19 | ✗ |
| 20 | ✗ |
| 21 | ✗ |
| 22 | ✗ |
| 23 | ✗ |
| 24 | ✗ |
| 25 | ✗ |
| 26 | ✓ |
| 27 | ✗ |
| 28 | ✗ |

| | |
|---|---|
| 29 | ✗ |
| 30 | ✗ |
| 31 | ✗ |
| 32 | ✓ |
| 33 | ✗ |
| 34 | ✗ |
| 35 | ✗ |
| 36 | ✗ |
| 37 | ✗ |
| 38 | ✗ |
| 39 | ✗ |
| 40 | ✗ |
| 41 | ✗ |
| 42 | ✗ |
| 43 | ✗ |
| 44 | ✓ |
| 45 | ✗ |
| 46 | ✗ |
| 47 | ✓ |
| 48 | ✗ |
| 49 | ✗ |
| 50 | ✗ |
| 51 | ✗ |
| 52 | ✗ |
| 53 | ✗ |
| 54 | ✗ |
| **55** | ✗ |
| 56 | ✗ |
| 57 | ✗ |
| 58 | ✗ |
| 59 | ✗ |
| 60 | ✗ |
| 61 | ✗ |
| 62 | ✓ |
| 63 | ✗ |
| 64 | ✗ |

| | |
|---|---|
| 65 | ✓ |
| 66 | ✕ |
| 67 | ✕ |
| 68 | ✕ |
| 69 | ✓ |
| 70 | ✓ |
| 71 | ✕ |
| 72 | ✕ |
| 73 | ✕ |
| 74 | ✓ |
| 75 | ✕ |
| 76 | ✕ |
| 77 | ✕ |
| 78 | ✕ |
| 79 | - |
| 80 | ✓ |
| 81 | ✕ |
| 82 | ✕ |
| 83 | ✕ |
| 84 | ✕ |
| 85 | ✕ |
| 86 | ✕ |
| 87 | ✕ |
| 88 | ✓ |
| 89 | ✓ |
| 90 | ✕ |
| 91 | ✕ |
| 92 | ✕ |
| 93 | ✕ |
| 94 | ✓ |
| 95 | ✕ |
| 96 | ✕ |
| 97 | ✕ |
| 98 | ✕ |
| 99 | ✓ |
| 100 | ✕ |

101 ✕

All contents of this site are © 2024 Passmedicine Limited

Back to top

A 45 year-old woman presents to her GP with an ulcer on her left shin. It has been present for the past 4 months and gradually got bigger. It is tender and yellow-brown in colour and there appears to be another smaller lesion that is growing next to the bigger one. She has a past medical history of multiple sclerosis, of which she is currently in remission phase and type 1 diabetes mellitus. Her only regular medication includes insulin.

What is the most appropriate treatment?

- Flucloxacillin
- Topical corticosteroids
- TED stockings
- Oral corticosteroids
- Topical tacrolimus

Submit answer

Reference ranges

Score: **14%**

| | |
|---|---|
| 1 | ✗ |
| 2 | ✗ |
| 3 | ✓ |
| 4 | ✗ |
| 5 | ✗ |
| 6 | ✗ |
| 7 | ✗ |

| | |
|---|---|
| 8 | ✗ |
| 9 | ✗ |
| 10 | ✗ |
| 11 | ✓ |
| 12 | ✗ |
| 13 | ✓ |
| 14 | ✗ |
| 15 | ✗ |
| 16 | ✗ |
| 17 | ✗ |
| 18 | ✗ |
| 19 | ✗ |
| 20 | ✗ |
| 21 | ✗ |
| 22 | ✗ |
| 23 | ✗ |
| 24 | ✗ |
| 25 | ✗ |
| 26 | ✓ |
| 27 | ✗ |
| 28 | ✗ |
| 29 | ✗ |
| 30 | ✗ |
| 31 | ✗ |
| 32 | ✓ |
| 33 | ✗ |
| 34 | ✗ |
| 35 | ✗ |
| 36 | ✗ |
| 37 | ✗ |
| 38 | ✗ |
| 39 | ✗ |
| 40 | ✗ |
| 41 | ✗ |
| 42 | ✗ |
| 43 | ✗ |

| | |
|---|---|
| 44 | ✓ |
| 45 | ✗ |
| 46 | ✗ |
| 47 | ✓ |
| 48 | ✗ |
| 49 | ✗ |
| 50 | ✗ |
| 51 | - |
| 52 | - |
| 53 | - |
| 54 | - |
| 55 | - |
| **56** | - |

All contents of this site are © 2024 Passmedicine Limited

A 45 year-old woman presents to her GP with an ulcer on her left shin. It has been present for the past 4 months and gradually got bigger. It is tender and yellow-brown in colour and there appears to be another smaller lesion that is growing next to the bigger one. She has a past medical history of multiple sclerosis, of which she is currently in remission phase and type 1 diabetes mellitus. Her only regular medication includes insulin.

What is the most appropriate treatment?

| | |
|---|---|
| Flucloxacillin | 7% |
| Topical corticosteroids | 39% |
| TED stockings | 14% |
| Oral corticosteroids | 26% |
| Topical tacrolimus | 15% |

The most likely diagnosis is necrobiosis lipoidica, a rare granulomatous skin disorder which can affect the shin of insulin dependent diabetics. Skin biopsy can confirm the diagnosis, although it is often done clinically and topical steroids are a useful treatment, along with injectable corticosteroids and camouflage creams.

Discuss (6) Improve

Next question

## Shin lesions

The differential diagnosis of shin lesions includes the following conditions:

- erythema nodosum
- pretibial myxoedema
- pyoderma gangrenosum
- necrobiosis lipoidica diabeticorum

Below are the characteristic features:

Erythema nodosum

- symmetrical, erythematous, tender, nodules which heal without scarring
- most common causes are streptococcal infections, sarcoidosis, inflammatory bowel disease and drugs (penicillins, sulphonamides, oral contraceptive pill)

Pretibial myxoedema

- symmetrical, erythematous lesions seen in Graves' disease
- shiny, orange peel skin

Pyoderma gangrenosum

- initially small red papule
- later deep, red, necrotic ulcers with a violaceous border
- idiopathic in 50%, may also be seen in inflammatory bowel disease, connective tissue disorders and myeloproliferative disorders

Necrobiosis lipoidica diabeticorum

- shiny, painless areas of yellow/red skin typically on the shin of diabetics
- often associated with telangiectasia

AI + Q 123

Next question >

Textbooks

High-yield textbook

Extended textbook

## Links

DermIS.net 9 10

Picture of pretibial myxoedema

DermNet NZ 12 4

Necrobiosis lipoidica

DermNet NZ 10 2

Pyoderma gangrenosum

DermNet NZ 13 1

Erythema nodosum

Suggest link Report broken link

Score: **17%**

1 ✗
2 ✗
3 ✓
4 ✗
5 ✗
6 ✗
7 ✗
8 ✗
9 ✗
10 ✗
11 ✓
12 ✗
13 ✓
14 ✗

| | |
|---|---|
| 15 | ✗ |
| 16 | ✗ |
| 17 | ✗ |
| 18 | ✗ |
| 19 | ✗ |
| 20 | ✗ |
| 21 | ✗ |
| 22 | ✗ |
| 23 | ✗ |
| 24 | ✗ |
| 25 | ✗ |
| 26 | ✓ |
| 27 | ✗ |
| 28 | ✗ |
| 29 | ✗ |
| 30 | ✗ |
| 31 | ✗ |
| 32 | ✓ |
| 33 | ✗ |
| 34 | ✗ |
| 35 | ✗ |
| 36 | ✗ |
| 37 | ✗ |
| 38 | ✗ |
| 39 | ✗ |
| 40 | ✗ |
| 41 | ✗ |
| 42 | ✗ |
| 43 | ✗ |
| 44 | ✓ |
| 45 | ✗ |
| 46 | ✗ |
| 47 | ✓ |
| 48 | ✗ |
| 49 | ✗ |
| 50 | ✗ |

| | |
|---|---|
| 51 | ✗ |
| 52 | ✗ |
| 53 | ✗ |
| 54 | ✗ |
| 55 | ✗ |
| **56** | ✗ |
| 57 | ✗ |
| 58 | ✗ |
| 59 | ✗ |
| 60 | ✗ |
| 61 | ✗ |
| 62 | ✓ |
| 63 | ✗ |
| 64 | ✗ |
| 65 | ✓ |
| 66 | ✗ |
| 67 | ✗ |
| 68 | ✗ |
| 69 | ✓ |
| 70 | ✓ |
| 71 | ✗ |
| 72 | ✗ |
| 73 | ✗ |
| 74 | ✓ |
| 75 | ✗ |
| 76 | ✗ |
| 77 | ✗ |
| 78 | ✗ |
| 79 | - |
| 80 | ✓ |
| 81 | ✗ |
| 82 | ✗ |
| 83 | ✗ |
| 84 | ✗ |
| 85 | ✗ |
| 86 | ✗ |

| | |
|---|---|
| 87 | ✗ |
| 88 | ✓ |
| 89 | ✓ |
| 90 | ✗ |
| 91 | ✗ |
| 92 | ✗ |
| 93 | ✗ |
| 94 | ✓ |
| 95 | ✗ |
| 96 | ✗ |
| 97 | ✗ |
| 98 | ✗ |
| 99 | ✓ |
| 100 | ✗ |
| 101 | ✗ |

All contents of this site are © 2024 Passmedicine Limited

Back to top

A 19-year-old woman asks you to have a look at a 'tag' on her neck. It developed around two months ago and has bled on a number of occasions after catching it.

© Image used on license from DermNet NZ

What is the most likely diagnosis?

- Pyogenic granuloma
- Capillary haemangioma
- Vital wart
- Malignant melanoma
- Molluscum contagiosum

Submit answer

Reference ranges

Score: **14%**

| | |
|---|---|
| 1 | ✗ |
| 2 | ✗ |
| 3 | ✓ |
| 4 | ✗ |
| 5 | ✗ |
| 6 | ✗ |
| 7 | ✗ |
| 8 | ✗ |
| 9 | ✗ |
| 10 | ✗ |
| 11 | ✓ |
| 12 | ✗ |
| 13 | ✓ |
| 14 | ✗ |
| 15 | ✗ |
| 16 | ✗ |
| 17 | ✗ |
| 18 | ✗ |
| 19 | ✗ |
| 20 | ✗ |
| 21 | ✗ |
| 22 | ✗ |
| 23 | ✗ |
| 24 | ✗ |
| 25 | ✗ |
| 26 | ✓ |
| 27 | ✗ |
| 28 | ✗ |
| 29 | ✗ |
| 30 | ✗ |

| | |
|---|---|
| 31 | ✗ |
| 32 | ✓ |
| 33 | ✗ |
| 34 | ✗ |
| 35 | ✗ |
| 36 | ✗ |
| 37 | ✗ |
| 38 | ✗ |
| 39 | ✗ |
| 40 | ✗ |
| 41 | ✗ |
| 42 | ✗ |
| 43 | ✗ |
| 44 | ✓ |
| 45 | ✗ |
| 46 | ✗ |
| 47 | ✓ |
| 48 | ✗ |
| 49 | ✗ |
| 50 | ✗ |
| 51 | - |
| 52 | - |
| 53 | - |
| 54 | - |
| 55 | - |
| 56 | - |
| **57** | - |

All contents of this site are © 2024 Passmedicine Limited

Back to top

A 19-year-old woman asks you to have a look at a 'tag' on her neck. It developed around two months ago and has bled on a number of occasions after catching it.

© Image used on license from DermNet NZ

What is the most likely diagnosis?

| | |
|---|---|
| Pyogenic granuloma | 59% |
| Capillary haemangioma | 32% |
| Vital wart | 5% |
| Malignant melanoma | 2% |
| Molluscum contagiosum | 2% |

The most likely diagnosis for this patient is a **Pyogenic granuloma**. Pyogenic granulomas are benign skin lesions that often appear as small, reddish bumps on the skin. They can develop rapidly over a few weeks and tend to bleed easily because they contain many blood vessels. The

history of this lesion developing over two months and bleeding after minor trauma is consistent with a pyogenic granuloma.

A **Capillary haemangioma**, also known as a strawberry naevus, is an incorrect choice. These usually present at birth or shortly thereafter and grow rapidly before starting to regress by 1-2 years of age. They are rarely seen in adults and do not typically bleed unless traumatised.

The option of **Viral wart** is also incorrect. Viral warts caused by human papillomavirus (HPV) are usually rough, hard, and non-bleeding unless injured.

**Malignant melanoma** is unlikely given the patient's history and clinical presentation. Melanomas usually have irregular borders, vary in colour from one area to another, have a diameter larger than 6mm and evolve over time (ABCDE criteria). Furthermore, malignant melanomas don't typically bleed unless they ulcerate or are traumatised.

Finally, **Molluscum contagiosum** is also an incorrect choice. Molluscum contagiosum presents as multiple small, dome-shaped papules with a central umbilication caused by a poxvirus. It does not generally cause bleeding but may become inflamed or itchy. The solitary nature of this lesion makes molluscum contagiosum less likely.

Discuss (2) Improve

Next question

## Pyogenic granuloma

Pyogenic granuloma is a relatively common benign skin lesion. The name is confusing as they are neither true granulomas nor pyogenic in nature. There are multiple alternative names but perhaps 'eruptive haemangioma' is the most useful.

The cause of pyogenic granuloma is not known but a number of factors are linked:

- trauma
- pregnancy
- more common in women and young adults

Features

- most common sites are head/neck, upper trunk and hands. Lesions in the oral mucosa are common in pregnancy
- initially small red/brown spot

- rapidly progress within days to weeks forming raised, red/brown lesions which are often spherical in shape
- the lesions may bleed profusely or ulcerate

Management

- lesions associated with pregnancy often resolve spontaneously post-partum
- other lesions usually persist. Removal methods include curettage and cauterisation, cryotherapy, excision

123

Next question

## Textbooks

High-yield textbook

Extended textbook

## Links

DermNet NZ 8 3

Pyogenic granuloma

Suggest link Report broken link

Score: **17%**

| | |
|---|---|
| 1 | ✗ |
| 2 | ✗ |
| 3 | ✓ |
| 4 | ✗ |
| 5 | ✗ |
| 6 | ✗ |
| 7 | ✗ |
| 8 | ✗ |
| 9 | ✗ |
| 10 | ✗ |
| 11 | ✓ |
| 12 | ✗ |
| 13 | ✓ |
| 14 | ✗ |
| 15 | ✗ |
| 16 | ✗ |
| 17 | ✗ |
| 18 | ✗ |
| 19 | ✗ |
| 20 | ✗ |
| 21 | ✗ |
| 22 | ✗ |
| 23 | ✗ |
| 24 | ✗ |
| 25 | ✗ |
| 26 | ✓ |
| 27 | ✗ |
| 28 | ✗ |
| 29 | ✗ |
| 30 | ✗ |
| 31 | ✗ |

| | |
|---|---|
| 32 | ✓ |
| 33 | ✗ |
| 34 | ✗ |
| 35 | ✗ |
| 36 | ✗ |
| 37 | ✗ |
| 38 | ✗ |
| 39 | ✗ |
| 40 | ✗ |
| 41 | ✗ |
| 42 | ✗ |
| 43 | ✗ |
| 44 | ✓ |
| 45 | ✗ |
| 46 | ✗ |
| 47 | ✓ |
| 48 | ✗ |
| 49 | ✗ |
| 50 | ✗ |
| 51 | ✗ |
| 52 | ✗ |
| 53 | ✗ |
| 54 | ✗ |
| 55 | ✗ |
| 56 | ✗ |
| **57** | ✗ |
| 58 | ✗ |
| 59 | ✗ |
| 60 | ✗ |
| 61 | ✗ |
| 62 | ✓ |
| 63 | ✗ |
| 64 | ✗ |
| 65 | ✓ |
| 66 | ✗ |
| 67 | ✗ |

| | |
|---|---|
| 68 | ✗ |
| 69 | ✓ |
| 70 | ✓ |
| 71 | ✗ |
| 72 | ✗ |
| 73 | ✗ |
| 74 | ✓ |
| 75 | ✗ |
| 76 | ✗ |
| 77 | ✗ |
| 78 | ✗ |
| 79 | - |
| 80 | ✓ |
| 81 | ✗ |
| 82 | ✗ |
| 83 | ✗ |
| 84 | ✗ |
| 85 | ✗ |
| 86 | ✗ |
| 87 | ✗ |
| 88 | ✓ |
| 89 | ✓ |
| 90 | ✗ |
| 91 | ✗ |
| 92 | ✗ |
| 93 | ✗ |
| 94 | ✓ |
| 95 | ✗ |
| 96 | ✗ |
| 97 | ✗ |
| 98 | ✗ |
| 99 | ✓ |
| 100 | ✗ |
| 101 | ✗ |

All contents of this site are © 2024 Passmedicine Limited

A 35-year-old woman who was born in Eastern Europe presents with a 5-day history of skin changes on her legs, as shown in the image below. She has a past medical history of asthma and type I diabetes. She has had a recent illness with persisting sore throat, myalgia and fatigue for 10 days.

There are no skin changes elsewhere in the body. She has some mild arthralgia affecting the knees and ankles on both sides, but no effusion or erythema affecting the joints.

© Image used on license from DermNet NZ

What is the most likely precipitating cause?

- *Haemophilus influenzae* infection
- Epstein Barr virus
- Sarcoidosis
- Streptococcal throat infection
- Tuberculosis

Submit answer

Reference ranges

Score: **14%**

| | |
|---|---|
| 1 | ✗ |
| 2 | ✗ |
| 3 | ✓ |
| 4 | ✗ |
| 5 | ✗ |
| 6 | ✗ |
| 7 | ✗ |
| 8 | ✗ |
| 9 | ✗ |
| 10 | ✗ |
| 11 | ✓ |
| 12 | ✗ |
| 13 | ✓ |
| 14 | ✗ |
| 15 | ✗ |
| 16 | ✗ |
| 17 | ✗ |
| 18 | ✗ |
| 19 | ✗ |
| 20 | ✗ |
| 21 | ✗ |
| 22 | ✗ |
| 23 | ✗ |
| 24 | ✗ |
| 25 | ✗ |
| 26 | ✓ |
| 27 | ✗ |
| 28 | ✗ |
| 29 | ✗ |
| 30 | ✗ |

| | |
|---|---|
| 31 | ✗ |
| 32 | ✓ |
| 33 | ✗ |
| 34 | ✗ |
| 35 | ✗ |
| 36 | ✗ |
| 37 | ✗ |
| 38 | ✗ |
| 39 | ✗ |
| 40 | ✗ |
| 41 | ✗ |
| 42 | ✗ |
| 43 | ✗ |
| 44 | ✓ |
| 45 | ✗ |
| 46 | ✗ |
| 47 | ✓ |
| 48 | ✗ |
| 49 | ✗ |
| 50 | ✗ |
| 51 | - |
| 52 | - |
| 53 | - |
| 54 | - |
| 55 | - |
| 56 | - |
| 57 | - |
| **58** | - |

All contents of this site are © 2024 Passmedicine Limited

Back to top

A 35-year-old woman who was born in Eastern Europe presents with a 5-day history of skin changes on her legs, as shown in the image below. She has a past medical history of asthma and type I diabetes. She has had a recent illness with persisting sore throat, myalgia and fatigue for 10 days.

There are no skin changes elsewhere in the body. She has some mild arthralgia affecting the knees and ankles on both sides, but no effusion or erythema affecting the joints.

© Image used on license from DermNet NZ

What is the most likely precipitating cause?

- *Haemophilus influenzae* infection 3%
- Epstein Barr virus 10%
- Sarcoidosis 25%
- Streptococcal throat infection 59%
- Tuberculosis 3%

This patient has erythema nodosum (EN) - as shown by the several raised erythematous tender lesions on her shins. This is a classical appearance of erythema nodosum, which is a delayed-type

hypersensitivity reaction, causing inflammation of the subcutaneous fat. Lesions are most common on the shins, but may also be found on the thighs, buttocks, or forearms. Erythema nodosum is more common in women than in men. There are numerous potential triggers for erythema nodosum, which can be broadly grouped into infectious, inflammatory, drug, or malignancy. In many cases, a specific trigger is never found.

The correct answer is **Streptococcal throat infection**. The most common trigger for erythema nodosum is a preceding infection with a beta-haemolytic Streptococcus, which is usually pharyngitis caused by *Streptococcus pyogenes* (Group A Strep). It is thought that 25-45% of all cases of erythema nodosum are due to Streptococcal throat infections.

**Epstein Barr virus** is incorrect. This virus is the causative agent of infectious mononucleosis. It can trigger EN but it is a less common cause than Streptococcal infections and accounts for <1% of cases.

***Haemophilus influenzae*** is incorrect. This is a common cause of upper respiratory tract infections but has no significant association with erythema nodosum.

**Sarcoidosis** is incorrect. Sarcoidosis is associated with around 10-25% of cases of EN, which is less than Streptococcal throat infections.

**Tuberculosis** is incorrect. TB and other mycobacteria can be associated with EN but the association is much less frequent than with Streptococcal infection.



## Erythema nodosum

Overview

- inflammation of subcutaneous fat
- typically causes tender, erythematous, nodular lesions
- usually occurs over shins, may also occur elsewhere (e.g. forearms, thighs)
- usually resolves within 6 weeks
- lesions heal without scarring

Causes

- infection
    - streptococci

    - tuberculosis
    - brucellosis
- systemic disease
    - sarcoidosis
    - inflammatory bowel disease
    - Behcet's
- malignancy/lymphoma
- drugs
    - penicillins
    - sulphonamides
    - combined oral contraceptive pill
- pregnancy

123

Next question

## Textbooks

High-yield textbook

Extended textbook

## Links

DermNet NZ

Erythema nodosum

30 14

Suggest link

Report broken link

Score: **17%**

| | |
|---|---|
| 1 | ✗ |
| 2 | ✗ |
| 3 | ✓ |
| 4 | ✗ |
| 5 | ✗ |
| 6 | ✗ |
| 7 | ✗ |
| 8 | ✗ |
| 9 | ✗ |
| 10 | ✗ |
| 11 | ✓ |
| 12 | ✗ |
| 13 | ✓ |
| 14 | ✗ |
| 15 | ✗ |
| 16 | ✗ |
| 17 | ✗ |
| 18 | ✗ |
| 19 | ✗ |
| 20 | ✗ |

21 ✗
22 ✗
23 ✗
24 ✗
25 ✗
26 ✓
27 ✗
28 ✗
29 ✗
30 ✗
31 ✗
32 ✓
33 ✗
34 ✗
35 ✗
36 ✗
37 ✗
38 ✗
39 ✗
40 ✗
41 ✗
42 ✗
43 ✗
44 ✓
45 ✗
46 ✗
47 ✓
48 ✗
49 ✗
50 ✗
51 ✗
52 ✗
53 ✗
54 ✗
55 ✗
56 ✗

| | |
|---|---|
| 57 | ✗ |
| **58** | ✗ |
| 59 | ✗ |
| 60 | ✗ |
| 61 | ✗ |
| 62 | ✓ |
| 63 | ✗ |
| 64 | ✗ |
| 65 | ✓ |
| 66 | ✗ |
| 67 | ✗ |
| 68 | ✗ |
| 69 | ✓ |
| 70 | ✓ |
| 71 | ✗ |
| 72 | ✗ |
| 73 | ✗ |
| 74 | ✓ |
| 75 | ✗ |
| 76 | ✗ |
| 77 | ✗ |
| 78 | ✗ |
| 79 | - |
| 80 | ✓ |
| 81 | ✗ |
| 82 | ✗ |
| 83 | ✗ |
| 84 | ✗ |
| 85 | ✗ |
| 86 | ✗ |
| 87 | ✗ |
| 88 | ✓ |
| 89 | ✓ |
| 90 | ✗ |
| 91 | ✗ |
| 92 | ✗ |

| | |
|---|---|
| 93 | ✗ |
| 94 | ✓ |
| 95 | ✗ |
| 96 | ✗ |
| 97 | ✗ |
| 98 | ✗ |
| 99 | ✓ |
| 100 | ✗ |
| 101 | ✗ |

All contents of this site are © 2024 Passmedicine Limited

A 74-year-old man is admitted with an infective exacerbation of chronic obstructive pulmonary disease. Whilst auscultating his chest you notice a number of lesions on his back:

© Image used on license from DermNet NZ

What is the most likely diagnosis?

- Bowen's disease
- Multiple benign moles
- Metastatic malignant melanoma
- Seborrhoeic keratoses
- Dysplastic naevus syndrome

Submit answer

Reference ranges

Score: **14%**

| | |
|---|---|
| 1 | ✗ |
| 2 | ✗ |
| 3 | ✓ |
| 4 | ✗ |
| 5 | ✗ |
| 6 | ✗ |
| 7 | ✗ |
| 8 | ✗ |
| 9 | ✗ |
| 10 | ✗ |
| 11 | ✓ |
| 12 | ✗ |
| 13 | ✓ |
| 14 | ✗ |
| 15 | ✗ |
| 16 | ✗ |
| 17 | ✗ |
| 18 | ✗ |
| 19 | ✗ |
| 20 | ✗ |
| 21 | ✗ |
| 22 | ✗ |
| 23 | ✗ |
| 24 | ✗ |
| 25 | ✗ |
| 26 | ✓ |
| 27 | ✗ |
| 28 | ✗ |
| 29 | ✗ |
| 30 | ✗ |
| 31 | ✗ |
| 32 | ✓ |
| 33 | ✗ |

| | |
|---|---|
| 34 | ✗ |
| 35 | ✗ |
| 36 | ✗ |
| 37 | ✗ |
| 38 | ✗ |
| 39 | ✗ |
| 40 | ✗ |
| 41 | ✗ |
| 42 | ✗ |
| 43 | ✗ |
| 44 | ✓ |
| 45 | ✗ |
| 46 | ✗ |
| 47 | ✓ |
| 48 | ✗ |
| 49 | ✗ |
| 50 | ✗ |
| 51 | - |
| 52 | - |
| 53 | - |
| 54 | - |
| 55 | - |
| 56 | - |
| 57 | - |
| 58 | - |
| **59** | - |

All contents of this site are © 2024 Passmedicine Limited

Back to top

A 74-year-old man is admitted with an infective exacerbation of chronic obstructive pulmonary disease. Whilst auscultating his chest you notice a number of lesions on his back:

© Image used on license from DermNet NZ

What is the most likely diagnosis?

| | |
|---|---|
| Bowen's disease | 5% |
| Multiple benign moles | 4% |
| Metastatic malignant melanoma | 2% |
| Seborrhoeic keratoses | 80% |
| Dysplastic naevus syndrome | 10% |

This man has multiple seborrhoeic keratoses, also known as basal cell papillomas.

Discuss (2) Improve

Next question

# Seborrhoeic keratoses

Seborrhoeic keratoses are benign epidermal skin lesions seen in older people.

Features
- large variation in colour from flesh to light-brown to black
- have a 'stuck-on' appearance
- keratotic plugs may be seen on the surface

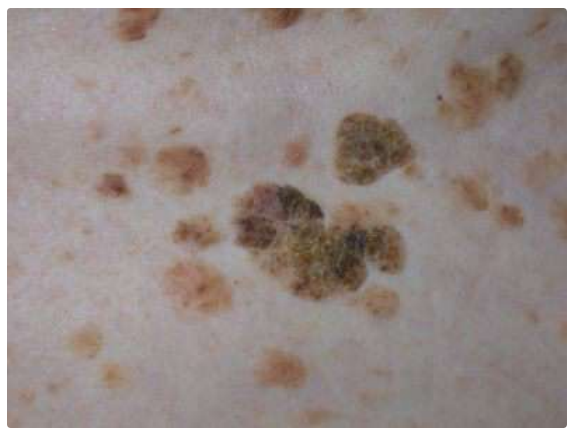

Management
- reassurance about the benign nature of the lesion is an option
- options for removal include curettage, cryosurgery and shave biopsy



**Textbooks**

High-yield textbook

Extended textbook

**Links**

DermNet NZ

5 5

Seborrhoeic keratoses

Suggest link Report broken link

Score: **17%**

| | |
|---|---|
| 1 | ✗ |
| 2 | ✗ |
| 3 | ✓ |
| 4 | ✗ |
| 5 | ✗ |
| 6 | ✗ |
| 7 | ✗ |
| 8 | ✗ |
| 9 | ✗ |
| 10 | ✗ |
| 11 | ✓ |
| 12 | ✗ |
| 13 | ✓ |
| 14 | ✗ |
| 15 | ✗ |
| 16 | ✗ |
| 17 | ✗ |
| 18 | ✗ |
| 19 | ✗ |
| 20 | ✗ |
| 21 | ✗ |
| 22 | ✗ |
| 23 | ✗ |
| 24 | ✗ |
| 25 | ✗ |
| 26 | ✓ |
| 27 | ✗ |

| | |
|---|---|
| 28 | ✗ |
| 29 | ✗ |
| 30 | ✗ |
| 31 | ✗ |
| 32 | ✓ |
| 33 | ✗ |
| 34 | ✗ |
| 35 | ✗ |
| 36 | ✗ |
| 37 | ✗ |
| 38 | ✗ |
| 39 | ✗ |
| 40 | ✗ |
| 41 | ✗ |
| 42 | ✗ |
| 43 | ✗ |
| 44 | ✓ |
| 45 | ✗ |
| 46 | ✗ |
| 47 | ✓ |
| 48 | ✗ |
| 49 | ✗ |
| 50 | ✗ |
| 51 | ✗ |
| 52 | ✗ |
| 53 | ✗ |
| 54 | ✗ |
| 55 | ✗ |
| 56 | ✗ |
| 57 | ✗ |
| 58 | ✗ |
| **59** | ✗ |
| 60 | ✗ |
| 61 | ✗ |
| 62 | ✓ |
| 63 | ✗ |

| | |
|---|---|
| 64 | ✗ |
| 65 | ✓ |
| 66 | ✗ |
| 67 | ✗ |
| 68 | ✗ |
| 69 | ✓ |
| 70 | ✓ |
| 71 | ✗ |
| 72 | ✗ |
| 73 | ✗ |
| 74 | ✓ |
| 75 | ✗ |
| 76 | ✗ |
| 77 | ✗ |
| 78 | ✗ |
| 79 | - |
| 80 | ✓ |
| 81 | ✗ |
| 82 | ✗ |
| 83 | ✗ |
| 84 | ✗ |
| 85 | ✗ |
| 86 | ✗ |
| 87 | ✗ |
| 88 | ✓ |
| 89 | ✓ |
| 90 | ✗ |
| 91 | ✗ |
| 92 | ✗ |
| 93 | ✗ |
| 94 | ✓ |
| 95 | ✗ |
| 96 | ✗ |
| 97 | ✗ |
| 98 | ✗ |
| 99 | ✓ |

100 ✕
101 ✕

All contents of this site are © 2024 Passmedicine Limited

Please look at the skin lesion shown below:

© Image used on license from DermNet NZ

Which one of the following statements regarding this type of skin lesion is true?

- Curettage is an acceptable treatment option
- They exhibit the Koebner phenomenon
- They typically grow rapidly
- Bleeding is unusual
- Metastases are present in 10% of patients at the time of diagnosis

Submit answer

Reference ranges

Score: **14%**

| | |
|---|---|
| 1 | ✗ |
| 2 | ✗ |
| 3 | ✓ |
| 4 | ✗ |
| 5 | ✗ |
| 6 | ✗ |
| 7 | ✗ |
| 8 | ✗ |
| 9 | ✗ |
| 10 | ✗ |
| 11 | ✓ |
| 12 | ✗ |
| 13 | ✓ |
| 14 | ✗ |
| 15 | ✗ |
| 16 | ✗ |
| 17 | ✗ |
| 18 | ✗ |
| 19 | ✗ |
| 20 | ✗ |
| 21 | ✗ |
| 22 | ✗ |
| 23 | ✗ |
| 24 | ✗ |
| 25 | ✗ |
| 26 | ✓ |
| 27 | ✗ |
| 28 | ✗ |
| 29 | ✗ |
| 30 | ✗ |

| | |
|---|---|
| 31 | ✗ |
| 32 | ✓ |
| 33 | ✗ |
| 34 | ✗ |
| 35 | ✗ |
| 36 | ✗ |
| 37 | ✗ |
| 38 | ✗ |
| 39 | ✗ |
| 40 | ✗ |
| 41 | ✗ |
| 42 | ✗ |
| 43 | ✗ |
| 44 | ✓ |
| 45 | ✗ |
| 46 | ✗ |
| 47 | ✓ |
| 48 | ✗ |
| 49 | ✗ |
| 50 | ✗ |
| 51 | - |
| 52 | - |
| 53 | - |
| 54 | - |
| 55 | - |
| 56 | - |
| 57 | - |
| 58 | - |
| 59 | - |
| **60** | - |

All contents of this site are © 2024 Passmedicine Limited

Please look at the skin lesion shown below:

© Image used on license from DermNet NZ

Which one of the following statements regarding this type of skin lesion is true?

- Curettage is an acceptable treatment option — 37%
- They exhibit the Koebner phenomenon — 11%
- They typically grow rapidly — 13%
- Bleeding is unusual — 19%
- Metastases are present in 10% of patients at the time of diagnosis — 19%

Discuss (3) Improve

Next question

# Basal cell carcinoma

Basal cell carcinoma (BCC) is one of the three main types of skin cancer. Lesions are also known as rodent ulcers and are characterised by slow-growth and local invasion. Metastases are extremely rare. BCC is the most common type of cancer in the Western world.

Features

- many types of BCC are described. The most common type is nodular BCC, which is described here
- sun-exposed sites, especially the head and neck account for the majority of lesions
- initially a pearly, flesh-coloured papule with telangiectasia
- may later ulcerate leaving a central 'crater'

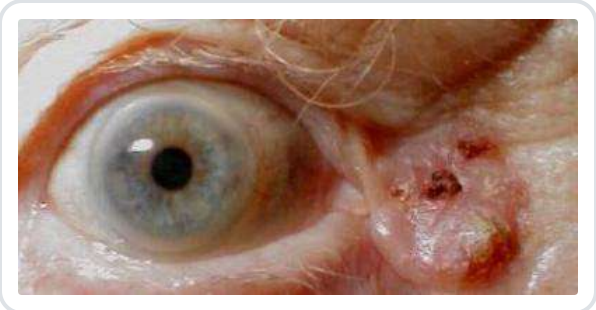

Referral

- generally, if a BCC is suspected, a routine referral should be made

Management options:

- surgical removal
- curettage
- cryotherapy
- topical cream: imiquimod, fluorouracil
- radiotherapy

Next question

## Textbooks

High-yield textbook

Extended textbook

## Links

DermNet NZ 21 7

Basal cell carcinoma

Suggest link Report broken link

## Media

Skin cancers

Osmosis - YouTube 4 2

Report broken media

Score: **17%**

1 ×

| | |
|---|---|
| 2 | ✗ |
| 3 | ✓ |
| 4 | ✗ |
| 5 | ✗ |
| 6 | ✗ |
| 7 | ✗ |
| 8 | ✗ |
| 9 | ✗ |
| 10 | ✗ |
| 11 | ✓ |
| 12 | ✗ |
| 13 | ✓ |
| 14 | ✗ |
| 15 | ✗ |
| 16 | ✗ |
| 17 | ✗ |
| 18 | ✗ |
| 19 | ✗ |
| 20 | ✗ |
| 21 | ✗ |
| 22 | ✗ |
| 23 | ✗ |
| 24 | ✗ |
| 25 | ✗ |
| 26 | ✓ |
| 27 | ✗ |
| 28 | ✗ |
| 29 | ✗ |
| 30 | ✗ |
| 31 | ✗ |
| 32 | ✓ |
| 33 | ✗ |
| 34 | ✗ |
| 35 | ✗ |
| 36 | ✗ |
| 37 | ✗ |

| | |
|---|---|
| 38 | ✗ |
| 39 | ✗ |
| 40 | ✗ |
| 41 | ✗ |
| 42 | ✗ |
| 43 | ✗ |
| 44 | ✓ |
| 45 | ✗ |
| 46 | ✗ |
| 47 | ✓ |
| 48 | ✗ |
| 49 | ✗ |
| 50 | ✗ |
| 51 | ✗ |
| 52 | ✗ |
| 53 | ✗ |
| 54 | ✗ |
| 55 | ✗ |
| 56 | ✗ |
| 57 | ✗ |
| 58 | ✗ |
| 59 | ✗ |
| **60** | ✗ |
| 61 | ✗ |
| 62 | ✓ |
| 63 | ✗ |
| 64 | ✗ |
| 65 | ✓ |
| 66 | ✗ |
| 67 | ✗ |
| 68 | ✗ |
| 69 | ✓ |
| 70 | ✓ |
| 71 | ✗ |
| 72 | ✗ |
| 73 | ✗ |

| | |
|---|---|
| 74 | ✓ |
| 75 | ✗ |
| 76 | ✗ |
| 77 | ✗ |
| 78 | ✗ |
| 79 | - |
| 80 | ✓ |
| 81 | ✗ |
| 82 | ✗ |
| 83 | ✗ |
| 84 | ✗ |
| 85 | ✗ |
| 86 | ✗ |
| 87 | ✗ |
| 88 | ✓ |
| 89 | ✓ |
| 90 | ✗ |
| 91 | ✗ |
| 92 | ✗ |
| 93 | ✗ |
| 94 | ✓ |
| 95 | ✗ |
| 96 | ✗ |
| 97 | ✗ |
| 98 | ✗ |
| 99 | ✓ |
| 100 | ✗ |
| 101 | ✗ |

All contents of this site are © 2024 Passmedicine Limited

Back to top

A 60-year-old homeless female is brought to the emergency department intoxicated. You note from her medical records she had diabetes mellitus only. You also note that her blood glucose levels are frequently high on attendances.

Her examination, other than the intoxication, is normal and observations are all within normal range except a slightly raised blood glucose.

After a few hours she beginnings to sober up and is preparing to leave the department. Prior to leaving, she asks you to have a look at the rash on the back of her hands (see below). She reports she has similar, mildly itchy rashes on her elbows and the dorsal of her feet.

© Image used on license from DermNet NZ

What is the most likely diagnosis?

- Dermatitis herpetiformis
- Erythema migrans
- Granuloma annulare
- Necrobiosis lipoidica
- Scabies

Submit answer

Reference ranges

Score: **14%**

| | |
|---|---|
| 1 | ✗ |
| 2 | ✗ |
| 3 | ✓ |
| 4 | ✗ |
| 5 | ✗ |
| 6 | ✗ |
| 7 | ✗ |
| 8 | ✗ |
| 9 | ✗ |
| 10 | ✗ |
| 11 | ✓ |
| 12 | ✗ |
| 13 | ✓ |
| 14 | ✗ |
| 15 | ✗ |
| 16 | ✗ |
| 17 | ✗ |
| 18 | ✗ |
| 19 | ✗ |
| 20 | ✗ |
| 21 | ✗ |
| 22 | ✗ |
| 23 | ✗ |
| 24 | ✗ |
| 25 | ✗ |
| 26 | ✓ |

| | |
|---|---|
| 27 | ✗ |
| 28 | ✗ |
| 29 | ✗ |
| 30 | ✗ |
| 31 | ✗ |
| 32 | ✓ |
| 33 | ✗ |
| 34 | ✗ |
| 35 | ✗ |
| 36 | ✗ |
| 37 | ✗ |
| 38 | ✗ |
| 39 | ✗ |
| 40 | ✗ |
| 41 | ✗ |
| 42 | ✗ |
| 43 | ✗ |
| 44 | ✓ |
| 45 | ✗ |
| 46 | ✗ |
| 47 | ✓ |
| 48 | ✗ |
| 49 | ✗ |
| 50 | ✗ |
| 51 | - |
| 52 | - |
| 53 | - |
| 54 | - |
| 55 | - |
| 56 | - |
| 57 | - |
| 58 | - |
| 59 | - |
| 60 | - |
| **61** | - |

All contents of this site are © 2024 Passmedicine Limited

A 60-year-old homeless female is brought to the emergency department intoxicated. You note from her medical records she had diabetes mellitus only. You also note that her blood glucose levels are frequently high on attendances.

Her examination, other than the intoxication, is normal and observations are all within normal range except a slightly raised blood glucose.

After a few hours she beginnings to sober up and is preparing to leave the department. Prior to leaving, she asks you to have a look at the rash on the back of her hands (see below). She reports she has similar, mildly itchy rashes on her elbows and the dorsal of her feet.

© Image used on license from DermNet NZ

What is the most likely diagnosis?

| | |
|---|---|
| Dermatitis herpetiformis | 19% |
| Erythema migrans | 6% |
| Granuloma annulare | 42% |
| Necrobiosis lipoidica | 16% |
| Scabies | 18% |

Granuloma annulare is a papular rash often with slightly hyperpigmented lesions which have

depressed centres. They are commonly found on the dorsal surfaces of the hands and feet as well as the elbows and knees. The lesions are sometimes mildly itchy and are through to be due to clustering of T cells below the skin. Granuloma annulare is 4x more prevalent in females and is thought to be linked to diabetes but there is limited evidence to confirm this.

Dermatitis herpetiformis is a cutaneous manifestation of coeliac disease, characterised by an intensely itchy, papulovesicular like rash, with blisters filled with watery fluid. The rash is similar in appears to a herpes rash (hence the name) and is normal found on the trunk.

Erythema migrans is an expanding erythematous plaque with central clearing, creating a 'bull's eye/target' like rash, often associated with the early stages of Lyme disease. The skin lesions occur at the site of a tick bite, normal around skin folds or on the trunk, and as such patient's common present following outdoor activities in a woodland area.

Necrobiosis lipoidica is a dermatological feature of a few conditions but is most commonly associated with diabetes. It presents as an initially asymptomatic, necrotising rash normally found on the shins which can become tender and ulcerate when injured.

Scabies is an intensely itchy, rash with associated small burrow lesions, caused by the mite *Sarcoptes scabiei*. The rash is normally found in the finger webs but also around the feet, ventral wrists, elbows, trunk, and external genitals.

Discuss (1) Improve

Next question

## Granuloma annulare

Basics

- papular lesions that are often slightly hyperpigmented and depressed centrally
- typically occur on the dorsal surfaces of the hands and feet, and on the extensor aspects of the arms and legs

A number of associations have been proposed to conditions such as diabetes mellitus but there is only weak evidence for this

123

Next question

## Textbooks

High-yield textbook

Extended textbook

## Links

DermNet NZ

Granuloma annulare

16 7

Suggest link

Report broken link

Score: **17%**

| | |
|---|---|
| 1 | ✗ |
| 2 | ✗ |
| 3 | ✓ |
| 4 | ✗ |
| 5 | ✗ |
| 6 | ✗ |
| 7 | ✗ |
| 8 | ✗ |

| | |
|---|---|
| 9 | ✗ |
| 10 | ✗ |
| 11 | ✓ |
| 12 | ✗ |
| 13 | ✓ |
| 14 | ✗ |
| 15 | ✗ |
| 16 | ✗ |
| 17 | ✗ |
| 18 | ✗ |
| 19 | ✗ |
| 20 | ✗ |
| 21 | ✗ |
| 22 | ✗ |
| 23 | ✗ |
| 24 | ✗ |
| 25 | ✗ |
| 26 | ✓ |
| 27 | ✗ |
| 28 | ✗ |
| 29 | ✗ |
| 30 | ✗ |
| 31 | ✗ |
| 32 | ✓ |
| 33 | ✗ |
| 34 | ✗ |
| 35 | ✗ |
| 36 | ✗ |
| 37 | ✗ |
| 38 | ✗ |
| 39 | ✗ |
| 40 | ✗ |
| 41 | ✗ |
| 42 | ✗ |
| 43 | ✗ |
| 44 | ✓ |

| | |
|---|---|
| 45 | ✗ |
| 46 | ✗ |
| 47 | ✓ |
| 48 | ✗ |
| 49 | ✗ |
| 50 | ✗ |
| 51 | ✗ |
| 52 | ✗ |
| 53 | ✗ |
| 54 | ✗ |
| 55 | ✗ |
| 56 | ✗ |
| 57 | ✗ |
| 58 | ✗ |
| 59 | ✗ |
| 60 | ✗ |
| **61** | ✗ |
| 62 | ✓ |
| 63 | ✗ |
| 64 | ✗ |
| 65 | ✓ |
| 66 | ✗ |
| 67 | ✗ |
| 68 | ✗ |
| 69 | ✓ |
| 70 | ✓ |
| 71 | ✗ |
| 72 | ✗ |
| 73 | ✗ |
| 74 | ✓ |
| 75 | ✗ |
| 76 | ✗ |
| 77 | ✗ |
| 78 | ✗ |
| 79 | - |
| 80 | ✓ |

| | |
|---|---|
| 81 | ✗ |
| 82 | ✗ |
| 83 | ✗ |
| 84 | ✗ |
| 85 | ✗ |
| 86 | ✗ |
| 87 | ✗ |
| 88 | ✓ |
| 89 | ✓ |
| 90 | ✗ |
| 91 | ✗ |
| 92 | ✗ |
| 93 | ✗ |
| 94 | ✓ |
| 95 | ✗ |
| 96 | ✗ |
| 97 | ✗ |
| 98 | ✗ |
| 99 | ✓ |
| 100 | ✗ |
| 101 | ✗ |

All contents of this site are © 2024 Passmedicine Limited

Back to top

A 56-year-old woman develops a rash in both axilla:

© Image used on license from DermNet NZ

What is the most likely diagnosis?

- Pellagra
- Erythema gyratum repens
- Hidradenitis suppurativa
- Tinea corporis
- Acanthosis nigricans

Submit answer

Reference ranges

Score: **14%**

| | |
|---|---|
| 1 | ✗ |
| 2 | ✗ |
| 3 | ✓ |
| 4 | ✗ |
| 5 | ✗ |
| 6 | ✗ |
| 7 | ✗ |
| 8 | ✗ |
| 9 | ✗ |
| 10 | ✗ |
| 11 | ✓ |
| 12 | ✗ |
| 13 | ✓ |
| 14 | ✗ |
| 15 | ✗ |
| 16 | ✗ |
| 17 | ✗ |
| 18 | ✗ |
| 19 | ✗ |
| 20 | ✗ |
| 21 | ✗ |
| 22 | ✗ |
| 23 | ✗ |
| 24 | ✗ |
| 25 | ✗ |
| 26 | ✓ |
| 27 | ✗ |
| 28 | ✗ |
| 29 | ✗ |
| 30 | ✗ |
| 31 | ✗ |
| 32 | ✓ |
| 33 | ✗ |
| 34 | ✗ |

| | |
|---|---|
| 35 | ✗ |
| 36 | ✗ |
| 37 | ✗ |
| 38 | ✗ |
| 39 | ✗ |
| 40 | ✗ |
| 41 | ✗ |
| 42 | ✗ |
| 43 | ✗ |
| 44 | ✓ |
| 45 | ✗ |
| 46 | ✗ |
| 47 | ✓ |
| 48 | ✗ |
| 49 | ✗ |
| 50 | ✗ |
| 51 | - |
| 52 | - |
| 53 | - |
| 54 | - |
| 55 | - |
| 56 | - |
| 57 | - |
| 58 | - |
| 59 | - |
| 60 | - |
| 61 | - |
| **62** | - |

All contents of this site are © 2024 Passmedicine Limited

A 56-year-old woman develops a rash in both axilla:

© Image used on license from DermNet NZ

What is the most likely diagnosis?

| | |
|---|---|
| Pellagra | 1% |
| Erythema gyratum repens | 2% |
| Hidradenitis suppurativa | 8% |
| Tinea corporis | 2% |
| Acanthosis nigricans | 87% |

The correct answer is **Acanthosis nigricans**. Acanthosis nigricans is a skin condition characterised by dark, thickened patches of skin that can appear in various parts of the body including the axilla. The image shows a velvety, hyperpigmented rash which is typical of acanthosis nigricans. It's often associated with insulin resistance and can be an early sign of type 2 diabetes.

**Pellagra** is incorrect because it typically presents with the 'three Ds': dermatitis, dementia, and diarrhoea. The dermatitis caused by pellagra usually occurs on areas exposed to sunlight and takes on a symmetrical, butterfly-shaped appearance on the face. It does not typically present as

darkened patches in the axilla.

**Erythema gyratum repens** is also incorrect. This condition produces concentric circles or waves of erythema that migrate across the skin surface, giving it a wood-grain appearance. These patterns are not visible in the provided image.

**Hidradenitis suppurativa** would be an incorrect choice as well because this chronic inflammatory skin condition causes painful lumps under the skin. These lumps or abscesses occur near hair follicles where many oil and sweat glands are found such as in the armpits or groin area. However, they do not resemble the darkened patches seen in this patient's axillae.

Lastly, **Tinea corporis** (ringworm) is also an incorrect option. Tinea corporis presents with circular rashes with raised borders that expand over time - often leaving clear or normal-looking skin in the centre which gives it a ring-like appearance hence its common name 'ringworm'. This pattern cannot be seen in this image either.

Discuss | Improve

Next question

## Acanthosis nigricans

Describes symmetrical, brown, velvety plaques that are often found on the neck, axilla and groin.

Causes
- type 2 diabetes mellitus
- gastrointestinal cancer
- obesity
- polycystic ovarian syndrome
- acromegaly
- Cushing's disease
- hypothyroidism
- familial
- Prader-Willi syndrome
- drugs
  - combined oral contraceptive pill
  - nicotinic acid

Pathophysiology

- insulin resistance → hyperinsulinemia → stimulation of keratinocytes and dermal fibroblast proliferation via interaction with insulin-like growth factor receptor-1 (IGFR1)

123

Next question

### Textbooks

High-yield textbook

Extended textbook

### Links

DermNet NZ 54 21

Acanthosis nigricans

Suggest link Report broken link

Score: **17%**

| | |
|---|---|
| 1 | ✗ |
| 2 | ✗ |
| 3 | ✓ |
| 4 | ✗ |
| 5 | ✗ |
| 6 | ✗ |
| 7 | ✗ |
| 8 | ✗ |
| 9 | ✗ |
| 10 | ✗ |
| 11 | ✓ |
| 12 | ✗ |
| 13 | ✓ |
| 14 | ✗ |
| 15 | ✗ |
| 16 | ✗ |
| 17 | ✗ |
| 18 | ✗ |
| 19 | ✗ |
| 20 | ✗ |
| 21 | ✗ |
| 22 | ✗ |
| 23 | ✗ |
| 24 | ✗ |
| 25 | ✗ |
| 26 | ✓ |
| 27 | ✗ |
| 28 | ✗ |
| 29 | ✗ |
| 30 | ✗ |
| 31 | ✗ |
| 32 | ✓ |
| 33 | ✗ |
| 34 | ✗ |
| 35 | ✗ |

| | |
|---|---|
| 36 | ✗ |
| 37 | ✗ |
| 38 | ✗ |
| 39 | ✗ |
| 40 | ✗ |
| 41 | ✗ |
| 42 | ✗ |
| 43 | ✗ |
| 44 | ✓ |
| 45 | ✗ |
| 46 | ✗ |
| 47 | ✓ |
| 48 | ✗ |
| 49 | ✗ |
| 50 | ✗ |
| 51 | ✗ |
| 52 | ✗ |
| 53 | ✗ |
| 54 | ✗ |
| 55 | ✗ |
| 56 | ✗ |
| 57 | ✗ |
| 58 | ✗ |
| 59 | ✗ |
| 60 | ✗ |
| 61 | ✗ |
| **62** | ✓ |
| 63 | ✗ |
| 64 | ✗ |
| 65 | ✓ |
| 66 | ✗ |
| 67 | ✗ |
| 68 | ✗ |
| 69 | ✓ |
| 70 | ✓ |
| 71 | ✗ |

| | |
|---|---|
| 72 | ✗ |
| 73 | ✗ |
| 74 | ✓ |
| 75 | ✗ |
| 76 | ✗ |
| 77 | ✗ |
| 78 | ✗ |
| 79 | - |
| 80 | ✓ |
| 81 | ✗ |
| 82 | ✗ |
| 83 | ✗ |
| 84 | ✗ |
| 85 | ✗ |
| 86 | ✗ |
| 87 | ✗ |
| 88 | ✓ |
| 89 | ✓ |
| 90 | ✗ |
| 91 | ✗ |
| 92 | ✗ |
| 93 | ✗ |
| 94 | ✓ |
| 95 | ✗ |
| 96 | ✗ |
| 97 | ✗ |
| 98 | ✗ |
| 99 | ✓ |
| 100 | ✗ |
| 101 | ✗ |

All contents of this site are © 2024 Passmedicine Limited

Back to top

A 60-year-old man has been an inpatient in a general medical ward for 2 weeks. He presented with a 10-day history of fever and malaise. He developed lesions on his lower legs the day before his admission. Despite the administration of broad-spectrum antibiotics since admission, he is continuing to have temperatures greater than 38ºC on a daily basis. The rest of his observations remain stable.

On examination, his skin appears as shown below:

© Image used on license from DermNet NZ

Blood tests are taken with the following results:

| | | |
|---|---|---|
| Hb | 108 g/L | Male: (135-180)<br>Female: (115 - 160) |
| Platelets | 114 * $10^9$/L | (150 - 400) |
| WBC | 14.5 * $10^9$/L | (4.0 - 11.0) |
| $Na^+$ | 138 mmol/L | (135 - 145) |
| $K^+$ | 4.2 mmol/L | (3.5 - 5.0) |
| Urea | 9.5 mmol/L | (2.0 - 7.0) |
| Creatinine | 145 µmol/L | (55 - 120) |
| CRP | 120 mg/L | (< 5) |

What is the most likely cause for this patient's skin changes?

- Drug reaction
- Haemolytic uraemic syndrome
- Kaposi's sarcoma
- Small vessel vasculitis
- Thrombocytopenia

Submit answer

Reference ranges

Score: **14%**

| | |
|---|---|
| 1 | ✗ |
| 2 | ✗ |
| 3 | ✓ |
| 4 | ✗ |
| 5 | ✗ |
| 6 | ✗ |
| 7 | ✗ |
| 8 | ✗ |
| 9 | ✗ |
| 10 | ✗ |
| 11 | ✓ |
| 12 | ✗ |
| 13 | ✓ |
| 14 | ✗ |
| 15 | ✗ |
| 16 | ✗ |

| | |
|---|---|
| 17 | ✗ |
| 18 | ✗ |
| 19 | ✗ |
| 20 | ✗ |
| 21 | ✗ |
| 22 | ✗ |
| 23 | ✗ |
| 24 | ✗ |
| 25 | ✗ |
| 26 | ✓ |
| 27 | ✗ |
| 28 | ✗ |
| 29 | ✗ |
| 30 | ✗ |
| 31 | ✗ |
| 32 | ✓ |
| 33 | ✗ |
| 34 | ✗ |
| 35 | ✗ |
| 36 | ✗ |
| 37 | ✗ |
| 38 | ✗ |
| 39 | ✗ |
| 40 | ✗ |
| 41 | ✗ |
| 42 | ✗ |
| 43 | ✗ |
| 44 | ✓ |
| 45 | ✗ |
| 46 | ✗ |
| 47 | ✓ |
| 48 | ✗ |
| 49 | ✗ |
| 50 | ✗ |
| 51 | - |
| 52 | - |

53 -
54 -
55 -
56 -
57 -
58 -
59 -
60 -
61 -
62 -
**63** -
64 -

All contents of this site are © 2024 Passmedicine Limited

A 60-year-old man has been an inpatient in a general medical ward for 2 weeks. He presented with a 10-day history of fever and malaise. He developed lesions on his lower legs the day before his admission. Despite the administration of broad-spectrum antibiotics since admission, he is continuing to have temperatures greater than 38ºC on a daily basis. The rest of his observations remain stable.

On examination, his skin appears as shown below:

© Image used on license from DermNet NZ

Blood tests are taken with the following results:

| | | |
|---|---|---|
| Hb | 108 g/L | Male: (135-180)<br>Female: (115 - 160) |
| Platelets | 114 * $10^9$/L | (150 - 400) |
| WBC | 14.5 * $10^9$/L | (4.0 - 11.0) |
| $Na^+$ | 138 mmol/L | (135 - 145) |
| $K^+$ | 4.2 mmol/L | (3.5 - 5.0) |
| Urea | 9.5 mmol/L | (2.0 - 7.0) |
| Creatinine | 145 µmol/L | (55 - 120) |
| CRP | 120 mg/L | (< 5) |

What is the most likely cause for this patient's skin changes?

| Option | % |
|---|---|
| Drug reaction | 6% |
| Haemolytic uraemic syndrome | 22% |
| Kaposi's sarcoma | 11% |
| Small vessel vasculitis | 59% |
| Thrombocytopenia | 3% |

The image shows a number of petechial and purpuric lesions of different sizes on the lower legs. This is a classic cutaneous presentation of the small vessel vasculitides, which can cause inflammation of the blood vessels in the skin, as well as elsewhere in the body.

The correct answer is **small vessel vasculitis** . This is a group of conditions, including ANCA-associated vasculitides, cryoglobulinaemia and Henoch-Schonlein purpura. They may often present with non-specific symptoms, including as pyrexia of unknown origin as in this scenario. The raised creatinine also points to a systemic condition.

**Drug reaction** is incorrect. Skin manifestations of drug reactions are varied, and drug-induced small vessel vasculitis can occasionally occur but this is rare. The patient also developed the lesions before his admission to the hospital, making a drug reaction less likely. This would also not explain the rest of his symptoms.

**Kaposi's sarcoma** is incorrect. This condition causes red to purplish lesions on the skin, but they tend to be solitary or few in number in the early stages, and would not be on a background of numerous small lesions as in this image. The progression of lesions also tends to be much slower than in this patient.

**Haemolytic uraemic syndrome (HUS)** is incorrect. This condition can cause a purpuric rash due to thrombocytopenia. It is unlikely in this patient as the renal function is only mildly abnormal, thrombocytopenia is mild and there is no clear evidence of haemolytic anaemia. HUS is also much more common in children than in adults. There is also no history of diarrhoea given in this patient, and HUS is usually triggered by infection with a verotoxin-producing strain of *E.coli* causing diarrhoea before the onset of HUS.

**Thrombocytopenia** is incorrect. Low platelets can cause petechiae and purpura due to bleeding into the skin, but this is unlikely with relatively mild thrombocytopenia as in this patient.

Discuss (1) Improve

Next question

# Vasculitides

Large vessel

- temporal arteritis
- Takayasu's arteritis

Medium vessel

- polyarteritis nodosa
- Kawasaki disease

Small vessel

- ANCA-associated vasculitides
  - granulomatosis with polyangiitis (Wegener's granulomatosis)
  - eosinophilic granulomatosis with polyangiitis (Churg-Strauss syndrome)
  - microscopic polyangiitis
- immune complex small-vessel vasculitis
  - Henoch-Schonlein purpura
  - Goodpasture's syndrome (anti-glomerular basement membrane disease)
  - cryoglobulinaemic vasculitis
  - hypocomplementemic urticarial vasculitis (anti-C1q vasculitis)

123

Next question

## Textbooks

High-yield textbook

Extended textbook

## Links

DermNet NZ

4 2

Cutaneous vasculitis

Patient.info

5 0

Vasculitis review

Suggest link

Report broken link

## Media

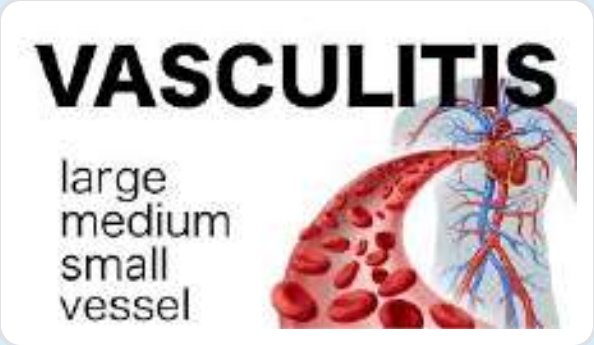


Vasculitis

Dirty USMLE - YouTube 6 0

Vasculitis

Osmosis - YouTube 1 0

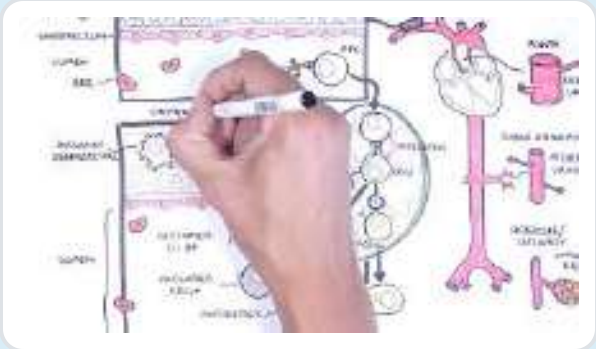

[Vasculitis Pathophysiology Overview]

Armando Hasudungan - YouTube 2 1

Report broken media

Score: **17%**

| | |
|---|---|
| 1 | ✗ |
| 2 | ✗ |
| 3 | ✓ |
| 4 | ✗ |
| 5 | ✗ |
| 6 | ✗ |
| 7 | ✗ |
| 8 | ✗ |
| 9 | ✗ |
| 10 | ✗ |
| 11 | ✓ |
| 12 | ✗ |
| 13 | ✓ |
| 14 | ✗ |
| 15 | ✗ |
| 16 | ✗ |
| 17 | ✗ |
| 18 | ✗ |
| 19 | ✗ |
| 20 | ✗ |
| 21 | ✗ |
| 22 | ✗ |
| 23 | ✗ |
| 24 | ✗ |

| | |
|---|---|
| 25 | ✗ |
| 26 | ✓ |
| 27 | ✗ |
| 28 | ✗ |
| 29 | ✗ |
| 30 | ✗ |
| 31 | ✗ |
| 32 | ✓ |
| 33 | ✗ |
| 34 | ✗ |
| 35 | ✗ |
| 36 | ✗ |
| 37 | ✗ |
| 38 | ✗ |
| 39 | ✗ |
| 40 | ✗ |
| 41 | ✗ |
| 42 | ✗ |
| 43 | ✗ |
| 44 | ✓ |
| 45 | ✗ |
| 46 | ✗ |
| 47 | ✓ |
| 48 | ✗ |
| 49 | ✗ |
| 50 | ✗ |
| 51 | ✗ |
| 52 | ✗ |
| 53 | ✗ |
| 54 | ✗ |
| 55 | ✗ |
| 56 | ✗ |
| 57 | ✗ |
| 58 | ✗ |
| 59 | ✗ |
| 60 | ✗ |

| | |
|---|---|
| 61 | ✗ |
| 62 | ✓ |
| **63** | ✗ |
| 64 | ✗ |
| 65 | ✓ |
| 66 | ✗ |
| 67 | ✗ |
| 68 | ✗ |
| 69 | ✓ |
| 70 | ✓ |
| 71 | ✗ |
| 72 | ✗ |
| 73 | ✗ |
| 74 | ✓ |
| 75 | ✗ |
| 76 | ✗ |
| 77 | ✗ |
| 78 | ✗ |
| 79 | - |
| 80 | ✓ |
| 81 | ✗ |
| 82 | ✗ |
| 83 | ✗ |
| 84 | ✗ |
| 85 | ✗ |
| 86 | ✗ |
| 87 | ✗ |
| 88 | ✓ |
| 89 | ✓ |
| 90 | ✗ |
| 91 | ✗ |
| 92 | ✗ |
| 93 | ✗ |
| 94 | ✓ |
| 95 | ✗ |
| 96 | ✗ |

| | |
|---|---|
| 97 | ✗ |
| 98 | ✗ |
| 99 | ✓ |
| 100 | ✗ |
| 101 | ✗ |

All contents of this site are © 2024 Passmedicine Limited

An elderly man presents with a lesion on his cheek that has got progressively worse over the past year. He asks for it to be removed as it is catching:

© Image used on license from DermNet NZ

What is the most likely diagnosis?

- Nodular malignant melanoma
- Viral wart
- Solar keratosis
- Seborrhoeic keratosis
- Squamous cell carcinoma

Submit answer

Reference ranges

Score: **14%**

| | |
|---|---|
| 1 | ✗ |
| 2 | ✗ |
| 3 | ✓ |
| 4 | ✗ |
| 5 | ✗ |
| 6 | ✗ |
| 7 | ✗ |
| 8 | ✗ |
| 9 | ✗ |
| 10 | ✗ |
| 11 | ✓ |
| 12 | ✗ |
| 13 | ✓ |
| 14 | ✗ |
| 15 | ✗ |
| 16 | ✗ |
| 17 | ✗ |
| 18 | ✗ |
| 19 | ✗ |
| 20 | ✗ |
| 21 | ✗ |
| 22 | ✗ |
| 23 | ✗ |
| 24 | ✗ |
| 25 | ✗ |
| 26 | ✓ |
| 27 | ✗ |
| 28 | ✗ |
| 29 | ✗ |
| 30 | ✗ |
| 31 | ✗ |
| 32 | ✓ |
| 33 | ✗ |

| | |
|---|---|
| 34 | ✗ |
| 35 | ✗ |
| 36 | ✗ |
| 37 | ✗ |
| 38 | ✗ |
| 39 | ✗ |
| 40 | ✗ |
| 41 | ✗ |
| 42 | ✗ |
| 43 | ✗ |
| 44 | ✓ |
| 45 | ✗ |
| 46 | ✗ |
| 47 | ✓ |
| 48 | ✗ |
| 49 | ✗ |
| 50 | ✗ |
| 51 | - |
| 52 | - |
| 53 | - |
| 54 | - |
| 55 | - |
| 56 | - |
| 57 | - |
| 58 | - |
| 59 | - |
| 60 | - |
| 61 | - |
| 62 | - |
| 63 | - |
| **64** | - |

All contents of this site are © 2024 Passmedicine Limited

Back to top

An elderly man presents with a lesion on his cheek that has got progressively worse over the past year. He asks for it to be removed as it is catching:

© Image used on license from DermNet NZ

What is the most likely diagnosis?

| | |
|---|---|
| Nodular malignant melanoma | 12% |
| Viral wart | 5% |
| Solar keratosis | 17% |
| Seborrhoeic keratosis | 22% |
| Squamous cell carcinoma | 45% |

The main differential diagnosis here is keratoacanthoma which are often described as 'mini-volcanos' with a central core filled with keratin.

Discuss (4) Improve

Next question

# Squamous cell carcinoma of the skin

Squamous cell carcinoma is a common variant of skin cancer. Metastases are rare but may occur in 2-5% of patients.

Risk factors include:

- excessive exposure to sunlight / psoralen UVA therapy
- actinic keratoses and Bowen's disease
- immunosuppression e.g. following renal transplant, HIV
- smoking
- long-standing leg ulcers (Marjolin's ulcer)
- genetic conditions e.g. xeroderma pigmentosum, oculocutaneous albinism

Features

- typically on sun-exposed sites such as the head and neck or dorsum of the hands and arms
- rapidly expanding painless, ulcerate nodules
- may have a cauliflower-like appearance
- there may be areas of bleeding

## Image gallery

## Treatment

Surgical excision with 4mm margins if lesion <20mm in diameter. If tumour >20mm then margins should be 6mm. Mohs micrographic surgery may be used in high-risk patients and in cosmetically important sites.

## Prognosis

| Good Prognosis | Poor prognosis |
|---|---|
| Well differentiated tumours | Poorly differentiated tumours |
| <20mm diameter | >20mm in diameter |
| <2mm deep | >4mm deep |
| No associated diseases | Immunosupression for whatever reason |

123

Next question

### Textbooks

High-yield textbook

Extended textbook

### Links

DermNet NZ 28 4

Squamous cell carcinoma

Suggest link Report broken link

### Media

Skin cancers

Osmosis - YouTube 4 1

Report broken media

Score: **17%**

| | |
|---|---|
| 1 | ✗ |
| 2 | ✗ |
| 3 | ✓ |
| 4 | ✗ |
| 5 | ✗ |
| 6 | ✗ |
| 7 | ✗ |
| 8 | ✗ |
| 9 | ✗ |
| 10 | ✗ |
| 11 | ✓ |
| 12 | ✗ |
| 13 | ✓ |
| 14 | ✗ |
| 15 | ✗ |
| 16 | ✗ |
| 17 | ✗ |
| 18 | ✗ |
| 19 | ✗ |
| 20 | ✗ |
| 21 | ✗ |
| 22 | ✗ |
| 23 | ✗ |

| | |
|---|---|
| 24 | ✗ |
| 25 | ✗ |
| 26 | ✓ |
| 27 | ✗ |
| 28 | ✗ |
| 29 | ✗ |
| 30 | ✗ |
| 31 | ✗ |
| 32 | ✓ |
| 33 | ✗ |
| 34 | ✗ |
| 35 | ✗ |
| 36 | ✗ |
| 37 | ✗ |
| 38 | ✗ |
| 39 | ✗ |
| 40 | ✗ |
| 41 | ✗ |
| 42 | ✗ |
| 43 | ✗ |
| 44 | ✓ |
| 45 | ✗ |
| 46 | ✗ |
| 47 | ✓ |
| 48 | ✗ |
| 49 | ✗ |
| 50 | ✗ |
| 51 | ✗ |
| 52 | ✗ |
| 53 | ✗ |
| 54 | ✗ |
| 55 | ✗ |
| 56 | ✗ |
| 57 | ✗ |
| 58 | ✗ |
| 59 | ✗ |

| | |
|---|---|
| 60 | ✗ |
| 61 | ✗ |
| 62 | ✓ |
| 63 | ✗ |
| **64** | ✗ |
| 65 | ✓ |
| 66 | ✗ |
| 67 | ✗ |
| 68 | ✗ |
| 69 | ✓ |
| 70 | ✓ |
| 71 | ✗ |
| 72 | ✗ |
| 73 | ✗ |
| 74 | ✓ |
| 75 | ✗ |
| 76 | ✗ |
| 77 | ✗ |
| 78 | ✗ |
| 79 | - |
| 80 | ✓ |
| 81 | ✗ |
| 82 | ✗ |
| 83 | ✗ |
| 84 | ✗ |
| 85 | ✗ |
| 86 | ✗ |
| 87 | ✗ |
| 88 | ✓ |
| 89 | ✓ |
| 90 | ✗ |
| 91 | ✗ |
| 92 | ✗ |
| 93 | ✗ |
| 94 | ✓ |
| 95 | ✗ |

| | |
|---|---|
| 96 | ✗ |
| 97 | ✗ |
| 98 | ✗ |
| 99 | ✓ |
| 100 | ✗ |
| 101 | ✗ |

All contents of this site are © 2024 Passmedicine Limited
Back to top

A 55-year-old man asks you to have a look at some 'red spots' on his torso. They have been present for about the past six months.

© Image used on license from DermNet NZ

What is the most likely diagnosis?

- Kaposi sarcoma
- Blue rubber bleb naevus syndrome
- Thrombocytopaenia
- Malignant melanoma
- Cherry haemangioma

Submit answer

Reference ranges

Score: **14%**

| | |
|---|---|
| 1 | ✗ |
| 2 | ✗ |
| 3 | ✓ |
| 4 | ✗ |
| 5 | ✗ |
| 6 | ✗ |
| 7 | ✗ |
| 8 | ✗ |
| 9 | ✗ |
| 10 | ✗ |
| 11 | ✓ |
| 12 | ✗ |
| 13 | ✓ |
| 14 | ✗ |
| 15 | ✗ |
| 16 | ✗ |
| 17 | ✗ |
| 18 | ✗ |
| 19 | ✗ |
| 20 | ✗ |
| 21 | ✗ |
| 22 | ✗ |
| 23 | ✗ |
| 24 | ✗ |
| 25 | ✗ |
| 26 | ✓ |
| 27 | ✗ |
| 28 | ✗ |
| 29 | ✗ |
| 30 | ✗ |
| 31 | ✗ |
| 32 | ✓ |
| 33 | ✗ |

| | |
|---|---|
| 34 | ✗ |
| 35 | ✗ |
| 36 | ✗ |
| 37 | ✗ |
| 38 | ✗ |
| 39 | ✗ |
| 40 | ✗ |
| 41 | ✗ |
| 42 | ✗ |
| 43 | ✗ |
| 44 | ✓ |
| 45 | ✗ |
| 46 | ✗ |
| 47 | ✓ |
| 48 | ✗ |
| 49 | ✗ |
| 50 | ✗ |
| 51 | - |
| 52 | - |
| 53 | - |
| 54 | - |
| 55 | - |
| 56 | - |
| 57 | - |
| 58 | - |
| 59 | - |
| 60 | - |
| 61 | - |
| 62 | - |
| 63 | - |
| 64 | - |
| **65** | - |

All contents of this site are © 2024 Passmedicine Limited

Back to top

A 55-year-old man asks you to have a look at some 'red spots' on his torso. They have been present for about the past six months.

© Image used on license from DermNet NZ

What is the most likely diagnosis?

| | |
|---|---|
| Kaposi sarcoma | 5% |
| Blue rubber bleb naevus syndrome | 6% |
| Thrombocytopaenia | 0% |
| Malignant melanoma | 1% |
| Cherry haemangioma | 87% |

The most likely diagnosis for the 'red spots' on the 55-year-old man's torso is **Cherry haemangioma**. This condition is characterized by small, bright red raised bumps that are usually found on the skin of adults aged over 30 years. The 'red spots' in the image provided are consistent with this description. Cherry haemangiomas are benign vascular proliferations and do not require treatment unless they become symptomatic or for cosmetic reasons.

**Kaposi sarcoma** is incorrect because it typically presents as purple, red, or brown blotches or tumours on the skin. It is a rare type of cancer that can occur in people with weakened immune

systems such as those with AIDS or who have had organ transplants, which does not seem to be applicable to this patient based on the information given.

**Blue rubber bleb naevus syndrome** is also unlikely as it involves venous malformations that appear as compressible blue nodules and can occur anywhere on the body including internal organs. These lesions are typically blue rather than red and often present at birth or during early childhood.

The option of **Thrombocytopaenia**, which translates to low platelet count, would usually present with petechiae (small red or purple spots), purpura (larger areas of bleeding into skin), easy bruising or mucosal bleeding rather than these isolated 'red spots'.

Finally, **Malignant melanoma** is an aggressive form of skin cancer that often appears as a new mole or changes in an existing mole rather than presenting as multiple 'red spots'. Melanomas typically have irregular borders, variations in colour within one lesion, larger diameter and evolving changes over time. This presentation does not match the image provided.

Discuss (1) Improve

Next question

## Cherry haemangioma

Cherry haemangiomas (Campbell de Morgan spots) are benign skin lesions which contain an abnormal proliferation of capillaries. They are more common with advancing age and affect men and women equally.

Features
- erythematous, papular lesions
- typically 1-3 mm in size
- non-blanching
- not found on the mucous membranes

As they are benign no treatment is usually required.

123

Next question

## Textbooks

High-yield textbook

Extended textbook

## Links

DermNet NZ 3 1

Angiomas

Suggest link Report broken link

Score: **17%**

| | |
|---|---|
| 1 | ✗ |
| 2 | ✗ |
| 3 | ✓ |
| 4 | ✗ |
| 5 | ✗ |
| 6 | ✗ |
| 7 | ✗ |
| 8 | ✗ |
| 9 | ✗ |
| 10 | ✗ |
| 11 | ✓ |
| 12 | ✗ |
| 13 | ✓ |

| | |
|---|---|
| 14 | ✗ |
| 15 | ✗ |
| 16 | ✗ |
| 17 | ✗ |
| 18 | ✗ |
| 19 | ✗ |
| 20 | ✗ |
| 21 | ✗ |
| 22 | ✗ |
| 23 | ✗ |
| 24 | ✗ |
| 25 | ✗ |
| 26 | ✓ |
| 27 | ✗ |
| 28 | ✗ |
| 29 | ✗ |
| 30 | ✗ |
| 31 | ✗ |
| 32 | ✓ |
| 33 | ✗ |
| 34 | ✗ |
| 35 | ✗ |
| 36 | ✗ |
| 37 | ✗ |
| 38 | ✗ |
| 39 | ✗ |
| 40 | ✗ |
| 41 | ✗ |
| 42 | ✗ |
| 43 | ✗ |
| 44 | ✓ |
| 45 | ✗ |
| 46 | ✗ |
| 47 | ✓ |
| 48 | ✗ |
| 49 | ✗ |

| | |
|---|---|
| 50 | ✗ |
| 51 | ✗ |
| 52 | ✗ |
| 53 | ✗ |
| 54 | ✗ |
| 55 | ✗ |
| 56 | ✗ |
| 57 | ✗ |
| 58 | ✗ |
| 59 | ✗ |
| 60 | ✗ |
| 61 | ✗ |
| 62 | ✓ |
| 63 | ✗ |
| 64 | ✗ |
| **65** | ✓ |
| 66 | ✗ |
| 67 | ✗ |
| 68 | ✗ |
| 69 | ✓ |
| 70 | ✓ |
| 71 | ✗ |
| 72 | ✗ |
| 73 | ✗ |
| 74 | ✓ |
| 75 | ✗ |
| 76 | ✗ |
| 77 | ✗ |
| 78 | ✗ |
| 79 | - |
| 80 | ✓ |
| 81 | ✗ |
| 82 | ✗ |
| 83 | ✗ |
| 84 | ✗ |
| 85 | ✗ |

| | |
|---|---|
| 86 | ✗ |
| 87 | ✗ |
| 88 | ✓ |
| 89 | ✓ |
| 90 | ✗ |
| 91 | ✗ |
| 92 | ✗ |
| 93 | ✗ |
| 94 | ✓ |
| 95 | ✗ |
| 96 | ✗ |
| 97 | ✗ |
| 98 | ✗ |
| 99 | ✓ |
| 100 | ✗ |
| 101 | ✗ |

All contents of this site are © 2024 Passmedicine Limited

A 50-year-old man presents to the dermatology clinic with a 1-month history of axillary skin discolouration. He finds it unpleasant to look at and is now complaining of increasing pruritus. He has no past medical history of note and smokes 15-20 cigarettes/day.

On examination, he is afebrile with a heart rate of 76 beats/min and a blood pressure of 130/65mmHg. His skin is examined, as shown below:

© Image used on license from DermNet NZ

Given the diagnosis, what is most likely to be associated with this presentation?

- Acromegaly
- Acute lymphoblastic leukaemia
- Addison's disease
- Coeliac disease

○ Diabetes insipidus ×

Submit answer

Reference ranges ⌄

Score: **14%**

| | |
|---|---|
| 1 | ✗ |
| 2 | ✗ |
| 3 | ✓ |
| 4 | ✗ |
| 5 | ✗ |
| 6 | ✗ |
| 7 | ✗ |
| 8 | ✗ |
| 9 | ✗ |
| 10 | ✗ |
| 11 | ✓ |
| 12 | ✗ |
| 13 | ✓ |
| 14 | ✗ |
| 15 | ✗ |
| 16 | ✗ |
| 17 | ✗ |
| 18 | ✗ |
| 19 | ✗ |
| 20 | ✗ |
| 21 | ✗ |
| 22 | ✗ |
| 23 | ✗ |
| 24 | ✗ |
| 25 | ✗ |

| | |
|---|---|
| 26 | ✓ |
| 27 | ✗ |
| 28 | ✗ |
| 29 | ✗ |
| 30 | ✗ |
| 31 | ✗ |
| 32 | ✓ |
| 33 | ✗ |
| 34 | ✗ |
| 35 | ✗ |
| 36 | ✗ |
| 37 | ✗ |
| 38 | ✗ |
| 39 | ✗ |
| 40 | ✗ |
| 41 | ✗ |
| 42 | ✗ |
| 43 | ✗ |
| 44 | ✓ |
| 45 | ✗ |
| 46 | ✗ |
| 47 | ✓ |
| 48 | ✗ |
| 49 | ✗ |
| 50 | ✗ |
| 51 | - |
| 52 | - |
| 53 | - |
| 54 | - |
| 55 | - |
| 56 | - |
| 57 | - |
| 58 | - |
| 59 | - |
| 60 | - |
| 61 | - |
| 62 | - |

| | |
|---|---|
| 63 | - |
| 64 | - |
| 65 | - |
| **66** | - |

All contents of this site are © 2024 Passmedicine Limited

A 50-year-old man presents to the dermatology clinic with a 1-month history of axillary skin discolouration. He finds it unpleasant to look at and is now complaining of increasing pruritus. He has no past medical history of note and smokes 15-20 cigarettes/day.

On examination, he is afebrile with a heart rate of 76 beats/min and a blood pressure of 130/65mmHg. His skin is examined, as shown below:

© Image used on license from DermNet NZ

Given the diagnosis, what is most likely to be associated with this presentation?

| | |
|---|---|
| Acromegaly | 55% |
| Acute lymphoblastic leukaemia | 5% |
| Addison's disease | 24% |
| Coeliac disease | 9% |

Diabetes insipidus 7%

**Acromegaly** is correct. This patient has a diagnosis of acanthosis nigricans characterised by hyperkeratosis and hyperpigmentation of the skin, predominantly affecting the flexural skin folds such as the axillae and groin. The skin may have a velvety texture secondary to papillomatous overgrowth of the epidermis. Common underlying causes include metabolic diseases such as obesity, type 2 diabetes mellitus, polycystic ovarian syndrome and acromegaly.

**Acute lymphoblastic leukaemia** is incorrect. Haematological malignancies are associated with Sweet syndrome, characterised by fever and inflamed and blistered skin with mucosal involvement.

**Addison's disease** is incorrect. Due to excess ACTH, patients with Addison's disease may have the appearance of tanned skin due to the stimulation of melanocytes. However, it does not cause acanthosis nigricans.

**Coeliac disease** is incorrect. Coeliac disease is associated with dermatitis herpetiformis, a vesicular rash commonly seen on the extensor surfaces of the skin. This is not the rash that is demonstrated here.

**Diabetes insipidus** is incorrect. Diabetes mellitus is associated with acanthosis nigricans. However, diabetes insipidus is not associated with any dermatological manifestations.

Discuss (1) | Improve

Next question

## Acanthosis nigricans

Describes symmetrical, brown, velvety plaques that are often found on the neck, axilla and groin.

Causes
- type 2 diabetes mellitus
- gastrointestinal cancer
- obesity
- polycystic ovarian syndrome
- acromegaly
- Cushing's disease
- hypothyroidism
- familial
- Prader-Willi syndrome

- drugs
    - combined oral contraceptive pill
    - nicotinic acid

Pathophysiology

- insulin resistance → hyperinsulinemia → stimulation of keratinocytes and dermal fibroblast proliferation via interaction with insulin-like growth factor receptor-1 (IGFR1)

123

Next question

**Textbooks**

High-yield textbook

Extended textbook

**Links**

DermNet NZ 54 21

Acanthosis nigricans

Suggest link Report broken link

Score: **17%**

| | |
|---|---|
| 1 | ✗ |
| 2 | ✗ |
| 3 | ✓ |
| 4 | ✗ |
| 5 | ✗ |
| 6 | ✗ |
| 7 | ✗ |
| 8 | ✗ |
| 9 | ✗ |
| 10 | ✗ |
| 11 | ✓ |
| 12 | ✗ |
| 13 | ✓ |
| 14 | ✗ |
| 15 | ✗ |
| 16 | ✗ |
| 17 | ✗ |
| 18 | ✗ |
| 19 | ✗ |
| 20 | ✗ |
| 21 | ✗ |
| 22 | ✗ |
| 23 | ✗ |
| 24 | ✗ |
| 25 | ✗ |
| 26 | ✓ |
| 27 | ✗ |
| 28 | ✗ |
| 29 | ✗ |
| 30 | ✗ |
| 31 | ✗ |

| | |
|---|---|
| 32 | ✓ |
| 33 | ✗ |
| 34 | ✗ |
| 35 | ✗ |
| 36 | ✗ |
| 37 | ✗ |
| 38 | ✗ |
| 39 | ✗ |
| 40 | ✗ |
| 41 | ✗ |
| 42 | ✗ |
| 43 | ✗ |
| 44 | ✓ |
| 45 | ✗ |
| 46 | ✗ |
| 47 | ✓ |
| 48 | ✗ |
| 49 | ✗ |
| 50 | ✗ |
| 51 | ✗ |
| 52 | ✗ |
| 53 | ✗ |
| 54 | ✗ |
| 55 | ✗ |
| 56 | ✗ |
| 57 | ✗ |
| 58 | ✗ |
| 59 | ✗ |
| 60 | ✗ |
| 61 | ✗ |
| 62 | ✓ |
| 63 | ✗ |
| 64 | ✗ |
| 65 | ✓ |
| **66** | ✗ |
| 67 | ✗ |

| | |
|---|---|
| 68 | ✗ |
| 69 | ✓ |
| 70 | ✓ |
| 71 | ✗ |
| 72 | ✗ |
| 73 | ✗ |
| 74 | ✓ |
| 75 | ✗ |
| 76 | ✗ |
| 77 | ✗ |
| 78 | ✗ |
| 79 | - |
| 80 | ✓ |
| 81 | ✗ |
| 82 | ✗ |
| 83 | ✗ |
| 84 | ✗ |
| 85 | ✗ |
| 86 | ✗ |
| 87 | ✗ |
| 88 | ✓ |
| 89 | ✓ |
| 90 | ✗ |
| 91 | ✗ |
| 92 | ✗ |
| 93 | ✗ |
| 94 | ✓ |
| 95 | ✗ |
| 96 | ✗ |
| 97 | ✗ |
| 98 | ✗ |
| 99 | ✓ |
| 100 | ✗ |
| 101 | ✗ |

All contents of this site are © 2024 Passmedicine Limited

A 68-year-old lady is reviewed in the cardiology outpatient clinic following a recent admission for a non-ST-elevation myocardial infarction (NSTEMI). An echocardiogram performed during her inpatient stay showed mild-moderate LV systolic dysfunction with an ejection fraction of 40%.

Since discharge, she has been feeling well and has experienced no further episodes of chest pain. She reports only mild breathlessness on climbing two flights of stairs but draws your attention to an itchy rash on her lower legs. On examination, there are tense blisters covering her lower limbs bilaterally with minimal underlying oedema.

Which of her medications is most likely to be implicated?

- Spironolactone
- Clopidogrel
- Bisoprolol
- Furosemide
- Ramipril

Submit answer

Reference ranges

Score: **14%**

| | |
|---|---|
| 1 | ✗ |
| 2 | ✗ |
| 3 | ✓ |
| 4 | ✗ |
| 5 | ✗ |

| | |
|---|---|
| 6 | ✗ |
| 7 | ✗ |
| 8 | ✗ |
| 9 | ✗ |
| 10 | ✗ |
| 11 | ✓ |
| 12 | ✗ |
| 13 | ✓ |
| 14 | ✗ |
| 15 | ✗ |
| 16 | ✗ |
| 17 | ✗ |
| 18 | ✗ |
| 19 | ✗ |
| 20 | ✗ |
| 21 | ✗ |
| 22 | ✗ |
| 23 | ✗ |
| 24 | ✗ |
| 25 | ✗ |
| 26 | ✓ |
| 27 | ✗ |
| 28 | ✗ |
| 29 | ✗ |
| 30 | ✗ |
| 31 | ✗ |
| 32 | ✓ |
| 33 | ✗ |
| 34 | ✗ |
| 35 | ✗ |
| 36 | ✗ |
| 37 | ✗ |
| 38 | ✗ |
| 39 | ✗ |
| 40 | ✗ |
| 41 | ✗ |

| | |
|---|---|
| 42 | ✗ |
| 43 | ✗ |
| 44 | ✓ |
| 45 | ✗ |
| 46 | ✗ |
| 47 | ✓ |
| 48 | ✗ |
| 49 | ✗ |
| 50 | ✗ |
| 51 | - |
| 52 | - |
| 53 | - |
| 54 | - |
| 55 | - |
| 56 | - |
| 57 | - |
| 58 | - |
| 59 | - |
| 60 | - |
| 61 | - |
| 62 | - |
| 63 | - |
| 64 | - |
| 65 | - |
| 66 | - |
| **67** | - |

All contents of this site are © 2024 Passmedicine Limited

Back to top

A 68-year-old lady is reviewed in the cardiology outpatient clinic following a recent admission for a non-ST-elevation myocardial infarction (NSTEMI). An echocardiogram performed during her inpatient stay showed mild-moderate LV systolic dysfunction with an ejection fraction of 40%.

Since discharge, she has been feeling well and has experienced no further episodes of chest pain. She reports only mild breathlessness on climbing two flights of stairs but draws your attention to an itchy rash on her lower legs. On examination, there are tense blisters covering her lower limbs bilaterally with minimal underlying oedema.

Which of her medications is most likely to be implicated?

| | |
|---|---|
| Spironolactone | 10% |
| Clopidogrel | 10% |
| Bisoprolol | 32% |
| Furosemide | 26% |
| Ramipril | 22% |

The patient has developed bullous pemphigoid, of which furosemide is a classic cause. Penicillamine, captopril, and penicillin derivatives are other common causes. The condition may remit or even disappear on cessation of the offending agent.

Discuss (8) Improve

Next question

## Bullous pemphigoid

Bullous pemphigoid is an autoimmune condition causing sub-epidermal blistering of the skin. This is secondary to the development of antibodies against hemidesmosomal proteins BP180 and BP230.

Bullous pemphigoid is more common in elderly patients. Features include

- itchy, tense blisters typically around flexures
- the blisters usually heal without scarring
- there is stereotypically no mucosal involvement (i.e. the mouth is spared)
    - in reality around 10-50% of patients have a degree of mucosal involvement. It would, however, be unusual for an exam question to mention mucosal involvement as it is seen as a classic differentiating feature between pemphigoid and pemphigus.

Skin biopsy

- immunofluorescence shows IgG and C3 at the dermoepidermal junction

Management

- referral to a dermatologist for biopsy and confirmation of diagnosis
- oral corticosteroids are the mainstay of treatment
- topical corticosteroids, immunosuppressants and antibiotics are also used

123

Next question

**Textbooks**

High-yield textbook

Extended textbook

## Links

British Association of Dermatologists 8 11

Bullous pemphigoid guidelines

DermNet NZ 15 9

Bullous pemphigoid

Suggest link Report broken link

## Media




Bullous pemphigoid

Osmosis - YouTube 5 1

Report broken media

Score: **17%**

1 ✗
2 ✗
3 ✓
4 ✗
5 ✗
6 ✗
7 ✗
8 ✗
9 ✗

| | |
|---|---|
| 10 | ✗ |
| 11 | ✓ |
| 12 | ✗ |
| 13 | ✓ |
| 14 | ✗ |
| 15 | ✗ |
| 16 | ✗ |
| 17 | ✗ |
| 18 | ✗ |
| 19 | ✗ |
| 20 | ✗ |
| 21 | ✗ |
| 22 | ✗ |
| 23 | ✗ |
| 24 | ✗ |
| 25 | ✗ |
| 26 | ✓ |
| 27 | ✗ |
| 28 | ✗ |
| 29 | ✗ |
| 30 | ✗ |
| 31 | ✗ |
| 32 | ✓ |
| 33 | ✗ |
| 34 | ✗ |
| 35 | ✗ |
| 36 | ✗ |
| 37 | ✗ |
| 38 | ✗ |
| 39 | ✗ |
| 40 | ✗ |
| 41 | ✗ |
| 42 | ✗ |
| 43 | ✗ |
| 44 | ✓ |
| 45 | ✗ |

| | |
|---|---|
| 46 | ✗ |
| 47 | ✓ |
| 48 | ✗ |
| 49 | ✗ |
| 50 | ✗ |
| 51 | ✗ |
| 52 | ✗ |
| 53 | ✗ |
| 54 | ✗ |
| 55 | ✗ |
| 56 | ✗ |
| 57 | ✗ |
| 58 | ✗ |
| 59 | ✗ |
| 60 | ✗ |
| 61 | ✗ |
| 62 | ✓ |
| 63 | ✗ |
| 64 | ✗ |
| 65 | ✓ |
| 66 | ✗ |
| **67** | ✗ |
| 68 | ✗ |
| 69 | ✓ |
| 70 | ✓ |
| 71 | ✗ |
| 72 | ✗ |
| 73 | ✗ |
| 74 | ✓ |
| 75 | ✗ |
| 76 | ✗ |
| 77 | ✗ |
| 78 | ✗ |
| 79 | - |
| 80 | ✓ |
| 81 | ✗ |

| | |
|---|---|
| 82 | ✗ |
| 83 | ✗ |
| 84 | ✗ |
| 85 | ✗ |
| 86 | ✗ |
| 87 | ✗ |
| 88 | ✓ |
| 89 | ✓ |
| 90 | ✗ |
| 91 | ✗ |
| 92 | ✗ |
| 93 | ✗ |
| 94 | ✓ |
| 95 | ✗ |
| 96 | ✗ |
| 97 | ✗ |
| 98 | ✗ |
| 99 | ✓ |
| 100 | ✗ |
| 101 | ✗ |

All contents of this site are © 2024 Passmedicine Limited

Back to top

You notice an abnormality on the neck of a 40-year-old woman:

© Image used on license from DermNet NZ and with the kind permission of Prof Raimo Suhonen

Which one of the following is most associated with this appearance?

- Lung cancer
- Acute pancreatitis
- Haemochromatosis
- Polycystic ovarian syndrome
- Digoxin use

Submit answer

Reference ranges

Score: **14%**

| | |
|---|---|
| 1 | ✗ |
| 2 | ✗ |
| 3 | ✓ |
| 4 | ✗ |
| 5 | ✗ |
| 6 | ✗ |
| 7 | ✗ |
| 8 | ✗ |
| 9 | ✗ |
| 10 | ✗ |
| 11 | ✓ |
| 12 | ✗ |
| 13 | ✓ |
| 14 | ✗ |
| 15 | ✗ |
| 16 | ✗ |
| 17 | ✗ |
| 18 | ✗ |
| 19 | ✗ |
| 20 | ✗ |
| 21 | ✗ |
| 22 | ✗ |
| 23 | ✗ |
| 24 | ✗ |
| 25 | ✗ |
| 26 | ✓ |
| 27 | ✗ |
| 28 | ✗ |
| 29 | ✗ |
| 30 | ✗ |
| 31 | ✗ |
| 32 | ✓ |
| 33 | ✗ |
| 34 | ✗ |

| | |
|---|---|
| 35 | ✗ |
| 36 | ✗ |
| 37 | ✗ |
| 38 | ✗ |
| 39 | ✗ |
| 40 | ✗ |
| 41 | ✗ |
| 42 | ✗ |
| 43 | ✗ |
| 44 | ✓ |
| 45 | ✗ |
| 46 | ✗ |
| 47 | ✓ |
| 48 | ✗ |
| 49 | ✗ |
| 50 | ✗ |
| 51 | - |
| 52 | - |
| 53 | - |
| 54 | - |
| 55 | - |
| 56 | - |
| 57 | - |
| 58 | - |
| 59 | - |
| 60 | - |
| 61 | - |
| 62 | - |
| 63 | - |
| 64 | - |
| 65 | - |
| 66 | - |
| 67 | - |
| **68** | - |

All contents of this site are © 2024 Passmedicine Limited

Back to top

You notice an abnormality on the neck of a 40-year-old woman:

© Image used on license from DermNet NZ and with the kind permission of Prof Raimo Suhonen

Which one of the following is most associated with this appearance?

| | |
|---|---|
| Lung cancer | 8% |
| Acute pancreatitis | 3% |
| Haemochromatosis | 5% |
| Polycystic ovarian syndrome | 83% |
| Digoxin use | 1% |

This patient has acanthosis nigricans which is associated with a number of hyperinsulinaemia states such as polycystic ovarian syndrome.

Whilst acanthosis nigricans can be associated with any type of cancer by far the most common malignant cause is gastrointestinal adenocarcinoma.

Discuss (1) Improve

# Acanthosis nigricans

Describes symmetrical, brown, velvety plaques that are often found on the neck, axilla and groin.

Causes
- type 2 diabetes mellitus
- gastrointestinal cancer
- obesity
- polycystic ovarian syndrome
- acromegaly
- Cushing's disease
- hypothyroidism
- familial
- Prader-Willi syndrome
- drugs
  - combined oral contraceptive pill
  - nicotinic acid

Pathophysiology
- insulin resistance → hyperinsulinemia → stimulation of keratinocytes and dermal fibroblast proliferation via interaction with insulin-like growth factor receptor-1 (IGFR1)

123

## Textbooks

High-yield textbook

Extended textbook

## Links

DermNet NZ 54 21

Acanthosis nigricans

Suggest link Report broken link

Score: **17%**

| | |
|---|---|
| 1 | ✗ |
| 2 | ✗ |
| 3 | ✓ |
| 4 | ✗ |
| 5 | ✗ |
| 6 | ✗ |
| 7 | ✗ |
| 8 | ✗ |
| 9 | ✗ |
| 10 | ✗ |
| 11 | ✓ |
| 12 | ✗ |
| 13 | ✓ |
| 14 | ✗ |
| 15 | ✗ |
| 16 | ✗ |

17 ✗
18 ✗
19 ✗
20 ✗
21 ✗
22 ✗
23 ✗
24 ✗
25 ✗
26 ✓
27 ✗
28 ✗
29 ✗
30 ✗
31 ✗
32 ✓
33 ✗
34 ✗
35 ✗
36 ✗
37 ✗
38 ✗
39 ✗
40 ✗
41 ✗
42 ✗
43 ✗
44 ✓
45 ✗
46 ✗
47 ✓
48 ✗
49 ✗
50 ✗
51 ✗
52 ✗

| | |
|---|---|
| 53 | ✗ |
| 54 | ✗ |
| 55 | ✗ |
| 56 | ✗ |
| 57 | ✗ |
| 58 | ✗ |
| 59 | ✗ |
| 60 | ✗ |
| 61 | ✗ |
| 62 | ✓ |
| 63 | ✗ |
| 64 | ✗ |
| 65 | ✓ |
| 66 | ✗ |
| 67 | ✗ |
| **68** | ✗ |
| 69 | ✓ |
| 70 | ✓ |
| 71 | ✗ |
| 72 | ✗ |
| 73 | ✗ |
| 74 | ✓ |
| 75 | ✗ |
| 76 | ✗ |
| 77 | ✗ |
| 78 | ✗ |
| 79 | - |
| 80 | ✓ |
| 81 | ✗ |
| 82 | ✗ |
| 83 | ✗ |
| 84 | ✗ |
| 85 | ✗ |
| 86 | ✗ |
| 87 | ✗ |
| 88 | ✓ |

| | |
|---|---|
| 89 | ✓ |
| 90 | ✗ |
| 91 | ✗ |
| 92 | ✗ |
| 93 | ✗ |
| 94 | ✓ |
| 95 | ✗ |
| 96 | ✗ |
| 97 | ✗ |
| 98 | ✗ |
| 99 | ✓ |
| 100 | ✗ |
| 101 | ✗ |

All contents of this site are © 2024 Passmedicine Limited

PassMedicine



A 21-year-old woman with a history of eczema presents with a change in the colour of her skin affecting the hands and feet symmetrically:

What is the most likely diagnosis?

- Excessive topical corticosteroid use
- Leprosy
- Tuberous sclerosis
- Vitiligo
- Pityriasis versicolor

Submit answer

Reference ranges

Score: **14%**

| | |
|---|---|
| 1 | ✗ |
| 2 | ✗ |
| 3 | ✓ |
| 4 | ✗ |
| 5 | ✗ |
| 6 | ✗ |
| 7 | ✗ |
| 8 | ✗ |
| 9 | ✗ |
| 10 | ✗ |
| 11 | ✓ |
| 12 | ✗ |
| 13 | ✓ |
| 14 | ✗ |
| 15 | ✗ |
| 16 | ✗ |
| 17 | ✗ |
| 18 | ✗ |
| 19 | ✗ |
| 20 | ✗ |
| 21 | ✗ |
| 22 | ✗ |
| 23 | ✗ |
| 24 | ✗ |
| 25 | ✗ |
| 26 | ✓ |

| | |
|---|---|
| 27 | ✗ |
| 28 | ✗ |
| 29 | ✗ |
| 30 | ✗ |
| 31 | ✗ |
| 32 | ✓ |
| 33 | ✗ |
| 34 | ✗ |
| 35 | ✗ |
| 36 | ✗ |
| 37 | ✗ |
| 38 | ✗ |
| 39 | ✗ |
| 40 | ✗ |
| 41 | ✗ |
| 42 | ✗ |
| 43 | ✗ |
| 44 | ✓ |
| 45 | ✗ |
| 46 | ✗ |
| 47 | ✓ |
| 48 | ✗ |
| 49 | ✗ |
| 50 | ✗ |
| 51 | - |
| 52 | - |
| 53 | - |
| 54 | - |
| 55 | - |
| 56 | - |
| 57 | - |
| 58 | - |
| 59 | - |
| 60 | - |
| 61 | - |
| 62 | - |
| 63 | - |

64 -
65 -
66 -
67 -
68 -
**69** -

All contents of this site are © 2024 Passmedicine Limited

A 21-year-old woman with a history of eczema presents with a change in the colour of her skin affecting the hands and feet symmetrically:

What is the most likely diagnosis?

| | |
|---|---|
| Excessive topical corticosteroid use | 10% |
| Leprosy | 1% |
| Tuberous sclerosis | 1% |
| Vitiligo | 82% |
| Pityriasis versicolor | 6% |

The correct answer is **Vitiligo**. Vitiligo is a condition that causes loss of skin colour in patches. It

can affect the skin on any part of your body and may also affect hair, the inside of the mouth and even the eyes. The main symptom is a loss of pigment which produces white patches on the skin, often symmetrical, as seen in this patient.

The first incorrect option, **Excessive topical corticosteroid use**, can lead to changes in skin colour, but these are typically characterised by thinning of the skin and formation of stretch marks rather than depigmentation. Additionally, excessive use would likely not produce such symmetrical patterns.

**Leprosy**, another incorrect option, is an infectious disease caused by *Mycobacterium leprae*. It usually presents with hypopigmented or reddish patches with a definite loss of sensation. However, it's rare in the UK and does not usually present symmetrically.

**Tuberous sclerosis** is a genetic disorder that causes non-cancerous (benign) tumours to grow in many parts of your body. Skin manifestations include hypomelanotic macules (white patches), facial angiofibromas or shagreen patches but these do not have a symmetrical distribution.

Lastly, **Pityriasis versicolor** is an infection caused by yeast from the Malassezia family. This condition causes small, scaly patches of discoloured skin that might be lighter or darker than the surrounding skin. However, unlike vitiligo, pityriasis versicolor does not cause complete depigmentation and it tends to affect the trunk more commonly than the hands and feet.

Discuss (2) Improve

Next question

## Vitiligo

Vitiligo is an autoimmune condition which results in the loss of melanocytes and consequent depigmentation of the skin. It is thought to affect around 1% of the population and symptoms typically develop by the age of 20-30 years.

Associated conditions

- type 1 diabetes mellitus
- Addison's disease
- autoimmune thyroid disorders
- pernicious anaemia
- alopecia areata

Features

- well-demarcated patches of depigmented skin
- the peripheries tend to be most affected
- trauma may precipitate new lesions (Koebner phenomenon)

Management

- sunblock for affected areas of skin
- camouflage make-up
- topical corticosteroids may reverse the changes if applied early
- there may also be a role for topical tacrolimus and phototherapy, although caution needs to be exercised with light-skinned patients

123

Next question

## Textbooks

High-yield textbook

Extended textbook

## Links

DermNet NZ 8 3

Vitiligo

Suggest link | Report broken link

## Media

Vitiligo

Osmosis - YouTube 👍 0 👎 1

Report broken media

Score: **17%**

| | |
|---|---|
| 1 | ✗ |
| 2 | ✗ |
| 3 | ✓ |
| 4 | ✗ |
| 5 | ✗ |
| 6 | ✗ |
| 7 | ✗ |
| 8 | ✗ |
| 9 | ✗ |
| 10 | ✗ |
| 11 | ✓ |
| 12 | ✗ |
| 13 | ✓ |
| 14 | ✗ |
| 15 | ✗ |
| 16 | ✗ |
| 17 | ✗ |
| 18 | ✗ |

| | |
|---|---|
| 19 | ✗ |
| 20 | ✗ |
| 21 | ✗ |
| 22 | ✗ |
| 23 | ✗ |
| 24 | ✗ |
| 25 | ✗ |
| 26 | ✓ |
| 27 | ✗ |
| 28 | ✗ |
| 29 | ✗ |
| 30 | ✗ |
| 31 | ✗ |
| 32 | ✓ |
| 33 | ✗ |
| 34 | ✗ |
| 35 | ✗ |
| 36 | ✗ |
| 37 | ✗ |
| 38 | ✗ |
| 39 | ✗ |
| 40 | ✗ |
| 41 | ✗ |
| 42 | ✗ |
| 43 | ✗ |
| 44 | ✓ |
| 45 | ✗ |
| 46 | ✗ |
| 47 | ✓ |
| 48 | ✗ |
| 49 | ✗ |
| 50 | ✗ |
| 51 | ✗ |
| 52 | ✗ |
| 53 | ✗ |
| 54 | ✗ |

| | |
|---|---|
| 55 | ✗ |
| 56 | ✗ |
| 57 | ✗ |
| 58 | ✗ |
| 59 | ✗ |
| 60 | ✗ |
| 61 | ✗ |
| 62 | ✓ |
| 63 | ✗ |
| 64 | ✗ |
| 65 | ✓ |
| 66 | ✗ |
| 67 | ✗ |
| 68 | ✗ |
| **69** | ✓ |
| 70 | ✓ |
| 71 | ✗ |
| 72 | ✗ |
| 73 | ✗ |
| 74 | ✓ |
| 75 | ✗ |
| 76 | ✗ |
| 77 | ✗ |
| 78 | ✗ |
| 79 | - |
| 80 | ✓ |
| 81 | ✗ |
| 82 | ✗ |
| 83 | ✗ |
| 84 | ✗ |
| 85 | ✗ |
| 86 | ✗ |
| 87 | ✗ |
| 88 | ✓ |
| 89 | ✓ |
| 90 | ✗ |

| | |
|---|---|
| 91 | ✗ |
| 92 | ✗ |
| 93 | ✗ |
| 94 | ✓ |
| 95 | ✗ |
| 96 | ✗ |
| 97 | ✗ |
| 98 | ✗ |
| 99 | ✓ |
| 100 | ✗ |
| 101 | ✗ |

All contents of this site are © 2024 Passmedicine Limited

Back to top

A 72-year-old woman presents with a new skin marking. She has noticed it recently and is fairly sure it was not present six months ago. It has not caused her any symptoms and has not been itching. On examination, it is a raised, slightly ulcerated, 7mm diameter lesion on her chest. What clinical finding would make squamous cell carcinoma more likely than basal cell carcinoma?

- Telangiectasia
- Not associated with ulceration
- Pearly appearance
- Erythematous base
- Nodular edge

Submit answer

Reference ranges

Score: **14%**

| | |
|---|---|
| 1 | ✗ |
| 2 | ✗ |
| 3 | ✓ |
| 4 | ✗ |
| 5 | ✗ |
| 6 | ✗ |
| 7 | ✗ |
| 8 | ✗ |
| 9 | ✗ |
| 10 | ✗ |

11 ✓
12 ✗
13 ✓
14 ✗
15 ✗
16 ✗
17 ✗
18 ✗
19 ✗
20 ✗
21 ✗
22 ✗
23 ✗
24 ✗
25 ✗
26 ✓
27 ✗
28 ✗
29 ✗
30 ✗
31 ✗
32 ✓
33 ✗
34 ✗
35 ✗
36 ✗
37 ✗
38 ✗
39 ✗
40 ✗
41 ✗
42 ✗
43 ✗
44 ✓
45 ✗
46 ✗

| | |
|---|---|
| 47 | ✓ |
| 48 | ✗ |
| 49 | ✗ |
| 50 | ✗ |
| 51 | - |
| 52 | - |
| 53 | - |
| 54 | - |
| 55 | - |
| 56 | - |
| 57 | - |
| 58 | - |
| 59 | - |
| 60 | - |
| 61 | - |
| 62 | - |
| 63 | - |
| 64 | - |
| 65 | - |
| 66 | - |
| 67 | - |
| 68 | - |
| 69 | - |
| **70** | - |

All contents of this site are © 2024 Passmedicine Limited

A 72-year-old woman presents with a new skin marking. She has noticed it recently and is fairly sure it was not present six months ago. It has not caused her any symptoms and has not been itching. On examination, it is a raised, slightly ulcerated, 7mm diameter lesion on her chest. What clinical finding would make squamous cell carcinoma more likely than basal cell carcinoma?

| | |
|---|---|
| Telangiectasia | 15% |
| Not associated with ulceration | 12% |
| Pearly appearance | 11% |
| Erythematous base | 41% |
| Nodular edge | 21% |

The correct answer is erythematous base. Squamous cell cancers present as crusty enlarging lumps on a background of acinic keratosis on sun-exposed skin. They may ulcerate and are often tender or painful. Basal cell cancers usually have telangiectasia, pearly appearance and have a nodular edge.

Discuss (1) Improve

Next question

## Squamous cell carcinoma of the skin

Squamous cell carcinoma is a common variant of skin cancer. Metastases are rare but may occur in 2-5% of patients.

Risk factors include:
- excessive exposure to sunlight / psoralen UVA therapy
- actinic keratoses and Bowen's disease
- immunosuppression e.g. following renal transplant, HIV
- smoking
- long-standing leg ulcers (Marjolin's ulcer)

- genetic conditions e.g. xeroderma pigmentosum, oculocutaneous albinism

Features
- typically on sun-exposed sites such as the head and neck or dorsum of the hands and arms
- rapidly expanding painless, ulcerate nodules
- may have a cauliflower-like appearance
- there may be areas of bleeding

## Image gallery

## Treatment

Surgical excision with 4mm margins if lesion <20mm in diameter. If tumour >20mm then margins should be 6mm. Mohs micrographic surgery may be used in high-risk patients and in cosmetically important sites.

## Prognosis

| **Good Prognosis** | **Poor prognosis** |
|---|---|
| Well differentiated tumours | Poorly differentiated tumours |
| <20mm diameter | >20mm in diameter |
| <2mm deep | >4mm deep |
| No associated diseases | Immunosupression for whatever reason |

Next question

## Textbooks

High-yield textbook

Extended textbook

## Links

DermNet NZ 28 4

Squamous cell carcinoma

Suggest link Report broken link

## Media

Skin cancers

Osmosis - YouTube 4 1

Report broken media

Score: **17%**

| | |
|---|---|
| 1 | ✗ |
| 2 | ✗ |
| 3 | ✓ |
| 4 | ✗ |
| 5 | ✗ |
| 6 | ✗ |
| 7 | ✗ |
| 8 | ✗ |
| 9 | ✗ |
| 10 | ✗ |
| 11 | ✓ |
| 12 | ✗ |
| 13 | ✓ |
| 14 | ✗ |
| 15 | ✗ |
| 16 | ✗ |
| 17 | ✗ |
| 18 | ✗ |
| 19 | ✗ |
| 20 | ✗ |
| 21 | ✗ |
| 22 | ✗ |
| 23 | ✗ |
| 24 | ✗ |
| 25 | ✗ |
| 26 | ✓ |
| 27 | ✗ |
| 28 | ✗ |
| 29 | ✗ |
| 30 | ✗ |
| 31 | ✗ |
| 32 | ✓ |
| 33 | ✗ |
| 34 | ✗ |

| | |
|---|---|
| 35 | ✗ |
| 36 | ✗ |
| 37 | ✗ |
| 38 | ✗ |
| 39 | ✗ |
| 40 | ✗ |
| 41 | ✗ |
| 42 | ✗ |
| 43 | ✗ |
| 44 | ✓ |
| 45 | ✗ |
| 46 | ✗ |
| 47 | ✓ |
| 48 | ✗ |
| 49 | ✗ |
| 50 | ✗ |
| 51 | ✗ |
| 52 | ✗ |
| 53 | ✗ |
| 54 | ✗ |
| 55 | ✗ |
| 56 | ✗ |
| 57 | ✗ |
| 58 | ✗ |
| 59 | ✗ |
| 60 | ✗ |
| 61 | ✗ |
| 62 | ✓ |
| 63 | ✗ |
| 64 | ✗ |
| 65 | ✓ |
| 66 | ✗ |
| 67 | ✗ |
| 68 | ✗ |
| 69 | ✓ |
| **70** | ✓ |

| | |
|---|---|
| 71 | ✗ |
| 72 | ✗ |
| 73 | ✗ |
| 74 | ✓ |
| 75 | ✗ |
| 76 | ✗ |
| 77 | ✗ |
| 78 | ✗ |
| 79 | - |
| 80 | ✓ |
| 81 | ✗ |
| 82 | ✗ |
| 83 | ✗ |
| 84 | ✗ |
| 85 | ✗ |
| 86 | ✗ |
| 87 | ✗ |
| 88 | ✓ |
| 89 | ✓ |
| 90 | ✗ |
| 91 | ✗ |
| 92 | ✗ |
| 93 | ✗ |
| 94 | ✓ |
| 95 | ✗ |
| 96 | ✗ |
| 97 | ✗ |
| 98 | ✗ |
| 99 | ✓ |
| 100 | ✗ |
| 101 | ✗ |

All contents of this site are © 2024 Passmedicine Limited

A 60-year-old man presents with a painful lesion on his right ear:

© Image used on license from DermNet NZ

What is the most likely diagnosis?

- Actinic keratosis
- Pseudocyst of the auricle
- Chondrodermatitis nodularis helicis
- Basal cell carcinoma
- Keratoacanthoma

Submit answer

Reference ranges

Score: **14%**

| | |
|---|---|
| 1 | ✗ |
| 2 | ✗ |
| 3 | ✓ |
| 4 | ✗ |
| 5 | ✗ |
| 6 | ✗ |
| 7 | ✗ |
| 8 | ✗ |
| 9 | ✗ |
| 10 | ✗ |
| 11 | ✓ |
| 12 | ✗ |
| 13 | ✓ |
| 14 | ✗ |
| 15 | ✗ |
| 16 | ✗ |
| 17 | ✗ |
| 18 | ✗ |
| 19 | ✗ |
| 20 | ✗ |
| 21 | ✗ |
| 22 | ✗ |
| 23 | ✗ |
| 24 | ✗ |
| 25 | ✗ |
| 26 | ✓ |
| 27 | ✗ |
| 28 | ✗ |
| 29 | ✗ |
| 30 | ✗ |
| 31 | ✗ |
| 32 | ✓ |
| 33 | ✗ |
| 34 | ✗ |

| | |
|---|---|
| 35 | ✗ |
| 36 | ✗ |
| 37 | ✗ |
| 38 | ✗ |
| 39 | ✗ |
| 40 | ✗ |
| 41 | ✗ |
| 42 | ✗ |
| 43 | ✗ |
| 44 | ✓ |
| 45 | ✗ |
| 46 | ✗ |
| 47 | ✓ |
| 48 | ✗ |
| 49 | ✗ |
| 50 | ✗ |
| 51 | - |
| 52 | - |
| 53 | - |
| 54 | - |
| 55 | - |
| 56 | - |
| 57 | - |
| 58 | - |
| 59 | - |
| 60 | - |
| 61 | - |
| 62 | - |
| 63 | - |
| 64 | - |
| 65 | - |
| 66 | - |
| 67 | - |
| 68 | - |
| 69 | - |
| 70 | - |
| **71** | - |

All contents of this site are © 2024 Passmedicine Limited

A 60-year-old man presents with a painful lesion on his right ear:

© Image used on license from DermNet NZ

What is the most likely diagnosis?

- Actinic keratosis 3%
- Pseudocyst of the auricle 3%
- Chondrodermatitis nodularis helicis 71%
- Basal cell carcinoma 18%
- Keratoacanthoma 5%

The correct answer is **Chondrodermatitis nodularis helicis**. This condition typically presents as a painful, inflamed nodule on the helix or antihelix of the ear. It most commonly affects middle-aged or elderly individuals and is thought to be related to pressure and sun exposure. The image provided shows a characteristic lesion of Chondrodermatitis nodularis helicis.

Moving on to the incorrect options:

**Actinic keratosis** is a precancerous skin condition characterised by scaly, crusty spots on the skin caused by damage from the sun's ultraviolet (UV) rays. While it may present in similar areas such

as face, lips, ears, back of your hands, forearms, scalp or neck due to sun exposure, it does not typically cause painful lesions.

**Pseudocyst of the auricle**, also known as auricular pseudocyst, presents as a non-inflammatory, fluid-filled swelling on the anterior aspect of the pinna. It's usually painless unless infected and does not appear erythematous like in this case.

**Basal cell carcinoma** is a type of skin cancer that begins in the basal cells which produce new skin cells when old ones die off. It often appears as a slightly transparent bump on the skin, though it can also form as red patches or sores. While it could potentially present with similar characteristics to our patient's lesion (especially if ulcerated), BCCs are typically less painful than Chondrodermatitis nodularis helicis.

Lastly, **Keratoacanthoma** manifests as a round, flesh-coloured growth that might resemble a small volcano with a central plug of keratin. They are rapidly growing tumours that often develop over weeks to months which then may resolve spontaneously over many months. However, they are usually solitary and painless, unlike our patient's presentation.

Discuss (2) Improve

Next question

## Chondrodermatitis nodularis helicis

Chondrodermatitis nodularis helicis (CNH) is a common and benign condition characterised by the development of a painful nodule on the ear. It is thought to be caused by factors such as persistent pressure on the ear (e.g. secondary to sleep, headsets), trauma or cold. CNH is more common in men and with increasing age.

Management
- reducing pressure on the ear: foam 'ear protectors' may be used during sleep
- other treatment options include cryotherapy, steroid injection, collagen injection
- surgical treatment may be used but there is a high recurrence rate

**Image gallery**

123

Next question

## Textbooks

High-yield textbook

Extended textbook

## Links

Primary Care Dermatology Societ — 4 1

[Chondrodermatitis nodularis helicis]

DermNet NZ — 1 0

[Chondrodermatitis nodularis]

Suggest link

Report broken link

Score: **17%**

| | |
|---|---|
| 1 | ✗ |
| 2 | ✗ |
| 3 | ✓ |
| 4 | ✗ |
| 5 | ✗ |
| 6 | ✗ |
| 7 | ✗ |
| 8 | ✗ |
| 9 | ✗ |
| 10 | ✗ |
| 11 | ✓ |
| 12 | ✗ |
| 13 | ✓ |
| 14 | ✗ |
| 15 | ✗ |
| 16 | ✗ |
| 17 | ✗ |
| 18 | ✗ |
| 19 | ✗ |
| 20 | ✗ |
| 21 | ✗ |
| 22 | ✗ |
| 23 | ✗ |
| 24 | ✗ |
| 25 | ✗ |
| 26 | ✓ |
| 27 | ✗ |
| 28 | ✗ |
| 29 | ✗ |
| 30 | ✗ |
| 31 | ✗ |
| 32 | ✓ |
| 33 | ✗ |
| 34 | ✗ |
| 35 | ✗ |

36 ✗
37 ✗
38 ✗
39 ✗
40 ✗
41 ✗
42 ✗
43 ✗
44 ✓
45 ✗
46 ✗
47 ✓
48 ✗
49 ✗
50 ✗
51 ✗
52 ✗
53 ✗
54 ✗
55 ✗
56 ✗
57 ✗
58 ✗
59 ✗
60 ✗
61 ✗
62 ✓
63 ✗
64 ✗
65 ✓
66 ✗
67 ✗
68 ✗
69 ✓
70 ✓
**71** ✗

| | |
|---|---|
| 72 | ✗ |
| 73 | ✗ |
| 74 | ✓ |
| 75 | ✗ |
| 76 | ✗ |
| 77 | ✗ |
| 78 | ✗ |
| 79 | - |
| 80 | ✓ |
| 81 | ✗ |
| 82 | ✗ |
| 83 | ✗ |
| 84 | ✗ |
| 85 | ✗ |
| 86 | ✗ |
| 87 | ✗ |
| 88 | ✓ |
| 89 | ✓ |
| 90 | ✗ |
| 91 | ✗ |
| 92 | ✗ |
| 93 | ✗ |
| 94 | ✓ |
| 95 | ✗ |
| 96 | ✗ |
| 97 | ✗ |
| 98 | ✗ |
| 99 | ✓ |
| 100 | ✗ |
| 101 | ✗ |

All contents of this site are © 2024 Passmedicine Limited

Back to top

A 79-year-old woman presents to the dermatology clinic with a 2-week history of a blistering rash over her body. She describes the rash to be predominantly over the lower limbs and forearms. Her past medical history includes hypothyroidism and mild hypertension for which she takes levothyroxine and amlodipine daily.

On examination, her observations are within normal limits. Her rash is examined, as shown below:

© Image used on license from DermNet NZ

Given the likely diagnosis, what findings are most likely to be seen on biopsy?

- Acantholysis
- IgA deposition
- IgG and C3 deposition
- Keratinocyte necrosis
- Positive gram stain

Submit answer

Reference ranges

Score: **14%**

| | |
|---|---|
| 1 | ✗ |
| 2 | ✗ |
| 3 | ✓ |
| 4 | ✗ |
| 5 | ✗ |
| 6 | ✗ |
| 7 | ✗ |
| 8 | ✗ |
| 9 | ✗ |
| 10 | ✗ |
| 11 | ✓ |
| 12 | ✗ |
| 13 | ✓ |
| 14 | ✗ |
| 15 | ✗ |
| 16 | ✗ |
| 17 | ✗ |
| 18 | ✗ |
| 19 | ✗ |
| 20 | ✗ |
| 21 | ✗ |
| 22 | ✗ |
| 23 | ✗ |
| 24 | ✗ |
| 25 | ✗ |
| 26 | ✓ |
| 27 | ✗ |
| 28 | ✗ |
| 29 | ✗ |
| 30 | ✗ |

| | |
|---|---|
| 31 | ✗ |
| 32 | ✓ |
| 33 | ✗ |
| 34 | ✗ |
| 35 | ✗ |
| 36 | ✗ |
| 37 | ✗ |
| 38 | ✗ |
| 39 | ✗ |
| 40 | ✗ |
| 41 | ✗ |
| 42 | ✗ |
| 43 | ✗ |
| 44 | ✓ |
| 45 | ✗ |
| 46 | ✗ |
| 47 | ✓ |
| 48 | ✗ |
| 49 | ✗ |
| 50 | ✗ |
| 51 | - |
| 52 | - |
| 53 | - |
| 54 | - |
| 55 | - |
| 56 | - |
| 57 | - |
| 58 | - |
| 59 | - |
| 60 | - |
| 61 | - |
| 62 | - |
| 63 | - |
| 64 | - |
| 65 | - |
| 66 | - |
| 67 | - |
| 68 | - |

| | |
|---|---|
| 69 | - |
| 70 | - |
| 71 | - |
| **72** | - |

All contents of this site are © 2024 Passmedicine Limited

A 79-year-old woman presents to the dermatology clinic with a 2-week history of a blistering rash over her body. She describes the rash to be predominantly over the lower limbs and forearms. Her past medical history includes hypothyroidism and mild hypertension for which she takes levothyroxine and amlodipine daily.

On examination, her observations are within normal limits. Her rash is examined, as shown below:

© Image used on license from DermNet NZ

Given the likely diagnosis, what findings are most likely to be seen on biopsy?

| | |
|---|---|
| Acantholysis | 14% |
| IgA deposition | 8% |
| IgG and C3 deposition | 73% |
| Keratinocyte necrosis | 3% |
| Positive gram stain | 2% |

This patient has a diagnosis of bullous pemphigoid, given the presence of a blistering rash over the body, predominantly affecting the limbs. The image shows tense blisters that are full of fluid with surrounding erythema. There are discrete, raised erythematous lesions that have a similar appearance to urticaria-like weals. Unlike, pemphigus vulgaris, the oral mucosa is usually spared.

The risk of bullous pemphigoid increases with age and those with a history of autoimmune disease. In order to confirm the diagnosis of bullous pemphigoid, a skin biopsy may be taken which shows **IgG and C3 deposition at the dermo-epidermal junction** on immunofluorescence.

**Acantholysis** is incorrect. Acantholysis is the loss of cohesion between adjacent keratinocytes due to a loss of intercellular connections. It is seen in pemphigus vulgaris and is absent in bullous pemphigoid, making a skin biopsy a useful diagnostic test to distinguish between the two blistering diseases.

**IgA deposition** is incorrect. IgA deposition is seen in dermatitis herpetiformis, a condition associated with coeliac disease. It causes a vesicular eruption, most commonly on the shins but would not be responsible for the rash seen in this patient.

**Keratinocyte necrosis** is incorrect. Keratinocyte necrosis is classically seen in Steven-Johnson syndrome (SJS). SJS is a rare, life-threatening condition that is almost always caused by a drug reaction. It is associated with fever, flaccid blistering causing large amounts of skin detachment, erythema and shock. Although this patient has evidence of a blistering disease, they are otherwise stable, making SJS unlikely.

**Positive gram stain** is incorrect. Although these blisters can become infected with a bacterial organism, bullous pemphigoid is not an infective process and a positive gram stain is not a diagnostic feature of the disease.

Discuss (1) | Improve

Next question

## Bullous pemphigoid

Bullous pemphigoid is an autoimmune condition causing sub-epidermal blistering of the skin. This is secondary to the development of antibodies against hemidesmosomal proteins BP180 and BP230.

Bullous pemphigoid is more common in elderly patients. Features include

- itchy, tense blisters typically around flexures
- the blisters usually heal without scarring
- there is stereotypically no mucosal involvement (i.e. the mouth is spared)
  - in reality around 10-50% of patients have a degree of mucosal involvement. It would, however, be unusual for an exam question to mention mucosal involvement as it is seen as a classic differentiating feature between pemphigoid and pemphigus.

Skin biopsy

- immunofluorescence shows IgG and C3 at the dermoepidermal junction

Management

- referral to a dermatologist for biopsy and confirmation of diagnosis
- oral corticosteroids are the mainstay of treatment
- topical corticosteroids, immunosuppressants and antibiotics are also used

123

Next question

## Textbooks

High-yield textbook

Extended textbook

## Links

British Association of Dermatologists 8 11

Bullous pemphigoid guidelines

DermNet NZ

15 9

Bullous pemphigoid

Suggest link | Report broken link

## Media




Bullous pemphigoid

Osmosis - YouTube 5 1

Report broken media

Score: **17%**

| | |
|---|---|
| 1 | ✗ |
| 2 | ✗ |
| 3 | ✓ |
| 4 | ✗ |
| 5 | ✗ |
| 6 | ✗ |
| 7 | ✗ |
| 8 | ✗ |
| 9 | ✗ |
| 10 | ✗ |
| 11 | ✓ |
| 12 | ✗ |
| 13 | ✓ |
| 14 | ✗ |
| 15 | ✗ |
| 16 | ✗ |
| 17 | ✗ |

| | |
|---|---|
| 18 | ✗ |
| 19 | ✗ |
| 20 | ✗ |
| 21 | ✗ |
| 22 | ✗ |
| 23 | ✗ |
| 24 | ✗ |
| 25 | ✗ |
| 26 | ✓ |
| 27 | ✗ |
| 28 | ✗ |
| 29 | ✗ |
| 30 | ✗ |
| 31 | ✗ |
| 32 | ✓ |
| 33 | ✗ |
| 34 | ✗ |
| 35 | ✗ |
| 36 | ✗ |
| 37 | ✗ |
| 38 | ✗ |
| 39 | ✗ |
| 40 | ✗ |
| 41 | ✗ |
| 42 | ✗ |
| 43 | ✗ |
| 44 | ✓ |
| 45 | ✗ |
| 46 | ✗ |
| 47 | ✓ |
| 48 | ✗ |
| 49 | ✗ |
| 50 | ✗ |
| 51 | ✗ |
| 52 | ✗ |
| 53 | ✗ |

| | |
|---|---|
| 54 | ✗ |
| 55 | ✗ |
| 56 | ✗ |
| 57 | ✗ |
| 58 | ✗ |
| 59 | ✗ |
| 60 | ✗ |
| 61 | ✗ |
| 62 | ✓ |
| 63 | ✗ |
| 64 | ✗ |
| 65 | ✓ |
| 66 | ✗ |
| 67 | ✗ |
| 68 | ✗ |
| 69 | ✓ |
| 70 | ✓ |
| 71 | ✗ |
| **72** | ✗ |
| 73 | ✗ |
| 74 | ✓ |
| 75 | ✗ |
| 76 | ✗ |
| 77 | ✗ |
| 78 | ✗ |
| 79 | - |
| 80 | ✓ |
| 81 | ✗ |
| 82 | ✗ |
| 83 | ✗ |
| 84 | ✗ |
| 85 | ✗ |
| 86 | ✗ |
| 87 | ✗ |
| 88 | ✓ |
| 89 | ✓ |

| | |
|---|---|
| 90 | ✗ |
| 91 | ✗ |
| 92 | ✗ |
| 93 | ✗ |
| 94 | ✓ |
| 95 | ✗ |
| 96 | ✗ |
| 97 | ✗ |
| 98 | ✗ |
| 99 | ✓ |
| 100 | ✗ |
| 101 | ✗ |

All contents of this site are © 2024 Passmedicine Limited

An elderly man develops a blistering skin rash:

© Image used on license from DermNet NZ

Which one of the following statements regarding the likely diagnosis is correct?

- It is associated with coeliac disease
- Eye involvement is the most common complication
- Topical corticosteroids are the mainstay of treatment
- It is less common than pemphigus vulgaris
- The blisters usually heal without scarring

Submit answer

Reference ranges

Score: **14%**

| | |
|---|---|
| 1 | ✗ |
| 2 | ✗ |
| 3 | ✓ |
| 4 | ✗ |
| 5 | ✗ |
| 6 | ✗ |
| 7 | ✗ |
| 8 | ✗ |
| 9 | ✗ |
| 10 | ✗ |
| 11 | ✓ |
| 12 | ✗ |
| 13 | ✓ |
| 14 | ✗ |
| 15 | ✗ |
| 16 | ✗ |
| 17 | ✗ |
| 18 | ✗ |
| 19 | ✗ |
| 20 | ✗ |
| 21 | ✗ |
| 22 | ✗ |
| 23 | ✗ |
| 24 | ✗ |
| 25 | ✗ |
| 26 | ✓ |
| 27 | ✗ |
| 28 | ✗ |
| 29 | ✗ |
| 30 | ✗ |
| 31 | ✗ |
| 32 | ✓ |
| 33 | ✗ |
| 34 | ✗ |

| | |
|---|---|
| 35 | ✗ |
| 36 | ✗ |
| 37 | ✗ |
| 38 | ✗ |
| 39 | ✗ |
| 40 | ✗ |
| 41 | ✗ |
| 42 | ✗ |
| 43 | ✗ |
| 44 | ✓ |
| 45 | ✗ |
| 46 | ✗ |
| 47 | ✓ |
| 48 | ✗ |
| 49 | ✗ |
| 50 | ✗ |
| 51 | - |
| 52 | - |
| 53 | - |
| 54 | - |
| 55 | - |
| 56 | - |
| 57 | - |
| 58 | - |
| 59 | - |
| 60 | - |
| 61 | - |
| 62 | - |
| 63 | - |
| 64 | - |
| 65 | - |
| 66 | - |
| 67 | - |
| 68 | - |
| 69 | - |
| 70 | - |
| 71 | - |
| 72 | - |

**73** -

All contents of this site are © 2024 Passmedicine Limited

Back to top

An elderly man develops a blistering skin rash:

© Image used on license from DermNet NZ

Which one of the following statements regarding the likely diagnosis is correct?

- It is associated with coeliac disease 7%
- Eye involvement is the most common complication 3%
- Topical corticosteroids are the mainstay of treatment 20%
- It is less common than pemphigus vulgaris 18%
- The blisters usually heal without scarring 52%

Discuss (2) Improve

Next question

# Bullous pemphigoid

Bullous pemphigoid is an autoimmune condition causing sub-epidermal blistering of the skin. This is secondary to the development of antibodies against hemidesmosomal proteins BP180 and BP230.

Bullous pemphigoid is more common in elderly patients. Features include

- itchy, tense blisters typically around flexures
- the blisters usually heal without scarring
- there is stereotypically no mucosal involvement (i.e. the mouth is spared)
    - in reality around 10-50% of patients have a degree of mucosal involvement. It would, however, be unusual for an exam question to mention mucosal involvement as it is seen as a classic differentiating feature between pemphigoid and pemphigus.

Skin biopsy

- immunofluorescence shows IgG and C3 at the dermoepidermal junction

Management

- referral to a dermatologist for biopsy and confirmation of diagnosis
- oral corticosteroids are the mainstay of treatment
- topical corticosteroids, immunosuppressants and antibiotics are also used

+ Q 123

Next question

## Textbooks

High-yield textbook

Extended textbook

## Links

British Association of Dermatologists 8 11

Bullous pemphigoid guidelines

DermNet NZ 15 9

Bullous pemphigoid

Suggest link Report broken link

## Media




Bullous pemphigoid

Osmosis - YouTube 5 1

Report broken media

Score: **17%**

1 ✗
2 ✗
3 ✓
4 ✗
5 ✗

| | |
|---|---|
| 6 | ✗ |
| 7 | ✗ |
| 8 | ✗ |
| 9 | ✗ |
| 10 | ✗ |
| 11 | ✓ |
| 12 | ✗ |
| 13 | ✓ |
| 14 | ✗ |
| 15 | ✗ |
| 16 | ✗ |
| 17 | ✗ |
| 18 | ✗ |
| 19 | ✗ |
| 20 | ✗ |
| 21 | ✗ |
| 22 | ✗ |
| 23 | ✗ |
| 24 | ✗ |
| 25 | ✗ |
| 26 | ✓ |
| 27 | ✗ |
| 28 | ✗ |
| 29 | ✗ |
| 30 | ✗ |
| 31 | ✗ |
| 32 | ✓ |
| 33 | ✗ |
| 34 | ✗ |
| 35 | ✗ |
| 36 | ✗ |
| 37 | ✗ |
| 38 | ✗ |
| 39 | ✗ |
| 40 | ✗ |
| 41 | ✗ |

| | |
|---|---|
| 42 | ✗ |
| 43 | ✗ |
| 44 | ✓ |
| 45 | ✗ |
| 46 | ✗ |
| 47 | ✓ |
| 48 | ✗ |
| 49 | ✗ |
| 50 | ✗ |
| 51 | ✗ |
| 52 | ✗ |
| 53 | ✗ |
| 54 | ✗ |
| 55 | ✗ |
| 56 | ✗ |
| 57 | ✗ |
| 58 | ✗ |
| 59 | ✗ |
| 60 | ✗ |
| 61 | ✗ |
| 62 | ✓ |
| 63 | ✗ |
| 64 | ✗ |
| 65 | ✓ |
| 66 | ✗ |
| 67 | ✗ |
| 68 | ✗ |
| 69 | ✓ |
| 70 | ✓ |
| 71 | ✗ |
| 72 | ✗ |
| **73** | ✗ |
| 74 | ✓ |
| 75 | ✗ |
| 76 | ✗ |
| 77 | ✗ |

| | |
|---|---|
| 78 | ✗ |
| 79 | - |
| 80 | ✓ |
| 81 | ✗ |
| 82 | ✗ |
| 83 | ✗ |
| 84 | ✗ |
| 85 | ✗ |
| 86 | ✗ |
| 87 | ✗ |
| 88 | ✓ |
| 89 | ✓ |
| 90 | ✗ |
| 91 | ✗ |
| 92 | ✗ |
| 93 | ✗ |
| 94 | ✓ |
| 95 | ✗ |
| 96 | ✗ |
| 97 | ✗ |
| 98 | ✗ |
| 99 | ✓ |
| 100 | ✗ |
| 101 | ✗ |

All contents of this site are © 2024 Passmedicine Limited

Back to top

Please look at the image below:

© Image used on license from DermNet NZ

Which one of the following is this patient most likely to go on and develop?

- Parkinson's disease
- Hypothyroidism
- Rheumatoid arthritis
- Sarcoidosis
- Metabolic syndrome

Submit answer

Reference ranges

Score: **14%**

| | |
|---|---|
| 1 | ✗ |
| 2 | ✗ |
| 3 | ✓ |
| 4 | ✗ |
| 5 | ✗ |
| 6 | ✗ |
| 7 | ✗ |
| 8 | ✗ |
| 9 | ✗ |
| 10 | ✗ |
| 11 | ✓ |
| 12 | ✗ |
| 13 | ✓ |
| 14 | ✗ |
| 15 | ✗ |
| 16 | ✗ |
| 17 | ✗ |
| 18 | ✗ |
| 19 | ✗ |
| 20 | ✗ |
| 21 | ✗ |
| 22 | ✗ |
| 23 | ✗ |
| 24 | ✗ |
| 25 | ✗ |
| 26 | ✓ |
| 27 | ✗ |
| 28 | ✗ |
| 29 | ✗ |
| 30 | ✗ |
| 31 | ✗ |
| 32 | ✓ |
| 33 | ✗ |
| 34 | ✗ |

| | |
|---|---|
| 35 | ✗ |
| 36 | ✗ |
| 37 | ✗ |
| 38 | ✗ |
| 39 | ✗ |
| 40 | ✗ |
| 41 | ✗ |
| 42 | ✗ |
| 43 | ✗ |
| 44 | ✓ |
| 45 | ✗ |
| 46 | ✗ |
| 47 | ✓ |
| 48 | ✗ |
| 49 | ✗ |
| 50 | ✗ |
| 51 | - |
| 52 | - |
| 53 | - |
| 54 | - |
| 55 | - |
| 56 | - |
| 57 | - |
| 58 | - |
| 59 | - |
| 60 | - |
| 61 | - |
| 62 | - |
| 63 | - |
| 64 | - |
| 65 | - |
| 66 | - |
| 67 | - |
| 68 | - |
| 69 | - |
| 70 | - |
| 71 | - |
| 72 | - |

| | |
|---|---|
| 73 | - |
| **74** | - |

All contents of this site are © 2024 Passmedicine Limited

Please look at the image below:

© Image used on license from DermNet NZ

Which one of the following is this patient most likely to go on and develop?

| | |
|---|---|
| Parkinson's disease | 14% |
| Hypothyroidism | 21% |
| Rheumatoid arthritis | 24% |
| Sarcoidosis | 8% |
| Metabolic syndrome | 34% |

Along with psoriatic arthritis, metabolic syndrome is one of the most common and significant complications of psoriasis.

Discuss (2) Improve

Next question

# Psoriasis

Psoriasis is a common (prevalence around 2%) and chronic skin disorder. It generally presents with red, scaly patches on the skin although it is now recognised that patients with psoriasis are at increased risk of arthritis and cardiovascular disease.

Pathophysiology

- multifactorial and not yet fully understood
- genetic: associated HLA-B13, -B17, and -Cw6. Strong concordance (70%) in identical twins
- immunological: abnormal T cell activity stimulates keratinocyte proliferation. There is increasing evidence this may be mediated by a novel group of T helper cells producing IL-17, designated Th17. These cells seem to be a third T-effector cell subset in addition to Th1 and Th2
- environmental: it is recognised that psoriasis may be worsened (e.g. Skin trauma, stress), triggered (e.g. Streptococcal infection) or improved (e.g. Sunlight) by environmental factors

Recognised subtypes of psoriasis

- plaque psoriasis: the most common sub-type resulting in the typical well-demarcated red, scaly patches affecting the extensor surfaces, sacrum and scalp
- flexural psoriasis: in contrast to plaque psoriasis the skin is smooth
- guttate psoriasis: transient psoriatic rash frequently triggered by a streptococcal infection. Multiple red, teardrop lesions appear on the body
- pustular psoriasis: commonly occurs on the palms and soles

Other features

- nail signs: pitting, onycholysis
- arthritis

Complications

- psoriatic arthropathy (around 10%)
- increased incidence of metabolic syndrome
- increased incidence of cardiovascular disease
- increased incidence of venous thromboembolism
- psychological distress

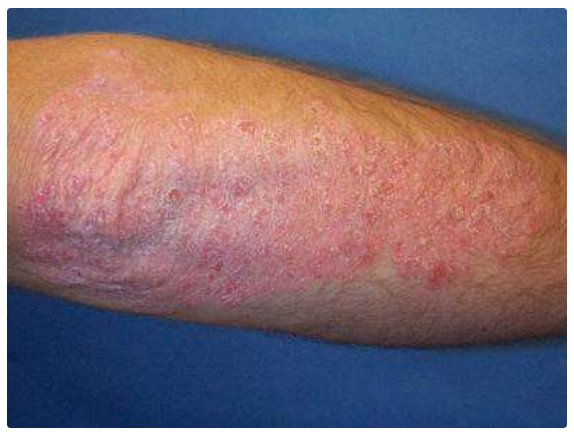

123

Next question

## Textbooks

High-yield textbook

Extended textbook

## Links

DermNet NZ — 3 👍 3 👎

Scalp psoriasis

SIGN — 4 👍 0 👎

2010 Psoriasis guidelines

Suggest link

Report broken link

## Media

Psoriasis

Osmosis - YouTube 2 0

Report broken media

Score: **17%**

| | |
|---|---|
| 1 | ✗ |
| 2 | ✗ |
| 3 | ✓ |
| 4 | ✗ |
| 5 | ✗ |
| 6 | ✗ |
| 7 | ✗ |
| 8 | ✗ |
| 9 | ✗ |
| 10 | ✗ |
| 11 | ✓ |
| 12 | ✗ |
| 13 | ✓ |
| 14 | ✗ |
| 15 | ✗ |
| 16 | ✗ |
| 17 | ✗ |
| 18 | ✗ |
| 19 | ✗ |
| 20 | ✗ |
| 21 | ✗ |
| 22 | ✗ |
| 23 | ✗ |

| | |
|---|---|
| 24 | ✗ |
| 25 | ✗ |
| 26 | ✓ |
| 27 | ✗ |
| 28 | ✗ |
| 29 | ✗ |
| 30 | ✗ |
| 31 | ✗ |
| 32 | ✓ |
| 33 | ✗ |
| 34 | ✗ |
| 35 | ✗ |
| 36 | ✗ |
| 37 | ✗ |
| 38 | ✗ |
| 39 | ✗ |
| 40 | ✗ |
| 41 | ✗ |
| 42 | ✗ |
| 43 | ✗ |
| 44 | ✓ |
| 45 | ✗ |
| 46 | ✗ |
| 47 | ✓ |
| 48 | ✗ |
| 49 | ✗ |
| 50 | ✗ |
| 51 | ✗ |
| 52 | ✗ |
| 53 | ✗ |
| 54 | ✗ |
| 55 | ✗ |
| 56 | ✗ |
| 57 | ✗ |
| 58 | ✗ |
| 59 | ✗ |

| | |
|---|---|
| 60 | ✗ |
| 61 | ✗ |
| 62 | ✓ |
| 63 | ✗ |
| 64 | ✗ |
| 65 | ✓ |
| 66 | ✗ |
| 67 | ✗ |
| 68 | ✗ |
| 69 | ✓ |
| 70 | ✓ |
| 71 | ✗ |
| 72 | ✗ |
| 73 | ✗ |
| **74** | ✓ |
| 75 | ✗ |
| 76 | ✗ |
| 77 | ✗ |
| 78 | ✗ |
| 79 | - |
| 80 | ✓ |
| 81 | ✗ |
| 82 | ✗ |
| 83 | ✗ |
| 84 | ✗ |
| 85 | ✗ |
| 86 | ✗ |
| 87 | ✗ |
| 88 | ✓ |
| 89 | ✓ |
| 90 | ✗ |
| 91 | ✗ |
| 92 | ✗ |
| 93 | ✗ |
| 94 | ✓ |
| 95 | ✗ |

| | |
|---|---|
| 96 | ✗ |
| 97 | ✗ |
| 98 | ✗ |
| 99 | ✓ |
| 100 | ✗ |
| 101 | ✗ |

All contents of this site are © 2024 Passmedicine Limited

A 67-year-old man who is a retired builder presents following the development of a number of red, scaly lesions on his forehead. These were initially small and flat but are now erythematous and rough to touch.

© Image used on license from DermNet NZ

What is the most likely diagnosis?

- Pityriasis versicolor
- Seborrhoeic keratosis
- Polymorphous light eruption
- Actinic keratoses
- Malignant melanoma

Submit answer

Reference ranges

Score: **14%**

| | |
|---|---|
| 1 | ✗ |
| 2 | ✗ |
| 3 | ✓ |
| 4 | ✗ |
| 5 | ✗ |
| 6 | ✗ |
| 7 | ✗ |
| 8 | ✗ |
| 9 | ✗ |
| 10 | ✗ |
| 11 | ✓ |
| 12 | ✗ |
| 13 | ✓ |
| 14 | ✗ |
| 15 | ✗ |
| 16 | ✗ |
| 17 | ✗ |
| 18 | ✗ |
| 19 | ✗ |
| 20 | ✗ |
| 21 | ✗ |
| 22 | ✗ |
| 23 | ✗ |
| 24 | ✗ |
| 25 | ✗ |
| 26 | ✓ |
| 27 | ✗ |
| 28 | ✗ |
| 29 | ✗ |
| 30 | ✗ |
| 31 | ✗ |
| 32 | ✓ |
| 33 | ✗ |
| 34 | ✗ |

| | |
|---|---|
| 35 | ✗ |
| 36 | ✗ |
| 37 | ✗ |
| 38 | ✗ |
| 39 | ✗ |
| 40 | ✗ |
| 41 | ✗ |
| 42 | ✗ |
| 43 | ✗ |
| 44 | ✓ |
| 45 | ✗ |
| 46 | ✗ |
| 47 | ✓ |
| 48 | ✗ |
| 49 | ✗ |
| 50 | ✗ |
| 51 | - |
| 52 | - |
| 53 | - |
| 54 | - |
| 55 | - |
| 56 | - |
| 57 | - |
| 58 | - |
| 59 | - |
| 60 | - |
| 61 | - |
| 62 | - |
| 63 | - |
| 64 | - |
| 65 | - |
| 66 | - |
| 67 | - |
| 68 | - |
| 69 | - |
| 70 | - |
| 71 | - |
| 72 | - |

73 -
74 -
**75** -

All contents of this site are © 2024 Passmedicine Limited

A 67-year-old man who is a retired builder presents following the development of a number of red, scaly lesions on his forehead. These were initially small and flat but are now erythematous and rough to touch.

© Image used on license from DermNet NZ

What is the most likely diagnosis?

| | |
|---|---|
| Pityriasis versicolor | 3% |
| Seborrhoeic keratosis | 16% |
| Polymorphous light eruption | 7% |
| Actinic keratoses | 74% |
| Malignant melanoma | 0% |

The most likely diagnosis for this 67-year-old retired builder presenting with red, scaly lesions on his forehead is **actinic keratoses**. Actinic keratoses are premalignant skin lesions caused by chronic exposure to ultraviolet (UV) radiation, typically seen in fair-skinned individuals and those with a history of outdoor work such as builders. The appearance of these lesions as erythematous, rough patches is consistent with actinic keratoses. In some cases, they can progress to squamous cell carcinoma if left untreated.

**Pityriasis versicolor** is an incorrect answer because it is a superficial fungal infection caused by the yeast *Malassezia*. It typically presents as hypopigmented or hyperpigmented scaly macules and patches on the trunk and upper extremities. The distribution and lack of pigmentary changes make pityriasis versicolor less likely in this case.

**Seborrhoeic keratosis** is also an incorrect answer. Seborrhoeic keratoses are benign epidermal growths that appear as waxy, brownish-black 'stuck-on' plaques. They commonly occur on the trunk and face but have a different appearance than the erythematous, rough lesions described in this case.

**Polymorphous light eruption** is not the correct answer either. Polymorphous light eruption is a delayed hypersensitivity reaction to UV radiation that presents as pruritic papules, vesicles, or plaques on sun-exposed skin areas shortly after sun exposure. While the patient's age and occupation might suggest sun exposure as a factor, the chronic nature of these lesions makes polymorphous light eruption less likely.

Finally, **malignant melanoma** would be an incorrect answer because malignant melanoma typically presents as an asymmetrical, irregularly bordered, variably coloured lesion with a diameter greater than 6mm. The red, scaly lesions described in this case do not fit the typical presentation of malignant melanoma.

Discuss Improve

Next question

## Actinic keratoses

Actinic, or solar, keratoses (AK) is a common premalignant skin lesion that develops as a consequence of chronic sun exposure

Features

- small, crusty or scaly, lesions
- may be pink, red, brown or the same colour as the skin
- typically on sun-exposed areas e.g. temples of head
- multiple lesions may be present

Management options include

- prevention of further risk: e.g. sun avoidance, sun cream
- fluorouracil cream: typically a 2 to 3 week course. The skin will become red and inflamed - sometimes topical hydrocortisone is given following fluorouracil to help settle the inflammation
- topical diclofenac: may be used for mild AKs. Moderate efficacy but much fewer side-effects
- topical imiquimod: trials have shown good efficacy
- cryotherapy
- curettage and cautery

+ Q 123

Next question >

## Textbooks

High-yield textbook

Extended textbook

## Links

British Association of Dermatologists 9 9

2017 Actinic keratoses guidelines

DermNet NZ 27 11

Actinic keratoses

Primary Care Dermatology Society 14 5

Actinic keratosis

Suggest link Report broken link

Score: **17%**

| | |
|---|---|
| 1 | ✗ |
| 2 | ✗ |
| 3 | ✓ |
| 4 | ✗ |
| 5 | ✗ |
| 6 | ✗ |
| 7 | ✗ |
| 8 | ✗ |
| 9 | ✗ |
| 10 | ✗ |
| 11 | ✓ |
| 12 | ✗ |
| 13 | ✓ |
| 14 | ✗ |
| 15 | ✗ |
| 16 | ✗ |
| 17 | ✗ |
| 18 | ✗ |
| 19 | ✗ |
| 20 | ✗ |
| 21 | ✗ |
| 22 | ✗ |
| 23 | ✗ |
| 24 | ✗ |
| 25 | ✗ |
| 26 | ✓ |
| 27 | ✗ |
| 28 | ✗ |

| | |
|---|---|
| 29 | ✗ |
| 30 | ✗ |
| 31 | ✗ |
| 32 | ✓ |
| 33 | ✗ |
| 34 | ✗ |
| 35 | ✗ |
| 36 | ✗ |
| 37 | ✗ |
| 38 | ✗ |
| 39 | ✗ |
| 40 | ✗ |
| 41 | ✗ |
| 42 | ✗ |
| 43 | ✗ |
| 44 | ✓ |
| 45 | ✗ |
| 46 | ✗ |
| 47 | ✓ |
| 48 | ✗ |
| 49 | ✗ |
| 50 | ✗ |
| 51 | ✗ |
| 52 | ✗ |
| 53 | ✗ |
| 54 | ✗ |
| 55 | ✗ |
| 56 | ✗ |
| 57 | ✗ |
| 58 | ✗ |
| 59 | ✗ |
| 60 | ✗ |
| 61 | ✗ |
| 62 | ✓ |
| 63 | ✗ |
| 64 | ✗ |

| | |
|---|---|
| 65 | ✓ |
| 66 | ✗ |
| 67 | ✗ |
| 68 | ✗ |
| 69 | ✓ |
| 70 | ✓ |
| 71 | ✗ |
| 72 | ✗ |
| 73 | ✗ |
| 74 | ✓ |
| **75** | ✗ |
| 76 | ✗ |
| 77 | ✗ |
| 78 | ✗ |
| 79 | - |
| 80 | ✓ |
| 81 | ✗ |
| 82 | ✗ |
| 83 | ✗ |
| 84 | ✗ |
| 85 | ✗ |
| 86 | ✗ |
| 87 | ✗ |
| 88 | ✓ |
| 89 | ✓ |
| 90 | ✗ |
| 91 | ✗ |
| 92 | ✗ |
| 93 | ✗ |
| 94 | ✓ |
| 95 | ✗ |
| 96 | ✗ |
| 97 | ✗ |
| 98 | ✗ |
| 99 | ✓ |
| 100 | ✗ |

101 ✕

All contents of this site are © 2024 Passmedicine Limited

Back to top

A 69-year-old man presents to the dermatology clinic for review due to a suspicious skin lesion. He noticed that a particular mole was of concern as it had been irritated and rubbed against his shirt. On his back, he has a 11x13mm brown lesion with an irregular border with a variation in colour. On view under a dermatoscope, there is no telangiectasia, the lesion looks like there are dark pigmented pin-prick spots within the brown lesion. What feature of this description provides reassurance that the diagnosis is more likely to be benign?

- The absence of telangiectasia
- Irregular border of lesion
- Presence of dark pigmented pin-prick spots
- The size of the lesion
- Variation in colour

Submit answer

Reference ranges

Score: **14%**

| | |
|---|---|
| 1 | ✗ |
| 2 | ✗ |
| 3 | ✓ |
| 4 | ✗ |
| 5 | ✗ |
| 6 | ✗ |
| 7 | ✗ |
| 8 | ✗ |

9 ✗
10 ✗
11 ✓
12 ✗
13 ✓
14 ✗
15 ✗
16 ✗
17 ✗
18 ✗
19 ✗
20 ✗
21 ✗
22 ✗
23 ✗
24 ✗
25 ✗
26 ✓
27 ✗
28 ✗
29 ✗
30 ✗
31 ✗
32 ✓
33 ✗
34 ✗
35 ✗
36 ✗
37 ✗
38 ✗
39 ✗
40 ✗
41 ✗
42 ✗
43 ✗
44 ✓

| | |
|---|---|
| 45 | ✗ |
| 46 | ✗ |
| 47 | ✓ |
| 48 | ✗ |
| 49 | ✗ |
| 50 | ✗ |
| 51 | - |
| 52 | - |
| 53 | - |
| 54 | - |
| 55 | - |
| 56 | - |
| 57 | - |
| 58 | - |
| 59 | - |
| 60 | - |
| 61 | - |
| 62 | - |
| 63 | - |
| 64 | - |
| 65 | - |
| 66 | - |
| 67 | - |
| 68 | - |
| 69 | - |
| 70 | - |
| 71 | - |
| 72 | - |
| 73 | - |
| 74 | - |
| 75 | - |
| **76** | - |

All contents of this site are © 2024 Passmedicine Limited

Back to top

A 69-year-old man presents to the dermatology clinic for review due to a suspicious skin lesion. He noticed that a particular mole was of concern as it had been irritated and rubbed against his shirt. On his back, he has a 11x13mm brown lesion with an irregular border with a variation in colour. On view under a dermatoscope, there is no telangiectasia, the lesion looks like there are dark pigmented pin-prick spots within the brown lesion. What feature of this description provides reassurance that the diagnosis is more likely to be benign?

| | |
|---|---|
| The absence of telangiectasia | 52% |
| Irregular border of lesion | 2% |
| Presence of dark pigmented pin-prick spots | 33% |
| The size of the lesion | 8% |
| Variation in colour | 5% |

Pseudo-comedones and pale spots help distinguish seborrhoeic lesions from malignant melanomas

Important for me Less important

The presence of dark pigmented pin-prick spots, sometimes described as pseudo-commodones, are consistent with seborrhoeic keratosis rather than malignant melanoma. Seborrhoeic keratosis can normally be distinguished clinically by a 'stuck-on' appearance, rather than an invasive one. The other features described are not reassuring and could be consistent with a melanoma, but it is also important to establish if there is change in the lesion.

Irregular shape, a size greater than 6mm, and variation in colour are all features which can be considered with skin malignancy. Telangiectasia is a feature of basal cell carcinoma rather than melanoma or seborrhoeic keratosis.

DermNet NZ
https://www.dermnetnz.org/topics/melanoma/

Discuss (1) Improve

Next question

# Malignant melanoma

There are four main subtypes of melanoma. Nodular melanoma is the most aggressive whilst the other forms spread more slowly.

| | Superficial spreading | Nodular | Lentigo maligna | Acral lentiginous |
|---|---|---|---|---|
| **Frequency** | 70% of cases | Second commonest | Less common | Rare form |
| **Typically affects** | Arms, legs, back and chest, young people | Sun exposed skin, middle-aged people | Chronically sun-exposed skin, older people | Nails, palms or soles, People with darker skin pigmentation |
| **Appearance** | A growing moles with diagnostic features listed above | Red or black lump or lump which bleeds or oozes | A growing mole with diagnostic features listed above | Subungual pigmentation (Hutchinson's sign) or on palms or feet |

There are other rare forms of melanoma including desmoplastic melanoma, amelanotic melanoma, or melanoma arising in other parts of the body such as ocular melanoma.

| The main diagnostic features (major criteria): | Secondary features (minor criteria) |
|---|---|
| • Change in size<br>• Change in shape<br>• Change in colour | • Diameter >= 7mm<br>• Inflammation<br>• Oozing or bleeding<br>• Altered sensation |

**Treatment**
- Suspicious lesions should undergo excision biopsy. The lesion should be removed in completely as incision biopsy can make subsequent histopathological assessment difficult.
- Once the diagnosis is confirmed the pathology report should be reviewed to determine whether further re-excision of margins is required (see below):

**Margins of excision-Related to Breslow thickness**

| | |
|---|---|
| **Lesions 0-1mm thick** | 1cm |
| **Lesions 1-2mm thick** | 1- 2cm (Depending upon site and pathological features) |
| **Lesions 2-4mm thick** | 2-3 cm (Depending upon site and pathological features) |
| **Lesions >4 mm thick** | 3cm |

Further treatments such as sentinel lymph node mapping, isolated limb perfusion and block dissection of regional lymph node groups should be selectively applied.


AI + Q 123

Next question


## Textbooks

High-yield textbook

Extended textbook

## Media

Melanoma

Podmedics - YouTube 2 0

[Skin cancers]

Osmosis - YouTube 👍 1 👎 0

Report broken media

Score: **17%**

| | |
|---|---|
| 1 | ✗ |
| 2 | ✗ |
| 3 | ✓ |
| 4 | ✗ |
| 5 | ✗ |
| 6 | ✗ |
| 7 | ✗ |
| 8 | ✗ |
| 9 | ✗ |
| 10 | ✗ |
| 11 | ✓ |
| 12 | ✗ |
| 13 | ✓ |
| 14 | ✗ |
| 15 | ✗ |
| 16 | ✗ |
| 17 | ✗ |
| 18 | ✗ |
| 19 | ✗ |
| 20 | ✗ |
| 21 | ✗ |
| 22 | ✗ |
| 23 | ✗ |
| 24 | ✗ |

| | |
|---|---|
| 25 | ✗ |
| 26 | ✓ |
| 27 | ✗ |
| 28 | ✗ |
| 29 | ✗ |
| 30 | ✗ |
| 31 | ✗ |
| 32 | ✓ |
| 33 | ✗ |
| 34 | ✗ |
| 35 | ✗ |
| 36 | ✗ |
| 37 | ✗ |
| 38 | ✗ |
| 39 | ✗ |
| 40 | ✗ |
| 41 | ✗ |
| 42 | ✗ |
| 43 | ✗ |
| 44 | ✓ |
| 45 | ✗ |
| 46 | ✗ |
| 47 | ✓ |
| 48 | ✗ |
| 49 | ✗ |
| 50 | ✗ |
| 51 | ✗ |
| 52 | ✗ |
| 53 | ✗ |
| 54 | ✗ |
| 55 | ✗ |
| 56 | ✗ |
| 57 | ✗ |
| 58 | ✗ |
| 59 | ✗ |
| 60 | ✗ |

| | |
|---|---|
| 61 | ✗ |
| 62 | ✓ |
| 63 | ✗ |
| 64 | ✗ |
| 65 | ✓ |
| 66 | ✗ |
| 67 | ✗ |
| 68 | ✗ |
| 69 | ✓ |
| 70 | ✓ |
| 71 | ✗ |
| 72 | ✗ |
| 73 | ✗ |
| 74 | ✓ |
| 75 | ✗ |
| **76** | ✗ |
| 77 | ✗ |
| 78 | ✗ |
| 79 | - |
| 80 | ✓ |
| 81 | ✗ |
| 82 | ✗ |
| 83 | ✗ |
| 84 | ✗ |
| 85 | ✗ |
| 86 | ✗ |
| 87 | ✗ |
| 88 | ✓ |
| 89 | ✓ |
| 90 | ✗ |
| 91 | ✗ |
| 92 | ✗ |
| 93 | ✗ |
| 94 | ✓ |
| 95 | ✗ |
| 96 | ✗ |

| | |
|---|---|
| 97 | ✗ |
| 98 | ✗ |
| 99 | ✓ |
| 100 | ✗ |
| 101 | ✗ |

All contents of this site are © 2024 Passmedicine Limited

Back to top

A 32-year-old woman is reviewed in the emergency department. She has developed a very painful rash on her left arm. It is a burning pain which preceded the formation of a rash. She has felt low in energy with this and has noticed that the rash is intensely tender to light touch. Apart from this she feels well in herself. She has a past medical history of appendicitis at the age of 18 which was treated surgically, and depression for which she has been attending cognitive behavioural therapy. On examination, she has an erythematous rash within on the underarm on the left side, roughly 8cm in length. There are small vesicles within this. She is diagnosed with shingles, and told that she can infect people with chicken-pox. She wonders how long she will be infectious for. What is the most appropriate advise?

- She will be infectious until she starts aciclovir
- She will be infectious up to two weeks from onset of rash
- She will be infectious up to two months from onset of rash
- She will be infectious until her vesicles have crusted over
- She will no longer be infectious as vesicles have appeared

Submit answer

Reference ranges

Score: **14%**

1 ✗
2 ✗
3 ✓
4 ✗
5 ✗

| | |
|---|---|
| 6 | ✗ |
| 7 | ✗ |
| 8 | ✗ |
| 9 | ✗ |
| 10 | ✗ |
| 11 | ✓ |
| 12 | ✗ |
| 13 | ✓ |
| 14 | ✗ |
| 15 | ✗ |
| 16 | ✗ |
| 17 | ✗ |
| 18 | ✗ |
| 19 | ✗ |
| 20 | ✗ |
| 21 | ✗ |
| 22 | ✗ |
| 23 | ✗ |
| 24 | ✗ |
| 25 | ✗ |
| 26 | ✓ |
| 27 | ✗ |
| 28 | ✗ |
| 29 | ✗ |
| 30 | ✗ |
| 31 | ✗ |
| 32 | ✓ |
| 33 | ✗ |
| 34 | ✗ |
| 35 | ✗ |
| 36 | ✗ |
| 37 | ✗ |
| 38 | ✗ |
| 39 | ✗ |
| 40 | ✗ |
| 41 | ✗ |

| | |
|---|---|
| 42 | ✗ |
| 43 | ✗ |
| 44 | ✓ |
| 45 | ✗ |
| 46 | ✗ |
| 47 | ✓ |
| 48 | ✗ |
| 49 | ✗ |
| 50 | ✗ |
| 51 | - |
| 52 | - |
| 53 | - |
| 54 | - |
| 55 | - |
| 56 | - |
| 57 | - |
| 58 | - |
| 59 | - |
| 60 | - |
| 61 | - |
| 62 | - |
| 63 | - |
| 64 | - |
| 65 | - |
| 66 | - |
| 67 | - |
| 68 | - |
| 69 | - |
| 70 | - |
| 71 | - |
| 72 | - |
| 73 | - |
| 74 | - |
| 75 | - |
| 76 | - |
| **77** | - |
| 78 | - |
| 79 | - |
| 80 | - |

All contents of this site are © 2024 Passmedicine Limited
Back to top

A 32-year-old woman is reviewed in the emergency department. She has developed a very painful rash on her left arm. It is a burning pain which preceded the formation of a rash. She has felt low in energy with this and has noticed that the rash is intensely tender to light touch. Apart from this she feels well in herself. She has a past medical history of appendicitis at the age of 18 which was treated surgically, and depression for which she has been attending cognitive behavioural therapy. On examination, she has an erythematous rash within on the underarm on the left side, roughly 8cm in length. There are small vesicles within this. She is diagnosed with shingles, and told that she can infect people with chicken-pox. She wonders how long she will be infectious for. What is the most appropriate advise?

- She will be infectious until she starts aciclovir — 1%
- She will be infectious up to two weeks from onset of rash — 6%
- She will be infectious up to two months from onset of rash — 1%
- She will be infectious until her vesicles have crusted over — 88%
- She will no longer be infectious as vesicles have appeared — 5%

People with shingles should be advised that they are infectious until the vesicles have crusted over, usually 5-7 days following onset

Important for me Less important

This patient has shingles, acute reactivation of herpes zoster virus (HZV). HZV in the form of shingles is contagious, but exposure could cause chickenpox, rather than shingles. People who have had chickenpox previously would be considered immune, but adults and especially pregnant women who have not had chickenpox are at risk of serious infection.

The patient is infectious until the vesicles have crusted over.

Discuss (2) Improve

Next question

# Shingles

Shingles (herpes zoster infection) is an acute, unilateral, painful blistering rash caused by reactivation of the varicella-zoster virus (VZV). Following primary infection with VZV (chickenpox), the virus lies dormant in the dorsal root or cranial nerve ganglia.

Risk factors

- increasing age
- HIV: strong risk factor, 15 times more common
- other immunosuppressive conditions (e.g. steroids, chemotherapy)

The most commonly affected dermatomes are T1-L2.

Features

- prodromal period
  - burning pain over the affected dermatome for 2-3 days
  - pain may be severe and interfere with sleep
  - around 20% of patients will experience fever, headache, lethargy
- rash
  - initially erythematous, macular rash over the affected dermatome
  - quickly becomes vesicular
  - characteristically is well demarcated by the dermatome and does not cross the midline. However, some 'bleeding' into adjacent areas may be seen

The diagnosis is usually clinical.

Management

- remind patients they are potentially infectious
  - may need to avoid pregnant women and the immunosuppressed
  - should be advised that they are infectious until the vesicles have crusted over, usually 5-7 days following onset
  - covering lesions reduces the risk
- analgesia

- paracetamol and NSAIDs are first-line
- if not responding then use of neuropathic agents (e.g. amitriptyline) can be considered
- oral corticosteroids may be considered in the first 2 weeks in immunocompetent adults with localized shingles if the pain is severe and not responding to the above treatments

- antivirals
  - NICE makes recommendations on when to use antivirals
  - in practice, they recommend antivirals within 72 hours for the majority of patients, unless the patient is < 50 years and has a 'mild' truncal rash associated with mild pain and no underlying risk factors
  - one of the benefits of prescribing antivirals is a reduced incidence of post-herpetic neuralgia, particularly in older people
  - aciclovir, famciclovir, or valaciclovir are recommended

Complications

- post-herpetic neuralgia
  - the most common complications
  - more common in older patients
  - affects between 5%-30% of patients depending on age
  - most commonly resolves with 6 months but may last longer
- herpes zoster ophthalmicus (shingles affecting affecting the ocular division of the trigeminal nerve) is associated with a variety of ocular complications
- herpes zoster oticus (Ramsay Hunt syndrome): may result in ear lesions and facial paralysis

AI + Q 123

Next question >

**Textbooks**

High-yield textbook

Extended textbook

## Links

Clinical Knowledge Summaries 8 7

Shingles guidelines

Suggest link | Report broken link

## Media

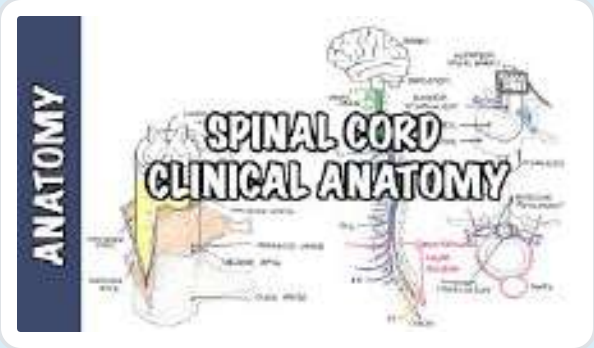


Spinal Cord - Clinical Anatomy and Physiology (dermatomes, blood supply, shingles, lumbar puncture)

Armando Hasudungan - YouTube 2 1

Report broken media

Score: **17%**

1 ✗
2 ✗
3 ✓
4 ✗
5 ✗
6 ✗
7 ✗
8 ✗
9 ✗
10 ✗
11 ✓
12 ✗
13 ✓
14 ✗
15 ✗

| | |
|---|---|
| 16 | ✗ |
| 17 | ✗ |
| 18 | ✗ |
| 19 | ✗ |
| 20 | ✗ |
| 21 | ✗ |
| 22 | ✗ |
| 23 | ✗ |
| 24 | ✗ |
| 25 | ✗ |
| 26 | ✓ |
| 27 | ✗ |
| 28 | ✗ |
| 29 | ✗ |
| 30 | ✗ |
| 31 | ✗ |
| 32 | ✓ |
| 33 | ✗ |
| 34 | ✗ |
| 35 | ✗ |
| 36 | ✗ |
| 37 | ✗ |
| 38 | ✗ |
| 39 | ✗ |
| 40 | ✗ |
| 41 | ✗ |
| 42 | ✗ |
| 43 | ✗ |
| 44 | ✓ |
| 45 | ✗ |
| 46 | ✗ |
| 47 | ✓ |
| 48 | ✗ |
| 49 | ✗ |
| 50 | ✗ |
| 51 | ✗ |

| | |
|---|---|
| 52 | ✗ |
| 53 | ✗ |
| 54 | ✗ |
| 55 | ✗ |
| 56 | ✗ |
| 57 | ✗ |
| 58 | ✗ |
| 59 | ✗ |
| 60 | ✗ |
| 61 | ✗ |
| 62 | ✓ |
| 63 | ✗ |
| 64 | ✗ |
| 65 | ✓ |
| 66 | ✗ |
| 67 | ✗ |
| 68 | ✗ |
| 69 | ✓ |
| 70 | ✓ |
| 71 | ✗ |
| 72 | ✗ |
| 73 | ✗ |
| 74 | ✓ |
| 75 | ✗ |
| 76 | ✗ |
| **77** | ✗ |
| 78 | ✗ |
| 79 | - |
| 80 | ✓ |
| 81 | ✗ |
| 82 | ✗ |
| 83 | ✗ |
| 84 | ✗ |
| 85 | ✗ |
| 86 | ✗ |
| 87 | ✗ |

| | |
|---|---|
| 88 | ✓ |
| 89 | ✓ |
| 90 | ✗ |
| 91 | ✗ |
| 92 | ✗ |
| 93 | ✗ |
| 94 | ✓ |
| 95 | ✗ |
| 96 | ✗ |
| 97 | ✗ |
| 98 | ✗ |
| 99 | ✓ |
| 100 | ✗ |
| 101 | ✗ |

All contents of this site are © 2024 Passmedicine Limited

Back to top

A 75-year-old asks you to have a look at a lesion on his right ear. It has developed slowly over the past few months and is tender to palpation.

© Image used on license from DermNet NZ

What is the most likely diagnosis?

- Cystic chondromalacia
- Actinic keratosis
- Chondrodermatitis nodularis helicis
- Perichondritis
- Keratin horn

Submit answer

Reference ranges

Score: **14%**

| | |
|---|---|
| 1 | ✗ |
| 2 | ✗ |
| 3 | ✓ |
| 4 | ✗ |
| 5 | ✗ |
| 6 | ✗ |
| 7 | ✗ |
| 8 | ✗ |
| 9 | ✗ |
| 10 | ✗ |
| 11 | ✓ |
| 12 | ✗ |
| 13 | ✓ |
| 14 | ✗ |
| 15 | ✗ |
| 16 | ✗ |
| 17 | ✗ |
| 18 | ✗ |
| 19 | ✗ |
| 20 | ✗ |
| 21 | ✗ |
| 22 | ✗ |
| 23 | ✗ |
| 24 | ✗ |
| 25 | ✗ |
| 26 | ✓ |
| 27 | ✗ |
| 28 | ✗ |
| 29 | ✗ |
| 30 | ✗ |
| 31 | ✗ |
| 32 | ✓ |
| 33 | ✗ |

| | |
|---|---|
| 34 | ✗ |
| 35 | ✗ |
| 36 | ✗ |
| 37 | ✗ |
| 38 | ✗ |
| 39 | ✗ |
| 40 | ✗ |
| 41 | ✗ |
| 42 | ✗ |
| 43 | ✗ |
| 44 | ✓ |
| 45 | ✗ |
| 46 | ✗ |
| 47 | ✓ |
| 48 | ✗ |
| 49 | ✗ |
| 50 | ✗ |
| 51 | - |
| 52 | - |
| 53 | - |
| 54 | - |
| 55 | - |
| 56 | - |
| 57 | - |
| 58 | - |
| 59 | - |
| 60 | - |
| 61 | - |
| 62 | - |
| 63 | - |
| 64 | - |
| 65 | - |
| 66 | - |
| 67 | - |
| 68 | - |
| 69 | - |
| 70 | - |
| 71 | - |

| | |
|---|---|
| 72 | - |
| 73 | - |
| 74 | - |
| 75 | - |
| 76 | - |
| 77 | - |
| **78** | - |
| 79 | - |
| 80 | - |

All contents of this site are © 2024 Passmedicine Limited

A 75-year-old asks you to have a look at a lesion on his right ear. It has developed slowly over the past few months and is tender to palpation.

© Image used on license from DermNet NZ

What is the most likely diagnosis?

- Cystic chondromalacia 2%
- Actinic keratosis 20%
- Chondrodermatitis nodularis helicis 70%
- Perichondritis 3%
- Keratin horn 5%

The correct answer is **Chondrodermatitis nodularis helicis**. This condition is a benign inflammatory process affecting the ear's cartilage and overlying skin. It typically presents as a tender nodule on the helix or antihelix of the ear, often in elderly patients. The slow development and tenderness to palpation of this patient's lesion are classic signs of chondrodermatitis nodularis helicis.

**Cystic chondromalacia**, also known as Relapsing Polychondritis, is an incorrect choice because it is a rare multi-system disorder characterized by recurrent episodes of painful inflammation and

deterioration of cartilage throughout the body. It would not present as a solitary lesion on the ear; instead, it often affects multiple sites including ears, nose, joints, respiratory tract and eyes.

**Actinic keratosis** is another incorrect option. While actinic keratosis can indeed present as a rough, scaly patch on sun-exposed skin (such as the ear), it is usually not tender unless it has progressed into squamous cell carcinoma. Furthermore, actinic keratosis lesions generally develop more rapidly than what was described in this case.

The option **Perichondritis** does involve inflammation of the ear cartilage but it's incorrect because perichondritis is typically caused by trauma to the ear or following ear surgery. It presents acutely with severe pain, redness and swelling around the entire ear structure rather than a slowly developing single nodule.

Finally, **Keratin horn** refers to a projection from the skin resulting from overgrowth of keratin. These lesions are typically hard and non-tender which contrasts with this patient's presentation of a tender lesion.

Discuss (2) Improve

Next question

## Chondrodermatitis nodularis helicis

Chondrodermatitis nodularis helicis (CNH) is a common and benign condition characterised by the development of a painful nodule on the ear. It is thought to be caused by factors such as persistent pressure on the ear (e.g. secondary to sleep, headsets), trauma or cold. CNH is more common in men and with increasing age.

Management

- reducing pressure on the ear: foam 'ear protectors' may be used during sleep
- other treatment options include cryotherapy, steroid injection, collagen injection
- surgical treatment may be used but there is a high recurrence rate

**Image gallery**

Next question

## Textbooks

High-yield textbook

Extended textbook

## Links

Primary Care Dermatology Societ 4 1

Chondrodermatitis nodularis helicis

DermNet NZ 1 0

Chondrodermatitis nodularis

Suggest link

Report broken link

Score: **17%**

1 ✗
2 ✗
3 ✓
4 ✗
5 ✗

| | |
|---|---|
| 6 | ✗ |
| 7 | ✗ |
| 8 | ✗ |
| 9 | ✗ |
| 10 | ✗ |
| 11 | ✓ |
| 12 | ✗ |
| 13 | ✓ |
| 14 | ✗ |
| 15 | ✗ |
| 16 | ✗ |
| 17 | ✗ |
| 18 | ✗ |
| 19 | ✗ |
| 20 | ✗ |
| 21 | ✗ |
| 22 | ✗ |
| 23 | ✗ |
| 24 | ✗ |
| 25 | ✗ |
| 26 | ✓ |
| 27 | ✗ |
| 28 | ✗ |
| 29 | ✗ |
| 30 | ✗ |
| 31 | ✗ |
| 32 | ✓ |
| 33 | ✗ |
| 34 | ✗ |
| 35 | ✗ |
| 36 | ✗ |
| 37 | ✗ |
| 38 | ✗ |
| 39 | ✗ |
| 40 | ✗ |
| 41 | ✗ |

| | |
|---|---|
| 42 | ✗ |
| 43 | ✗ |
| 44 | ✓ |
| 45 | ✗ |
| 46 | ✗ |
| 47 | ✓ |
| 48 | ✗ |
| 49 | ✗ |
| 50 | ✗ |
| 51 | ✗ |
| 52 | ✗ |
| 53 | ✗ |
| 54 | ✗ |
| 55 | ✗ |
| 56 | ✗ |
| 57 | ✗ |
| 58 | ✗ |
| 59 | ✗ |
| 60 | ✗ |
| 61 | ✗ |
| 62 | ✓ |
| 63 | ✗ |
| 64 | ✗ |
| 65 | ✓ |
| 66 | ✗ |
| 67 | ✗ |
| 68 | ✗ |
| 69 | ✓ |
| 70 | ✓ |
| 71 | ✗ |
| 72 | ✗ |
| 73 | ✗ |
| 74 | ✓ |
| 75 | ✗ |
| 76 | ✗ |
| 77 | ✗ |

| | |
|---|---|
| **78** | ✗ |
| 79 | - |
| 80 | ✓ |
| 81 | ✗ |
| 82 | ✗ |
| 83 | ✗ |
| 84 | ✗ |
| 85 | ✗ |
| 86 | ✗ |
| 87 | ✗ |
| 88 | ✓ |
| 89 | ✓ |
| 90 | ✗ |
| 91 | ✗ |
| 92 | ✗ |
| 93 | ✗ |
| 94 | ✓ |
| 95 | ✗ |
| 96 | ✗ |
| 97 | ✗ |
| 98 | ✗ |
| 99 | ✓ |
| 100 | ✗ |
| 101 | ✗ |

All contents of this site are © 2024 Passmedicine Limited

A 37-year-old gentleman is referred to the cardiology clinic with a 7-month history of bilateral foot pain. Initially, the pain only occurred towards the end of his daily commute; improving when he sat at his desk, but over the past 3 weeks his symptoms have progressed. The pain is now provoked by walking short distances and has occasionally occurred at rest. He describes being woken by the pain at night, although he is able to obtain relief by standing on the cool tiles in his bathroom. He eventually decided to see his GP when he developed similar pain in his right wrist 10 days ago.

His past medical history is unremarkable. There is no history of hypertension, dyslipidaemia or diabetes. He is a current smoker with a 20 pack year history. He drinks alcohol in moderation.

On examination, both feet are noted to be smooth and hairless. The right dorsalis pedis is difficult to feel and the medial 3 toes are cold and dusky. Urgent angiography is performed and shows a number of distal stenoses in the right limb affecting the anterior and posterior tibial arteries as well as the distal fibular artery. A number of similar stenoses are seen in the contralateral limb with 'corkscrew' collateral formation.

Blood tests are as follows:

| | | | |
|---|---|---|---|
| Hb | 130 g/l | $Na^+$ | 139 mmol/l |
| Platelets | $322*10^9$/l | $K^+$ | 4.1 mmol/l |
| WBC | $9.1*10^9$/l | Urea | 5.3 mmol/l |
| Neuts | $6.2*10^9$/l | Creatinine | 113 µmol/l |
| Lymphs | $2.1*10^9$/l | CRP | 19 mg/l |
| Eosin | $0.1*10^9$/l | | |

| | |
|---|---|
| MPO | negative |
| PR3 | negative |
| anti-cardiolipin | negative |

What is the most likely diagnosis?

- Peripheral vascular disease

- Microscopic polyangiitis
- Takayasu arteritis
- Thromboangiitis obliterans
- Polyarteritis nodosa

Submit answer

Reference ranges

Score: **14%**

| | |
|---|---|
| 1 | ✗ |
| 2 | ✗ |
| 3 | ✓ |
| 4 | ✗ |
| 5 | ✗ |
| 6 | ✗ |
| 7 | ✗ |
| 8 | ✗ |
| 9 | ✗ |
| 10 | ✗ |
| 11 | ✓ |
| 12 | ✗ |
| 13 | ✓ |
| 14 | ✗ |
| 15 | ✗ |
| 16 | ✗ |
| 17 | ✗ |
| 18 | ✗ |
| 19 | ✗ |

| | |
|---|---|
| 20 | ✗ |
| 21 | ✗ |
| 22 | ✗ |
| 23 | ✗ |
| 24 | ✗ |
| 25 | ✗ |
| 26 | ✓ |
| 27 | ✗ |
| 28 | ✗ |
| 29 | ✗ |
| 30 | ✗ |
| 31 | ✗ |
| 32 | ✓ |
| 33 | ✗ |
| 34 | ✗ |
| 35 | ✗ |
| 36 | ✗ |
| 37 | ✗ |
| 38 | ✗ |
| 39 | ✗ |
| 40 | ✗ |
| 41 | ✗ |
| 42 | ✗ |
| 43 | ✗ |
| 44 | ✓ |
| 45 | ✗ |
| 46 | ✗ |
| 47 | ✓ |
| 48 | ✗ |
| 49 | ✗ |
| 50 | ✗ |
| 51 | - |
| 52 | - |
| 53 | - |
| 54 | - |
| 55 | - |
| 56 | - |

57 -
58 -
59 -
60 -
61 -
62 -
63 -
64 -
65 -
66 -
67 -
68 -
69 -
70 -
71 -
72 -
73 -
74 -
75 -
76 -
77 -
78 -
**79** -
80 -

All contents of this site are © 2024 Passmedicine Limited

Back to top

A 37-year-old gentleman is referred to the cardiology clinic with a 7-month history of bilateral foot pain. Initially, the pain only occurred towards the end of his daily commute; improving when he sat at his desk, but over the past 3 weeks his symptoms have progressed. The pain is now provoked by walking short distances and has occasionally occurred at rest. He describes being woken by the pain at night, although he is able to obtain relief by standing on the cool tiles in his bathroom. He eventually decided to see his GP when he developed similar pain in his right wrist 10 days ago.

His past medical history is unremarkable. There is no history of hypertension, dyslipidaemia or diabetes. He is a current smoker with a 20 pack year history. He drinks alcohol in moderation.

On examination, both feet are noted to be smooth and hairless. The right dorsalis pedis is difficult to feel and the medial 3 toes are cold and dusky. Urgent angiography is performed and shows a number of distal stenoses in the right limb affecting the anterior and posterior tibial arteries as well as the distal fibular artery. A number of similar stenoses are seen in the contralateral limb with 'corkscrew' collateral formation.

Blood tests are as follows:

| | | | |
|---|---|---|---|
| Hb | 130 g/l | $Na^+$ | 139 mmol/l |
| Platelets | $322*10^9$/l | $K^+$ | 4.1 mmol/l |
| WBC | $9.1*10^9$/l | Urea | 5.3 mmol/l |
| Neuts | $6.2*10^9$/l | Creatinine | 113 µmol/l |
| Lymphs | $2.1*10^9$/l | CRP | 19 mg/l |
| Eosin | $0.1*10^9$/l | | |

| | |
|---|---|
| MPO | negative |
| PR3 | negative |
| anti-cardiolipin | negative |

What is the most likely diagnosis?

- Peripheral vascular disease

- ◯ Microscopic polyangiitis ×
- ◯ Takayasu arteritis ×
- ◯ Thromboangiitis obliterans ×
- ◯ Polyarteritis nodosa ×

Submit answer

Reference ranges

Score: **17%**

| | |
|---|---|
| 1 | ✗ |
| 2 | ✗ |
| 3 | ✓ |
| 4 | ✗ |
| 5 | ✗ |
| 6 | ✗ |
| 7 | ✗ |
| 8 | ✗ |
| 9 | ✗ |
| 10 | ✗ |
| 11 | ✓ |
| 12 | ✗ |
| 13 | ✓ |
| 14 | ✗ |
| 15 | ✗ |
| 16 | ✗ |
| 17 | ✗ |
| 18 | ✗ |
| 19 | ✗ |

| | |
|---|---|
| 20 | ✗ |
| 21 | ✗ |
| 22 | ✗ |
| 23 | ✗ |
| 24 | ✗ |
| 25 | ✗ |
| 26 | ✓ |
| 27 | ✗ |
| 28 | ✗ |
| 29 | ✗ |
| 30 | ✗ |
| 31 | ✗ |
| 32 | ✓ |
| 33 | ✗ |
| 34 | ✗ |
| 35 | ✗ |
| 36 | ✗ |
| 37 | ✗ |
| 38 | ✗ |
| 39 | ✗ |
| 40 | ✗ |
| 41 | ✗ |
| 42 | ✗ |
| 43 | ✗ |
| 44 | ✓ |
| 45 | ✗ |
| 46 | ✗ |
| 47 | ✓ |
| 48 | ✗ |
| 49 | ✗ |
| 50 | ✗ |
| 51 | ✗ |
| 52 | ✗ |
| 53 | ✗ |
| 54 | ✗ |
| 55 | ✗ |

| | |
|---|---|
| 56 | ✗ |
| 57 | ✗ |
| 58 | ✗ |
| 59 | ✗ |
| 60 | ✗ |
| 61 | ✗ |
| 62 | ✓ |
| 63 | ✗ |
| 64 | ✗ |
| 65 | ✓ |
| 66 | ✗ |
| 67 | ✗ |
| 68 | ✗ |
| 69 | ✓ |
| 70 | ✓ |
| 71 | ✗ |
| 72 | ✗ |
| 73 | ✗ |
| 74 | ✓ |
| 75 | ✗ |
| 76 | ✗ |
| 77 | ✗ |
| 78 | ✗ |
| **79** | - |
| 80 | ✓ |
| 81 | ✗ |
| 82 | ✗ |
| 83 | ✗ |
| 84 | ✗ |
| 85 | ✗ |
| 86 | ✗ |
| 87 | ✗ |
| 88 | ✓ |
| 89 | ✓ |
| 90 | ✗ |
| 91 | ✗ |

| | |
|---|---|
| 92 | ✗ |
| 93 | ✗ |
| 94 | ✓ |
| 95 | ✗ |
| 96 | ✗ |
| 97 | ✗ |
| 98 | ✗ |
| 99 | ✓ |
| 100 | ✗ |
| 101 | ✗ |

All contents of this site are © 2024 Passmedicine Limited

Back to top

A 54-year-old man comes to the dermatology clinic for review. He has a hyperpigmented rash affecting the back of his neck, his axillae and his groin that has become more prominent over the past few weeks. There has been increased shortness of breath and decreased exercise tolerance over the past 3 months. He smokes 20 cigarettes per day and is treated for COPD with a high dose salmeterol / fluticasone combination inhaler. Examination reveals a blood pressure of 132/82 mmHg, and a pulse of 65 beats per minute. You confirm the rash. There is quiet wheeze on auscultation of the chest. Abdomen is soft and he complains of mild tenderness in epigastrium. His body mass index is 22 kg/m$^2$.

Investigations

| | | | |
|---|---|---|---|
| Hb | 90 g/l | $Na^+$ | 140 mmol/l |
| Platelets | 191 * $10^9$/l | $K^+$ | 4.3 mmol/l |
| WBC | 7.0 * $10^9$/l | Urea | 7.2 mmol/l |
| Neuts | 3.2 * $10^9$/l | Creatinine | 110 µmol/l |
| Lymphs | 1.4 * $10^9$/l | CRP | 32 mg/l |
| ESR | 72 mm/hr | | |

Which of the following is the most useful next investigation?

- Bronchoscopy
- Colonoscopy
- Skin biopsy
- Ultrasound abdomen
- Upper gastrointestinal endoscopy

Submit answer

Reference ranges

Score: **14%**

| | |
|---|---|
| 1 | ✗ |
| 2 | ✗ |
| 3 | ✓ |
| 4 | ✗ |
| 5 | ✗ |
| 6 | ✗ |
| 7 | ✗ |
| 8 | ✗ |
| 9 | ✗ |
| 10 | ✗ |
| 11 | ✓ |
| 12 | ✗ |
| 13 | ✓ |
| 14 | ✗ |
| 15 | ✗ |
| 16 | ✗ |
| 17 | ✗ |
| 18 | ✗ |
| 19 | ✗ |
| 20 | ✗ |
| 21 | ✗ |
| 22 | ✗ |
| 23 | ✗ |
| 24 | ✗ |
| 25 | ✗ |
| 26 | ✓ |
| 27 | ✗ |
| 28 | ✗ |
| 29 | ✗ |
| 30 | ✗ |

| | |
|---|---|
| 31 | ✗ |
| 32 | ✓ |
| 33 | ✗ |
| 34 | ✗ |
| 35 | ✗ |
| 36 | ✗ |
| 37 | ✗ |
| 38 | ✗ |
| 39 | ✗ |
| 40 | ✗ |
| 41 | ✗ |
| 42 | ✗ |
| 43 | ✗ |
| 44 | ✓ |
| 45 | ✗ |
| 46 | ✗ |
| 47 | ✓ |
| 48 | ✗ |
| 49 | ✗ |
| 50 | ✗ |
| 51 | - |
| 52 | - |
| 53 | - |
| 54 | - |
| 55 | - |
| 56 | - |
| 57 | - |
| 58 | - |
| 59 | - |
| 60 | - |
| 61 | - |
| 62 | - |
| 63 | - |
| 64 | - |
| 65 | - |
| 66 | - |
| 67 | - |
| 68 | - |

69 -
70 -
71 -
72 -
73 -
74 -
75 -
76 -
77 -
78 -
79 -
**80** -

All contents of this site are © 2024 Passmedicine Limited

A 54-year-old man comes to the dermatology clinic for review. He has a hyperpigmented rash affecting the back of his neck, his axillae and his groin that has become more prominent over the past few weeks. There has been increased shortness of breath and decreased exercise tolerance over the past 3 months. He smokes 20 cigarettes per day and is treated for COPD with a high dose salmeterol / fluticasone combination inhaler. Examination reveals a blood pressure of 132/82 mmHg, and a pulse of 65 beats per minute. You confirm the rash. There is quiet wheeze on auscultation of the chest. Abdomen is soft and he complains of mild tenderness in epigastrium. His body mass index is 22 kg/m$^2$.

Investigations

| | | | |
|---|---|---|---|
| Hb | 90 g/l | $Na^+$ | 140 mmol/l |
| Platelets | 191 * $10^9$/l | $K^+$ | 4.3 mmol/l |
| WBC | 7.0 * $10^9$/l | Urea | 7.2 mmol/l |
| Neuts | 3.2 * $10^9$/l | Creatinine | 110 µmol/l |
| Lymphs | 1.4 * $10^9$/l | CRP | 32 mg/l |
| ESR | 72 mm/hr | | |

Which of the following is the most useful next investigation?

- Bronchoscopy 14%
- Colonoscopy 7%
- Skin biopsy 10%
- Ultrasound abdomen 9%
- Upper gastrointestinal endoscopy 61%

The most common malignancy associated with acanthosis nigricans is gastrointestinal adenocarcinoma

Important for me Less important

The character of the rash is most suggestive of a diagnosis of acanthosis nigricans. Given the history of smoking and the anaemia, the possibility of underlying gastric cancer is raised, for this reason, an endoscopy +/- biopsy of any lesion is the most useful next step.

Bronchoscopy isn't indicated, nor is a colonoscopy, because lung cancer and colon cancer are not as strongly associated with acanthosis. Ultrasound of the abdomen may reveal an epigastric mass, but it is a relatively insensitive way of detecting gastric cancer. Skin biopsy reveals hyperkeratosis and papillomatosis, relatively minor hyperpigmentation is also seen.

Discuss (3) Improve

Next question

# Acanthosis nigricans

Describes symmetrical, brown, velvety plaques that are often found on the neck, axilla and groin.

Causes

- type 2 diabetes mellitus
- gastrointestinal cancer
- obesity
- polycystic ovarian syndrome
- acromegaly
- Cushing's disease
- hypothyroidism
- familial
- Prader-Willi syndrome
- drugs
    - combined oral contraceptive pill
    - nicotinic acid

Pathophysiology

- insulin resistance → hyperinsulinemia → stimulation of keratinocytes and dermal fibroblast proliferation via interaction with insulin-like growth factor receptor-1 (IGFR1)

123

Next question

## Textbooks

High-yield textbook

Extended textbook

## Links

DermNet NZ 54 21

Acanthosis nigricans

Suggest link

Report broken link

Score: **17%**

1 ✗
2 ✗
3 ✓

| | |
|---|---|
| 4 | ✗ |
| 5 | ✗ |
| 6 | ✗ |
| 7 | ✗ |
| 8 | ✗ |
| 9 | ✗ |
| 10 | ✗ |
| 11 | ✓ |
| 12 | ✗ |
| 13 | ✓ |
| 14 | ✗ |
| 15 | ✗ |
| 16 | ✗ |
| 17 | ✗ |
| 18 | ✗ |
| 19 | ✗ |
| 20 | ✗ |
| 21 | ✗ |
| 22 | ✗ |
| 23 | ✗ |
| 24 | ✗ |
| 25 | ✗ |
| 26 | ✓ |
| 27 | ✗ |
| 28 | ✗ |
| 29 | ✗ |
| 30 | ✗ |
| 31 | ✗ |
| 32 | ✓ |
| 33 | ✗ |
| 34 | ✗ |
| 35 | ✗ |
| 36 | ✗ |
| 37 | ✗ |
| 38 | ✗ |
| 39 | ✗ |

40 ✗
41 ✗
42 ✗
43 ✗
44 ✓
45 ✗
46 ✗
47 ✓
48 ✗
49 ✗
50 ✗
51 ✗
52 ✗
53 ✗
54 ✗
55 ✗
56 ✗
57 ✗
58 ✗
59 ✗
60 ✗
61 ✗
62 ✓
63 ✗
64 ✗
65 ✓
66 ✗
67 ✗
68 ✗
69 ✓
70 ✓
71 ✗
72 ✗
73 ✗
74 ✓
75 ✗

| | |
|---|---|
| 76 | ✗ |
| 77 | ✗ |
| 78 | ✗ |
| 79 | - |
| **80** | ✓ |
| 81 | ✗ |
| 82 | ✗ |
| 83 | ✗ |
| 84 | ✗ |
| 85 | ✗ |
| 86 | ✗ |
| 87 | ✗ |
| 88 | ✓ |
| 89 | ✓ |
| 90 | ✗ |
| 91 | ✗ |
| 92 | ✗ |
| 93 | ✗ |
| 94 | ✓ |
| 95 | ✗ |
| 96 | ✗ |
| 97 | ✗ |
| 98 | ✗ |
| 99 | ✓ |
| 100 | ✗ |
| 101 | ✗ |

All contents of this site are © 2024 Passmedicine Limited

Back to top

A 16-year-old male is investigated for recurrent epistaxis, haemoptysis and iron-deficiency anaemia. Blood tests show the following:

| | |
|---|---|
| Hb | 11.1 g/dl |
| Platelets | 341 * $10^9$/l |
| WBC | 4.3 * $10^9$/l |

| | |
|---|---|
| Bilirubin | 33 µmol/l |
| ALP | 131 u/l |
| ALT | 54 u/l |
| γGT | 135 u/l |
| Albumin | 40 g/l |

A chest x-ray and CT abdomen are requested:

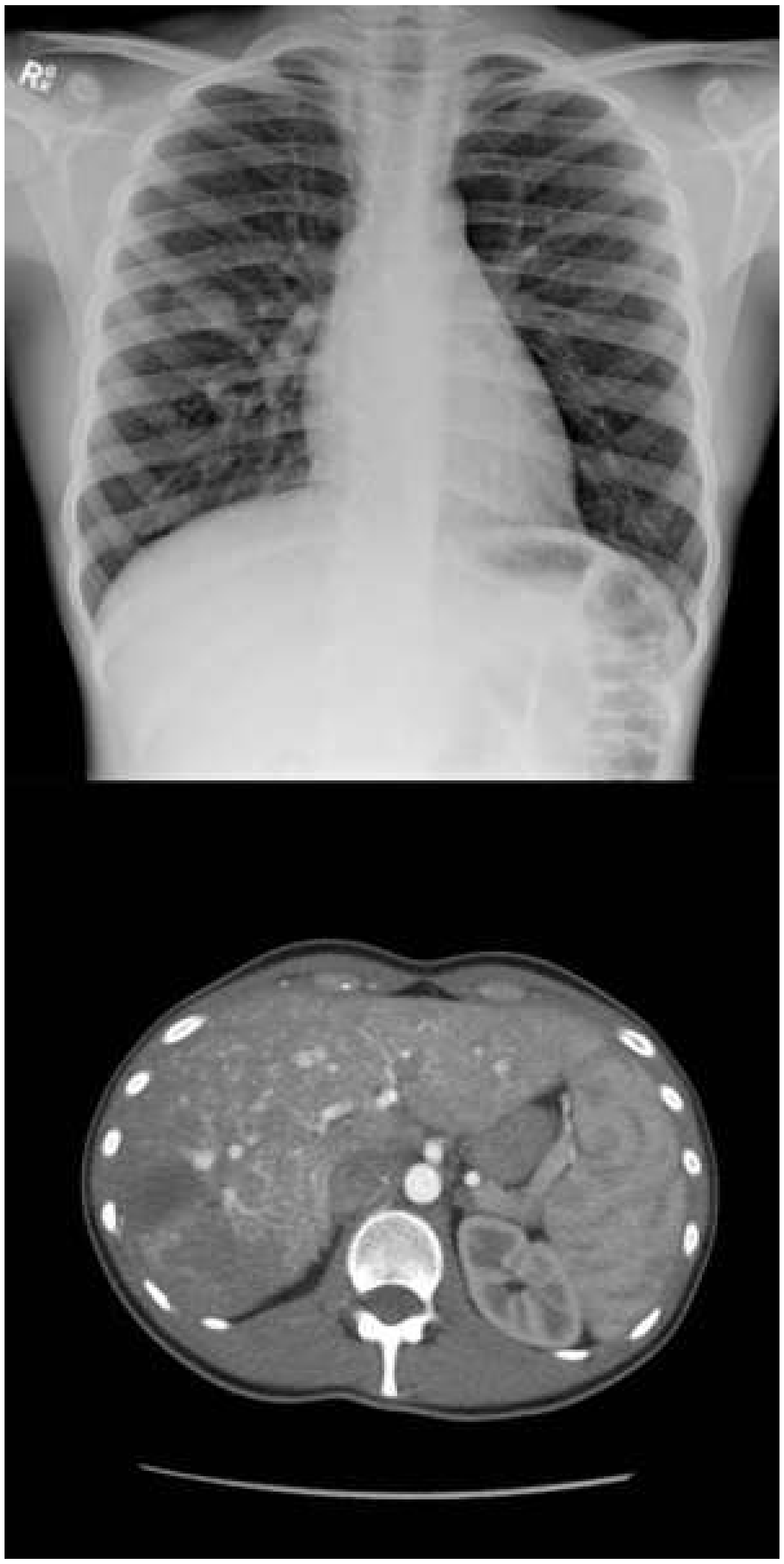

© Image used on license from Radiopaedia

What is the most likely diagnosis?

- Acute lymphoblastic leukaemia
- Metastatic cancer secondary to familial adenomatous polyposis
- Hereditary haemorrhagic telangiectasia
- Metastatic pleuropulmonary blastoma
- Peutz-Jeghers syndrome

Submit answer

Reference ranges

Score: **14%**

| | |
|---|---|
| 1 | ✗ |
| 2 | ✗ |
| 3 | ✓ |
| 4 | ✗ |
| 5 | ✗ |
| 6 | ✗ |
| 7 | ✗ |
| 8 | ✗ |
| 9 | ✗ |
| 10 | ✗ |
| 11 | ✓ |
| 12 | ✗ |
| 13 | ✓ |
| 14 | ✗ |
| 15 | ✗ |
| 16 | ✗ |
| 17 | ✗ |
| 18 | ✗ |
| 19 | ✗ |
| 20 | ✗ |
| 21 | ✗ |
| 22 | ✗ |
| 23 | ✗ |
| 24 | ✗ |
| 25 | ✗ |
| 26 | ✓ |
| 27 | ✗ |
| 28 | ✗ |
| 29 | ✗ |

| | |
|---|---|
| 30 | ✗ |
| 31 | ✗ |
| 32 | ✓ |
| 33 | ✗ |
| 34 | ✗ |
| 35 | ✗ |
| 36 | ✗ |
| 37 | ✗ |
| 38 | ✗ |
| 39 | ✗ |
| 40 | ✗ |
| 41 | ✗ |
| 42 | ✗ |
| 43 | ✗ |
| 44 | ✓ |
| 45 | ✗ |
| 46 | ✗ |
| 47 | ✓ |
| 48 | ✗ |
| 49 | ✗ |
| 50 | ✗ |
| 51 | - |
| 52 | - |
| 53 | - |
| 54 | - |
| 55 | - |
| 56 | - |
| 57 | - |
| 58 | - |
| 59 | - |
| 60 | - |
| 61 | - |
| 62 | - |
| 63 | - |
| 64 | - |
| 65 | - |
| 66 | - |
| 67 | - |

68 -
69 -
70 -
71 -
72 -
73 -
74 -
75 -
76 -
77 -
78 -
79 -
80 -
**81** -
82 -

All contents of this site are © 2024 Passmedicine Limited

A 16-year-old male is investigated for recurrent epistaxis, haemoptysis and iron-deficiency anaemia. Blood tests show the following:

| | |
|---|---|
| Hb | 11.1 g/dl |
| Platelets | 341 * $10^9$/l |
| WBC | 4.3 * $10^9$/l |

| | |
|---|---|
| Bilirubin | 33 µmol/l |
| ALP | 131 u/l |
| ALT | 54 u/l |
| γGT | 135 u/l |
| Albumin | 40 g/l |

A chest x-ray and CT abdomen are requested:

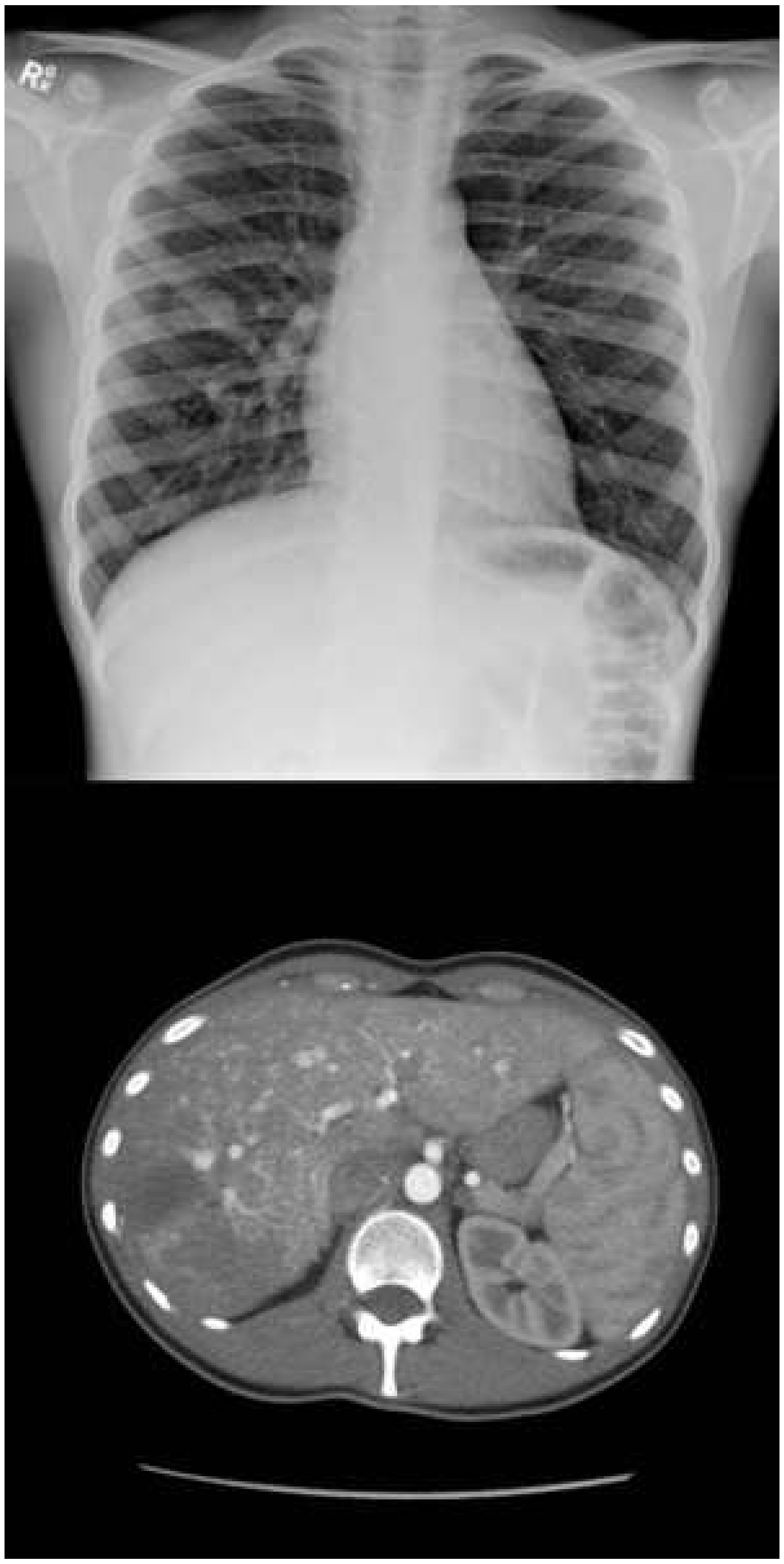


© Image used on license from Radiopaedia

What is the most likely diagnosis?

| | |
|---|---|
| Acute lymphoblastic leukaemia | 1% |
| Metastatic cancer secondary to familial adenomatous polyposis | 1% |
| Hereditary haemorrhagic telangiectasia | 89% |
| Metastatic pleuropulmonary blastoma | 3% |
| Peutz-Jeghers syndrome | 6% |

The correct answer is **Hereditary haemorrhagic telangiectasia**. This is a rare autosomal dominant disorder characterised by the presence of multiple arteriovenous malformations (AVMs)

that lack intervening capillaries and result in direct connections between arteries and veins.

The chest x-ray shows multiple pulmonary nodules representing arteriovenous malformations, the largest in the right mid-zone. The CT scan shows multiple hepatic arteriovenous malformations.

The clinical presentation of recurrent epistaxis, haemoptysis, and iron-deficiency anaemia in this 16-year-old male is suggestive of Hereditary haemorrhagic telangiectasia (HHT), also known as Osler-Weber-Rendu syndrome. HHT can affect various organs, including the lungs, liver, brain, and gastrointestinal tract, causing bleeding.

The other options are less likely based on the given information:

**Acute lymphoblastic leukaemia** typically presents with symptoms related to bone marrow suppression, such as fatigue, pallor, fever or infection due to neutropenia. This patient's blood test results do not show any significant abnormalities in white blood cell count or platelet count that would be expected in acute leukaemia.

**Metastatic cancer secondary to familial adenomatous polyposis** is an unlikely diagnosis as this condition is primarily associated with colorectal cancers developing from numerous adenomatous polyps in the colon. The patient's presenting symptoms of recurrent epistaxis and haemoptysis do not fit this diagnosis.

**Metastatic pleuropulmonary blastoma**, a rare malignant mesenchymal tumour of childhood affecting the lung parenchyma and pleura, usually presents with respiratory distress or pneumonia-like symptoms rather than recurrent epistaxis and haemoptysis.

Finally, **Peutz-Jeghers syndrome** is characterised by hamartomatous gastrointestinal polyps and mucocutaneous pigmentation. While this syndrome can cause anaemia due to gastrointestinal bleeding, it does not typically present with recurrent epistaxis or haemoptysis as seen in this patient.

Discuss (2) | Improve

Next question

## Hereditary haemorrhagic telangiectasia

Also known as Osler-Weber-Rendu syndrome, hereditary haemorrhagic telangiectasia (HHT) is an autosomal dominant condition characterised by (as the name suggests) multiple telangiectasia over the skin and mucous membranes. Twenty percent of cases occur spontaneously without prior family history.

There are 4 main diagnostic criteria. If the patient has 2 then they are said to have a possible diagnosis of HHT. If they meet 3 or more of the criteria they are said to have a definite diagnosis of HHT:

- epistaxis : spontaneous, recurrent nosebleeds
- telangiectases: multiple at characteristic sites (lips, oral cavity, fingers, nose)
- visceral lesions: for example gastrointestinal telangiectasia (with or without bleeding), pulmonary arteriovenous malformations (AVM), hepatic AVM, cerebral AVM, spinal AVM
- family history: a first-degree relative with HHT

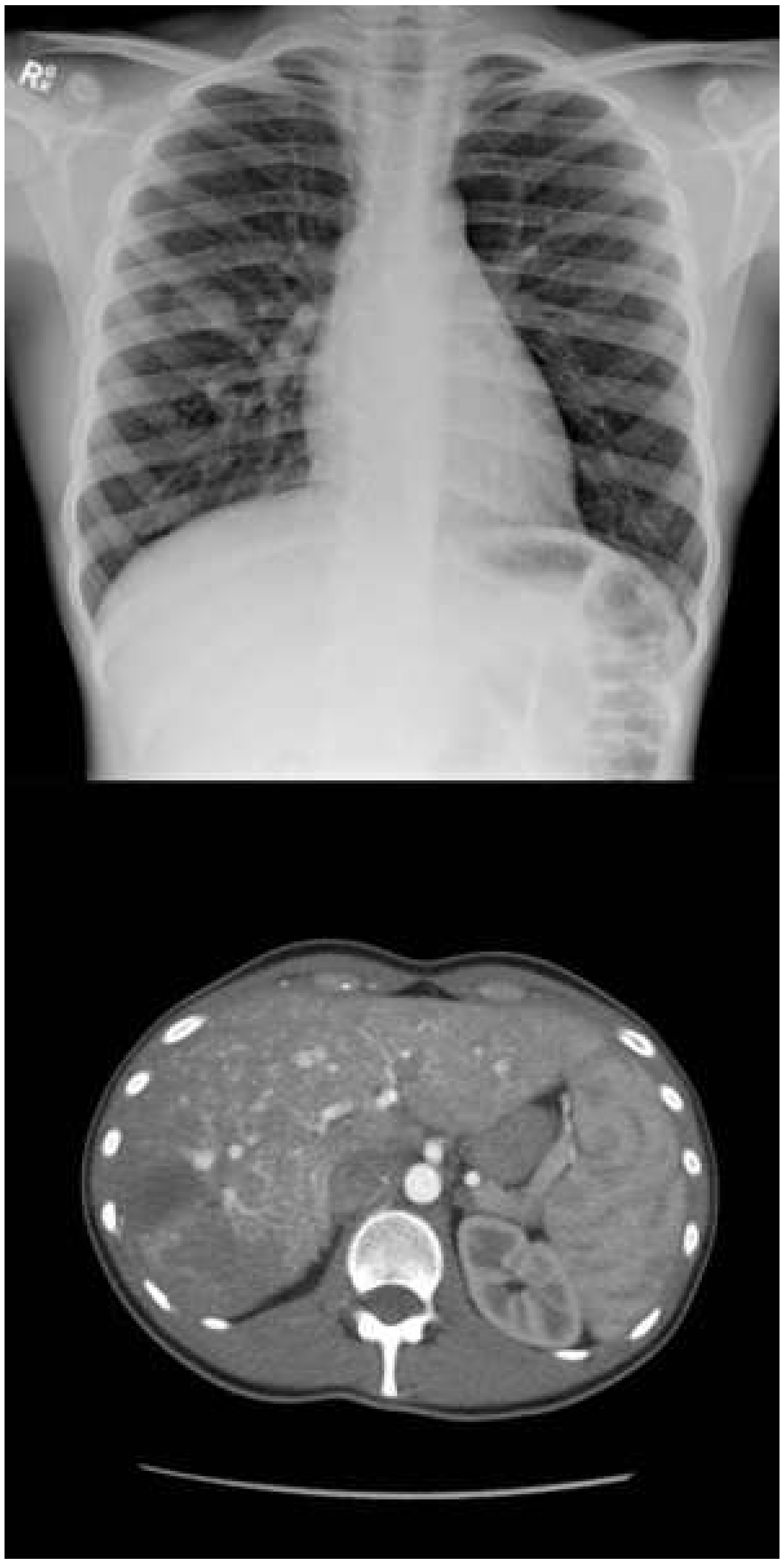

© Image used on license from Radiopaedia

The chest x-ray shows multiple pulmonary nodules representing arteriovenous malformations, the largest in the right mid-zone. The CT scan shows multiple hepatic arteriovenous malformations

AI + Q 123

Next question

## Textbooks

High-yield textbook

Extended textbook

## Links

DermNet NZ — 5 / 6

Hereditary haemorrhagic telangiectasia

Postgraduate Medical Journal — 5 / 1

Review of HHT

Suggest link | Report broken link

Score: **17%**

1 ✗
2 ✗
3 ✓
4 ✗
5 ✗
6 ✗
7 ✗

| | |
|---|---|
| 8 | ✗ |
| 9 | ✗ |
| 10 | ✗ |
| 11 | ✓ |
| 12 | ✗ |
| 13 | ✓ |
| 14 | ✗ |
| 15 | ✗ |
| 16 | ✗ |
| 17 | ✗ |
| 18 | ✗ |
| 19 | ✗ |
| 20 | ✗ |
| 21 | ✗ |
| 22 | ✗ |
| 23 | ✗ |
| 24 | ✗ |
| 25 | ✗ |
| 26 | ✓ |
| 27 | ✗ |
| 28 | ✗ |
| 29 | ✗ |
| 30 | ✗ |
| 31 | ✗ |
| 32 | ✓ |
| 33 | ✗ |
| 34 | ✗ |
| 35 | ✗ |
| 36 | ✗ |
| 37 | ✗ |
| 38 | ✗ |
| 39 | ✗ |
| 40 | ✗ |
| 41 | ✗ |
| 42 | ✗ |
| 43 | ✗ |

| | |
|---|---|
| 44 | ✓ |
| 45 | ✗ |
| 46 | ✗ |
| 47 | ✓ |
| 48 | ✗ |
| 49 | ✗ |
| 50 | ✗ |
| 51 | ✗ |
| 52 | ✗ |
| 53 | ✗ |
| 54 | ✗ |
| 55 | ✗ |
| 56 | ✗ |
| 57 | ✗ |
| 58 | ✗ |
| 59 | ✗ |
| 60 | ✗ |
| 61 | ✗ |
| 62 | ✓ |
| 63 | ✗ |
| 64 | ✗ |
| 65 | ✓ |
| 66 | ✗ |
| 67 | ✗ |
| 68 | ✗ |
| 69 | ✓ |
| 70 | ✓ |
| 71 | ✗ |
| 72 | ✗ |
| 73 | ✗ |
| 74 | ✓ |
| 75 | ✗ |
| 76 | ✗ |
| 77 | ✗ |
| 78 | ✗ |
| 79 | - |

80 ✓
**81** ✗
82 ✗
83 ✗
84 ✗
85 ✗
86 ✗
87 ✗
88 ✓
89 ✓
90 ✗
91 ✗
92 ✗
93 ✗
94 ✓
95 ✗
96 ✗
97 ✗
98 ✗
99 ✓
100 ✗
101 ✗

All contents of this site are © 2024 Passmedicine Limited

Back to top

A 75-year-old man presents with a 'sore' on his lip. This has been present for around four months and has been getting slowly worse. His past medical history includes ischaemic heart disease and chronic obstructive pulmonary disease. He still smokes around 20 cigarettes per day.

© Image used on license from DermNet NZ

What is the most likely diagnosis?

- Actinic keratosis
- Leukoplakia
- Squamous cell carcinoma
- Mucocoele
- Bowen's disease

Submit answer

Reference ranges

Score: **14%**

| | |
|---|---|
| 1 | ✗ |
| 2 | ✗ |
| 3 | ✓ |
| 4 | ✗ |
| 5 | ✗ |
| 6 | ✗ |
| 7 | ✗ |
| 8 | ✗ |
| 9 | ✗ |
| 10 | ✗ |
| 11 | ✓ |
| 12 | ✗ |
| 13 | ✓ |
| 14 | ✗ |
| 15 | ✗ |
| 16 | ✗ |
| 17 | ✗ |
| 18 | ✗ |
| 19 | ✗ |
| 20 | ✗ |
| 21 | ✗ |
| 22 | ✗ |
| 23 | ✗ |
| 24 | ✗ |
| 25 | ✗ |
| 26 | ✓ |
| 27 | ✗ |
| 28 | ✗ |
| 29 | ✗ |
| 30 | ✗ |
| 31 | ✗ |
| 32 | ✓ |
| 33 | ✗ |
| 34 | ✗ |

| | |
|---|---|
| 35 | ✗ |
| 36 | ✗ |
| 37 | ✗ |
| 38 | ✗ |
| 39 | ✗ |
| 40 | ✗ |
| 41 | ✗ |
| 42 | ✗ |
| 43 | ✗ |
| 44 | ✓ |
| 45 | ✗ |
| 46 | ✗ |
| 47 | ✓ |
| 48 | ✗ |
| 49 | ✗ |
| 50 | ✗ |
| 51 | - |
| 52 | - |
| 53 | - |
| 54 | - |
| 55 | - |
| 56 | - |
| 57 | - |
| 58 | - |
| 59 | - |
| 60 | - |
| 61 | - |
| 62 | - |
| 63 | - |
| 64 | - |
| 65 | - |
| 66 | - |
| 67 | - |
| 68 | - |
| 69 | - |
| 70 | - |
| 71 | - |
| 72 | - |

| | |
|---|---|
| 73 | - |
| 74 | - |
| 75 | - |
| 76 | - |
| 77 | - |
| 78 | - |
| 79 | - |
| 80 | - |
| 81 | - |
| **82** | - |

All contents of this site are © 2024 Passmedicine Limited

A 75-year-old man presents with a 'sore' on his lip. This has been present for around four months and has been getting slowly worse. His past medical history includes ischaemic heart disease and chronic obstructive pulmonary disease. He still smokes around 20 cigarettes per day.

© Image used on license from DermNet NZ

What is the most likely diagnosis?

- Actinic keratosis 3%
- Leukoplakia 1%
- Squamous cell carcinoma 84%
- Mucocoele 1%
- Bowen's disease 11%

The most likely diagnosis in this case is **Squamous cell carcinoma**. The patient's age, history of smoking, and the appearance of the lesion with its chronicity and progressive worsening are all suggestive of squamous cell carcinoma (SCC). SCC is a malignant tumour arising from keratinocytes in the epidermis. It commonly affects sun-exposed areas like the face and lips. Smoking is a significant risk factor for SCC development.

**Actinic keratosis** is an incorrect option because it typically presents as a rough, scaly patch on sun-exposed skin. It is a precursor to SCC but does not have the same appearance as the lesion described in this case.

**Leukoplakia** is also incorrect as it usually presents as white patches or plaques on the oral mucosa, which cannot be scraped off. While leukoplakia can be associated with malignancy, it does not have the same clinical appearance as the lip sore described here.

**Mucocoele** is another incorrect choice because it presents as a painless, fluid-filled swelling that often occurs on the lower lip due to trauma or obstruction of salivary glands. The chronicity and worsening nature of the lesion in this case do not fit with a mucocoele.

Finally, **Bowen's disease** is an incorrect option because it typically appears as an erythematous, scaly patch with well-defined borders on sun-exposed skin. Although Bowen's disease represents squamous cell carcinoma in situ and shares some risk factors with invasive SCC, its clinical presentation differs from that described in this scenario.

Discuss (1) | Improve

Next question ›

## Squamous cell carcinoma of the skin

Squamous cell carcinoma is a common variant of skin cancer. Metastases are rare but may occur in 2-5% of patients.

Risk factors include:
- excessive exposure to sunlight / psoralen UVA therapy
- actinic keratoses and Bowen's disease
- immunosuppression e.g. following renal transplant, HIV
- smoking
- long-standing leg ulcers (Marjolin's ulcer)
- genetic conditions e.g. xeroderma pigmentosum, oculocutaneous albinism

Features
- typically on sun-exposed sites such as the head and neck or dorsum of the hands and arms
- rapidly expanding painless, ulcerate nodules
- may have a cauliflower-like appearance
- there may be areas of bleeding

## Image gallery

## Treatment

Surgical excision with 4mm margins if lesion <20mm in diameter. If tumour >20mm then margins should be 6mm. Mohs micrographic surgery may be used in high-risk patients and in cosmetically important sites.

## Prognosis

| **Good Prognosis** | **Poor prognosis** |
|---|---|
| Well differentiated tumours | Poorly differentiated tumours |
| <20mm diameter | >20mm in diameter |
| <2mm deep | >4mm deep |
| No associated diseases | Immunosupression for whatever reason |

123

Next question

## Textbooks

High-yield textbook

Extended textbook

## Links

DermNet NZ 28 4

Squamous cell carcinoma

Suggest link Report broken link

## Media

Skin cancers

Osmosis - YouTube 4 1

Report broken media

Score: **17%**

1 ✗
2 ✗
3 ✓
4 ✗
5 ✗
6 ✗
7 ✗

| | |
|---|---|
| 8 | ✗ |
| 9 | ✗ |
| 10 | ✗ |
| 11 | ✓ |
| 12 | ✗ |
| 13 | ✓ |
| 14 | ✗ |
| 15 | ✗ |
| 16 | ✗ |
| 17 | ✗ |
| 18 | ✗ |
| 19 | ✗ |
| 20 | ✗ |
| 21 | ✗ |
| 22 | ✗ |
| 23 | ✗ |
| 24 | ✗ |
| 25 | ✗ |
| 26 | ✓ |
| 27 | ✗ |
| 28 | ✗ |
| 29 | ✗ |
| 30 | ✗ |
| 31 | ✗ |
| 32 | ✓ |
| 33 | ✗ |
| 34 | ✗ |
| 35 | ✗ |
| 36 | ✗ |
| 37 | ✗ |
| 38 | ✗ |
| 39 | ✗ |
| 40 | ✗ |
| 41 | ✗ |
| 42 | ✗ |
| 43 | ✗ |

| | |
|---|---|
| 44 | ✓ |
| 45 | ✗ |
| 46 | ✗ |
| 47 | ✓ |
| 48 | ✗ |
| 49 | ✗ |
| 50 | ✗ |
| 51 | ✗ |
| 52 | ✗ |
| 53 | ✗ |
| 54 | ✗ |
| 55 | ✗ |
| 56 | ✗ |
| 57 | ✗ |
| 58 | ✗ |
| 59 | ✗ |
| 60 | ✗ |
| 61 | ✗ |
| 62 | ✓ |
| 63 | ✗ |
| 64 | ✗ |
| 65 | ✓ |
| 66 | ✗ |
| 67 | ✗ |
| 68 | ✗ |
| 69 | ✓ |
| 70 | ✓ |
| 71 | ✗ |
| 72 | ✗ |
| 73 | ✗ |
| 74 | ✓ |
| 75 | ✗ |
| 76 | ✗ |
| 77 | ✗ |
| 78 | ✗ |
| 79 | - |

| | |
|---|---|
| 80 | ✓ |
| 81 | ✗ |
| **82** | ✗ |
| 83 | ✗ |
| 84 | ✗ |
| 85 | ✗ |
| 86 | ✗ |
| 87 | ✗ |
| 88 | ✓ |
| 89 | ✓ |
| 90 | ✗ |
| 91 | ✗ |
| 92 | ✗ |
| 93 | ✗ |
| 94 | ✓ |
| 95 | ✗ |
| 96 | ✗ |
| 97 | ✗ |
| 98 | ✗ |
| 99 | ✓ |
| 100 | ✗ |
| 101 | ✗ |

All contents of this site are © 2024 Passmedicine Limited

Back to top

A 34-year-old man presents with a scaly rash on his elbows and knees that has been getting progressively worse for the past 3 months. He has tried using some of his wife's Diprobase cream which has helped the itching somewhat.

© Image used on license from DermNet NZ

Following NICE guidance, what is the most appropriate next step in management?

- Topical potent corticosteroid + vitamin D analogue
- Topical potent corticosteroid
- Refer for ultraviolet light therapy
- Topical vitamin D analogue
- Topical coal tar

Submit answer

Reference ranges

Score: **14%**

| | |
|---|---|
| 1 | ✗ |
| 2 | ✗ |
| 3 | ✓ |
| 4 | ✗ |
| 5 | ✗ |
| 6 | ✗ |
| 7 | ✗ |
| 8 | ✗ |
| 9 | ✗ |
| 10 | ✗ |
| 11 | ✓ |
| 12 | ✗ |
| 13 | ✓ |
| 14 | ✗ |
| 15 | ✗ |
| 16 | ✗ |
| 17 | ✗ |
| 18 | ✗ |
| 19 | ✗ |
| 20 | ✗ |
| 21 | ✗ |
| 22 | ✗ |
| 23 | ✗ |
| 24 | ✗ |
| 25 | ✗ |
| 26 | ✓ |
| 27 | ✗ |
| 28 | ✗ |
| 29 | ✗ |
| 30 | ✗ |
| 31 | ✗ |
| 32 | ✓ |
| 33 | ✗ |
| 34 | ✗ |

| | |
|---|---|
| 35 | ✗ |
| 36 | ✗ |
| 37 | ✗ |
| 38 | ✗ |
| 39 | ✗ |
| 40 | ✗ |
| 41 | ✗ |
| 42 | ✗ |
| 43 | ✗ |
| 44 | ✓ |
| 45 | ✗ |
| 46 | ✗ |
| 47 | ✓ |
| 48 | ✗ |
| 49 | ✗ |
| 50 | ✗ |
| 51 | - |
| 52 | - |
| 53 | - |
| 54 | - |
| 55 | - |
| 56 | - |
| 57 | - |
| 58 | - |
| 59 | - |
| 60 | - |
| 61 | - |
| 62 | - |
| 63 | - |
| 64 | - |
| 65 | - |
| 66 | - |
| 67 | - |
| 68 | - |
| 69 | - |
| 70 | - |
| 71 | - |
| 72 | - |

73 -
74 -
75 -
76 -
77 -
78 -
79 -
80 -
81 -
82 -
**83** -

All contents of this site are © 2024 Passmedicine Limited
Back to top

A 34-year-old man presents with a scaly rash on his elbows and knees that has been getting progressively worse for the past 3 months. He has tried using some of his wife's Diprobase cream which has helped the itching somewhat.

© Image used on license from DermNet NZ

Following NICE guidance, what is the most appropriate next step in management?

- Topical potent corticosteroid + vitamin D analogue 70%
- Topical potent corticosteroid 14%
- Refer for ultraviolet light therapy 1%
- Topical vitamin D analogue 13%
- Topical coal tar 2%

Topical potent corticosteroid + vitamin D analogue is first-line for chronic plaque psoriasis

Important for me Less important

The correct answer is **Topical potent corticosteroid + vitamin D analogue**. According to NICE guidelines, the first-line treatment for psoriasis in adults should be a combination of a topical corticosteroid and a vitamin D analogue. This combination has been shown to be more effective

than using either treatment alone. The patient's presentation of a scaly rash on his elbows and knees is consistent with plaque psoriasis, and the use of a potent corticosteroid combined with a vitamin D analogue would provide both anti-inflammatory and keratolytic effects, helping to reduce symptoms and improve the appearance of the skin.

The option **Topical potent corticosteroid** alone may provide some relief from inflammation but would not address the abnormal keratinocyte proliferation seen in psoriasis. Additionally, using a corticosteroid alone increases the risk of skin atrophy and other side effects associated with long-term use.

**Refer for ultraviolet light therapy** is not the most appropriate next step as per NICE guidelines. Ultraviolet light therapy can be considered if topical treatments have failed or are contraindicated; however, this patient has not yet tried any targeted topical treatments for his psoriasis.

Using only a **Topical vitamin D analogue**, while it may help regulate keratinocyte proliferation, would not provide sufficient anti-inflammatory effects needed to manage this patient's symptoms effectively. As mentioned earlier, combining it with a potent corticosteroid provides better results.

Finally, **Topical coal tar** is an older treatment option for psoriasis that works by reducing inflammation and slowing down skin cell growth. However, it is less commonly used today due to its unpleasant smell, staining properties, and potential carcinogenic risks. It is also less effective than newer treatments such as topical corticosteroids and vitamin D analogues.

Discuss (4) | Improve

Next question >

# Psoriasis: management

NICE released guidelines in 2012 on the management of psoriasis and psoriatic arthropathy. Please see the link for more details.

## Chronic plaque psoriasis management

NICE recommend a step-wise approach for chronic plaque psoriasis

- regular emollients may help to reduce scale loss and reduce pruritus
- first-line: NICE recommend:
  - a potent corticosteroid applied once daily plus vitamin D analogue applied once daily
  - should be applied separately, one in the morning and the other in the evening)
  - for up to 4 weeks as initial treatment
- second-line: if no improvement after 8 weeks then offer:

    - a vitamin D analogue twice daily
- third-line: if no improvement after 8-12 weeks then offer either:
    - a potent corticosteroid applied twice daily for up to 4 weeks, or
    - a coal tar preparation applied once or twice daily
- short-acting dithranol can also be used

**Secondary care management**

Phototherapy

- narrowband ultraviolet B light is now the treatment of choice. If possible this should be given 3 times a week
- photochemotherapy is also used - psoralen + ultraviolet A light (PUVA)
- adverse effects: skin ageing, squamous cell cancer (not melanoma)

Systemic therapy

- oral methotrexate is used first-line. It is particularly useful if there is associated joint disease
- ciclosporin
- systemic retinoids
- biological agents: infliximab, etanercept and adalimumab
- ustekinumab (IL-12 and IL-23 blocker) is showing promise in early trials

## Scalp psoriasis management

Outline

- NICE recommend the use of potent topical corticosteroids used once daily for 4 weeks
- if no improvement after 4 weeks then either use a different formulation of the potent corticosteroid (for example, a shampoo or mousse) and/or a topical agents to remove adherent scale (for example, agents containing salicylic acid, emollients and oils) before application of the potent corticosteroid

## Face, flexural and genital psoriasis management

Outline

- NICE recommend offering a mild or moderate potency corticosteroid applied once or twice daily for a maximum of 2 weeks

## Notes on medication

Using topical steroids in psoriasis

- as we know topical corticosteroid therapy may lead to skin atrophy, striae and rebound symptoms
    - the scalp, face and flexures are particularly prone to steroid atrophy so topical steroids should not be used for more than 1-2 weeks/month
- systemic side-effects may be seen when potent corticosteroids are used on large areas e.g. > 10% of the body surface area
- NICE recommend that we aim for a 4-week break before starting another course of topical corticosteroids
- they also recommend using potent corticosteroids for no longer than 8 weeks at a time and very potent corticosteroids for no longer than 4 weeks at a time

Vitamin D analogues

- examples of vitamin D analogues include calcipotriol (Dovonex), calcitriol and tacalcitol
- they work by ↓ cell division and differentiation → ↓ epidermal proliferation
- adverse effects are uncommon
- unlike corticosteroids they may be used long-term
- unlike coal tar and dithranol they do not smell or stain
- they tend to reduce the scale and thickness of plaques but not the erythema
- they should be avoided in pregnancy
- the maximum weekly amount for adults is 100g

© Image used on license from DermNet NZ

A 'before and after' image showing the effect of 6 weeks of calcipotriol therapy on a large plaque. Note how the scale has improved but the erythema remains

Dithranol

- inhibits DNA synthesis
- wash off after 30 mins
- adverse effects include burning, staining

Coal tar

- mechanism of action not fully understood - probably inhibit DNA synthesis

+ Q 123

Next question >

## Textbooks

High-yield textbook

Extended textbook

## Links

SIGN 👍 14 👎 13

2010 Psoriasis guidelines

British Association of Dermatologists 👍 14 👎 11

2017 Guidelines for biologic therapy for psoriasis

NICE 👍 21 👎 16

2012 Psoriasis guidelines

Suggest link

Report broken link

## Media

Psoriasis

Osmosis - YouTube 👍 1 👎 1

Report broken media

Score: **17%**

1 ✗

2 ✗

| | |
|---|---|
| 3 | ✓ |
| 4 | ✗ |
| 5 | ✗ |
| 6 | ✗ |
| 7 | ✗ |
| 8 | ✗ |
| 9 | ✗ |
| 10 | ✗ |
| 11 | ✓ |
| 12 | ✗ |
| 13 | ✓ |
| 14 | ✗ |
| 15 | ✗ |
| 16 | ✗ |
| 17 | ✗ |
| 18 | ✗ |
| 19 | ✗ |
| 20 | ✗ |
| 21 | ✗ |
| 22 | ✗ |
| 23 | ✗ |
| 24 | ✗ |
| 25 | ✗ |
| 26 | ✓ |
| 27 | ✗ |
| 28 | ✗ |
| 29 | ✗ |
| 30 | ✗ |
| 31 | ✗ |
| 32 | ✓ |
| 33 | ✗ |
| 34 | ✗ |
| 35 | ✗ |
| 36 | ✗ |
| 37 | ✗ |
| 38 | ✗ |

| | |
|---|---|
| 39 | ✗ |
| 40 | ✗ |
| 41 | ✗ |
| 42 | ✗ |
| 43 | ✗ |
| 44 | ✓ |
| 45 | ✗ |
| 46 | ✗ |
| 47 | ✓ |
| 48 | ✗ |
| 49 | ✗ |
| 50 | ✗ |
| 51 | ✗ |
| 52 | ✗ |
| 53 | ✗ |
| 54 | ✗ |
| 55 | ✗ |
| 56 | ✗ |
| 57 | ✗ |
| 58 | ✗ |
| 59 | ✗ |
| 60 | ✗ |
| 61 | ✗ |
| 62 | ✓ |
| 63 | ✗ |
| 64 | ✗ |
| 65 | ✓ |
| 66 | ✗ |
| 67 | ✗ |
| 68 | ✗ |
| 69 | ✓ |
| 70 | ✓ |
| 71 | ✗ |
| 72 | ✗ |
| 73 | ✗ |
| 74 | ✓ |

| | |
|---|---|
| 75 | ✗ |
| 76 | ✗ |
| 77 | ✗ |
| 78 | ✗ |
| 79 | - |
| 80 | ✓ |
| 81 | ✗ |
| 82 | ✗ |
| **83** | ✗ |
| 84 | ✗ |
| 85 | ✗ |
| 86 | ✗ |
| 87 | ✗ |
| 88 | ✓ |
| 89 | ✓ |
| 90 | ✗ |
| 91 | ✗ |
| 92 | ✗ |
| 93 | ✗ |
| 94 | ✓ |
| 95 | ✗ |
| 96 | ✗ |
| 97 | ✗ |
| 98 | ✗ |
| 99 | ✓ |
| 100 | ✗ |
| 101 | ✗ |

All contents of this site are © 2024 Passmedicine Limited

A 64-year-old man attends with a severe facial skin rash. He describes recurrent redness on his face. This has been on and off for several years but has recently worsened and the rash is not going away. It is associated with burning and stinging sensations and occasional swelling around the eyes.

On examination, he has an erythematous rash over his cheeks, nasal bridge, and forehead. Within the erythema are numerous large pustules and some pitted scarring with interspersed papules and single plaque. He also has an erythematous rash over his neck and shoulders that is warm to the touch and has the appearance of sunburn.

Given the likely diagnosis, what would be the most appropriate treatment option for this patient?

- Laser therapy
- Topical brimonidine gel
- Topical ivermectin
- Topical ivermectin and oral doxycycline combination therapy
- Topical ivermectin and oral doxycycline combination therapy and dermatology referral

Submit answer

Reference ranges

Score: **14%**

1 ✗
2 ✗
3 ✓
4 ✗

5 ✗
6 ✗
7 ✗
8 ✗
9 ✗
10 ✗
11 ✓
12 ✗
13 ✓
14 ✗
15 ✗
16 ✗
17 ✗
18 ✗
19 ✗
20 ✗
21 ✗
22 ✗
23 ✗
24 ✗
25 ✗
26 ✓
27 ✗
28 ✗
29 ✗
30 ✗
31 ✗
32 ✓
33 ✗
34 ✗
35 ✗
36 ✗
37 ✗
38 ✗
39 ✗
40 ✗

| | |
|---|---|
| 41 | ✗ |
| 42 | ✗ |
| 43 | ✗ |
| 44 | ✓ |
| 45 | ✗ |
| 46 | ✗ |
| 47 | ✓ |
| 48 | ✗ |
| 49 | ✗ |
| 50 | ✗ |
| 51 | - |
| 52 | - |
| 53 | - |
| 54 | - |
| 55 | - |
| 56 | - |
| 57 | - |
| 58 | - |
| 59 | - |
| 60 | - |
| 61 | - |
| 62 | - |
| 63 | - |
| 64 | - |
| 65 | - |
| 66 | - |
| 67 | - |
| 68 | - |
| 69 | - |
| 70 | - |
| 71 | - |
| 72 | - |
| 73 | - |
| 74 | - |
| 75 | - |
| 76 | - |
| 77 | - |
| 78 | - |
| 79 | - |

| | |
|---|---|
| 80 | - |
| 81 | - |
| 82 | - |
| 83 | - |
| **84** | - |

All contents of this site are © 2024 Passmedicine Limited

A 64-year-old man attends with a severe facial skin rash. He describes recurrent redness on his face. This has been on and off for several years but has recently worsened and the rash is not going away. It is associated with burning and stinging sensations and occasional swelling around the eyes.

On examination, he has an erythematous rash over his cheeks, nasal bridge, and forehead. Within the erythema are numerous large pustules and some pitted scarring with interspersed papules and single plaque. He also has an erythematous rash over his neck and shoulders that is warm to the touch and has the appearance of sunburn.

Given the likely diagnosis, what would be the most appropriate treatment option for this patient?

| | |
|---|---|
| Laser therapy | 1% |
| Topical brimonidine gel | 5% |
| Topical ivermectin | 11% |
| Topical ivermectin and oral doxycycline combination therapy | 41% |
| Topical ivermectin and oral doxycycline combination therapy and dermatology referral | 42% |

Rosacea: a combination of topical ivermectin + oral doxycycline is first-line for patients with severe papules and/or pustules

Important for me    Less important

The most likely diagnosis here is rosacea. Recurrent erythematous facial rash that comes and goes with the distribution described in the stem is typical of rosacea. It is commonly associated with flushing, papules, and pustules, in some cases, rhinophyma can develop. Another clue is that this patient has sunburn - the skin rash in rosacea is commonly exacerbated by sunlight and sunburn indicates significant sun exposure.

**Topical ivermectin and oral doxycycline combination therapy** is the correct answer. We have a persistent rash with a significant burden of papules and pustules, this would be deemed 'moderate to severe' so a combination of topical ivermectin and oral doxycycline would be advisable.

**Topical ivermectin** is incorrect. This would be a reasonable first-line option for patients with mild

to moderate rash. 'Few' papules/pustules would be classed as 'mild', 'several' would be classed as 'moderate', and 'many' would be classed as 'severe' rosacea according to the National Rosacea Society. The presence of plaque also indicates 'severe' rosacea.

**Laser therapy** is incorrect. This would be guided by secondary care specialists and does not form part of the first-line management for rosacea, it is predominantly used for patients with extensive telangiectasia which is not a main issue for this patient.

**Topical ivermectin and oral doxycycline combination therapy and dermatology referral** is incorrect. It would be reasonable to trial optimal management in primary care before onward referral to dermatology specialists.

**Topical brimonidine gel** is incorrect. This topical alpha-adrenergic agonist is used to manage flushing associated with rosacea. It would not be of benefit in this case as it would not have efficacy in managing the pustules and papules. This patient has pustule and papule-predominant rosacea which is better managed with ivermectin, doxycycline, or alternative options such as metronidazole and topical azelaic acid.

Discuss (2) | Improve

Next question

# Rosacea

Rosacea (sometimes referred to as acne rosacea) is a chronic skin disease of unknown aetiology.

Features

- typically affects nose, cheeks and forehead
- flushing is often first symptom
- telangiectasia are common
- later develops into persistent erythema with papules and pustules
- rhinophyma
- ocular involvement: blepharitis
- sunlight may exacerbate symptoms

Management

- simple measures
  - recommend daily application of a high-factor sunscreen
  - camouflage creams may help conceal redness
- predominant erythema/flushing
  - topical brimonidine gel may be considered for patients with predominant flushing but limited telangiectasia
  - brimonidine is a topical alpha-adrenergic agonist
  - this can be used on an 'as required basis' to temporarily reduce redness
  - it typically reduces redness within 30 minutes, reaching peak action at 3-6 hours, after which the redness returns to the baseline
- mild-to-moderate papules and/or pustules
  - topical ivermectin is first-line
  - alternatives include: topical metronidazole or topical azelaic acid
- moderate-to-severe papules and/or pustules
  - combination of topical ivermectin + oral doxycycline

Referral should be considered if

- symptoms have not improved with optimal management in primary care
  - laser therapy may be appropriate for patients with prominent telangiectasia
- patients with a rhinophyma

+ Q 123

Next question

**Textbooks**

High-yield textbook

Extended textbook

## Links

DermNet NZ — 11 / 17

Rhinophyma

BNF — 10 / 11

Acne rosacea

Dermnet NZ — 23 / 13

Acne rosacea

Clinical Knowledge Summaries — 19 / 10

Acne rosacea guidelines

Primary Care Dermatology Society — 27 / 9

Rosacea review

Suggest link

Report broken link

Score: **17%**

1 ✗
2 ✗
3 ✓
4 ✗
5 ✗
6 ✗

| | |
|---|---|
| 7 | ✗ |
| 8 | ✗ |
| 9 | ✗ |
| 10 | ✗ |
| 11 | ✓ |
| 12 | ✗ |
| 13 | ✓ |
| 14 | ✗ |
| 15 | ✗ |
| 16 | ✗ |
| 17 | ✗ |
| 18 | ✗ |
| 19 | ✗ |
| 20 | ✗ |
| 21 | ✗ |
| 22 | ✗ |
| 23 | ✗ |
| 24 | ✗ |
| 25 | ✗ |
| 26 | ✓ |
| 27 | ✗ |
| 28 | ✗ |
| 29 | ✗ |
| 30 | ✗ |
| 31 | ✗ |
| 32 | ✓ |
| 33 | ✗ |
| 34 | ✗ |
| 35 | ✗ |
| 36 | ✗ |
| 37 | ✗ |
| 38 | ✗ |
| 39 | ✗ |
| 40 | ✗ |
| 41 | ✗ |
| 42 | ✗ |

| | |
|---|---|
| 43 | ✗ |
| 44 | ✓ |
| 45 | ✗ |
| 46 | ✗ |
| 47 | ✓ |
| 48 | ✗ |
| 49 | ✗ |
| 50 | ✗ |
| 51 | ✗ |
| 52 | ✗ |
| 53 | ✗ |
| 54 | ✗ |
| 55 | ✗ |
| 56 | ✗ |
| 57 | ✗ |
| 58 | ✗ |
| 59 | ✗ |
| 60 | ✗ |
| 61 | ✗ |
| 62 | ✓ |
| 63 | ✗ |
| 64 | ✗ |
| 65 | ✓ |
| 66 | ✗ |
| 67 | ✗ |
| 68 | ✗ |
| 69 | ✓ |
| 70 | ✓ |
| 71 | ✗ |
| 72 | ✗ |
| 73 | ✗ |
| 74 | ✓ |
| 75 | ✗ |
| 76 | ✗ |
| 77 | ✗ |
| 78 | ✗ |

| | |
|---|---|
| 79 | - |
| 80 | ✓ |
| 81 | ✗ |
| 82 | ✗ |
| 83 | ✗ |
| **84** | ✗ |
| 85 | ✗ |
| 86 | ✗ |
| 87 | ✗ |
| 88 | ✓ |
| 89 | ✓ |
| 90 | ✗ |
| 91 | ✗ |
| 92 | ✗ |
| 93 | ✗ |
| 94 | ✓ |
| 95 | ✗ |
| 96 | ✗ |
| 97 | ✗ |
| 98 | ✗ |
| 99 | ✓ |
| 100 | ✗ |
| 101 | ✗ |

All contents of this site are © 2024 Passmedicine Limited

A 50-year-old woman attends your clinic with an itchy rash on her forearms. It constitutes several small violaceous polygonal papules, mainly clustered around the wrist flexors. Her background is notable for left ventricular failure, for which she was recently commenced on 5mg bisoprolol OD.

Bloods are unremarkable.

Which of the following is true in this condition?

- Scalp lesions are common
- Oral lesions have a better prognosis
- Nail involvement is not seen
- It is a type IV hypersensitivity reaction
- Exhibits the Koebner phenomenon

Submit answer

Reference ranges

Score: **14%**

| | |
|---|---|
| 1 | ✗ |
| 2 | ✗ |
| 3 | ✓ |
| 4 | ✗ |
| 5 | ✗ |
| 6 | ✗ |
| 7 | ✗ |

| | |
|---|---|
| 8 | ✗ |
| 9 | ✗ |
| 10 | ✗ |
| 11 | ✓ |
| 12 | ✗ |
| 13 | ✓ |
| 14 | ✗ |
| 15 | ✗ |
| 16 | ✗ |
| 17 | ✗ |
| 18 | ✗ |
| 19 | ✗ |
| 20 | ✗ |
| 21 | ✗ |
| 22 | ✗ |
| 23 | ✗ |
| 24 | ✗ |
| 25 | ✗ |
| 26 | ✓ |
| 27 | ✗ |
| 28 | ✗ |
| 29 | ✗ |
| 30 | ✗ |
| 31 | ✗ |
| 32 | ✓ |
| 33 | ✗ |
| 34 | ✗ |
| 35 | ✗ |
| 36 | ✗ |
| 37 | ✗ |
| 38 | ✗ |
| 39 | ✗ |
| 40 | ✗ |
| 41 | ✗ |
| 42 | ✗ |
| 43 | ✗ |

| | |
|---|---|
| 44 | ✓ |
| 45 | ✗ |
| 46 | ✗ |
| 47 | ✓ |
| 48 | ✗ |
| 49 | ✗ |
| 50 | ✗ |
| 51 | - |
| 52 | - |
| 53 | - |
| 54 | - |
| 55 | - |
| 56 | - |
| 57 | - |
| 58 | - |
| 59 | - |
| 60 | - |
| 61 | - |
| 62 | - |
| 63 | - |
| 64 | - |
| 65 | - |
| 66 | - |
| 67 | - |
| 68 | - |
| 69 | - |
| 70 | - |
| 71 | - |
| 72 | - |
| 73 | - |
| 74 | - |
| 75 | - |
| 76 | - |
| 77 | - |
| 78 | - |
| 79 | - |
| 80 | - |
| 81 | - |
| 82 | - |

| | |
|---|---|
| 83 | - |
| 84 | - |
| **85** | - |

All contents of this site are © 2024 Passmedicine Limited

A 50-year-old woman attends your clinic with an itchy rash on her forearms. It constitutes several small violaceous polygonal papules, mainly clustered around the wrist flexors. Her background is notable for left ventricular failure, for which she was recently commenced on 5mg bisoprolol OD.

Bloods are unremarkable.

Which of the following is true in this condition?

| | |
|---|---|
| Scalp lesions are common | 5% |
| Oral lesions have a better prognosis | 5% |
| Nail involvement is not seen | 9% |
| It is a type IV hypersensitivity reaction | 9% |
| Exhibits the Koebner phenomenon | 71% |

Koebner phenomenon - Warts And ALL (warts, autoimmune, AIDS, lichen planus & lichen sclerosis)

Important for me Less important

This is the typical description of lichen planus. It is possible that bisoprolol has precipitated it - as can thiazide diuretics and anti-malarial drugs. Cutaneous lesions can take up to a year to fully heal and oral lesions can take much longer, with many requiring oral steroids and topical calcineurin inhibitors.

Lichen planus exhibits the Koebner phenomenon, in which minor trauma can cause new lesions. Other conditions that exhibit this phenomenon include viral warts, vitiligo, molluscum contagiosum and lichen sclerosis.

Nail involvement can be seen in lichen planus and is characterised by longitudinal grooving, which can be helpful at differentiating the condition from psoriasis.

Allergic contact dermatitis is a type IV hypersensitivity reaction and would have a more eczematous appearance.

Discuss (2) Improve

Next question

## Koebner phenomenon

The Koebner phenomenon describes skin lesions that appear at the site of injury. It is seen in:

- psoriasis
- vitiligo
- warts
- lichen planus
- lichen sclerosus
- molluscum contagiosum

+ Q 123

Next question

### Textbooks

High-yield textbook

Extended textbook

### Links

DermNet NZ 8 8

Koebner phenonmen

Suggest link Report broken link

Score: **17%**

| | |
|---|---|
| 1 | ✗ |
| 2 | ✗ |
| 3 | ✓ |
| 4 | ✗ |
| 5 | ✗ |
| 6 | ✗ |
| 7 | ✗ |
| 8 | ✗ |
| 9 | ✗ |
| 10 | ✗ |
| 11 | ✓ |
| 12 | ✗ |
| 13 | ✓ |
| 14 | ✗ |
| 15 | ✗ |
| 16 | ✗ |
| 17 | ✗ |
| 18 | ✗ |
| 19 | ✗ |
| 20 | ✗ |
| 21 | ✗ |
| 22 | ✗ |
| 23 | ✗ |
| 24 | ✗ |
| 25 | ✗ |
| 26 | ✓ |
| 27 | ✗ |
| 28 | ✗ |
| 29 | ✗ |
| 30 | ✗ |
| 31 | ✗ |

| | |
|---|---|
| 32 | ✓ |
| 33 | ✗ |
| 34 | ✗ |
| 35 | ✗ |
| 36 | ✗ |
| 37 | ✗ |
| 38 | ✗ |
| 39 | ✗ |
| 40 | ✗ |
| 41 | ✗ |
| 42 | ✗ |
| 43 | ✗ |
| 44 | ✓ |
| 45 | ✗ |
| 46 | ✗ |
| 47 | ✓ |
| 48 | ✗ |
| 49 | ✗ |
| 50 | ✗ |
| 51 | ✗ |
| 52 | ✗ |
| 53 | ✗ |
| 54 | ✗ |
| 55 | ✗ |
| 56 | ✗ |
| 57 | ✗ |
| 58 | ✗ |
| 59 | ✗ |
| 60 | ✗ |
| 61 | ✗ |
| 62 | ✓ |
| 63 | ✗ |
| 64 | ✗ |
| 65 | ✓ |
| 66 | ✗ |
| 67 | ✗ |

| | |
|---|---|
| 68 | ✗ |
| 69 | ✓ |
| 70 | ✓ |
| 71 | ✗ |
| 72 | ✗ |
| 73 | ✗ |
| 74 | ✓ |
| 75 | ✗ |
| 76 | ✗ |
| 77 | ✗ |
| 78 | ✗ |
| 79 | - |
| 80 | ✓ |
| 81 | ✗ |
| 82 | ✗ |
| 83 | ✗ |
| 84 | ✗ |
| **85** | ✗ |
| 86 | ✗ |
| 87 | ✗ |
| 88 | ✓ |
| 89 | ✓ |
| 90 | ✗ |
| 91 | ✗ |
| 92 | ✗ |
| 93 | ✗ |
| 94 | ✓ |
| 95 | ✗ |
| 96 | ✗ |
| 97 | ✗ |
| 98 | ✗ |
| 99 | ✓ |
| 100 | ✗ |
| 101 | ✗ |

All contents of this site are © 2024 Passmedicine Limited 

A middle aged man develops a non-pruritic rash after starting allopurinol therapy for gout. The rash develop within 24 hours and started on the back of his hands.

© Image used on license from DermNet NZ

What is the most likely diagnosis?

- Allopurinol-associated dermatitis
- Plaque-type tophi
- Erythema multiforme
- Erythema marginatum
- Eosinophilic folliculitis

Submit answer

Reference ranges

Score: **14%**

| | |
|---|---|
| 1 | ✗ |
| 2 | ✗ |
| 3 | ✓ |
| 4 | ✗ |
| 5 | ✗ |
| 6 | ✗ |
| 7 | ✗ |
| 8 | ✗ |
| 9 | ✗ |
| 10 | ✗ |
| 11 | ✓ |
| 12 | ✗ |
| 13 | ✓ |
| 14 | ✗ |
| 15 | ✗ |
| 16 | ✗ |
| 17 | ✗ |
| 18 | ✗ |
| 19 | ✗ |
| 20 | ✗ |
| 21 | ✗ |
| 22 | ✗ |
| 23 | ✗ |
| 24 | ✗ |
| 25 | ✗ |
| 26 | ✓ |
| 27 | ✗ |
| 28 | ✗ |
| 29 | ✗ |
| 30 | ✗ |
| 31 | ✗ |
| 32 | ✓ |
| 33 | ✗ |

| | |
|---|---|
| 34 | ✗ |
| 35 | ✗ |
| 36 | ✗ |
| 37 | ✗ |
| 38 | ✗ |
| 39 | ✗ |
| 40 | ✗ |
| 41 | ✗ |
| 42 | ✗ |
| 43 | ✗ |
| 44 | ✓ |
| 45 | ✗ |
| 46 | ✗ |
| 47 | ✓ |
| 48 | ✗ |
| 49 | ✗ |
| 50 | ✗ |
| 51 | - |
| 52 | - |
| 53 | - |
| 54 | - |
| 55 | - |
| 56 | - |
| 57 | - |
| 58 | - |
| 59 | - |
| 60 | - |
| 61 | - |
| 62 | - |
| 63 | - |
| 64 | - |
| 65 | - |
| 66 | - |
| 67 | - |
| 68 | - |
| 69 | - |
| 70 | - |
| 71 | - |

72 -
73 -
74 -
75 -
76 -
77 -
78 -
79 -
80 -
81 -
82 -
83 -
84 -
85 -
**86** -

All contents of this site are © 2024 Passmedicine Limited

A middle aged man develops a non-pruritic rash after starting allopurinol therapy for gout. The rash develop within 24 hours and started on the back of his hands.

© Image used on license from DermNet NZ

What is the most likely diagnosis?

- Allopurinol-associated dermatitis 10%
- Plaque-type tophi 3%
- Erythema multiforme 75%
- Erythema marginatum 4%
- Eosinophilic folliculitis 7%

Discuss (1) Improve

Next question

# Erythema multiforme

Erythema multiforme is a hypersensitivity reaction that is most commonly triggered by infections. It may be divided into minor and major forms.

Previously it was thought that Stevens-Johnson syndrome (SJS) was a severe form of erythema multiforme. They are now however considered as separate entities.

Features

- target lesions
- initially seen on the back of the hands / feet before spreading to the torso
- upper limbs are more commonly affected than the lower limbs
- pruritus is occasionally seen and is usually mild

Causes

- viruses: herpes simplex virus (the most common cause), Orf*
- idiopathic
- bacteria: *Mycoplasma*, *Streptococcus*
- drugs: penicillin, sulphonamides, carbamazepine, allopurinol, NSAIDs, oral contraceptive pill, nevirapine
- connective tissue disease e.g. Systemic lupus erythematosus
- sarcoidosis
- malignancy

## Erythema multiforme major

The more severe form, erythema multiforme major is associated with mucosal involvement.

*Orf is a skin disease of sheep and goats caused by a parapox virus

+ Q 123

Next question >

## Textbooks

High-yield textbook

Extended textbook

## Links

DermNet NZ 18 10

Erythema multiforme

Suggest link Report broken link

## Media

Erythema multiforme

Osmosis - YouTube 1 0

Report broken media

Score: **17%**

| | |
|---|---|
| 1 | ✗ |
| 2 | ✗ |
| 3 | ✓ |
| 4 | ✗ |
| 5 | ✗ |
| 6 | ✗ |
| 7 | ✗ |
| 8 | ✗ |
| 9 | ✗ |
| 10 | ✗ |
| 11 | ✓ |
| 12 | ✗ |
| 13 | ✓ |
| 14 | ✗ |
| 15 | ✗ |
| 16 | ✗ |
| 17 | ✗ |
| 18 | ✗ |
| 19 | ✗ |
| 20 | ✗ |
| 21 | ✗ |
| 22 | ✗ |
| 23 | ✗ |

| | |
|---|---|
| 24 | ✗ |
| 25 | ✗ |
| 26 | ✓ |
| 27 | ✗ |
| 28 | ✗ |
| 29 | ✗ |
| 30 | ✗ |
| 31 | ✗ |
| 32 | ✓ |
| 33 | ✗ |
| 34 | ✗ |
| 35 | ✗ |
| 36 | ✗ |
| 37 | ✗ |
| 38 | ✗ |
| 39 | ✗ |
| 40 | ✗ |
| 41 | ✗ |
| 42 | ✗ |
| 43 | ✗ |
| 44 | ✓ |
| 45 | ✗ |
| 46 | ✗ |
| 47 | ✓ |
| 48 | ✗ |
| 49 | ✗ |
| 50 | ✗ |
| 51 | ✗ |
| 52 | ✗ |
| 53 | ✗ |
| 54 | ✗ |
| 55 | ✗ |
| 56 | ✗ |
| 57 | ✗ |
| 58 | ✗ |
| 59 | ✗ |

| | |
|---|---|
| 60 | ✗ |
| 61 | ✗ |
| 62 | ✓ |
| 63 | ✗ |
| 64 | ✗ |
| 65 | ✓ |
| 66 | ✗ |
| 67 | ✗ |
| 68 | ✗ |
| 69 | ✓ |
| 70 | ✓ |
| 71 | ✗ |
| 72 | ✗ |
| 73 | ✗ |
| 74 | ✓ |
| 75 | ✗ |
| 76 | ✗ |
| 77 | ✗ |
| 78 | ✗ |
| 79 | - |
| 80 | ✓ |
| 81 | ✗ |
| 82 | ✗ |
| 83 | ✗ |
| 84 | ✗ |
| 85 | ✗ |
| **86** | ✗ |
| 87 | ✗ |
| 88 | ✓ |
| 89 | ✓ |
| 90 | ✗ |
| 91 | ✗ |
| 92 | ✗ |
| 93 | ✗ |
| 94 | ✓ |
| 95 | ✗ |

| | |
|---|---|
| 96 | ✗ |
| 97 | ✗ |
| 98 | ✗ |
| 99 | ✓ |
| 100 | ✗ |
| 101 | ✗ |

All contents of this site are © 2024 Passmedicine Limited

A 40-year-old woman visits her general practitioner with a 2-day history of a new rash that has developed over her hands and forearms. She denies pain or itch and has no history of previous dermatological conditions. Over the last week, she reports feeling generally lethargic with low-grade fevers and a dry cough. There is no past medical history of note and she takes no allergies.

Her rash is examined, as shown below. There is no nail or mucosal involvement.

© Image used on license from DermNet NZ

What is the most likely diagnosis?

- Erythema marginatum
- Erythema multiforme
- Irritant contact dermatitis

- ○ Lichen planus ×
- ○ Plaque psoriasis ×

Submit answer

Reference ranges ⌄

Score: **14%**

| | |
|---|---|
| 1 | ✗ |
| 2 | ✗ |
| 3 | ✓ |
| 4 | ✗ |
| 5 | ✗ |
| 6 | ✗ |
| 7 | ✗ |
| 8 | ✗ |
| 9 | ✗ |
| 10 | ✗ |
| 11 | ✓ |
| 12 | ✗ |
| 13 | ✓ |
| 14 | ✗ |
| 15 | ✗ |
| 16 | ✗ |
| 17 | ✗ |
| 18 | ✗ |
| 19 | ✗ |
| 20 | ✗ |
| 21 | ✗ |
| 22 | ✗ |
| 23 | ✗ |

| | |
|---|---|
| 24 | ✗ |
| 25 | ✗ |
| 26 | ✓ |
| 27 | ✗ |
| 28 | ✗ |
| 29 | ✗ |
| 30 | ✗ |
| 31 | ✗ |
| 32 | ✓ |
| 33 | ✗ |
| 34 | ✗ |
| 35 | ✗ |
| 36 | ✗ |
| 37 | ✗ |
| 38 | ✗ |
| 39 | ✗ |
| 40 | ✗ |
| 41 | ✗ |
| 42 | ✗ |
| 43 | ✗ |
| 44 | ✓ |
| 45 | ✗ |
| 46 | ✗ |
| 47 | ✓ |
| 48 | ✗ |
| 49 | ✗ |
| 50 | ✗ |
| 51 | - |
| 52 | - |
| 53 | - |
| 54 | - |
| 55 | - |
| 56 | - |
| 57 | - |
| 58 | - |
| 59 | - |
| 60 | - |

61 -
62 -
63 -
64 -
65 -
66 -
67 -
68 -
69 -
70 -
71 -
72 -
73 -
74 -
75 -
76 -
77 -
78 -
79 -
80 -
81 -
82 -
83 -
84 -
85 -
86 -
**87** -

All contents of this site are © 2024 Passmedicine Limited

Back to top

A 40-year-old woman visits her general practitioner with a 2-day history of a new rash that has developed over her hands and forearms. She denies pain or itch and has no history of previous dermatological conditions. Over the last week, she reports feeling generally lethargic with low-grade fevers and a dry cough. There is no past medical history of note and she takes no allergies.

Her rash is examined, as shown below. There is no nail or mucosal involvement.

© Image used on license from DermNet NZ

What is the most likely diagnosis?

| | |
|---|---|
| Erythema marginatum | 10% |
| Erythema multiforme | 76% |
| Irritant contact dermatitis | 6% |

Lichen planus 5%

Plaque psoriasis 4%

This patient has multiple erythematous, round lesions on her hands. On closer inspection, some of these lesions have a characteristic appearance of a target lesion with an outermost erythematous ring and paler centre, in keeping with a diagnosis of erythema multiforme. Erythema multiforme is an acute, self-limiting skin eruption most commonly secondary to an infective trigger (e.g. herpes simplex virus or *Mycoplasma pneumoniae*). The history of low-grade fevers and a dry cough further support an infective component of this patient's rash. The rash appears abruptly and affects the upper limbs most often before spreading down towards the trunk. A history of lethargy and low-grade fevers suggests a recent infection that may have triggered the onset of the rash.

Erythema marginatum is a manifestation of acute rheumatic fever. It is most commonly seen in children and is rare in adults. It presents as annular erythematous macules or papules that spread outwards with central clearance. The lesions are not itchy or painful and may be asymptomatic.

Irritant contact dermatitis is an inflammatory skin condition secondary to contact with irritants to the skin (e.g. detergents). The rash manifests as an erythematous and dry rash that may feel painful or itchy. There is no history of exposure to irritants in this question and the rash does not appear to be dry or flaky which makes irritant contact dermatitis less likely.

Lichen planus is a chronic inflammatory skin condition characterised by purplish papules and plaques commonly found on the front of the wrists. They are often shiny and may have fine white lines covering the surface (Wickham striae). This description does not match the rash in the photograph, making it the incorrect answer.

Plaque psoriasis is a chronic inflammatory skin condition that gives rise to well-defined red plaques with an overlying silver scale. Common features include itch and painful fissures. The rash in the image does not show the presence of erythematous plaques. Furthermore, this patient's rash has had an acute onset which is atypical of psoriasis that has a much slower onset.

Discuss (1) | Improve

Next question

## Erythema multiforme

Erythema multiforme is a hypersensitivity reaction that is most commonly triggered by infections. It may be divided into minor and major forms.

Previously it was thought that Stevens-Johnson syndrome (SJS) was a severe form of erythema multiforme. They are now however considered as separate entities.

Features

- target lesions
- initially seen on the back of the hands / feet before spreading to the torso
- upper limbs are more commonly affected than the lower limbs
- pruritus is occasionally seen and is usually mild

Causes

- viruses: herpes simplex virus (the most common cause), Orf*
- idiopathic
- bacteria: *Mycoplasma*, *Streptococcus*
- drugs: penicillin, sulphonamides, carbamazepine, allopurinol, NSAIDs, oral contraceptive pill, nevirapine
- connective tissue disease e.g. Systemic lupus erythematosus
- sarcoidosis
- malignancy

## Erythema multiforme major

The more severe form, erythema multiforme major is associated with mucosal involvement.

*Orf is a skin disease of sheep and goats caused by a parapox virus

123

Next question

## Textbooks

High-yield textbook

Extended textbook

## Links

DermNet NZ 18 10

Erythema multiforme

Suggest link

Report broken link

## Media

Erythema multiforme

Osmosis - YouTube

1 0

Report broken media

Score: **17%**

| | |
|---|---|
| 1 | ✗ |
| 2 | ✗ |
| 3 | ✓ |
| 4 | ✗ |
| 5 | ✗ |
| 6 | ✗ |
| 7 | ✗ |
| 8 | ✗ |
| 9 | ✗ |
| 10 | ✗ |
| 11 | ✓ |
| 12 | ✗ |
| 13 | ✓ |
| 14 | ✗ |
| 15 | ✗ |
| 16 | ✗ |
| 17 | ✗ |
| 18 | ✗ |
| 19 | ✗ |
| 20 | ✗ |
| 21 | ✗ |
| 22 | ✗ |
| 23 | ✗ |
| 24 | ✗ |
| 25 | ✗ |
| 26 | ✓ |
| 27 | ✗ |
| 28 | ✗ |

| | |
|---|---|
| 29 | ✗ |
| 30 | ✗ |
| 31 | ✗ |
| 32 | ✓ |
| 33 | ✗ |
| 34 | ✗ |
| 35 | ✗ |
| 36 | ✗ |
| 37 | ✗ |
| 38 | ✗ |
| 39 | ✗ |
| 40 | ✗ |
| 41 | ✗ |
| 42 | ✗ |
| 43 | ✗ |
| 44 | ✓ |
| 45 | ✗ |
| 46 | ✗ |
| 47 | ✓ |
| 48 | ✗ |
| 49 | ✗ |
| 50 | ✗ |
| 51 | ✗ |
| 52 | ✗ |
| 53 | ✗ |
| 54 | ✗ |
| 55 | ✗ |
| 56 | ✗ |
| 57 | ✗ |
| 58 | ✗ |
| 59 | ✗ |
| 60 | ✗ |
| 61 | ✗ |
| 62 | ✓ |
| 63 | ✗ |
| 64 | ✗ |

| | |
|---|---|
| 65 | ✓ |
| 66 | ✗ |
| 67 | ✗ |
| 68 | ✗ |
| 69 | ✓ |
| 70 | ✓ |
| 71 | ✗ |
| 72 | ✗ |
| 73 | ✗ |
| 74 | ✓ |
| 75 | ✗ |
| 76 | ✗ |
| 77 | ✗ |
| 78 | ✗ |
| 79 | - |
| 80 | ✓ |
| 81 | ✗ |
| 82 | ✗ |
| 83 | ✗ |
| 84 | ✗ |
| 85 | ✗ |
| 86 | ✗ |
| **87** | ✗ |
| 88 | ✓ |
| 89 | ✓ |
| 90 | ✗ |
| 91 | ✗ |
| 92 | ✗ |
| 93 | ✗ |
| 94 | ✓ |
| 95 | ✗ |
| 96 | ✗ |
| 97 | ✗ |
| 98 | ✗ |
| 99 | ✓ |
| 100 | ✗ |

101 ✕

All contents of this site are © 2024 Passmedicine Limited

A 68-year-old man asks you to 'check his moles' during an admission. He was admitted three days ago with a non-ST elevation myocardial infarction. You look at the following area of skin on his back:

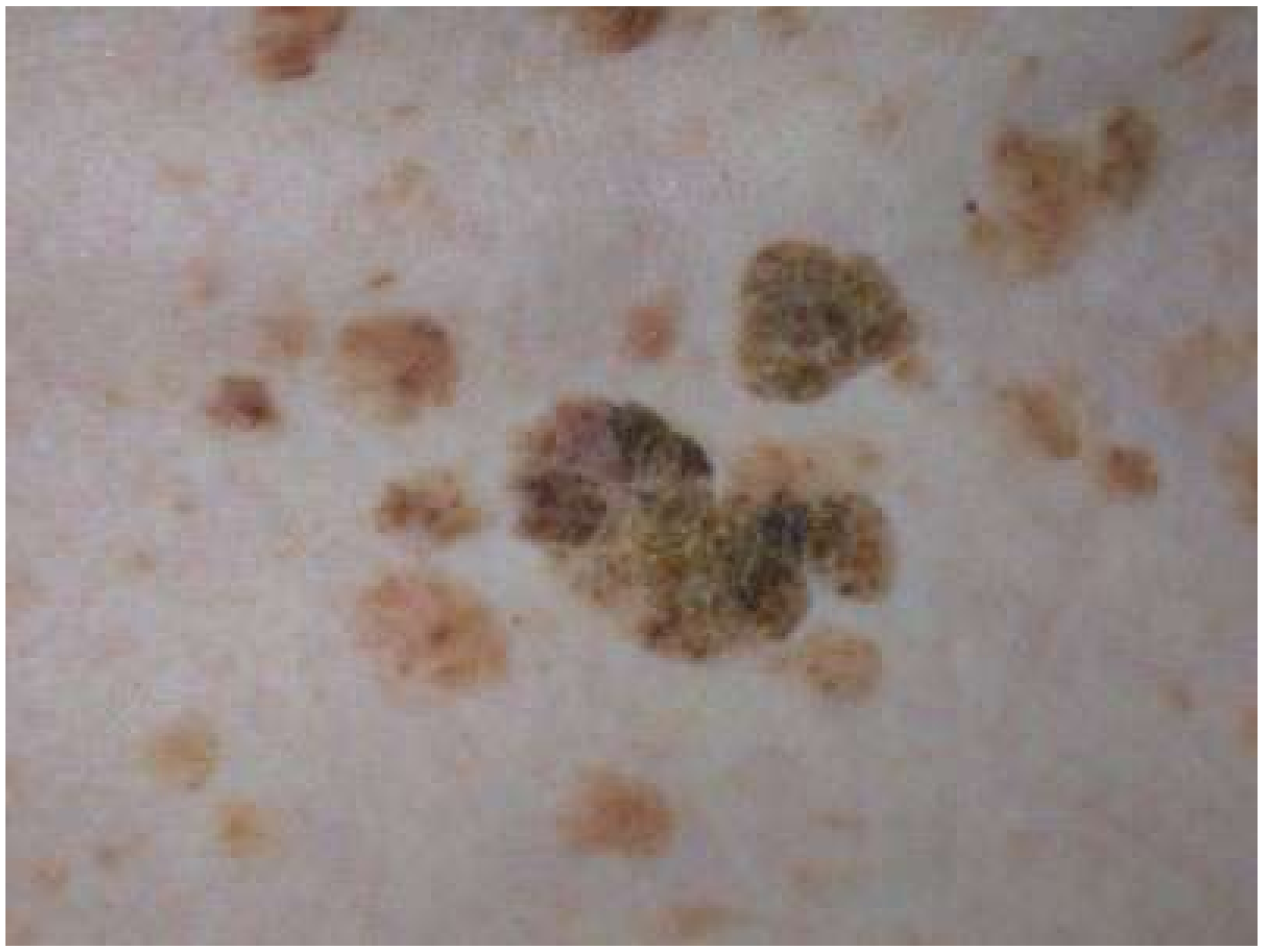

© Image used on license from DermNet NZ

What is the most likely diagnosis?

- Actinic keratosis
- Benign mole
- Bowen's disease
- Malignant melanoma
- Seborrhoeic keratosis

Submit answer

Reference ranges

Score: **14%**

| | |
|---|---|
| 1 | ✗ |
| 2 | ✗ |
| 3 | ✓ |
| 4 | ✗ |
| 5 | ✗ |
| 6 | ✗ |
| 7 | ✗ |
| 8 | ✗ |
| 9 | ✗ |
| 10 | ✗ |
| 11 | ✓ |
| 12 | ✗ |
| 13 | ✓ |
| 14 | ✗ |
| 15 | ✗ |
| 16 | ✗ |
| 17 | ✗ |
| 18 | ✗ |
| 19 | ✗ |
| 20 | ✗ |
| 21 | ✗ |
| 22 | ✗ |
| 23 | ✗ |
| 24 | ✗ |
| 25 | ✗ |
| 26 | ✓ |
| 27 | ✗ |
| 28 | ✗ |
| 29 | ✗ |
| 30 | ✗ |
| 31 | ✗ |
| 32 | ✓ |
| 33 | ✗ |
| 34 | ✗ |

| | |
|---|---|
| 35 | ✗ |
| 36 | ✗ |
| 37 | ✗ |
| 38 | ✗ |
| 39 | ✗ |
| 40 | ✗ |
| 41 | ✗ |
| 42 | ✗ |
| 43 | ✗ |
| 44 | ✓ |
| 45 | ✗ |
| 46 | ✗ |
| 47 | ✓ |
| 48 | ✗ |
| 49 | ✗ |
| 50 | ✗ |
| 51 | - |
| 52 | - |
| 53 | - |
| 54 | - |
| 55 | - |
| 56 | - |
| 57 | - |
| 58 | - |
| 59 | - |
| 60 | - |
| 61 | - |
| 62 | - |
| 63 | - |
| 64 | - |
| 65 | - |
| 66 | - |
| 67 | - |
| 68 | - |
| 69 | - |
| 70 | - |
| 71 | - |
| 72 | - |

73 -
74 -
75 -
76 -
77 -
78 -
79 -
80 -
81 -
82 -
83 -
84 -
85 -
86 -
87 -
**88** -

All contents of this site are © 2024 Passmedicine Limited

Back to top

A 68-year-old man asks you to 'check his moles' during an admission. He was admitted three days ago with a non-ST elevation myocardial infarction. You look at the following area of skin on his back:

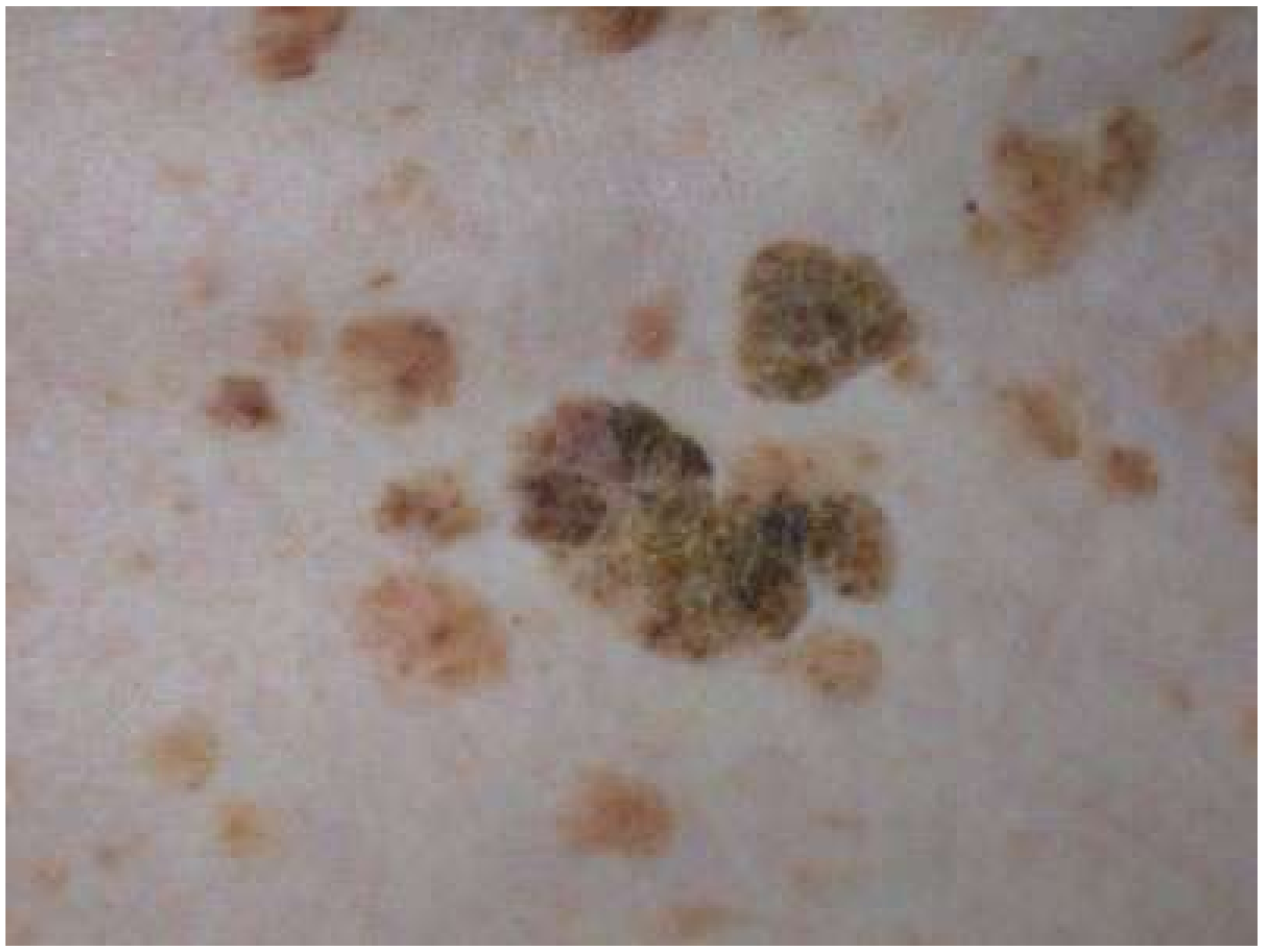

© Image used on license from DermNet NZ

What is the most likely diagnosis?

| | |
|---|---|
| Actinic keratosis | 14% |
| Benign mole | 2% |
| Bowen's disease | 7% |
| Malignant melanoma | 23% |
| Seborrhoeic keratosis | 54% |

This lesion has the typical warty, 'stuck-on' appearance of a seborrhoeic keratosis.

Discuss (1) Improve

Next question

# Seborrhoeic keratoses ★

Seborrhoeic keratoses are benign epidermal skin lesions seen in older people.

Features

- large variation in colour from flesh to light-brown to black
- have a 'stuck-on' appearance
- keratotic plugs may be seen on the surface

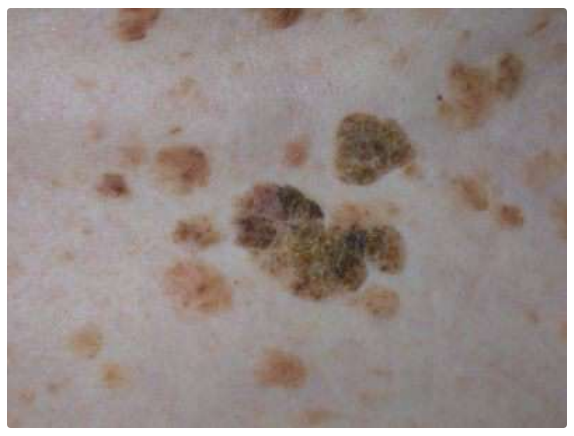

Management

- reassurance about the benign nature of the lesion is an option
- options for removal include curettage, cryosurgery and shave biopsy

AI + Q 123

Next question >

## Textbooks

High-yield textbook

Extended textbook

## Links

DermNet NZ

Seborrhoeic keratoses

5 5

Suggest link Report broken link

Score: **17%**

| | |
|---|---|
| 1 | ✗ |
| 2 | ✗ |
| 3 | ✓ |
| 4 | ✗ |
| 5 | ✗ |
| 6 | ✗ |
| 7 | ✗ |
| 8 | ✗ |
| 9 | ✗ |
| 10 | ✗ |
| 11 | ✓ |
| 12 | ✗ |
| 13 | ✓ |
| 14 | ✗ |
| 15 | ✗ |
| 16 | ✗ |
| 17 | ✗ |
| 18 | ✗ |
| 19 | ✗ |
| 20 | ✗ |
| 21 | ✗ |
| 22 | ✗ |
| 23 | ✗ |
| 24 | ✗ |
| 25 | ✗ |
| 26 | ✓ |

| | |
|---|---|
| 27 | ✗ |
| 28 | ✗ |
| 29 | ✗ |
| 30 | ✗ |
| 31 | ✗ |
| 32 | ✓ |
| 33 | ✗ |
| 34 | ✗ |
| 35 | ✗ |
| 36 | ✗ |
| 37 | ✗ |
| 38 | ✗ |
| 39 | ✗ |
| 40 | ✗ |
| 41 | ✗ |
| 42 | ✗ |
| 43 | ✗ |
| 44 | ✓ |
| 45 | ✗ |
| 46 | ✗ |
| 47 | ✓ |
| 48 | ✗ |
| 49 | ✗ |
| 50 | ✗ |
| 51 | ✗ |
| 52 | ✗ |
| 53 | ✗ |
| 54 | ✗ |
| 55 | ✗ |
| 56 | ✗ |
| 57 | ✗ |
| 58 | ✗ |
| 59 | ✗ |
| 60 | ✗ |
| 61 | ✗ |
| 62 | ✓ |

| | |
|---|---|
| 63 | ✗ |
| 64 | ✗ |
| 65 | ✓ |
| 66 | ✗ |
| 67 | ✗ |
| 68 | ✗ |
| 69 | ✓ |
| 70 | ✓ |
| 71 | ✗ |
| 72 | ✗ |
| 73 | ✗ |
| 74 | ✓ |
| 75 | ✗ |
| 76 | ✗ |
| 77 | ✗ |
| 78 | ✗ |
| 79 | - |
| 80 | ✓ |
| 81 | ✗ |
| 82 | ✗ |
| 83 | ✗ |
| 84 | ✗ |
| 85 | ✗ |
| 86 | ✗ |
| 87 | ✗ |
| **88** | ✓ |
| 89 | ✓ |
| 90 | ✗ |
| 91 | ✗ |
| 92 | ✗ |
| 93 | ✗ |
| 94 | ✓ |
| 95 | ✗ |
| 96 | ✗ |
| 97 | ✗ |
| 98 | ✗ |

99 ✓
100 ✗
101 ✗

All contents of this site are © 2024 Passmedicine Limited Back to top

A 34-year-old man presents with a small lump on his hand. He says that it has been present for several months. He cannot remember a clear onset, although does remember a thorn-related injury on that hand whilst gardening.

On examination, the lump appears as shown below:

© Image used on license from DermNet NZ

It is approximately 8mm in diameter and not tender.

Given the most likely diagnosis, which of the following should happen next?

- Aspiration
- Biopsy
- Cryotherapy
- Excision
- Observation

Submit answer

Reference ranges

Score: **14%**

| | |
|---|---|
| 1 | ✗ |
| 2 | ✗ |
| 3 | ✓ |
| 4 | ✗ |
| 5 | ✗ |
| 6 | ✗ |
| 7 | ✗ |
| 8 | ✗ |
| 9 | ✗ |
| 10 | ✗ |
| 11 | ✓ |
| 12 | ✗ |
| 13 | ✓ |
| 14 | ✗ |
| 15 | ✗ |
| 16 | ✗ |
| 17 | ✗ |
| 18 | ✗ |
| 19 | ✗ |
| 20 | ✗ |
| 21 | ✗ |
| 22 | ✗ |
| 23 | ✗ |
| 24 | ✗ |
| 25 | ✗ |
| 26 | ✓ |
| 27 | ✗ |
| 28 | ✗ |
| 29 | ✗ |
| 30 | ✗ |

| | |
|---|---|
| 31 | ✗ |
| 32 | ✓ |
| 33 | ✗ |
| 34 | ✗ |
| 35 | ✗ |
| 36 | ✗ |
| 37 | ✗ |
| 38 | ✗ |
| 39 | ✗ |
| 40 | ✗ |
| 41 | ✗ |
| 42 | ✗ |
| 43 | ✗ |
| 44 | ✓ |
| 45 | ✗ |
| 46 | ✗ |
| 47 | ✓ |
| 48 | ✗ |
| 49 | ✗ |
| 50 | ✗ |
| 51 | - |
| 52 | - |
| 53 | - |
| 54 | - |
| 55 | - |
| 56 | - |
| 57 | - |
| 58 | - |
| 59 | - |
| 60 | - |
| 61 | - |
| 62 | - |
| 63 | - |
| 64 | - |
| 65 | - |
| 66 | - |
| 67 | - |
| 68 | - |

| | |
|---|---|
| 69 | - |
| 70 | - |
| 71 | - |
| 72 | - |
| 73 | - |
| 74 | - |
| 75 | - |
| 76 | - |
| 77 | - |
| 78 | - |
| 79 | - |
| 80 | - |
| 81 | - |
| 82 | - |
| 83 | - |
| 84 | - |
| 85 | - |
| 86 | - |
| 87 | - |
| 88 | - |
| **89** | - |

All contents of this site are © 2024 Passmedicine Limited
Back to top

A 34-year-old man presents with a small lump on his hand. He says that it has been present for several months. He cannot remember a clear onset, although does remember a thorn-related injury on that hand whilst gardening.

On examination, the lump appears as shown below:

© Image used on license from DermNet NZ

It is approximately 8mm in diameter and not tender.

Given the most likely diagnosis, which of the following should happen next?

| | |
|---|---|
| Aspiration | 2% |
| Biopsy | 4% |
| Cryotherapy | 8% |
| Excision | 14% |
| Observation | 72% |

This photo is indicative of a dermatofibroma, commonly found in young people - more so on the legs, rather than on the hands as seen here. It is a solitary, firm papule, usually less than 1cm in diameter. It has a regular border, shape, colour and is symmetrical - there are no concerning

features regarding its appearance. In this case, as the lesion is not tender or irritating, it can simply be observed for now and the patient reassured.

Aspiration is inappropriate - dermatofibromas are solid lesions, not fluid-filled.

A biopsy may be undertaken if any atypical features trigger concern for a more serious diagnosis. However, in this instance, we can see the lesion looks entirely regular and typical.

Cryotherapy is a suitable option for treatment if the lesion is bothersome, according to the British Association of Dermatologists. In this scenario, there are no troublesome features mentioned and so the patient should be reassured at this stage.

Excision is another suitable option for treatment if bothersome. However, in this scenario, the lesion causes no issues and so should simply be observed for now.

Discuss Improve

Next question

## Dermatofibroma

Dermatofibromas (also known as histiocytomas) are common benign fibrous skin lesions. They are caused by the abnormal growth of dermal dendritic histiocyte cells, often following a precipitating injury. Common areas include the arms and legs.

Features
- solitary firm papule or nodule, typically on a limb
- typically around 5-10mm in size
- overlying skin dimples on pinching the lesion

123

Next question

**Textbooks**

High-yield textbook

Extended textbook

Score: **17%**

| | |
|---|---|
| 1 | ✗ |
| 2 | ✗ |
| 3 | ✓ |
| 4 | ✗ |
| 5 | ✗ |
| 6 | ✗ |
| 7 | ✗ |
| 8 | ✗ |
| 9 | ✗ |
| 10 | ✗ |
| 11 | ✓ |
| 12 | ✗ |
| 13 | ✓ |
| 14 | ✗ |
| 15 | ✗ |
| 16 | ✗ |
| 17 | ✗ |
| 18 | ✗ |
| 19 | ✗ |

| | |
|---|---|
| 20 | ✗ |
| 21 | ✗ |
| 22 | ✗ |
| 23 | ✗ |
| 24 | ✗ |
| 25 | ✗ |
| 26 | ✓ |
| 27 | ✗ |
| 28 | ✗ |
| 29 | ✗ |
| 30 | ✗ |
| 31 | ✗ |
| 32 | ✓ |
| 33 | ✗ |
| 34 | ✗ |
| 35 | ✗ |
| 36 | ✗ |
| 37 | ✗ |
| 38 | ✗ |
| 39 | ✗ |
| 40 | ✗ |
| 41 | ✗ |
| 42 | ✗ |
| 43 | ✗ |
| 44 | ✓ |
| 45 | ✗ |
| 46 | ✗ |
| 47 | ✓ |
| 48 | ✗ |
| 49 | ✗ |
| 50 | ✗ |
| 51 | ✗ |
| 52 | ✗ |
| 53 | ✗ |
| 54 | ✗ |
| 55 | ✗ |

| | |
|---|---|
| 56 | ✗ |
| 57 | ✗ |
| 58 | ✗ |
| 59 | ✗ |
| 60 | ✗ |
| 61 | ✗ |
| 62 | ✓ |
| 63 | ✗ |
| 64 | ✗ |
| 65 | ✓ |
| 66 | ✗ |
| 67 | ✗ |
| 68 | ✗ |
| 69 | ✓ |
| 70 | ✓ |
| 71 | ✗ |
| 72 | ✗ |
| 73 | ✗ |
| 74 | ✓ |
| 75 | ✗ |
| 76 | ✗ |
| 77 | ✗ |
| 78 | ✗ |
| 79 | - |
| 80 | ✓ |
| 81 | ✗ |
| 82 | ✗ |
| 83 | ✗ |
| 84 | ✗ |
| 85 | ✗ |
| 86 | ✗ |
| 87 | ✗ |
| 88 | ✓ |
| **89** | ✓ |
| 90 | ✗ |
| 91 | ✗ |

| | |
|---|---|
| 92 | ✗ |
| 93 | ✗ |
| 94 | ✓ |
| 95 | ✗ |
| 96 | ✗ |
| 97 | ✗ |
| 98 | ✗ |
| 99 | ✓ |
| 100 | ✗ |
| 101 | ✗ |

All contents of this site are © 2024 Passmedicine Limited

Back to top

A 30-year-old woman presents with a painful 'rash' on her shins:

© Image used on license from DermNet NZ and with the kind permission of Prof Raimo Suhonen

These have been present for the past 2 weeks. There is no past medical history of note although she had a course of penicillin V for a bout of tonsillitis around a month ago. She also takes Cerazette (a progestogen-only pill) for contraception.

A chest x-ray is requested:

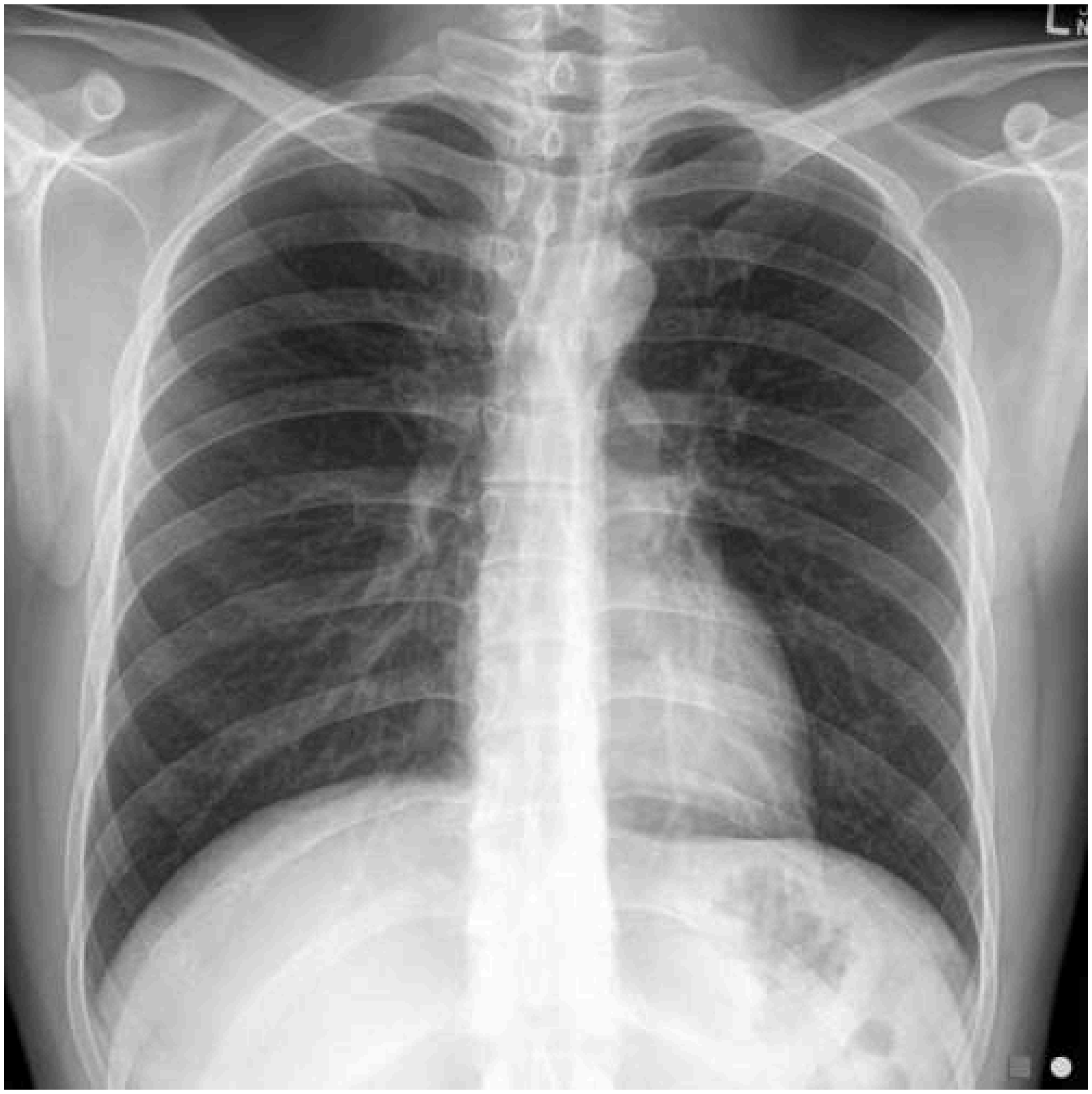

© Image used on license from Radiopaedia

What is the most likely cause of the skin lesions?

- Lymphoma
- Sarcoidosis
- Progestogen-only pill
- Penicillin
- Tuberculosis

Submit answer

Reference ranges

Score: **14%**

| | |
|---|---|
| 1 | ✗ |
| 2 | ✗ |
| 3 | ✓ |
| 4 | ✗ |
| 5 | ✗ |
| 6 | ✗ |
| 7 | ✗ |
| 8 | ✗ |
| 9 | ✗ |
| 10 | ✗ |
| 11 | ✓ |
| 12 | ✗ |
| 13 | ✓ |
| 14 | ✗ |
| 15 | ✗ |
| 16 | ✗ |
| 17 | ✗ |
| 18 | ✗ |
| 19 | ✗ |
| 20 | ✗ |
| 21 | ✗ |
| 22 | ✗ |
| 23 | ✗ |
| 24 | ✗ |
| 25 | ✗ |
| 26 | ✓ |
| 27 | ✗ |
| 28 | ✗ |
| 29 | ✗ |
| 30 | ✗ |
| 31 | ✗ |
| 32 | ✓ |
| 33 | ✗ |

| | |
|---|---|
| 34 | ✗ |
| 35 | ✗ |
| 36 | ✗ |
| 37 | ✗ |
| 38 | ✗ |
| 39 | ✗ |
| 40 | ✗ |
| 41 | ✗ |
| 42 | ✗ |
| 43 | ✗ |
| 44 | ✓ |
| 45 | ✗ |
| 46 | ✗ |
| 47 | ✓ |
| 48 | ✗ |
| 49 | ✗ |
| 50 | ✗ |
| 51 | - |
| 52 | - |
| 53 | - |
| 54 | - |
| 55 | - |
| 56 | - |
| 57 | - |
| 58 | - |
| 59 | - |
| 60 | - |
| 61 | - |
| 62 | - |
| 63 | - |
| 64 | - |
| 65 | - |
| 66 | - |
| 67 | - |
| 68 | - |
| 69 | - |
| 70 | - |
| 71 | - |

72 -
73 -
74 -
75 -
76 -
77 -
78 -
79 -
80 -
81 -
82 -
83 -
84 -
85 -
86 -
87 -
88 -
89 -
**90** -
91 -
92 -
93 -
94 -

All contents of this site are © 2024 Passmedicine Limited Back to top

A 30-year-old woman presents with a painful 'rash' on her shins:

© Image used on license from DermNet NZ and with the kind permission of Prof Raimo Suhonen

These have been present for the past 2 weeks. There is no past medical history of note although she had a course of penicillin V for a bout of tonsillitis around a month ago. She also takes Cerazette (a progestogen-only pill) for contraception.

A chest x-ray is requested:

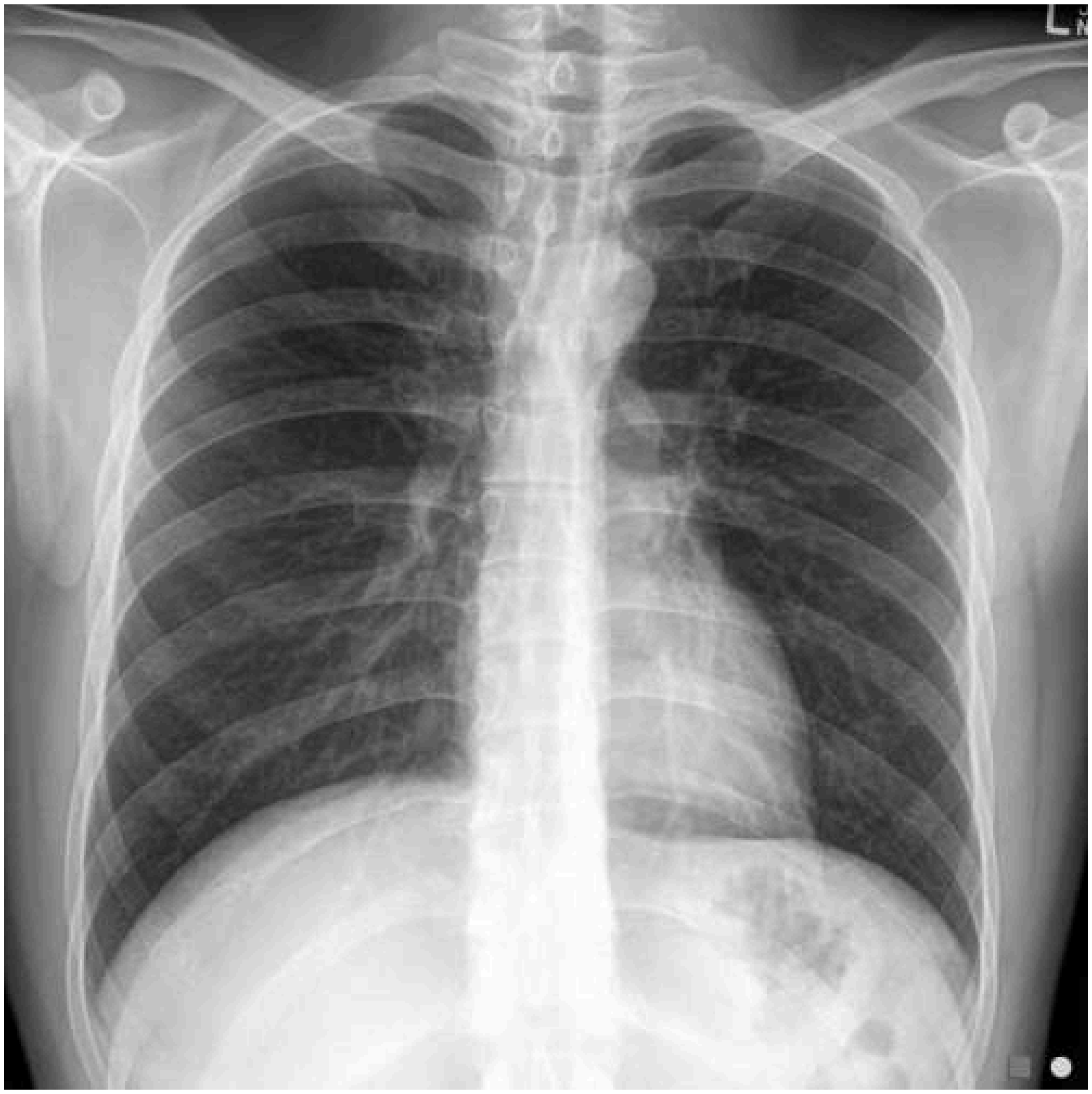
© Image used on license from Radiopaedia

What is the most likely cause of the skin lesions?

| | |
|---|---|
| Lymphoma | 1% |
| Sarcoidosis | 37% |
| Progestogen-only pill | 26% |
| Penicillin | 35% |
| Tuberculosis | 1% |

The likely diagnosis here is erythema nodosum (EN). The chest x-ray is completely normal making penicillin the likely culprit in precipitating skin lesions.

The combined oral contraceptive pill is linked to EN rather than the progestogen-only pill.

# Erythema nodosum

Overview

- inflammation of subcutaneous fat
- typically causes tender, erythematous, nodular lesions
- usually occurs over shins, may also occur elsewhere (e.g. forearms, thighs)
- usually resolves within 6 weeks
- lesions heal without scarring

Causes

- infection
  - streptococci
  - tuberculosis
  - brucellosis
- systemic disease
  - sarcoidosis
  - inflammatory bowel disease
  - Behcet's
- malignancy/lymphoma
- drugs
  - penicillins
  - sulphonamides
  - combined oral contraceptive pill
- pregnancy

123

Next question

## Textbooks

High-yield textbook

Extended textbook

## Links

DermNet NZ 30 14

Erythema nodosum

Suggest link Report broken link

Score: **17%**

1 ✗
2 ✗
3 ✓

| | |
|---|---|
| 4 | ✗ |
| 5 | ✗ |
| 6 | ✗ |
| 7 | ✗ |
| 8 | ✗ |
| 9 | ✗ |
| 10 | ✗ |
| 11 | ✓ |
| 12 | ✗ |
| 13 | ✓ |
| 14 | ✗ |
| 15 | ✗ |
| 16 | ✗ |
| 17 | ✗ |
| 18 | ✗ |
| 19 | ✗ |
| 20 | ✗ |
| 21 | ✗ |
| 22 | ✗ |
| 23 | ✗ |
| 24 | ✗ |
| 25 | ✗ |
| 26 | ✓ |
| 27 | ✗ |
| 28 | ✗ |
| 29 | ✗ |
| 30 | ✗ |
| 31 | ✗ |
| 32 | ✓ |
| 33 | ✗ |
| 34 | ✗ |
| 35 | ✗ |
| 36 | ✗ |
| 37 | ✗ |
| 38 | ✗ |
| 39 | ✗ |

| | |
|---|---|
| 40 | ✗ |
| 41 | ✗ |
| 42 | ✗ |
| 43 | ✗ |
| 44 | ✓ |
| 45 | ✗ |
| 46 | ✗ |
| 47 | ✓ |
| 48 | ✗ |
| 49 | ✗ |
| 50 | ✗ |
| 51 | ✗ |
| 52 | ✗ |
| 53 | ✗ |
| 54 | ✗ |
| 55 | ✗ |
| 56 | ✗ |
| 57 | ✗ |
| 58 | ✗ |
| 59 | ✗ |
| 60 | ✗ |
| 61 | ✗ |
| 62 | ✓ |
| 63 | ✗ |
| 64 | ✗ |
| 65 | ✓ |
| 66 | ✗ |
| 67 | ✗ |
| 68 | ✗ |
| 69 | ✓ |
| 70 | ✓ |
| 71 | ✗ |
| 72 | ✗ |
| 73 | ✗ |
| 74 | ✓ |
| 75 | ✗ |

| | |
|---|---|
| 76 | ✗ |
| 77 | ✗ |
| 78 | ✗ |
| 79 | - |
| 80 | ✓ |
| 81 | ✗ |
| 82 | ✗ |
| 83 | ✗ |
| 84 | ✗ |
| 85 | ✗ |
| 86 | ✗ |
| 87 | ✗ |
| 88 | ✓ |
| 89 | ✓ |
| **90** | ✗ |
| 91 | ✗ |
| 92 | ✗ |
| 93 | ✗ |
| 94 | ✓ |
| 95 | ✗ |
| 96 | ✗ |
| 97 | ✗ |
| 98 | ✗ |
| 99 | ✓ |
| 100 | ✗ |
| 101 | ✗ |

All contents of this site are © 2024 Passmedicine Limited

Back to top

A 32-year-old man with autism spectrum disorder presents to the general medical clinic. He was referred by his GP for urgent review whilst awaiting a dermatology appointment. The patient has been experiencing a severe eczema flare which has not been controlled despite the use of emollients twice each day, strong topical corticosteroids for five days and non-sedating antihistamines. He has no other medical problems. He has become very concerned about the spreading rash and feels a high level of anxiety with it. On examination, there is spreading erythema from flexural folds on arms and legs. What is the most appropriate treatment option whilst awaiting dermatology opinion?

- Admit for IV hydrocortisone 200mg QDS
- Start prednisolone 30mg OD for one week
- Start prednisolone 30mg OD long-term with bone protection
- Advise for bandaging
- Start urea-containing emollient

Submit answer

Reference ranges

Score: **14%**

| | |
|---|---|
| 1 | ✗ |
| 2 | ✗ |
| 3 | ✓ |
| 4 | ✗ |
| 5 | ✗ |
| 6 | ✗ |

| | |
|---|---|
| 7 | ✗ |
| 8 | ✗ |
| 9 | ✗ |
| 10 | ✗ |
| 11 | ✓ |
| 12 | ✗ |
| 13 | ✓ |
| 14 | ✗ |
| 15 | ✗ |
| 16 | ✗ |
| 17 | ✗ |
| 18 | ✗ |
| 19 | ✗ |
| 20 | ✗ |
| 21 | ✗ |
| 22 | ✗ |
| 23 | ✗ |
| 24 | ✗ |
| 25 | ✗ |
| 26 | ✓ |
| 27 | ✗ |
| 28 | ✗ |
| 29 | ✗ |
| 30 | ✗ |
| 31 | ✗ |
| 32 | ✓ |
| 33 | ✗ |
| 34 | ✗ |
| 35 | ✗ |
| 36 | ✗ |
| 37 | ✗ |
| 38 | ✗ |
| 39 | ✗ |
| 40 | ✗ |
| 41 | ✗ |
| 42 | ✗ |

| | |
|---|---|
| 43 | ✗ |
| 44 | ✓ |
| 45 | ✗ |
| 46 | ✗ |
| 47 | ✓ |
| 48 | ✗ |
| 49 | ✗ |
| 50 | ✗ |
| 51 | - |
| 52 | - |
| 53 | - |
| 54 | - |
| 55 | - |
| 56 | - |
| 57 | - |
| 58 | - |
| 59 | - |
| 60 | - |
| 61 | - |
| 62 | - |
| 63 | - |
| 64 | - |
| 65 | - |
| 66 | - |
| 67 | - |
| 68 | - |
| 69 | - |
| 70 | - |
| 71 | - |
| 72 | - |
| 73 | - |
| 74 | - |
| 75 | - |
| 76 | - |
| 77 | - |
| 78 | - |
| 79 | - |
| 80 | - |
| 81 | - |

| | |
|---|---|
| 82 | - |
| 83 | - |
| 84 | - |
| 85 | - |
| 86 | - |
| 87 | - |
| 88 | - |
| 89 | - |
| 90 | - |
| **91** | - |
| 92 | - |
| 93 | - |
| 94 | - |

All contents of this site are © 2024 Passmedicine Limited

A 32-year-old man with autism spectrum disorder presents to the general medical clinic. He was referred by his GP for urgent review whilst awaiting a dermatology appointment. The patient has been experiencing a severe eczema flare which has not been controlled despite the use of emollients twice each day, strong topical corticosteroids for five days and non-sedating antihistamines. He has no other medical problems. He has become very concerned about the spreading rash and feels a high level of anxiety with it. On examination, there is spreading erythema from flexural folds on arms and legs. What is the most appropriate treatment option whilst awaiting dermatology opinion?

| | |
|---|---|
| Admit for IV hydrocortisone 200mg QDS | 5% |
| Start prednisolone 30mg OD for one week | 38% |
| Start prednisolone 30mg OD long-term with bone protection | 5% |
| Advise for bandaging | 32% |
| Start urea-containing emollient | 20% |

Prednisolone treatment for eczema flares needs several weeks of treatment and then tapering off to prevent rebound

Important for me Less important

The most appropriate action for this patient is for a trial of oral prednisolone. NICE advises one week of 30mg OD whilst awaiting dermatology review, which can be extended as necessary, but this should be done under close review. This would be especially done for people who are suffering psychological distress from severe eczema. Admission is not necessary but would be if the patient was unstable or had eczema herpeticum. Bandaging would be a better approach for weeping or lichenified eczema. and urea-containing emollients are useful when greater hydration is needed for pruritic skin in the absence of severe inflammation.

# Eczema: management

## Management

Avoidance of triggers and skin care education

- Key components include avoiding known irritants, allergens, and providing guidance on gentle skin care routines.

Emollients

- Integral to all treatment plans, regardless of eczema severity.
- Advise on liberal and regular use, even when the skin is clear, to maintain skin hydration and barrier function.
- Selection of emollient should be based on patient preference to improve adherence
    - Creams are generally preferred by most people - adherence is key so
    - Ointments provide the strongest emollient effect and may be more effective. However, they are greasy and so may be more suitable for use at night.

Topical therapies

- Topical corticosteroids
    - Vital for managing flare-ups, with potency tailored to the severity and lesion location
    - Example treatments recommended by NICE:
    - Mild eczema: hydrocortisone 1%
    - Moderate eczema: betamethasone valerate 0.025% or clobetasone butyrate 0.05%
    - Severe eczema: betamethasone valerate 0.1%
- Topical calcineurin inhibitors
    - Suitable for sensitive skin regions; include agents like tacrolimus and pimecrolimus.
- Topical antimicrobials
    - Used when there is clinical evidence of secondary infection.

Systemic therapies

- Indicated for severe or unresponsive cases.
- Oral corticosteroids:
    - Employed cautiously for acute severe exacerbations.
- Immunosuppressants:
    - Ciclosporin, methotrexate, or azathioprine are reserved for chronic, severe eczema.
- Biologic therapies:
    - Dupilumab is an advanced option for cases unresponsive to conventional therapy.

Phototherapy

- Considered for extensive eczema

## Prognosis

Prognostic markers associated with severe disease include:
- onset at age 3-6 months
- severe disease in childhood
- associated asthma or hay fever
- small family size
- high IgE serum levels

+ Q 123

Next question ›

### Textbooks

High-yield textbook

Extended textbook

### Links

British Association of Dermatologists 1 1

Atopic eczema guidelines

Clinical Knowledge Summaries 0 0

Atopic eczema

Suggest link Report broken link

**Media**

Eczema

Osmosis - YouTube 👍 2 👎 0

Report broken media

Score: **17%**

| | |
|---|---|
| 1 | ✗ |
| 2 | ✗ |
| 3 | ✓ |
| 4 | ✗ |
| 5 | ✗ |
| 6 | ✗ |
| 7 | ✗ |
| 8 | ✗ |
| 9 | ✗ |
| 10 | ✗ |
| 11 | ✓ |
| 12 | ✗ |
| 13 | ✓ |
| 14 | ✗ |
| 15 | ✗ |
| 16 | ✗ |
| 17 | ✗ |
| 18 | ✗ |
| 19 | ✗ |
| 20 | ✗ |
| 21 | ✗ |
| 22 | ✗ |

| | |
|---|---|
| 23 | ✗ |
| 24 | ✗ |
| 25 | ✗ |
| 26 | ✓ |
| 27 | ✗ |
| 28 | ✗ |
| 29 | ✗ |
| 30 | ✗ |
| 31 | ✗ |
| 32 | ✓ |
| 33 | ✗ |
| 34 | ✗ |
| 35 | ✗ |
| 36 | ✗ |
| 37 | ✗ |
| 38 | ✗ |
| 39 | ✗ |
| 40 | ✗ |
| 41 | ✗ |
| 42 | ✗ |
| 43 | ✗ |
| 44 | ✓ |
| 45 | ✗ |
| 46 | ✗ |
| 47 | ✓ |
| 48 | ✗ |
| 49 | ✗ |
| 50 | ✗ |
| 51 | ✗ |
| 52 | ✗ |
| 53 | ✗ |
| 54 | ✗ |
| 55 | ✗ |
| 56 | ✗ |
| 57 | ✗ |
| 58 | ✗ |

| | |
|---|---|
| 59 | ✗ |
| 60 | ✗ |
| 61 | ✗ |
| 62 | ✓ |
| 63 | ✗ |
| 64 | ✗ |
| 65 | ✓ |
| 66 | ✗ |
| 67 | ✗ |
| 68 | ✗ |
| 69 | ✓ |
| 70 | ✓ |
| 71 | ✗ |
| 72 | ✗ |
| 73 | ✗ |
| 74 | ✓ |
| 75 | ✗ |
| 76 | ✗ |
| 77 | ✗ |
| 78 | ✗ |
| 79 | - |
| 80 | ✓ |
| 81 | ✗ |
| 82 | ✗ |
| 83 | ✗ |
| 84 | ✗ |
| 85 | ✗ |
| 86 | ✗ |
| 87 | ✗ |
| 88 | ✓ |
| 89 | ✓ |
| 90 | ✗ |
| **91** | ✗ |
| 92 | ✗ |
| 93 | ✗ |
| 94 | ✓ |

| | |
|---|---|
| 95 | ✗ |
| 96 | ✗ |
| 97 | ✗ |
| 98 | ✗ |
| 99 | ✓ |
| 100 | ✗ |
| 101 | ✗ |

All contents of this site are © 2024 Passmedicine Limited

Back to top

A 30-year-old lady was admitted with a painful ulcer on her right lower limb. At first, the patient described developing a painful erythematous area which then rapidly broke down to form a painful ulcer. The edges of the ulcer had a purple discolouration. She did recall recently knocking this area whilst riding her bike to work. She had recently been considering seeing her GP as she had been opening her bowels around eight times a day with some mucus and she had noticed some mild abdominal pain. She attributed this to irritable bowel syndrome which she is believed to have had since the age of 20 years.

Her past medical history included migraines and a right deep vein thrombosis after a flight to America. Her father had a family history of diabetes. She had a biopsy of the ulcer which showed heavy neutrophil infiltration.

What is the most likely diagnosis?

- Pyoderma gangrenosum
- Erythema nodosum
- Necrobiosis lipoidica
- Leishmaniasis
- Venous ulcer

Submit answer

Reference ranges

Score: **14%**

1 ✗

| | |
|---|---|
| 2 | ✗ |
| 3 | ✓ |
| 4 | ✗ |
| 5 | ✗ |
| 6 | ✗ |
| 7 | ✗ |
| 8 | ✗ |
| 9 | ✗ |
| 10 | ✗ |
| 11 | ✓ |
| 12 | ✗ |
| 13 | ✓ |
| 14 | ✗ |
| 15 | ✗ |
| 16 | ✗ |
| 17 | ✗ |
| 18 | ✗ |
| 19 | ✗ |
| 20 | ✗ |
| 21 | ✗ |
| 22 | ✗ |
| 23 | ✗ |
| 24 | ✗ |
| 25 | ✗ |
| 26 | ✓ |
| 27 | ✗ |
| 28 | ✗ |
| 29 | ✗ |
| 30 | ✗ |
| 31 | ✗ |
| 32 | ✓ |
| 33 | ✗ |
| 34 | ✗ |
| 35 | ✗ |
| 36 | ✗ |
| 37 | ✗ |

| | |
|---|---|
| 38 | ✗ |
| 39 | ✗ |
| 40 | ✗ |
| 41 | ✗ |
| 42 | ✗ |
| 43 | ✗ |
| 44 | ✓ |
| 45 | ✗ |
| 46 | ✗ |
| 47 | ✓ |
| 48 | ✗ |
| 49 | ✗ |
| 50 | ✗ |
| 51 | - |
| 52 | - |
| 53 | - |
| 54 | - |
| 55 | - |
| 56 | - |
| 57 | - |
| 58 | - |
| 59 | - |
| 60 | - |
| 61 | - |
| 62 | - |
| 63 | - |
| 64 | - |
| 65 | - |
| 66 | - |
| 67 | - |
| 68 | - |
| 69 | - |
| 70 | - |
| 71 | - |
| 72 | - |
| 73 | - |
| 74 | - |
| 75 | - |
| 76 | - |

| | |
|---|---|
| 77 | - |
| 78 | - |
| 79 | - |
| 80 | - |
| 81 | - |
| 82 | - |
| 83 | - |
| 84 | - |
| 85 | - |
| 86 | - |
| 87 | - |
| 88 | - |
| 89 | - |
| 90 | - |
| 91 | - |
| **92** | - |
| 93 | - |
| 94 | - |

All contents of this site are © 2024 Passmedicine Limited

Back to top

A 30-year-old lady was admitted with a painful ulcer on her right lower limb. At first, the patient described developing a painful erythematous area which then rapidly broke down to form a painful ulcer. The edges of the ulcer had a purple discolouration. She did recall recently knocking this area whilst riding her bike to work. She had recently been considering seeing her GP as she had been opening her bowels around eight times a day with some mucus and she had noticed some mild abdominal pain. She attributed this to irritable bowel syndrome which she is believed to have had since the age of 20 years.

Her past medical history included migraines and a right deep vein thrombosis after a flight to America. Her father had a family history of diabetes. She had a biopsy of the ulcer which showed heavy neutrophil infiltration.

What is the most likely diagnosis?

- Pyoderma gangrenosum 87%
- Erythema nodosum 4%
- Necrobiosis lipoidica 6%
- Leishmaniasis 1%
- Venous ulcer 2%

This patient has Pyoderma gangrenosum with underlying undiagnosed inflammatory bowel disease.

Pyoderma gangrenosum is a rare, non-infectious, inflammatory disorder. It is an uncommon cause of very painful skin ulceration. It may affect any part of the skin, but the lower legs are the most common site. In 50% there is no underlying cause but in 10-15% it is associated with ulcerative colitis or Crohn's disease. Other associations include rheumatoid arthritis, myeloproliferative disorders, malignancy, and Wegener's granulomatosis.

Pyoderma gangrenosum is classified as a neutrophilic dermatosis. Neutrophilic dermatoses are skin conditions characterised by dense infiltration of neutrophils in the affected tissue and this is often seen on biopsy.

Pyoderma gangrenosum usually starts quite suddenly, often at the site of a minor injury as in this patient's case and this is known as pathergy. It may start as a small pustule, red bump or blood-blister. The skin then breaks down resulting in an ulcer which is often painful. The edge of the ulcer is often described as purple, violaceous and undermined.
Diagnosis of Pyoderma gangrenosum can be difficult. Diagnosis is often made by its characteristic appearance, associations with other diseases, the presence of pathergy, histology results and when other diseases have been ruled out. Histology is not specific and can vary depending on time and site of the specimen. It is helpful in ruling out other causes of an ulcer. The ulcer should be swabbed and cultured for micro-organisms and fungi.

Treatment is mainly steroid (0.5-2mg/kg) therapy which is slowly tapered over 1-2 months. Immunosuppressants are useful as a steroid sparing agent and maintenance therapy. These may include ciclosporin, methotrexate, mycophenolate mofetil and cyclophosphamide. Surgery should be postponed until the disease process is controlled on immunosuppression to risk worsening of the disease (pathergy).

Necrobiosis lipoidica is a skin disorder which can affect the shins. This most commonly occurs in patients with insulin dependent diabetics, although it may occur in non-diabetic patients. These lesions are characteristically yellowish brown patches which appear slowly over a few months. The patch is often pale, shiny and has telangiectasia present. They are often painless. Ulceration can occur if the patch has a minor injury to the area.

Erythema nodosum is often described as red lumps that form on the shins, but can also occur on the forearms and thighs. It is an inflammatory disorder affecting subcutaneous fat (panniculitis). Patients commonly develop these in association with bacterial infections (commonly mycoplasma pneumonia), streptococcal throat infections, sarcoidosis, tuberculosis, drugs such as the oral contractive pill, NSAIDS and salicylates, pregnancy and inflammatory bowel disease.

The lesions may appear in a range of sizes and number. The nodules are often painful, warm and red on first appearance. Later they may change to a purple colour and appear more like a bruise. This bruise like colour often evolves over the next 1-2 weeks and then subsides by 3rd to 6th week. The patient may also complain of a fever, arthralgia and malaise.

Discuss Improve

Next question

## Pyoderma gangrenosum

Pyoderma gangrenosum is a rare, non-infectious, inflammatory disorder. It is an uncommon cause of very painful skin ulceration. It may affect any part of the skin, but the lower legs are the most common site.

Pathophysiology

- pyoderma gangrenosum is classified as a neutrophilic dermatosis
- neutrophilic dermatoses are skin conditions characterised by dense infiltration of neutrophils in the affected tissue and this is often seen on biopsy

Causes

- idiopathic in 50%
- inflammatory bowel disease in 10-15%
  - ulcerative colitis
  - Crohn's
- rheumatological
  - rheumatoid arthritis
  - SLE
- haematological
  - myeloproliferative disorders
  - lymphoma
  - myeloid leukaemias
  - monoclonal gammopathy (IgA)
- granulomatosis with polyangiitis
- primary biliary cirrhosis

Features

- location
  - typically on the lower limb
  - soften at the site of a minor injury as in this patient's case and this is known as pathergy
- initially features:
  - usually starts quite suddenly
  - small pustule, red bump or blood-blister
- later features:
  - the skin then breaks down resulting in an ulcer which is often painful
  - the edge of the ulcer is often described as purple, violaceous and undermined.
  - the ulcer itself may be deep and necrotic
- may be accompanied by systemic symptoms
  - fever
  - myalgia

Diagnosis

- often made by the characteristic appearance, associations with other diseases, the presence of pathergy, histology results and when other diseases have been ruled out
- histology is not specific and can vary depending on the time and site of the specimen but may be helpful in ruling out other causes of an ulcer.

Management

- the potential for rapid progression is high in most patients and most doctors advocate oral steroids as first-line treatment
- other immunosuppressive therapy, for example, ciclosporin and infliximab, have a role in difficult cases
- any surgery should be postponed until the disease process is controlled on immunosuppression to risk worsening of the disease (pathergy)

123

Next question

**Textbooks**

High-yield textbook

Extended textbook

**Links**

DermNet NZ 10 9

Stoma skin problems

DermNet NZ 19 6

Pyoderma gangrenosum

Suggest link Report broken link

Score: **17%**

| | |
|---|---|
| 1 | ✗ |
| 2 | ✗ |
| 3 | ✓ |
| 4 | ✗ |
| 5 | ✗ |
| 6 | ✗ |
| 7 | ✗ |
| 8 | ✗ |
| 9 | ✗ |
| 10 | ✗ |
| 11 | ✓ |
| 12 | ✗ |
| 13 | ✓ |
| 14 | ✗ |
| 15 | ✗ |
| 16 | ✗ |
| 17 | ✗ |
| 18 | ✗ |
| 19 | ✗ |
| 20 | ✗ |
| 21 | ✗ |
| 22 | ✗ |
| 23 | ✗ |
| 24 | ✗ |
| 25 | ✗ |

| | |
|---|---|
| 26 | ✓ |
| 27 | ✗ |
| 28 | ✗ |
| 29 | ✗ |
| 30 | ✗ |
| 31 | ✗ |
| 32 | ✓ |
| 33 | ✗ |
| 34 | ✗ |
| 35 | ✗ |
| 36 | ✗ |
| 37 | ✗ |
| 38 | ✗ |
| 39 | ✗ |
| 40 | ✗ |
| 41 | ✗ |
| 42 | ✗ |
| 43 | ✗ |
| 44 | ✓ |
| 45 | ✗ |
| 46 | ✗ |
| 47 | ✓ |
| 48 | ✗ |
| 49 | ✗ |
| 50 | ✗ |
| 51 | ✗ |
| 52 | ✗ |
| 53 | ✗ |
| 54 | ✗ |
| 55 | ✗ |
| 56 | ✗ |
| 57 | ✗ |
| 58 | ✗ |
| 59 | ✗ |
| 60 | ✗ |
| 61 | ✗ |

| | |
|---|---|
| 62 | ✓ |
| 63 | ✗ |
| 64 | ✗ |
| 65 | ✓ |
| 66 | ✗ |
| 67 | ✗ |
| 68 | ✗ |
| 69 | ✓ |
| 70 | ✓ |
| 71 | ✗ |
| 72 | ✗ |
| 73 | ✗ |
| 74 | ✓ |
| 75 | ✗ |
| 76 | ✗ |
| 77 | ✗ |
| 78 | ✗ |
| 79 | - |
| 80 | ✓ |
| 81 | ✗ |
| 82 | ✗ |
| 83 | ✗ |
| 84 | ✗ |
| 85 | ✗ |
| 86 | ✗ |
| 87 | ✗ |
| 88 | ✓ |
| 89 | ✓ |
| 90 | ✗ |
| 91 | ✗ |
| **92** | ✗ |
| 93 | ✗ |
| 94 | ✓ |
| 95 | ✗ |
| 96 | ✗ |
| 97 | ✗ |

| | |
|---|---|
| 98 | ✗ |
| 99 | ✓ |
| 100 | ✗ |
| 101 | ✗ |

All contents of this site are © 2024 Passmedicine Limited

A 33-year-old lady in her third trimester of her first pregnancy comes to see you regarding a rash she has developed. It started over her abdomen but has now spread over her upper thighs and buttocks. You examine her and see the rash is erythematous, and there are small papules evident which have coalesced into patches in some areas. Around her abdomen, the rash is most marked in areas related to her stretchmarks and around the umbilicus seems to be spared; there are no blisters evident. What is the most likely diagnosis?

- Polymorphic eruption of pregnancy
- Atopic eruption of pregnancy
- Pemphigoid gestationis
- Psoriasis
- Obstetric cholestasis

Submit answer

Reference ranges

Score: **14%**

| | |
|---|---|
| 1 | ✗ |
| 2 | ✗ |
| 3 | ✓ |
| 4 | ✗ |
| 5 | ✗ |
| 6 | ✗ |
| 7 | ✗ |
| 8 | ✗ |

9 ✗
10 ✗
11 ✓
12 ✗
13 ✓
14 ✗
15 ✗
16 ✗
17 ✗
18 ✗
19 ✗
20 ✗
21 ✗
22 ✗
23 ✗
24 ✗
25 ✗
26 ✓
27 ✗
28 ✗
29 ✗
30 ✗
31 ✗
32 ✓
33 ✗
34 ✗
35 ✗
36 ✗
37 ✗
38 ✗
39 ✗
40 ✗
41 ✗
42 ✗
43 ✗
44 ✓

| | |
|---|---|
| 45 | ✗ |
| 46 | ✗ |
| 47 | ✓ |
| 48 | ✗ |
| 49 | ✗ |
| 50 | ✗ |
| 51 | - |
| 52 | - |
| 53 | - |
| 54 | - |
| 55 | - |
| 56 | - |
| 57 | - |
| 58 | - |
| 59 | - |
| 60 | - |
| 61 | - |
| 62 | - |
| 63 | - |
| 64 | - |
| 65 | - |
| 66 | - |
| 67 | - |
| 68 | - |
| 69 | - |
| 70 | - |
| 71 | - |
| 72 | - |
| 73 | - |
| 74 | - |
| 75 | - |
| 76 | - |
| 77 | - |
| 78 | - |
| 79 | - |
| 80 | - |
| 81 | - |
| 82 | - |
| 83 | - |

84 -
85 -
86 -
87 -
88 -
89 -
90 -
91 -
92 -
**93** -
94 -

All contents of this site are © 2024 Passmedicine Limited

A 33-year-old lady in her third trimester of her first pregnancy comes to see you regarding a rash she has developed. It started over her abdomen but has now spread over her upper thighs and buttocks. You examine her and see the rash is erythematous, and there are small papules evident which have coalesced into patches in some areas. Around her abdomen, the rash is most marked in areas related to her stretchmarks and around the umbilicus seems to be spared; there are no blisters evident. What is the most likely diagnosis?

- Polymorphic eruption of pregnancy 84%
- Atopic eruption of pregnancy 4%
- Pemphigoid gestationis 12%
- Psoriasis 0%
- Obstetric cholestasis 1%

The answer here is the polymorphic eruption of pregnancy. This is a condition usually occurs in the third trimester, often only in a first pregnancy, and typically there are pruritic urticarial papules that coalesce into plaques. These often start on the abdomen, particularly related to striae but may also extend elsewhere. Around the umbilicus is typically spared.
Atopic eruption of pregnancy is most common in patients that have eczema. It is most common in the first trimester and it is typically eczematous lesions that break out, unlike in this case.
Pemphigoid gestationis is not the answer as it is a very rare condition that is characterised by initial erythematous urticarial papules that progress to form bullae especially over the abdomen.
Obstetric cholestasis is not associated with a rash so this is unlikely. The history and lesions are not typical of psoriasis so this is not the diagnosis here.

Discuss (2) Improve

Next question

## Skin disorders associated with pregnancy

Atopic eruption of pregnancy

- is the commonest skin disorder found in pregnancy
- it typically presents as an eczematous, itchy red rash.
- no specific treatment is needed

Polymorphic eruption of pregnancy

- pruritic condition associated with last trimester
- lesions often first appear in abdominal striae
- management depends on severity: emollients, mild potency topical steroids and oral steroids may be used

© Image used on license from DermNet NZ

Polymorphic eruption of pregnancy

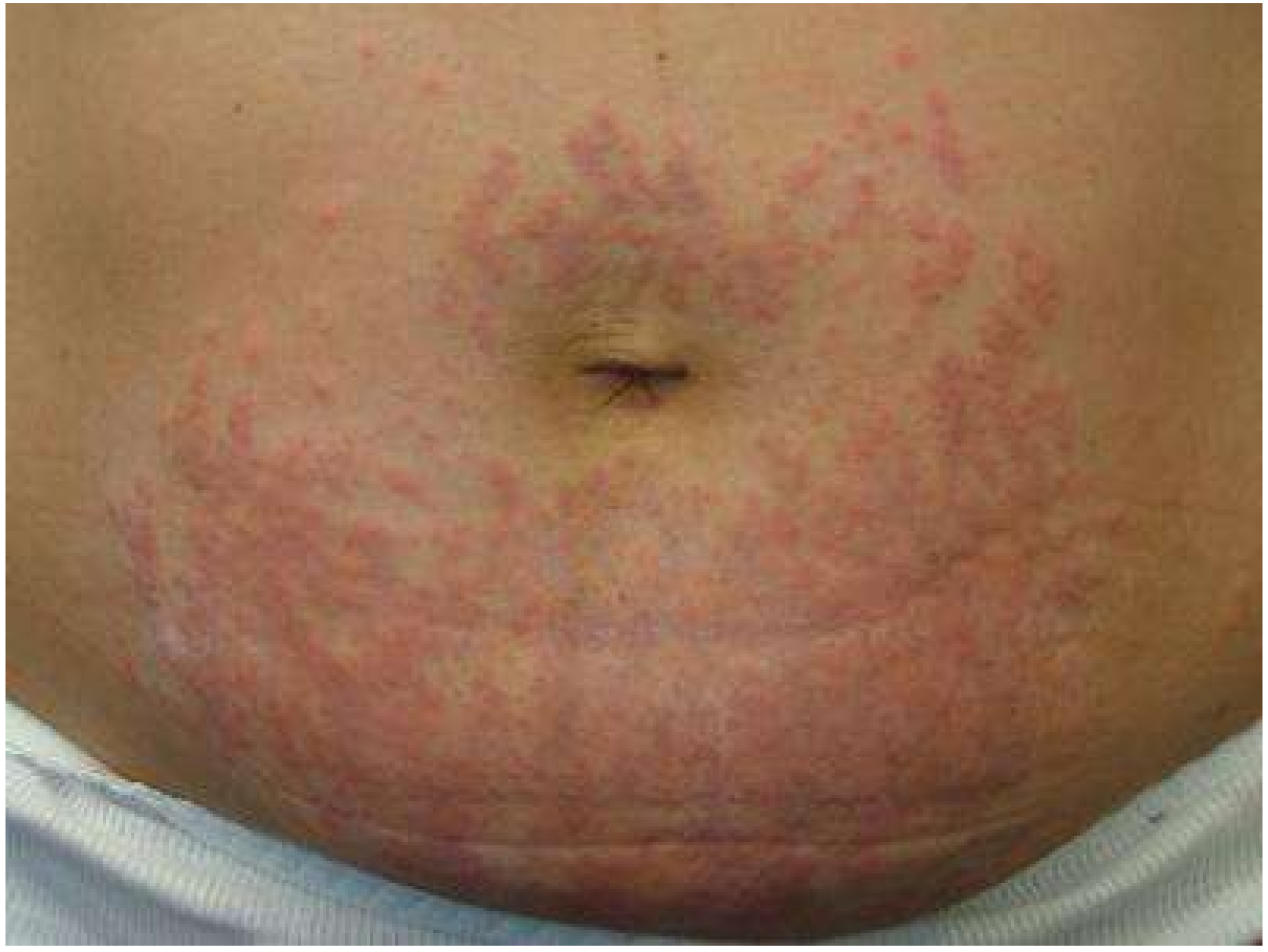

© Image used on license from DermNet NZ

Polymorphic eruption of pregnancy

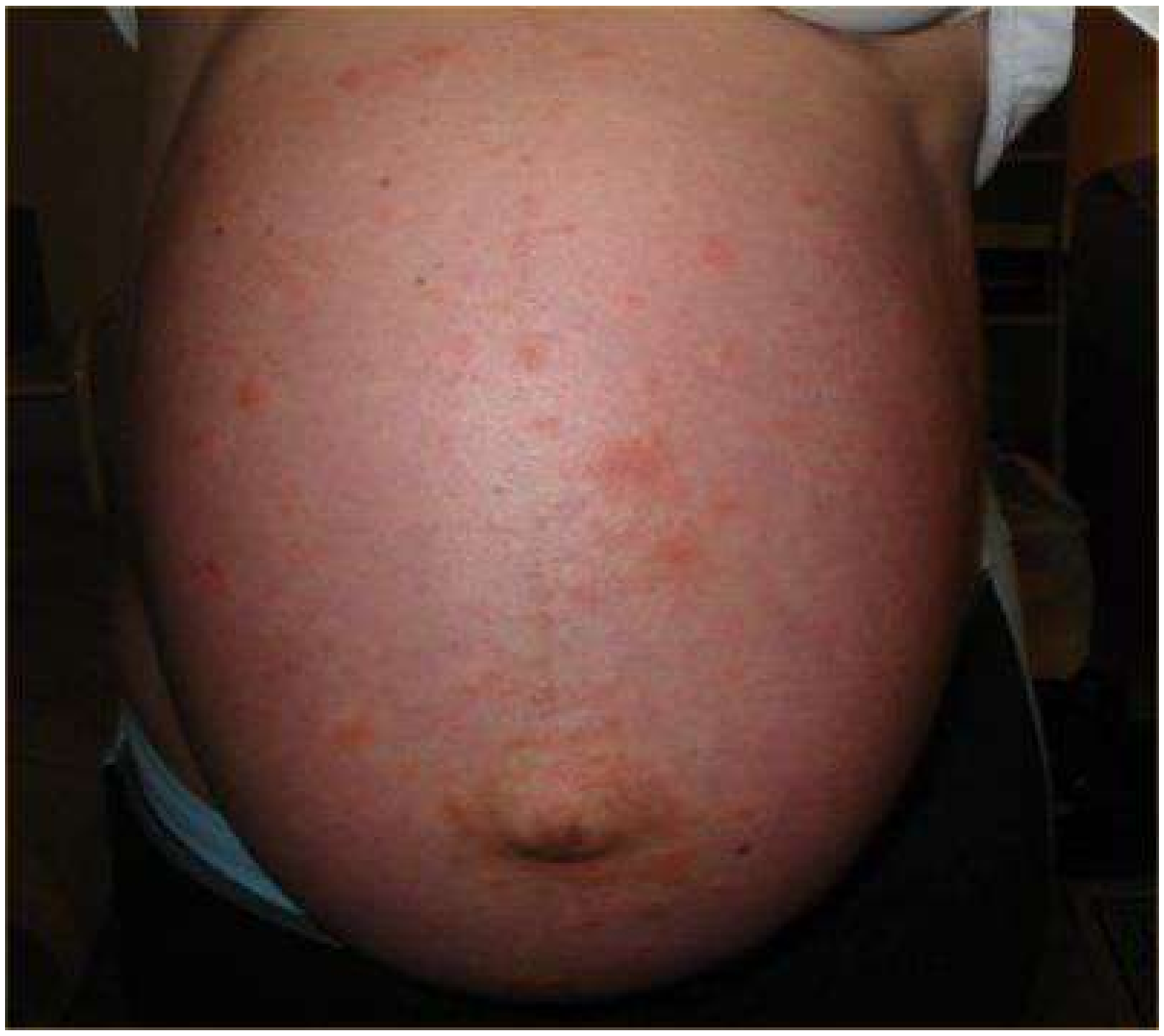

Polymorphic eruption of pregnancy

Pemphigoid gestationis

- pruritic blistering lesions
- often develop in peri-umbilical region, later spreading to the trunk, back, buttocks and arms
- usually presents 2nd or 3rd trimester and is rarely seen in the first pregnancy
- oral corticosteroids are usually required

© Image used on license from DermNet NZ

Pemphigoid gestationis

© Image used on license from DermNet NZ

Pemphigoid gestationis

123

Next question

## Textbooks

High-yield textbook

Extended textbook

## Links

DermNet NZ 13 5

Pemphigoid gestationis

DermNet NZ 11 4

Polymorphic eruption of pregnancy

Suggest link Report broken link

Score: **17%**

| | |
|---|---|
| 1 | ✗ |
| 2 | ✗ |
| 3 | ✓ |
| 4 | ✗ |
| 5 | ✗ |
| 6 | ✗ |
| 7 | ✗ |
| 8 | ✗ |
| 9 | ✗ |
| 10 | ✗ |
| 11 | ✓ |
| 12 | ✗ |
| 13 | ✓ |
| 14 | ✗ |
| 15 | ✗ |

| | |
|---|---|
| 16 | ✗ |
| 17 | ✗ |
| 18 | ✗ |
| 19 | ✗ |
| 20 | ✗ |
| 21 | ✗ |
| 22 | ✗ |
| 23 | ✗ |
| 24 | ✗ |
| 25 | ✗ |
| 26 | ✓ |
| 27 | ✗ |
| 28 | ✗ |
| 29 | ✗ |
| 30 | ✗ |
| 31 | ✗ |
| 32 | ✓ |
| 33 | ✗ |
| 34 | ✗ |
| 35 | ✗ |
| 36 | ✗ |
| 37 | ✗ |
| 38 | ✗ |
| 39 | ✗ |
| 40 | ✗ |
| 41 | ✗ |
| 42 | ✗ |
| 43 | ✗ |
| 44 | ✓ |
| 45 | ✗ |
| 46 | ✗ |
| 47 | ✓ |
| 48 | ✗ |
| 49 | ✗ |
| 50 | ✗ |
| 51 | ✗ |

| | |
|---|---|
| 52 | ✗ |
| 53 | ✗ |
| 54 | ✗ |
| 55 | ✗ |
| 56 | ✗ |
| 57 | ✗ |
| 58 | ✗ |
| 59 | ✗ |
| 60 | ✗ |
| 61 | ✗ |
| 62 | ✓ |
| 63 | ✗ |
| 64 | ✗ |
| 65 | ✓ |
| 66 | ✗ |
| 67 | ✗ |
| 68 | ✗ |
| 69 | ✓ |
| 70 | ✓ |
| 71 | ✗ |
| 72 | ✗ |
| 73 | ✗ |
| 74 | ✓ |
| 75 | ✗ |
| 76 | ✗ |
| 77 | ✗ |
| 78 | ✗ |
| 79 | - |
| 80 | ✓ |
| 81 | ✗ |
| 82 | ✗ |
| 83 | ✗ |
| 84 | ✗ |
| 85 | ✗ |
| 86 | ✗ |
| 87 | ✗ |

88 ✓
89 ✓
90 ✗
91 ✗
92 ✗
**93** ✗
94 ✓
95 ✗
96 ✗
97 ✗
98 ✗
99 ✓
100 ✗
101 ✗

All contents of this site are © 2024 Passmedicine Limited

A 65-year-old Caucasian lady presents with a new skin lesion to the forearm which has been present for 4 weeks. She reports she first noticed it after sustaining a minor abrasion to the area, and it has quickly increased in size since. On examination, there is a 10mm raised, symmetrical nodular lesion, which has a large keratinised central core. The surrounding skin appears normal, with no other similar lesions. What is the most likely diagnosis?

- Basal cell carcinoma
- Actinic keratosis
- Pyogenic granuloma
- Molluscum contagiosum
- Keratoacanthoma

Submit answer

Reference ranges

Score: **14%**

| | |
|---|---|
| 1 | ✗ |
| 2 | ✗ |
| 3 | ✓ |
| 4 | ✗ |
| 5 | ✗ |
| 6 | ✗ |
| 7 | ✗ |
| 8 | ✗ |
| 9 | ✗ |

| | |
|---|---|
| 10 | ✗ |
| 11 | ✓ |
| 12 | ✗ |
| 13 | ✓ |
| 14 | ✗ |
| 15 | ✗ |
| 16 | ✗ |
| 17 | ✗ |
| 18 | ✗ |
| 19 | ✗ |
| 20 | ✗ |
| 21 | ✗ |
| 22 | ✗ |
| 23 | ✗ |
| 24 | ✗ |
| 25 | ✗ |
| 26 | ✓ |
| 27 | ✗ |
| 28 | ✗ |
| 29 | ✗ |
| 30 | ✗ |
| 31 | ✗ |
| 32 | ✓ |
| 33 | ✗ |
| 34 | ✗ |
| 35 | ✗ |
| 36 | ✗ |
| 37 | ✗ |
| 38 | ✗ |
| 39 | ✗ |
| 40 | ✗ |
| 41 | ✗ |
| 42 | ✗ |
| 43 | ✗ |
| 44 | ✓ |
| 45 | ✗ |

| | |
|---|---|
| 46 | ✗ |
| 47 | ✓ |
| 48 | ✗ |
| 49 | ✗ |
| 50 | ✗ |
| 51 | - |
| 52 | - |
| 53 | - |
| 54 | - |
| 55 | - |
| 56 | - |
| 57 | - |
| 58 | - |
| 59 | - |
| 60 | - |
| 61 | - |
| 62 | - |
| 63 | - |
| 64 | - |
| 65 | - |
| 66 | - |
| 67 | - |
| 68 | - |
| 69 | - |
| 70 | - |
| 71 | - |
| 72 | - |
| 73 | - |
| 74 | - |
| 75 | - |
| 76 | - |
| 77 | - |
| 78 | - |
| 79 | - |
| 80 | - |
| 81 | - |
| 82 | - |
| 83 | - |
| 84 | - |
| 85 | - |

86 -
87 -
88 -
89 -
90 -
91 -
92 -
93 -
**94** -

All contents of this site are © 2024 Passmedicine Limited

Back to top

A 65-year-old Caucasian lady presents with a new skin lesion to the forearm which has been present for 4 weeks. She reports she first noticed it after sustaining a minor abrasion to the area, and it has quickly increased in size since. On examination, there is a 10mm raised, symmetrical nodular lesion, which has a large keratinised central core. The surrounding skin appears normal, with no other similar lesions. What is the most likely diagnosis?

| | |
|---|---|
| Basal cell carcinoma | 4% |
| Actinic keratosis | 8% |
| Pyogenic granuloma | 23% |
| Molluscum contagiosum | 3% |
| Keratoacanthoma | 62% |

Keratoacanthoma are fast-growing skin lesions which may appear in areas of sun damaged skin. They may also develop after a minor skin injury. They typically start as a small, round fleshy nodule before developing a keratinised central core. Though they may spontaneously regress, they are difficult to distinguish clinically from a squamous cell carcinoma, and therefore should be referred for surgical removal.

Basal cell carcinomas tend to be slow growing lesions. Actinic keratoses tend to be scaly plaques. Pyogenic granuloma is another fast growing lesion which occur at the site of minor skin injury, but are vascular, bleeding easily. Molluscum contagiosum are round lesions with a small central punctum caused by a pox virus that tend to appear in crops, mainly in children.

Discuss (3) Improve

Next question

# Keratoacanthoma

Keratoacanthoma is a benign epithelial tumour. They are more common with advancing age and rare in young people.

Features - said to look like a volcano or crater

- initially a smooth dome-shaped papule
- rapidly grows to become a crater centrally-filled with keratin

Spontaneous regression of keratoacanthoma within 3 months is common, often resulting in a scar. Such lesions should however be urgently excised as it is difficult clinically to exclude squamous cell carcinoma. Removal also may prevent scarring.

123

Next question

## Textbooks

High-yield textbook

Extended textbook

## Links

DermNet NZ 13 5

Keratoacanthoma pictures

Suggest link Report broken link

Score: **17%**

| | |
|---|---|
| 1 | ✗ |
| 2 | ✗ |
| 3 | ✓ |
| 4 | ✗ |
| 5 | ✗ |
| 6 | ✗ |
| 7 | ✗ |
| 8 | ✗ |
| 9 | ✗ |
| 10 | ✗ |
| 11 | ✓ |
| 12 | ✗ |
| 13 | ✓ |
| 14 | ✗ |
| 15 | ✗ |
| 16 | ✗ |
| 17 | ✗ |
| 18 | ✗ |
| 19 | ✗ |
| 20 | ✗ |
| 21 | ✗ |
| 22 | ✗ |
| 23 | ✗ |
| 24 | ✗ |
| 25 | ✗ |
| 26 | ✓ |
| 27 | ✗ |
| 28 | ✗ |
| 29 | ✗ |
| 30 | ✗ |
| 31 | ✗ |
| 32 | ✓ |

33 ✗
34 ✗
35 ✗
36 ✗
37 ✗
38 ✗
39 ✗
40 ✗
41 ✗
42 ✗
43 ✗
44 ✓
45 ✗
46 ✗
47 ✓
48 ✗
49 ✗
50 ✗
51 ✗
52 ✗
53 ✗
54 ✗
55 ✗
56 ✗
57 ✗
58 ✗
59 ✗
60 ✗
61 ✗
62 ✓
63 ✗
64 ✗
65 ✓
66 ✗
67 ✗
68 ✗

| | |
|---|---|
| 69 | ✓ |
| 70 | ✓ |
| 71 | ✗ |
| 72 | ✗ |
| 73 | ✗ |
| 74 | ✓ |
| 75 | ✗ |
| 76 | ✗ |
| 77 | ✗ |
| 78 | ✗ |
| 79 | - |
| 80 | ✓ |
| 81 | ✗ |
| 82 | ✗ |
| 83 | ✗ |
| 84 | ✗ |
| 85 | ✗ |
| 86 | ✗ |
| 87 | ✗ |
| 88 | ✓ |
| 89 | ✓ |
| 90 | ✗ |
| 91 | ✗ |
| 92 | ✗ |
| 93 | ✗ |
| **94** | ✓ |
| 95 | ✗ |
| 96 | ✗ |
| 97 | ✗ |
| 98 | ✗ |
| 99 | ✓ |
| 100 | ✗ |
| 101 | ✗ |

All contents of this site are © 2024 Passmedicine Limited

Back to top

A 47-year-old woman complains of an itchy neck and scalp:

© Image used on license from DermNet NZ

This skin condition is though to occur as a result of a reaction to:

- Trichophyton rubrum
- Trichophyton schoenleinii
- Microsporum audouinii
- *Candida albicans*
- Malassezia furfur

Submit answer

Reference ranges

Score: **14%**

| | |
|---|---|
| 1 | ✗ |
| 2 | ✗ |
| 3 | ✓ |
| 4 | ✗ |
| 5 | ✗ |
| 6 | ✗ |
| 7 | ✗ |
| 8 | ✗ |
| 9 | ✗ |
| 10 | ✗ |
| 11 | ✓ |
| 12 | ✗ |
| 13 | ✓ |
| 14 | ✗ |
| 15 | ✗ |
| 16 | ✗ |
| 17 | ✗ |
| 18 | ✗ |
| 19 | ✗ |
| 20 | ✗ |
| 21 | ✗ |
| 22 | ✗ |
| 23 | ✗ |
| 24 | ✗ |
| 25 | ✗ |
| 26 | ✓ |
| 27 | ✗ |
| 28 | ✗ |
| 29 | ✗ |
| 30 | ✗ |
| 31 | ✗ |
| 32 | ✓ |
| 33 | ✗ |
| 34 | ✗ |

| | |
|---|---|
| 35 | ✗ |
| 36 | ✗ |
| 37 | ✗ |
| 38 | ✗ |
| 39 | ✗ |
| 40 | ✗ |
| 41 | ✗ |
| 42 | ✗ |
| 43 | ✗ |
| 44 | ✓ |
| 45 | ✗ |
| 46 | ✗ |
| 47 | ✓ |
| 48 | ✗ |
| 49 | ✗ |
| 50 | ✗ |
| 51 | - |
| 52 | - |
| 53 | - |
| 54 | - |
| 55 | - |
| 56 | - |
| 57 | - |
| 58 | - |
| 59 | - |
| 60 | - |
| 61 | - |
| 62 | - |
| 63 | - |
| 64 | - |
| 65 | - |
| 66 | - |
| 67 | - |
| 68 | - |
| 69 | - |
| 70 | - |
| 71 | - |
| 72 | - |

| | |
|---|---|
| 73 | - |
| 74 | - |
| 75 | - |
| 76 | - |
| 77 | - |
| 78 | - |
| 79 | - |
| 80 | - |
| 81 | - |
| 82 | - |
| 83 | - |
| 84 | - |
| 85 | - |
| 86 | - |
| 87 | - |
| 88 | - |
| 89 | - |
| 90 | - |
| 91 | - |
| 92 | - |
| 93 | - |
| 94 | - |
| **95** | - |

All contents of this site are © 2024 Passmedicine Limited
Back to top

A 47-year-old woman complains of an itchy neck and scalp:

© Image used on license from DermNet NZ

This skin condition is though to occur as a result of a reaction to:

| | |
|---|---|
| Trichophyton rubrum | 23% |
| Trichophyton schoenleinii | 9% |
| Microsporum audouinii | 5% |
| *Candida albicans* | 1% |
| Malassezia furfur | 62% |

Seborrhoeic dermatitis - an inflammatory reaction to *Malassezia furfur*

Important for me Less important

The correct answer to this question is ***Malassezia furfur***. This yeast-like fungus is a part of the normal skin flora but can overgrow in certain conditions, leading to various skin diseases including Pityriasis versicolor, seborrheic dermatitis and dandruff. The image provided shows signs of seborrheic dermatitis on the scalp and neck which is typically associated with an overgrowth of *Malassezia furfur*. It is thought that this organism causes irritation and inflammation in susceptible individuals, leading to the characteristic flaky, itchy skin.

The other options listed are all organisms that can cause skin infections, but they are not typically associated with the symptoms and presentation described in the question.

***Trichophyton rubrum*** is a dermatophyte fungus that causes athlete's foot (tinea pedis), jock itch (tinea cruris) and ringworm (tinea corporis). These conditions present with a well-defined red, scaly rash often accompanied by itching. However, these rashes usually appear on the feet, groin or body rather than the scalp or neck.

***Trichophyton schoenleinii*** is another dermatophyte fungus, which primarily causes tinea capitis (scalp ringworm). While this condition does affect the scalp, it presents differently from seborrheic dermatitis. Tinea capitis typically causes patchy hair loss and a scaly scalp rather than generalised itching and flaking.

***Microsporum audouinii***, also a cause of tinea capitis, would similarly result in patchy hair loss rather than widespread itching and flaking. It's important to note that while both *T. schoenleinii* and *M. audouinii* can cause scalp infections, they are more commonly seen in children rather than adults.

Finally, ***Candida albicans***, a type of yeast fungus, can cause various infections including oral thrush and vaginal yeast infections. While it can affect the skin causing candidal intertrigo or diaper rash for example; it's less likely to be responsible for an itchy neck and scalp as described in this scenario.

Discuss (3) | Improve

Next question

## Seborrhoeic dermatitis in adults

Seborrhoeic dermatitis in adults is a chronic dermatitis thought to be caused by an inflammatory reaction related to a proliferation of a normal skin inhabitant, a fungus called *Malassezia furfur* (formerly known as *Pityrosporum ovale*). It is common, affecting around 2% of the general population.

Features

- eczematous lesions on the sebum-rich areas: scalp (may cause dandruff), periorbital, auricular and nasolabial folds
- otitis externa and blepharitis may develop

Associated conditions include

- HIV
- Parkinson's disease

Scalp disease management

- the first-line treatment is ketoconazole 2% shampoo
- over the counter preparations containing zinc pyrithione ('Head & Shoulders') and tar ('Neutrogena T/Gel') may be used if ketoconazole is not appropriate or acceptable to the person
- selenium sulphide and topical corticosteroid may also be useful

Face and body management

- topical antifungals: e.g. ketoconazole
- topical steroids: best used for short periods
- difficult to treat - recurrences are common

123

Next question

**Textbooks**

High-yield textbook

Extended textbook

**Links**

Clinical Knowledge Summaries 20 11

Seborrhoeic dermatitis guidelines

DermNet NZ 24 4

Overview and pictures of seborrhoeic dermatitis

Suggest link

Report broken link

Score: **17%**

| | |
|---|---|
| 1 | ✗ |
| 2 | ✗ |
| 3 | ✓ |
| 4 | ✗ |
| 5 | ✗ |
| 6 | ✗ |
| 7 | ✗ |
| 8 | ✗ |
| 9 | ✗ |
| 10 | ✗ |
| 11 | ✓ |
| 12 | ✗ |
| 13 | ✓ |
| 14 | ✗ |
| 15 | ✗ |
| 16 | ✗ |
| 17 | ✗ |
| 18 | ✗ |
| 19 | ✗ |
| 20 | ✗ |
| 21 | ✗ |

| | |
|---|---|
| 22 | ✗ |
| 23 | ✗ |
| 24 | ✗ |
| 25 | ✗ |
| 26 | ✓ |
| 27 | ✗ |
| 28 | ✗ |
| 29 | ✗ |
| 30 | ✗ |
| 31 | ✗ |
| 32 | ✓ |
| 33 | ✗ |
| 34 | ✗ |
| 35 | ✗ |
| 36 | ✗ |
| 37 | ✗ |
| 38 | ✗ |
| 39 | ✗ |
| 40 | ✗ |
| 41 | ✗ |
| 42 | ✗ |
| 43 | ✗ |
| 44 | ✓ |
| 45 | ✗ |
| 46 | ✗ |
| 47 | ✓ |
| 48 | ✗ |
| 49 | ✗ |
| 50 | ✗ |
| 51 | ✗ |
| 52 | ✗ |
| 53 | ✗ |
| 54 | ✗ |
| 55 | ✗ |
| 56 | ✗ |
| 57 | ✗ |

| | |
|---|---|
| 58 | ✗ |
| 59 | ✗ |
| 60 | ✗ |
| 61 | ✗ |
| 62 | ✓ |
| 63 | ✗ |
| 64 | ✗ |
| 65 | ✓ |
| 66 | ✗ |
| 67 | ✗ |
| 68 | ✗ |
| 69 | ✓ |
| 70 | ✓ |
| 71 | ✗ |
| 72 | ✗ |
| 73 | ✗ |
| 74 | ✓ |
| 75 | ✗ |
| 76 | ✗ |
| 77 | ✗ |
| 78 | ✗ |
| 79 | - |
| 80 | ✓ |
| 81 | ✗ |
| 82 | ✗ |
| 83 | ✗ |
| 84 | ✗ |
| 85 | ✗ |
| 86 | ✗ |
| 87 | ✗ |
| 88 | ✓ |
| 89 | ✓ |
| 90 | ✗ |
| 91 | ✗ |
| 92 | ✗ |
| 93 | ✗ |

| | |
|---|---|
| 94 | ✓ |
| **95** | ✗ |
| 96 | ✗ |
| 97 | ✗ |
| 98 | ✗ |
| 99 | ✓ |
| 100 | ✗ |
| 101 | ✗ |

All contents of this site are © 2024 Passmedicine Limited

Back to top

A 33-year-old woman asks you to look at a 'spot' on her arm that has been present for several months. It has not changed recently and is completely asymptomatic.

© Image used on license from DermNet NZ

What is the most likely diagnosis?

- Leiomyoma
- Basal cell carcinoma
- Amelanotic malignant melanoma
- Dermatofibroma
- Nodular prurigo

Submit answer

Reference ranges

Score: **14%**

| | |
|---|---|
| 1 | ✗ |
| 2 | ✗ |
| 3 | ✓ |
| 4 | ✗ |
| 5 | ✗ |
| 6 | ✗ |
| 7 | ✗ |
| 8 | ✗ |
| 9 | ✗ |
| 10 | ✗ |
| 11 | ✓ |
| 12 | ✗ |
| 13 | ✓ |
| 14 | ✗ |
| 15 | ✗ |
| 16 | ✗ |
| 17 | ✗ |
| 18 | ✗ |
| 19 | ✗ |
| 20 | ✗ |
| 21 | ✗ |
| 22 | ✗ |
| 23 | ✗ |
| 24 | ✗ |
| 25 | ✗ |
| 26 | ✓ |
| 27 | ✗ |
| 28 | ✗ |
| 29 | ✗ |
| 30 | ✗ |
| 31 | ✗ |
| 32 | ✓ |
| 33 | ✗ |

| | |
|---|---|
| 34 | ✗ |
| 35 | ✗ |
| 36 | ✗ |
| 37 | ✗ |
| 38 | ✗ |
| 39 | ✗ |
| 40 | ✗ |
| 41 | ✗ |
| 42 | ✗ |
| 43 | ✗ |
| 44 | ✓ |
| 45 | ✗ |
| 46 | ✗ |
| 47 | ✓ |
| 48 | ✗ |
| 49 | ✗ |
| 50 | ✗ |
| 51 | - |
| 52 | - |
| 53 | - |
| 54 | - |
| 55 | - |
| 56 | - |
| 57 | - |
| 58 | - |
| 59 | - |
| 60 | - |
| 61 | - |
| 62 | - |
| 63 | - |
| 64 | - |
| 65 | - |
| 66 | - |
| 67 | - |
| 68 | - |
| 69 | - |
| 70 | - |
| 71 | - |

72 -
73 -
74 -
75 -
76 -
77 -
78 -
79 -
80 -
81 -
82 -
83 -
84 -
85 -
86 -
87 -
88 -
89 -
90 -
91 -
92 -
93 -
94 -
95 -
**96** -

All contents of this site are © 2024 Passmedicine Limited
Back to top

A 33-year-old woman asks you to look at a 'spot' on her arm that has been present for several months. It has not changed recently and is completely asymptomatic.

© Image used on license from DermNet NZ

What is the most likely diagnosis?

| | |
|---|---|
| Leiomyoma | 5% |
| Basal cell carcinoma | 6% |
| Amelanotic malignant melanoma | 6% |
| Dermatofibroma | 72% |
| Nodular prurigo | 11% |

The most likely diagnosis for the lesion presented in the image is a **Dermatofibroma**. Dermatofibromas are common benign skin nodules that often develop after minor skin injuries. They are typically asymptomatic, firm to touch, and can be brownish or purplish in colour. The patient's history of having a 'spot' on her arm for several months without any changes or symptoms is consistent with this diagnosis.

The first option, a **Leiomyoma**, is less likely as these are smooth muscle tumours that usually present as painful lesions when exposed to cold or pressure, which does not match the patient's

presentation of an asymptomatic lesion.

The second option, a **Basal cell carcinoma**, is also unlikely. Although it is one of the most common forms of skin cancer, it usually presents as a pearly nodule with telangiectasia (visible blood vessels) on sun-exposed areas. It may ulcerate and bleed but rarely metastasises. This does not fit with the clinical picture described here.

An **Amelanotic malignant melanoma**, the third option, is a type of skin cancer that lacks pigment. While it can appear similar to the lesion in question, amelanotic melanomas tend to change rapidly over weeks to months and may have irregular borders and surface characteristics. Given this woman's stable lesion over several months without any symptoms, an amelanotic melanoma seems unlikely.

Finally, **Nodular prurigo** could present as multiple intensely itchy nodules predominantly found on extensor surfaces such as arms and legs. However, given that this woman has no mention of itchiness or multiple lesions, nodular prurigo would be an unlikely diagnosis for her condition.

Discuss | Improve

Next question

## Dermatofibroma

Dermatofibromas (also known as histiocytomas) are common benign fibrous skin lesions. They are caused by the abnormal growth of dermal dendritic histiocyte cells, often following a precipitating injury. Common areas include the arms and legs.

Features
- solitary firm papule or nodule, typically on a limb
- typically around 5-10mm in size
- overlying skin dimples on pinching the lesion

123

Next question

**Textbooks**

High-yield textbook

Extended textbook

Score: **17%**

| | |
|---|---|
| 1 | ✗ |
| 2 | ✗ |
| 3 | ✓ |
| 4 | ✗ |
| 5 | ✗ |
| 6 | ✗ |
| 7 | ✗ |
| 8 | ✗ |
| 9 | ✗ |
| 10 | ✗ |
| 11 | ✓ |
| 12 | ✗ |
| 13 | ✓ |
| 14 | ✗ |
| 15 | ✗ |
| 16 | ✗ |
| 17 | ✗ |

| | |
|---|---|
| 18 | ✗ |
| 19 | ✗ |
| 20 | ✗ |
| 21 | ✗ |
| 22 | ✗ |
| 23 | ✗ |
| 24 | ✗ |
| 25 | ✗ |
| 26 | ✓ |
| 27 | ✗ |
| 28 | ✗ |
| 29 | ✗ |
| 30 | ✗ |
| 31 | ✗ |
| 32 | ✓ |
| 33 | ✗ |
| 34 | ✗ |
| 35 | ✗ |
| 36 | ✗ |
| 37 | ✗ |
| 38 | ✗ |
| 39 | ✗ |
| 40 | ✗ |
| 41 | ✗ |
| 42 | ✗ |
| 43 | ✗ |
| 44 | ✓ |
| 45 | ✗ |
| 46 | ✗ |
| 47 | ✓ |
| 48 | ✗ |
| 49 | ✗ |
| 50 | ✗ |
| 51 | ✗ |
| 52 | ✗ |
| 53 | ✗ |

| | |
|---|---|
| 54 | ✗ |
| 55 | ✗ |
| 56 | ✗ |
| 57 | ✗ |
| 58 | ✗ |
| 59 | ✗ |
| 60 | ✗ |
| 61 | ✗ |
| 62 | ✓ |
| 63 | ✗ |
| 64 | ✗ |
| 65 | ✓ |
| 66 | ✗ |
| 67 | ✗ |
| 68 | ✗ |
| 69 | ✓ |
| 70 | ✓ |
| 71 | ✗ |
| 72 | ✗ |
| 73 | ✗ |
| 74 | ✓ |
| 75 | ✗ |
| 76 | ✗ |
| 77 | ✗ |
| 78 | ✗ |
| 79 | - |
| 80 | ✓ |
| 81 | ✗ |
| 82 | ✗ |
| 83 | ✗ |
| 84 | ✗ |
| 85 | ✗ |
| 86 | ✗ |
| 87 | ✗ |
| 88 | ✓ |
| 89 | ✓ |

90 ✗
91 ✗
92 ✗
93 ✗
94 ✓
95 ✗
**96** ✗
97 ✗
98 ✗
99 ✓
100 ✗
101 ✗

All contents of this site are © 2024 Passmedicine Limited

Back to top

A 62-year-old man presents with a lesion on the right side of his nose. He is unsure how long it has been there.

What is the most likely diagnosis?

- Desmoplastic trichoepithelioma
- Squamous cell carcinoma
- Impetigo
- Basal cell carcinoma
- Actinic keratosis

Submit answer

Reference ranges

Score: **14%**

| | |
|---|---|
| 1 | ✗ |
| 2 | ✗ |
| 3 | ✓ |
| 4 | ✗ |
| 5 | ✗ |
| 6 | ✗ |
| 7 | ✗ |
| 8 | ✗ |
| 9 | ✗ |
| 10 | ✗ |
| 11 | ✓ |
| 12 | ✗ |
| 13 | ✓ |
| 14 | ✗ |
| 15 | ✗ |
| 16 | ✗ |
| 17 | ✗ |
| 18 | ✗ |
| 19 | ✗ |
| 20 | ✗ |
| 21 | ✗ |
| 22 | ✗ |
| 23 | ✗ |
| 24 | ✗ |
| 25 | ✗ |
| 26 | ✓ |
| 27 | ✗ |
| 28 | ✗ |
| 29 | ✗ |
| 30 | ✗ |
| 31 | ✗ |
| 32 | ✓ |
| 33 | ✗ |
| 34 | ✗ |

| | |
|---|---|
| 35 | ✗ |
| 36 | ✗ |
| 37 | ✗ |
| 38 | ✗ |
| 39 | ✗ |
| 40 | ✗ |
| 41 | ✗ |
| 42 | ✗ |
| 43 | ✗ |
| 44 | ✓ |
| 45 | ✗ |
| 46 | ✗ |
| 47 | ✓ |
| 48 | ✗ |
| 49 | ✗ |
| 50 | ✗ |
| 51 | - |
| 52 | - |
| 53 | - |
| 54 | - |
| 55 | - |
| 56 | - |
| 57 | - |
| 58 | - |
| 59 | - |
| 60 | - |
| 61 | - |
| 62 | - |
| 63 | - |
| 64 | - |
| 65 | - |
| 66 | - |
| 67 | - |
| 68 | - |
| 69 | - |
| 70 | - |
| 71 | - |
| 72 | - |

73 -
74 -
75 -
76 -
77 -
78 -
79 -
80 -
81 -
82 -
83 -
84 -
85 -
86 -
87 -
88 -
89 -
90 -
91 -
92 -
93 -
94 -
95 -
96 -
**97** -

All contents of this site are © 2024 Passmedicine Limited
Back to top

A 62-year-old man presents with a lesion on the right side of his nose. He is unsure how long it has been there.

What is the most likely diagnosis?

- Desmoplastic trichoepithelioma 2%
- Squamous cell carcinoma 14%
- Impetigo 1%
- Basal cell carcinoma 81%
- Actinic keratosis 3%

The rolled, pearly edges with telangiectasia surrounding a central crater make basal cell carcinoma the most likely diagnosis.

# Basal cell carcinoma

Basal cell carcinoma (BCC) is one of the three main types of skin cancer. Lesions are also known as rodent ulcers and are characterised by slow-growth and local invasion. Metastases are extremely rare. BCC is the most common type of cancer in the Western world.

Features

- many types of BCC are described. The most common type is nodular BCC, which is described here
- sun-exposed sites, especially the head and neck account for the majority of lesions
- initially a pearly, flesh-coloured papule with telangiectasia
- may later ulcerate leaving a central 'crater'

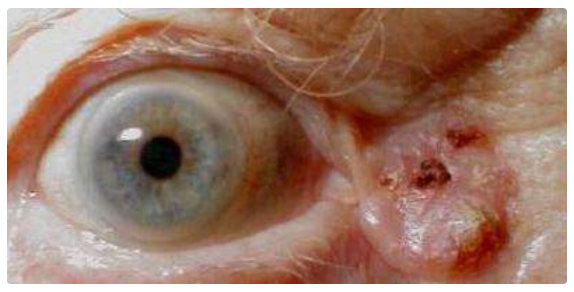

Referral

- generally, if a BCC is suspected, a routine referral should be made

Management options:

- surgical removal
- curettage
- cryotherapy
- topical cream: imiquimod, fluorouracil
- radiotherapy

AI + Q 123

Next question >

## Textbooks

High-yield textbook

Extended textbook

## Links

DermNet NZ 21 7

Basal cell carcinoma

Suggest link

Report broken link

## Media

Skin cancers

Osmosis - YouTube 4 2

Report broken media

Score: **17%**

1 ✕

| | |
|---|---|
| 2 | ✗ |
| 3 | ✓ |
| 4 | ✗ |
| 5 | ✗ |
| 6 | ✗ |
| 7 | ✗ |
| 8 | ✗ |
| 9 | ✗ |
| 10 | ✗ |
| 11 | ✓ |
| 12 | ✗ |
| 13 | ✓ |
| 14 | ✗ |
| 15 | ✗ |
| 16 | ✗ |
| 17 | ✗ |
| 18 | ✗ |
| 19 | ✗ |
| 20 | ✗ |
| 21 | ✗ |
| 22 | ✗ |
| 23 | ✗ |
| 24 | ✗ |
| 25 | ✗ |
| 26 | ✓ |
| 27 | ✗ |
| 28 | ✗ |
| 29 | ✗ |
| 30 | ✗ |
| 31 | ✗ |
| 32 | ✓ |
| 33 | ✗ |
| 34 | ✗ |
| 35 | ✗ |
| 36 | ✗ |
| 37 | ✗ |

| | |
|---|---|
| 38 | ✗ |
| 39 | ✗ |
| 40 | ✗ |
| 41 | ✗ |
| 42 | ✗ |
| 43 | ✗ |
| 44 | ✓ |
| 45 | ✗ |
| 46 | ✗ |
| 47 | ✓ |
| 48 | ✗ |
| 49 | ✗ |
| 50 | ✗ |
| 51 | ✗ |
| 52 | ✗ |
| 53 | ✗ |
| 54 | ✗ |
| 55 | ✗ |
| 56 | ✗ |
| 57 | ✗ |
| 58 | ✗ |
| 59 | ✗ |
| 60 | ✗ |
| 61 | ✗ |
| 62 | ✓ |
| 63 | ✗ |
| 64 | ✗ |
| 65 | ✓ |
| 66 | ✗ |
| 67 | ✗ |
| 68 | ✗ |
| 69 | ✓ |
| 70 | ✓ |
| 71 | ✗ |
| 72 | ✗ |
| 73 | ✗ |

| | |
|---|---|
| 74 | ✓ |
| 75 | ✗ |
| 76 | ✗ |
| 77 | ✗ |
| 78 | ✗ |
| 79 | - |
| 80 | ✓ |
| 81 | ✗ |
| 82 | ✗ |
| 83 | ✗ |
| 84 | ✗ |
| 85 | ✗ |
| 86 | ✗ |
| 87 | ✗ |
| 88 | ✓ |
| 89 | ✓ |
| 90 | ✗ |
| 91 | ✗ |
| 92 | ✗ |
| 93 | ✗ |
| 94 | ✓ |
| 95 | ✗ |
| 96 | ✗ |
| **97** | ✗ |
| 98 | ✗ |
| 99 | ✓ |
| 100 | ✗ |
| 101 | ✗ |

All contents of this site are © 2024 Passmedicine Limited

An elderly man develops a generalised pruritic rash:

© Image used on license from DermNet NZ and with the kind permission of Prof Raimo Suhonen

Which one of the following is the mainstay of treatment?

- Gluten free diet
- Phototherapy
- Oral corticosteroids
- Long-term oral antibiotics
- Potent topical corticosteroids

Submit answer

Reference ranges

Score: **14%**

| | |
|---|---|
| 1 | ✗ |
| 2 | ✗ |
| 3 | ✓ |
| 4 | ✗ |
| 5 | ✗ |
| 6 | ✗ |
| 7 | ✗ |
| 8 | ✗ |
| 9 | ✗ |
| 10 | ✗ |
| 11 | ✓ |
| 12 | ✗ |
| 13 | ✓ |
| 14 | ✗ |
| 15 | ✗ |
| 16 | ✗ |
| 17 | ✗ |
| 18 | ✗ |
| 19 | ✗ |
| 20 | ✗ |
| 21 | ✗ |
| 22 | ✗ |
| 23 | ✗ |
| 24 | ✗ |
| 25 | ✗ |
| 26 | ✓ |
| 27 | ✗ |
| 28 | ✗ |
| 29 | ✗ |
| 30 | ✗ |
| 31 | ✗ |
| 32 | ✓ |
| 33 | ✗ |
| 34 | ✗ |

| | |
|---|---|
| 35 | ✗ |
| 36 | ✗ |
| 37 | ✗ |
| 38 | ✗ |
| 39 | ✗ |
| 40 | ✗ |
| 41 | ✗ |
| 42 | ✗ |
| 43 | ✗ |
| 44 | ✓ |
| 45 | ✗ |
| 46 | ✗ |
| 47 | ✓ |
| 48 | ✗ |
| 49 | ✗ |
| 50 | ✗ |
| 51 | - |
| 52 | - |
| 53 | - |
| 54 | - |
| 55 | - |
| 56 | - |
| 57 | - |
| 58 | - |
| 59 | - |
| 60 | - |
| 61 | - |
| 62 | - |
| 63 | - |
| 64 | - |
| 65 | - |
| 66 | - |
| 67 | - |
| 68 | - |
| 69 | - |
| 70 | - |
| 71 | - |
| 72 | - |

73 -
74 -
75 -
76 -
77 -
78 -
79 -
80 -
81 -
82 -
83 -
84 -
85 -
86 -
87 -
88 -
89 -
90 -
91 -
92 -
93 -
94 -
95 -
96 -
97 -
**98** -

All contents of this site are © 2024 Passmedicine Limited
Back to top

An elderly man develops a generalised pruritic rash:

© Image used on license from DermNet NZ and with the kind permission of Prof Raimo Suhonen

Which one of the following is the mainstay of treatment?

| | |
|---|---|
| Gluten free diet | 5% |
| Phototherapy | 1% |
| Oral corticosteroids | 83% |
| Long-term oral antibiotics | 1% |
| Potent topical corticosteroids | 11% |

Discuss (2) Improve

Next question

# Bullous pemphigoid

Bullous pemphigoid is an autoimmune condition causing sub-epidermal blistering of the skin. This is secondary to the development of antibodies against hemidesmosomal proteins BP180 and BP230.

Bullous pemphigoid is more common in elderly patients. Features include

- itchy, tense blisters typically around flexures
- the blisters usually heal without scarring
- there is stereotypically no mucosal involvement (i.e. the mouth is spared)
    - in reality around 10-50% of patients have a degree of mucosal involvement. It would, however, be unusual for an exam question to mention mucosal involvement as it is seen as a classic differentiating feature between pemphigoid and pemphigus.

Skin biopsy

- immunofluorescence shows IgG and C3 at the dermoepidermal junction

Management

- referral to a dermatologist for biopsy and confirmation of diagnosis
- oral corticosteroids are the mainstay of treatment
- topical corticosteroids, immunosuppressants and antibiotics are also used

+ Q 123

Next question

## Textbooks

High-yield textbook

Extended textbook

## Links

British Association of Dermatologists 8 11

Bullous pemphigoid guidelines

DermNet NZ 15 9

Bullous pemphigoid

Suggest link Report broken link

## Media




Bullous pemphigoid

Osmosis - YouTube 5 1

Report broken media

Score: **17%**

1 ✗
2 ✗
3 ✓
4 ✗
5 ✗

| | |
|---|---|
| 6 | ✗ |
| 7 | ✗ |
| 8 | ✗ |
| 9 | ✗ |
| 10 | ✗ |
| 11 | ✓ |
| 12 | ✗ |
| 13 | ✓ |
| 14 | ✗ |
| 15 | ✗ |
| 16 | ✗ |
| 17 | ✗ |
| 18 | ✗ |
| 19 | ✗ |
| 20 | ✗ |
| 21 | ✗ |
| 22 | ✗ |
| 23 | ✗ |
| 24 | ✗ |
| 25 | ✗ |
| 26 | ✓ |
| 27 | ✗ |
| 28 | ✗ |
| 29 | ✗ |
| 30 | ✗ |
| 31 | ✗ |
| 32 | ✓ |
| 33 | ✗ |
| 34 | ✗ |
| 35 | ✗ |
| 36 | ✗ |
| 37 | ✗ |
| 38 | ✗ |
| 39 | ✗ |
| 40 | ✗ |
| 41 | ✗ |

| | |
|---|---|
| 42 | ✗ |
| 43 | ✗ |
| 44 | ✓ |
| 45 | ✗ |
| 46 | ✗ |
| 47 | ✓ |
| 48 | ✗ |
| 49 | ✗ |
| 50 | ✗ |
| 51 | ✗ |
| 52 | ✗ |
| 53 | ✗ |
| 54 | ✗ |
| 55 | ✗ |
| 56 | ✗ |
| 57 | ✗ |
| 58 | ✗ |
| 59 | ✗ |
| 60 | ✗ |
| 61 | ✗ |
| 62 | ✓ |
| 63 | ✗ |
| 64 | ✗ |
| 65 | ✓ |
| 66 | ✗ |
| 67 | ✗ |
| 68 | ✗ |
| 69 | ✓ |
| 70 | ✓ |
| 71 | ✗ |
| 72 | ✗ |
| 73 | ✗ |
| 74 | ✓ |
| 75 | ✗ |
| 76 | ✗ |
| 77 | ✗ |

| | |
|---|---|
| 78 | ✗ |
| 79 | - |
| 80 | ✓ |
| 81 | ✗ |
| 82 | ✗ |
| 83 | ✗ |
| 84 | ✗ |
| 85 | ✗ |
| 86 | ✗ |
| 87 | ✗ |
| 88 | ✓ |
| 89 | ✓ |
| 90 | ✗ |
| 91 | ✗ |
| 92 | ✗ |
| 93 | ✗ |
| 94 | ✓ |
| 95 | ✗ |
| 96 | ✗ |
| 97 | ✗ |
| **98** | ✗ |
| 99 | ✓ |
| 100 | ✗ |
| 101 | ✗ |

All contents of this site are © 2024 Passmedicine Limited

Back to top

A 59-year-old man with extensive small bowel stricturing Crohn's disease underwent a large small bowel resection. It was complicated by an anastomotic breakdown which required a further resection and jejunostomy formation. He was referred to a local intestinal failure unit and, after a period of assessment, was discharged home on parenteral nutrition. He gained weight and made good progress, although an intermittently high-output stoma persisted. When reviewed in clinic after a year on home parenteral nutrition, he complained of hair loss, a skin rash, and impairment of taste. Examination revealed a superficial scaling erythematous patchy rash that was most prominent in intertriginous areas and periorally.

Which is the most likely nutrient deficiency?

- Niacin
- Selenium
- Vitamin A
- Vitamin E
- Zinc

Submit answer

Reference ranges

Score: **14%**

| | |
|---|---|
| 1 | ✗ |
| 2 | ✗ |
| 3 | ✓ |
| 4 | ✗ |
| 5 | ✗ |

| | |
|---|---|
| 6 | ✗ |
| 7 | ✗ |
| 8 | ✗ |
| 9 | ✗ |
| 10 | ✗ |
| 11 | ✓ |
| 12 | ✗ |
| 13 | ✓ |
| 14 | ✗ |
| 15 | ✗ |
| 16 | ✗ |
| 17 | ✗ |
| 18 | ✗ |
| 19 | ✗ |
| 20 | ✗ |
| 21 | ✗ |
| 22 | ✗ |
| 23 | ✗ |
| 24 | ✗ |
| 25 | ✗ |
| 26 | ✓ |
| 27 | ✗ |
| 28 | ✗ |
| 29 | ✗ |
| 30 | ✗ |
| 31 | ✗ |
| 32 | ✓ |
| 33 | ✗ |
| 34 | ✗ |
| 35 | ✗ |
| 36 | ✗ |
| 37 | ✗ |
| 38 | ✗ |
| 39 | ✗ |
| 40 | ✗ |
| 41 | ✗ |

42 ✗
43 ✗
44 ✓
45 ✗
46 ✗
47 ✓
48 ✗
49 ✗
50 ✗
51 -
52 -
53 -
54 -
55 -
56 -
57 -
58 -
59 -
60 -
61 -
62 -
63 -
64 -
65 -
66 -
67 -
68 -
69 -
70 -
71 -
72 -
73 -
74 -
75 -
76 -
77 -
78 -
79 -
80 -

81 -
82 -
83 -
84 -
85 -
86 -
87 -
88 -
89 -
90 -
91 -
92 -
93 -
94 -
95 -
96 -
97 -
98 -
**99** -

All contents of this site are © 2024 Passmedicine Limited
Back to top

A 59-year-old man with extensive small bowel stricturing Crohn's disease underwent a large small bowel resection. It was complicated by an anastomotic breakdown which required a further resection and jejunostomy formation. He was referred to a local intestinal failure unit and, after a period of assessment, was discharged home on parenteral nutrition. He gained weight and made good progress, although an intermittently high-output stoma persisted. When reviewed in clinic after a year on home parenteral nutrition, he complained of hair loss, a skin rash, and impairment of taste. Examination revealed a superficial scaling erythematous patchy rash that was most prominent in intertriginous areas and perorally.

Which is the most likely nutrient deficiency?

| | |
|---|---|
| Niacin | 26% |
| Selenium | 8% |
| Vitamin A | 3% |
| Vitamin E | 3% |
| Zinc | 60% |

Zinc deficiency causes a characteristic skin rash (mainly at the intertriginous and perioral areas), alopecia, taste impairment, glucose intolerance, and diarrhoea

Important for me Less important

Zinc deficiency causes a characteristic skin rash (mainly affecting the intertriginous and perioral areas), alopecia, taste impairment, glucose intolerance, and diarrhoea. In addition to the above symptoms, deficiency also causes acne, visual problems, impaired ability to smell, subtle cognitive and memory changes, and increased susceptibility to respiratory infections. Secondary skin infections may develop with extensive skin rashes. Nail changes, including white spots, bands, lines, or leuconychia, may also be evident. Diarrhoea, stomal and fistula losses increase the loss of zinc.

In contrast to the other options, vitamin A deficiency causes night blindness and eventually xerophthalmia. It can also lead to impaired immune function, cancer, and birth defects. Vitamin E deficiency can lead to problems such as spinocerebellar ataxia and myopathies, and anaemia, due to oxidative damage to red blood cells. Selenium deficiency has been seen in patients with

malabsorption and in those on total parenteral nutrition. The effects include myocardial necrosis leading to congestive cardiomyopathy. There is increased susceptibility to infection and can also cause disruption of thyroid metabolism ( hypothyroidism). Niacin deficiency causes pellagra, dermatitis, alopecia, oedema, and glossitis. Psychological changes include emotional problems, aggression, insomnia, confusion, and dementia. Neurological signs include weakness, ataxia, paralysis, and peripheral neuritis. Diarrhoea and a dilated cardiomyopathy may also occur.

Discuss (3) Improve

Next question

## Zinc deficiency

Features

- acrodermatitis: red, crusted lesions
  - acral distribution
  - peri-orificial
  - perianal
- alopecia
- short stature
- hypogonadism
- hepatosplenomegaly
- geophagia (ingesting clay/soil)
- cognitive impairment

Acrodermatitis enteropathica is a recessively inherited partial defect in intestinal zinc absorption.

AI + Q 123

Next question

**Textbooks**

High-yield textbook

Extended textbook

Score: **17%**

| | |
|---|---|
| 1 | ✗ |
| 2 | ✗ |
| 3 | ✓ |
| 4 | ✗ |
| 5 | ✗ |
| 6 | ✗ |
| 7 | ✗ |
| 8 | ✗ |
| 9 | ✗ |
| 10 | ✗ |
| 11 | ✓ |
| 12 | ✗ |
| 13 | ✓ |
| 14 | ✗ |
| 15 | ✗ |
| 16 | ✗ |
| 17 | ✗ |
| 18 | ✗ |
| 19 | ✗ |
| 20 | ✗ |
| 21 | ✗ |
| 22 | ✗ |
| 23 | ✗ |
| 24 | ✗ |
| 25 | ✗ |
| 26 | ✓ |
| 27 | ✗ |

| | |
|---|---|
| 28 | ✗ |
| 29 | ✗ |
| 30 | ✗ |
| 31 | ✗ |
| 32 | ✓ |
| 33 | ✗ |
| 34 | ✗ |
| 35 | ✗ |
| 36 | ✗ |
| 37 | ✗ |
| 38 | ✗ |
| 39 | ✗ |
| 40 | ✗ |
| 41 | ✗ |
| 42 | ✗ |
| 43 | ✗ |
| 44 | ✓ |
| 45 | ✗ |
| 46 | ✗ |
| 47 | ✓ |
| 48 | ✗ |
| 49 | ✗ |
| 50 | ✗ |
| 51 | ✗ |
| 52 | ✗ |
| 53 | ✗ |
| 54 | ✗ |
| 55 | ✗ |
| 56 | ✗ |
| 57 | ✗ |
| 58 | ✗ |
| 59 | ✗ |
| 60 | ✗ |
| 61 | ✗ |
| 62 | ✓ |
| 63 | ✗ |

| | |
|---|---|
| 64 | ✗ |
| 65 | ✓ |
| 66 | ✗ |
| 67 | ✗ |
| 68 | ✗ |
| 69 | ✓ |
| 70 | ✓ |
| 71 | ✗ |
| 72 | ✗ |
| 73 | ✗ |
| 74 | ✓ |
| 75 | ✗ |
| 76 | ✗ |
| 77 | ✗ |
| 78 | ✗ |
| 79 | - |
| 80 | ✓ |
| 81 | ✗ |
| 82 | ✗ |
| 83 | ✗ |
| 84 | ✗ |
| 85 | ✗ |
| 86 | ✗ |
| 87 | ✗ |
| 88 | ✓ |
| 89 | ✓ |
| 90 | ✗ |
| 91 | ✗ |
| 92 | ✗ |
| 93 | ✗ |
| 94 | ✓ |
| 95 | ✗ |
| 96 | ✗ |
| 97 | ✗ |
| 98 | ✗ |
| **99** | ✓ |

100 ✕
101 ✕

All contents of this site are © 2024 Passmedicine Limited

A 82-year-old man presents to dermatology clinic with changes on his scalp. He is a bald man and has noticed that he has had thickened and abnormal skin. He has a long history of sun exposure from having been living in Spain for five years previously but has now returned to the UK permanently. He has also a history of smoking, but quit 15 years ago, and has also quit drinking. He has been diagnosed with COPD, fractured NOF, gout and hypertension. He normally uses ipratropium and seretide, as well as allopurinol, ramipril, amlodipine and alendronic acid.

On examination of his scalp he has erythematous skin with thickened plaques. It is mildly tender, and looks slightly irritated. What is the most appropriate treatment?

- Emollients
- Topical hydrocortisone
- Miconazole shampoo
- Topical 5-FU
- Salicylate cream

Submit answer

Reference ranges

Score: **14%**

1 ✗
2 ✗
3 ✓
4 ✗
5 ✗

| | |
|---|---|
| 6 | ✗ |
| 7 | ✗ |
| 8 | ✗ |
| 9 | ✗ |
| 10 | ✗ |
| 11 | ✓ |
| 12 | ✗ |
| 13 | ✓ |
| 14 | ✗ |
| 15 | ✗ |
| 16 | ✗ |
| 17 | ✗ |
| 18 | ✗ |
| 19 | ✗ |
| 20 | ✗ |
| 21 | ✗ |
| 22 | ✗ |
| 23 | ✗ |
| 24 | ✗ |
| 25 | ✗ |
| 26 | ✓ |
| 27 | ✗ |
| 28 | ✗ |
| 29 | ✗ |
| 30 | ✗ |
| 31 | ✗ |
| 32 | ✓ |
| 33 | ✗ |
| 34 | ✗ |
| 35 | ✗ |
| 36 | ✗ |
| 37 | ✗ |
| 38 | ✗ |
| 39 | ✗ |
| 40 | ✗ |
| 41 | ✗ |

| | |
|---|---|
| 42 | ✗ |
| 43 | ✗ |
| 44 | ✓ |
| 45 | ✗ |
| 46 | ✗ |
| 47 | ✓ |
| 48 | ✗ |
| 49 | ✗ |
| 50 | ✗ |
| 51 | - |
| 52 | - |
| 53 | - |
| 54 | - |
| 55 | - |
| 56 | - |
| 57 | - |
| 58 | - |
| 59 | - |
| 60 | - |
| 61 | - |
| 62 | - |
| 63 | - |
| 64 | - |
| 65 | - |
| 66 | - |
| 67 | - |
| 68 | - |
| 69 | - |
| 70 | - |
| 71 | - |
| 72 | - |
| 73 | - |
| 74 | - |
| 75 | - |
| 76 | - |
| 77 | - |
| 78 | - |
| 79 | - |
| 80 | - |

81 -
82 -
83 -
84 -
85 -
86 -
87 -
88 -
89 -
90 -
91 -
92 -
93 -
94 -
95 -
96 -
97 -
98 -
99 -
**100** -

All contents of this site are © 2024 Passmedicine Limited
Back to top

A 82-year-old man presents to dermatology clinic with changes on his scalp. He is a bald man and has noticed that he has had thickened and abnormal skin. He has a long history of sun exposure from having been living in Spain for five years previously but has now returned to the UK permanently. He has also a history of smoking, but quit 15 years ago, and has also quit drinking. He has been diagnosed with COPD, fractured NOF, gout and hypertension. He normally uses ipratropium and seretide, as well as allopurinol, ramipril, amlodipine and alendronic acid.

On examination of his scalp he has erythematous skin with thickened plaques. It is mildly tender, and looks slightly irritated. What is the most appropriate treatment?

| | |
|---|---|
| Emollients | 4% |
| Topical hydrocortisone | 18% |
| Miconazole shampoo | 13% |
| Topical 5-FU | 60% |
| Salicylate cream | 4% |

Topical 5-FU, imiquimob or difclofenac can be used as first line treatment for actinic keratosis

Important for me Less important

This patient has a typical presentation of actinic keratoses. Actinic keratoses, also known as solar keratosis, is an area of sun-damaged skin which is considered an early form of cutaneous squamous cell carcinoma. There are several treatment options available, including topical 5-FU, topical diclofenac, cryotherapy and topical imiquimod.

Topical hydrocortisone and emollients are used for eczema. Miconazole shampoo is used for tinea and other infections. Salicylate creams can help with scales, especially in psoriasis.

Based on British 'Association of Dermatologists' guidelines for the care of patients with actinic keratosis 2017'
http://www.bad.org.uk/shared/get-file.ashx?itemtype=document&id=4289

Discuss (8) Improve

Next question

# Actinic keratoses

Actinic, or solar, keratoses (AK) is a common premalignant skin lesion that develops as a consequence of chronic sun exposure

Features

- small, crusty or scaly, lesions
- may be pink, red, brown or the same colour as the skin
- typically on sun-exposed areas e.g. temples of head
- multiple lesions may be present

Management options include

- prevention of further risk: e.g. sun avoidance, sun cream
- fluorouracil cream: typically a 2 to 3 week course. The skin will become red and inflamed - sometimes topical hydrocortisone is given following fluorouracil to help settle the inflammation
- topical diclofenac: may be used for mild AKs. Moderate efficacy but much fewer side-effects
- topical imiquimod: trials have shown good efficacy
- cryotherapy
- curettage and cautery

Next question

## Textbooks

High-yield textbook

Extended textbook

## Links

British Association of Dermatologists — 👍 9 👎 9

2017 Actinic keratoses guidelines

DermNet NZ — 👍 27 👎 11

Actinic keratoses

Primary Care Dermatology Society — 👍 14 👎 5

Actinic keratosis

Suggest link | Report broken link

Score: **17%**

| | |
|---|---|
| 1 | ✗ |
| 2 | ✗ |
| 3 | ✓ |
| 4 | ✗ |
| 5 | ✗ |
| 6 | ✗ |
| 7 | ✗ |
| 8 | ✗ |
| 9 | ✗ |

| | |
|---|---|
| 10 | ✗ |
| 11 | ✓ |
| 12 | ✗ |
| 13 | ✓ |
| 14 | ✗ |
| 15 | ✗ |
| 16 | ✗ |
| 17 | ✗ |
| 18 | ✗ |
| 19 | ✗ |
| 20 | ✗ |
| 21 | ✗ |
| 22 | ✗ |
| 23 | ✗ |
| 24 | ✗ |
| 25 | ✗ |
| 26 | ✓ |
| 27 | ✗ |
| 28 | ✗ |
| 29 | ✗ |
| 30 | ✗ |
| 31 | ✗ |
| 32 | ✓ |
| 33 | ✗ |
| 34 | ✗ |
| 35 | ✗ |
| 36 | ✗ |
| 37 | ✗ |
| 38 | ✗ |
| 39 | ✗ |
| 40 | ✗ |
| 41 | ✗ |
| 42 | ✗ |
| 43 | ✗ |
| 44 | ✓ |
| 45 | ✗ |

| | |
|---|---|
| 46 | ✗ |
| 47 | ✓ |
| 48 | ✗ |
| 49 | ✗ |
| 50 | ✗ |
| 51 | ✗ |
| 52 | ✗ |
| 53 | ✗ |
| 54 | ✗ |
| 55 | ✗ |
| 56 | ✗ |
| 57 | ✗ |
| 58 | ✗ |
| 59 | ✗ |
| 60 | ✗ |
| 61 | ✗ |
| 62 | ✓ |
| 63 | ✗ |
| 64 | ✗ |
| 65 | ✓ |
| 66 | ✗ |
| 67 | ✗ |
| 68 | ✗ |
| 69 | ✓ |
| 70 | ✓ |
| 71 | ✗ |
| 72 | ✗ |
| 73 | ✗ |
| 74 | ✓ |
| 75 | ✗ |
| 76 | ✗ |
| 77 | ✗ |
| 78 | ✗ |
| 79 | - |
| 80 | ✓ |
| 81 | ✗ |

| | |
|---|---|
| 82 | ✗ |
| 83 | ✗ |
| 84 | ✗ |
| 85 | ✗ |
| 86 | ✗ |
| 87 | ✗ |
| 88 | ✓ |
| 89 | ✓ |
| 90 | ✗ |
| 91 | ✗ |
| 92 | ✗ |
| 93 | ✗ |
| 94 | ✓ |
| 95 | ✗ |
| 96 | ✗ |
| 97 | ✗ |
| 98 | ✗ |
| 99 | ✓ |
| **100** | ✗ |
| 101 | ✗ |

All contents of this site are © 2024 Passmedicine Limited

Back to top

A 72-year-old man presents to the general medical clinic with his daughter. She is concerned about him because she has developed shingles and is concerned that he may catch shingles from her, and wonders if he could have a shingles vaccination. The patient is well and has no rash. He has a past medical history of type 2 diabetes which is diet controlled, high cholesterol, previous stroke without residual weakness, as well as a fractured hip repaired with hemiarthroplasty. He normally takes aspirin, atorvastatin and paracetamol.

He believes that he has had chicken pox when he was young but does not think that he has ever had shingles or a shingles vaccination. What is the most appropriate plan?

- Offer oral aciclovir
- Offer shingles vaccination
- Explain that he is not eligible for shingles vaccination and should monitor for symptoms of shingles
- Arrange admission for IV aciclovir
- Offer oral corticosteroids

Submit answer

Reference ranges

Score: **14%**

| | |
|---|---|
| 1 | ✗ |
| 2 | ✗ |
| 3 | ✓ |
| 4 | ✗ |
| 5 | ✗ |

| | |
|---|---|
| 6 | ✗ |
| 7 | ✗ |
| 8 | ✗ |
| 9 | ✗ |
| 10 | ✗ |
| 11 | ✓ |
| 12 | ✗ |
| 13 | ✓ |
| 14 | ✗ |
| 15 | ✗ |
| 16 | ✗ |
| 17 | ✗ |
| 18 | ✗ |
| 19 | ✗ |
| 20 | ✗ |
| 21 | ✗ |
| 22 | ✗ |
| 23 | ✗ |
| 24 | ✗ |
| 25 | ✗ |
| 26 | ✓ |
| 27 | ✗ |
| 28 | ✗ |
| 29 | ✗ |
| 30 | ✗ |
| 31 | ✗ |
| 32 | ✓ |
| 33 | ✗ |
| 34 | ✗ |
| 35 | ✗ |
| 36 | ✗ |
| 37 | ✗ |
| 38 | ✗ |
| 39 | ✗ |
| 40 | ✗ |
| 41 | ✗ |

| | |
|---|---|
| 42 | ✗ |
| 43 | ✗ |
| 44 | ✓ |
| 45 | ✗ |
| 46 | ✗ |
| 47 | ✓ |
| 48 | ✗ |
| 49 | ✗ |
| 50 | ✗ |
| 51 | - |
| 52 | - |
| 53 | - |
| 54 | - |
| 55 | - |
| 56 | - |
| 57 | - |
| 58 | - |
| 59 | - |
| 60 | - |
| 61 | - |
| 62 | - |
| 63 | - |
| 64 | - |
| 65 | - |
| 66 | - |
| 67 | - |
| 68 | - |
| 69 | - |
| 70 | - |
| 71 | - |
| 72 | - |
| 73 | - |
| 74 | - |
| 75 | - |
| 76 | - |
| 77 | - |
| 78 | - |
| 79 | - |
| 80 | - |

| | |
|---|---|
| 81 | - |
| 82 | - |
| 83 | - |
| 84 | - |
| 85 | - |
| 86 | - |
| 87 | - |
| 88 | - |
| 89 | - |
| 90 | - |
| 91 | - |
| 92 | - |
| 93 | - |
| 94 | - |
| 95 | - |
| 96 | - |
| 97 | - |
| 98 | - |
| 99 | - |
| 100 | - |
| **101** | - |

All contents of this site are © 2024 Passmedicine Limited

Back to top

A 72-year-old man presents to the general medical clinic with his daughter. She is concerned about him because she has developed shingles and is concerned that he may catch shingles from her, and wonders if he could have a shingles vaccination. The patient is well and has no rash. He has a past medical history of type 2 diabetes which is diet controlled, high cholesterol, previous stroke without residual weakness, as well as a fractured hip repaired with hemiarthroplasty. He normally takes aspirin, atorvastatin and paracetamol.

He believes that he has had chicken pox when he was young but does not think that he has ever had shingles or a shingles vaccination. What is the most appropriate plan?

| | |
|---|---|
| Offer oral aciclovir | 8% |
| Offer shingles vaccination | 51% |
| Explain that he is not eligible for shingles vaccination and should monitor for symptoms of shingles | 39% |
| Arrange admission for IV aciclovir | 1% |
| Offer oral corticosteroids | 1% |

People aged between 70-79 years old are eligible for shingles vaccine

Important for me Less important

The patient is not at risk of catching shingles from another person with shingles, but is eligible for shingles vaccination. This is the most appropriate plan available. It could be argued that he should be asked to monitor for symptoms only as he is not of increased risk of shingles, but as he is eligible for vaccination and has inquired this should be offered.

Oral aciclovir can be used to treat acute shingles, whilst ophthalmic shingles would need hospital admission for IV aciclovir or ganciclovir.

Discuss (6) Improve

Next question

# Varicella-zoster vaccination ★

Varicella-zoster is the herpes virus that causes chickenpox. Shingles is an acute, unilateral, painful blistering rash caused by reactivation of the varicella-zoster virus (VZV).

There are two types of varicella-zoster vaccine:
- a vaccine that stops you from developing primary varicella infection (chickenpox)
- a vaccine that reduces the incidence of herpes zoster (shingles) caused by reactivation of VZV

## Vaccination against primary varicella infection (chickenpox)

This is a live attenuated vaccine. Examples include *Varilrix* and *Varivax*.

Example indications include:
- healthcare workers who are not already immune to VZV
- contacts of immunocompromised patients (e.g. child whose parent is undergoing chemotherapy)

## The 'shingles vaccine'

In 2013 the NHS introduced a vaccine to boost the immunity of elderly people against herpes zoster. Some important points about the vaccine:
- offered to all patients aged 70-79 years*
- is live-attenuated and given sub-cutaneously
- examples include *Zostavax*

As it is a live-attenuated vaccine the main contraindications are immunosuppression.

Side-effects
- injection site reactions
- less than 1 in 10,000 individuals will develop chickenpox

*there is also a catch up campaign. The following is taken from the NHS vaccination website:

> *Anyone aged 70 can have the shingles vaccine on the NHS. You become eligible for the vaccine from the first day of September after your 70th birthday.*

*From September 1 2015, the shingles vaccine will be offered routinely to people aged 70 and, as a catch up, to those aged 78. You become eligible for the vaccine on the first day of September 2015 after you've turned 70 or 78.*

*In addition, anyone who was eligible for immunisation in the previous two years of the programme but missed out on their vaccinations remains eligible until their 80th birthday. This includes:*

- *people aged 71 and 72 on 1 September 2015*
- *people aged 79*

*The shingles vaccine is not available on the NHS to anyone aged 80 and over because it seems to be less effective in this age group.*

+ Q 123

Next question

## Textbooks

High-yield textbook

Extended textbook

## Links

Clinical Knowledge Summaries 7 6

Shingles guidelines

Suggest link Report broken link

## Media

Varicella zoster virus

Osmosis - YouTube 1 0

Report broken media

Score: **17%**

| | |
|---|---|
| 1 | ✗ |
| 2 | ✗ |
| 3 | ✓ |
| 4 | ✗ |
| 5 | ✗ |
| 6 | ✗ |
| 7 | ✗ |
| 8 | ✗ |
| 9 | ✗ |
| 10 | ✗ |
| 11 | ✓ |
| 12 | ✗ |
| 13 | ✓ |
| 14 | ✗ |
| 15 | ✗ |
| 16 | ✗ |
| 17 | ✗ |
| 18 | ✗ |
| 19 | ✗ |
| 20 | ✗ |
| 21 | ✗ |
| 22 | ✗ |

| | |
|---|---|
| 23 | ✗ |
| 24 | ✗ |
| 25 | ✗ |
| 26 | ✓ |
| 27 | ✗ |
| 28 | ✗ |
| 29 | ✗ |
| 30 | ✗ |
| 31 | ✗ |
| 32 | ✓ |
| 33 | ✗ |
| 34 | ✗ |
| 35 | ✗ |
| 36 | ✗ |
| 37 | ✗ |
| 38 | ✗ |
| 39 | ✗ |
| 40 | ✗ |
| 41 | ✗ |
| 42 | ✗ |
| 43 | ✗ |
| 44 | ✓ |
| 45 | ✗ |
| 46 | ✗ |
| 47 | ✓ |
| 48 | ✗ |
| 49 | ✗ |
| 50 | ✗ |
| 51 | ✗ |
| 52 | ✗ |
| 53 | ✗ |
| 54 | ✗ |
| 55 | ✗ |
| 56 | ✗ |
| 57 | ✗ |
| 58 | ✗ |

| | |
|---|---|
| 59 | ✗ |
| 60 | ✗ |
| 61 | ✗ |
| 62 | ✓ |
| 63 | ✗ |
| 64 | ✗ |
| 65 | ✓ |
| 66 | ✗ |
| 67 | ✗ |
| 68 | ✗ |
| 69 | ✓ |
| 70 | ✓ |
| 71 | ✗ |
| 72 | ✗ |
| 73 | ✗ |
| 74 | ✓ |
| 75 | ✗ |
| 76 | ✗ |
| 77 | ✗ |
| 78 | ✗ |
| 79 | - |
| 80 | ✓ |
| 81 | ✗ |
| 82 | ✗ |
| 83 | ✗ |
| 84 | ✗ |
| 85 | ✗ |
| 86 | ✗ |
| 87 | ✗ |
| 88 | ✓ |
| 89 | ✓ |
| 90 | ✗ |
| 91 | ✗ |
| 92 | ✗ |
| 93 | ✗ |
| 94 | ✓ |

| | |
|---|---|
| 95 | ✗ |
| 96 | ✗ |
| 97 | ✗ |
| 98 | ✗ |
| 99 | ✓ |
| 100 | ✗ |
| **101** | ✗ |

All contents of this site are © 2024 Passmedicine Limited

Back to top

A 37-year-old gentleman is referred to the cardiology clinic with a 7-month history of bilateral foot pain. Initially, the pain only occurred towards the end of his daily commute; improving when he sat at his desk, but over the past 3 weeks his symptoms have progressed. The pain is now provoked by walking short distances and has occasionally occurred at rest. He describes being woken by the pain at night, although he is able to obtain relief by standing on the cool tiles in his bathroom. He eventually decided to see his GP when he developed similar pain in his right wrist 10 days ago.

His past medical history is unremarkable. There is no history of hypertension, dyslipidaemia or diabetes. He is a current smoker with a 20 pack year history. He drinks alcohol in moderation.

On examination, both feet are noted to be smooth and hairless. The right dorsalis pedis is difficult to feel and the medial 3 toes are cold and dusky. Urgent angiography is performed and shows a number of distal stenoses in the right limb affecting the anterior and posterior tibial arteries as well as the distal fibular artery. A number of similar stenoses are seen in the contralateral limb with 'corkscrew' collateral formation.

Blood tests are as follows:

| | | | |
|---|---|---|---|
| Hb | 130 g/l | $Na^+$ | 139 mmol/l |
| Platelets | $322*10^9$/l | $K^+$ | 4.1 mmol/l |
| WBC | $9.1*10^9$/l | Urea | 5.3 mmol/l |
| Neuts | $6.2*10^9$/l | Creatinine | 113 µmol/l |
| Lymphs | $2.1*10^9$/l | CRP | 19 mg/l |
| Eosin | $0.1*10^9$/l | | |

| | |
|---|---|
| MPO | negative |
| PR3 | negative |
| anti-cardiolipin | negative |

What is the most likely diagnosis?

- Peripheral vascular disease

- Microscopic polyangiitis
- Takayasu arteritis
- Thromboangiitis obliterans
- Polyarteritis nodosa

Submit answer

Reference ranges

Score: **0%**

**1** -

All contents of this site are © 2024 Passmedicine Limited

A 37-year-old gentleman is referred to the cardiology clinic with a 7-month history of bilateral foot pain. Initially, the pain only occurred towards the end of his daily commute; improving when he sat at his desk, but over the past 3 weeks his symptoms have progressed. The pain is now provoked by walking short distances and has occasionally occurred at rest. He describes being woken by the pain at night, although he is able to obtain relief by standing on the cool tiles in his bathroom. He eventually decided to see his GP when he developed similar pain in his right wrist 10 days ago.

His past medical history is unremarkable. There is no history of hypertension, dyslipidaemia or diabetes. He is a current smoker with a 20 pack year history. He drinks alcohol in moderation.

On examination, both feet are noted to be smooth and hairless. The right dorsalis pedis is difficult to feel and the medial 3 toes are cold and dusky. Urgent angiography is performed and shows a number of distal stenoses in the right limb affecting the anterior and posterior tibial arteries as well as the distal fibular artery. A number of similar stenoses are seen in the contralateral limb with 'corkscrew' collateral formation.

Blood tests are as follows:

| | | | |
|---|---|---|---|
| Hb | 130 g/l | $Na^+$ | 139 mmol/l |
| Platelets | $322*10^9$/l | $K^+$ | 4.1 mmol/l |
| WBC | $9.1*10^9$/l | Urea | 5.3 mmol/l |
| Neuts | $6.2*10^9$/l | Creatinine | 113 µmol/l |
| Lymphs | $2.1*10^9$/l | CRP | 19 mg/l |
| Eosin | $0.1*10^9$/l | | |

| | |
|---|---|
| MPO | negative |
| PR3 | negative |
| anti-cardiolipin | negative |

What is the most likely diagnosis?

Peripheral vascular disease 25%

| | |
|---|---|
| Microscopic polyangiitis | 4% |
| Takayasu arteritis | 9% |
| Thromboangiitis obliterans | 49% |
| Polyarteritis nodosa | 12% |

The patient presents with symptoms of arterial insufficiency; however, his age, lack of vascular risk factors and upper limb involvement should alert you to the fact this may not be a simple case of peripheral vascular disease.

Both microscopic polyangiitis and polyarteritis nodosa are multisystem vasculitic disorders characterised by constitutional symptoms such as weight loss, fever, anorexia, and fatigue. Renal involvement and skin rash are common, as is an association with p-ANCA (MPO) antibodies and elevation of the inflammatory markers.

Takayasu arteritis is a large vessel vasculitis that affects the aorta and its branches. It is more common in females and would not typically cause the isolated small and medium vessel stenoses described above.

Thromboangiitis obliterans is an inflammatory disorder of the small to medium-sized arteries and superficial veins in the distal extremities. Segmental arterial inflammation and thrombus formation lead to peripheral limb ischaemia, with the disease often pursuing an aggressive course. The aetiology is unclear but the condition is strongly associated with smoking, and disease progression is closely linked to continued tobacco use. It most commonly affects men aged 20-40.

The diagnosis is made on the basis of a characteristic history and examination, angiographic findings and the exclusion of proximal emboli and vasculitic disorders. Typical findings on angiography include segmental occlusions of the distal arteries in the hands and feet, 'corkscrew' collateral vessels and the lack of widespread atherosclerotic disease. Thromboangiitis obliterans is, therefore, the most appropriate answer to the question.

Discuss (10) Improve

Next question

## Vasculitides

Large vessel

- temporal arteritis
- Takayasu's arteritis

Medium vessel

- polyarteritis nodosa
- Kawasaki disease

Small vessel

- ANCA-associated vasculitides
    - granulomatosis with polyangiitis (Wegener's granulomatosis)
    - eosinophilic granulomatosis with polyangiitis (Churg-Strauss syndrome)
    - microscopic polyangiitis
- immune complex small-vessel vasculitis
    - Henoch-Schonlein purpura
    - Goodpasture's syndrome (anti-glomerular basement membrane disease)
    - cryoglobulinaemic vasculitis
    - hypocomplementemic urticarial vasculitis (anti-C1q vasculitis)

+ Q 123

Next question >

**Textbooks**

High-yield textbook

Extended textbook

## Links

DermNet NZ 4 2

Cutaneous vasculitis

Patient.info 5 0

Vasculitis review

Suggest link Report broken link

## Media

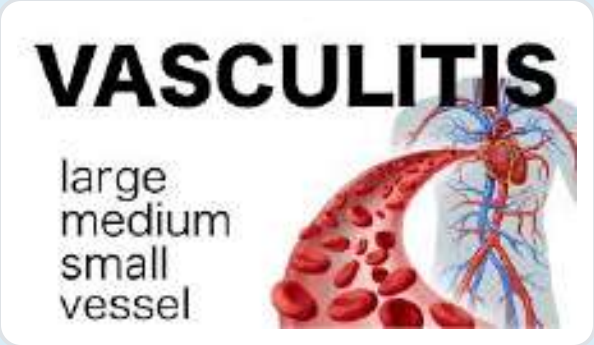


Vasculitis

Dirty USMLE - YouTube 6 0

Vasculitis

Osmosis - YouTube 1 0

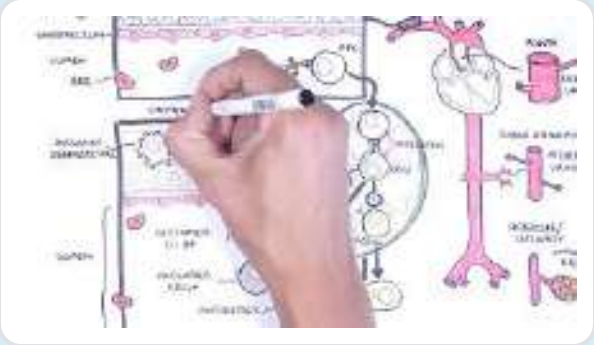

Vasculitis Pathophysiology Overview

Armando Hasudungan - YouTube 2 1

Report broken media

Score: **28%**

| | |
|---|---|
| **1** | ✗ |
| 2 | ✓ |
| 3 | ✓ |
| 4 | ✗ |
| 5 | ✗ |
| 6 | ✗ |
| 7 | ✗ |
| 8 | ✗ |
| 9 | ✗ |
| 10 | ✗ |
| 11 | ✗ |
| 12 | ✗ |
| 13 | ✓ |
| 14 | ✓ |
| 15 | ✓ |
| 16 | ✗ |
| 17 | ✓ |
| 18 | ✓ |
| 19 | ✗ |
| 20 | ✗ |
| 21 | ✗ |
| 22 | ✗ |
| 23 | ✗ |
| 24 | ✓ |
| 25 | ✗ |
| 26 | ✓ |
| 27 | ✗ |
| 28 | ✗ |
| 29 | ✗ |
| 30 | ✓ |
| 31 | ✗ |
| 32 | ✗ |
| 33 | ✗ |

| | |
|---|---|
| 34 | ✗ |
| 35 | ✓ |
| 36 | ✗ |
| 37 | ✗ |
| 38 | ✗ |
| 39 | ✗ |
| 40 | ✗ |
| 41 | ✗ |
| 42 | ✓ |
| 43 | ✗ |
| 44 | ✗ |
| 45 | ✓ |
| 46 | ✓ |
| 47 | ✗ |
| 48 | ✗ |
| 49 | ✗ |
| 50 | ✗ |

All contents of this site are © 2024 Passmedicine Limited

Back to top

A 66-year-old man presents to the GP with the following lesion on his nose, which he says has been growing over the course of several years:

© Image used on license from DermNet NZ

He is otherwise well in himself, and takes amlodipine for hypertension.

Given the likely diagnosis, which of the following is the most appropriate, definitive management?

- Conventional surgery
- Cryotherapy
- Fluorouracil
- Imiquimod
- Mohs surgery

Submit answer

Reference ranges

Score: **0%**

1 -
**2** -

All contents of this site are © 2024 Passmedicine Limited

A 66-year-old man presents to the GP with the following lesion on his nose, which he says has been growing over the course of several years:

© Image used on license from DermNet NZ

He is otherwise well in himself, and takes amlodipine for hypertension.

Given the likely diagnosis, which of the following is the most appropriate, definitive management?

| | |
|---|---|
| Conventional surgery | 12% |
| Cryotherapy | 8% |
| Fluorouracil | 7% |
| Imiquimod | 3% |
| Mohs surgery | 70% |

The most appropriate option is Mohs surgery. The lesion shown here is a basal cell carcinoma (BCC), which are characterised by slow growth and local invasion. BCCs are typically found on sun-exposed sites, such as the nose in this scenario. The picture here depicts the typical features of a BCC - it is a papule with 'pearly, rolled edges' and a depressed, crater-like central area which has followed ulceration. BCCs often have associated telangiectasia, which is not so obvious in this photo. Definitive management involves surgical removal. Mohs surgery is the preferable option for

cosmetically challenging locations such as the face, removing very small amounts at a time, thus leaving the smallest scar.

Conventional surgery almost always results in complete cure. However, it should be reserved for areas where tissue sparing is not important, as it is likely to result in significant scarring. For sensitive areas such as the face, Mohs surgery is more appropriate.

Cryotherapy is a potential option if the BCC is not advanced and does not extend deeply upon palpation. This BCC, however, appears to have ulcerated and left a crater visible in the photo, which suggests it is more advanced. Furthermore, the question asks for 'definitive' management - surgery is the most definitive route for BCCs.

Fluouracil is a topical option, often used when multiple BCCs are present. It can significantly reduce the size and appearance of the lesions over time, with repeated application. It is not, however, the most definitive management.

Imiquimod is another topical option and has more evidence supporting its efficacy than fluouracil. It has a good cure rate, although is not as definitive or successful as surgery.

Discuss Improve

Next question

## Basal cell carcinoma

Basal cell carcinoma (BCC) is one of the three main types of skin cancer. Lesions are also known as rodent ulcers and are characterised by slow-growth and local invasion. Metastases are extremely rare. BCC is the most common type of cancer in the Western world.

Features

- many types of BCC are described. The most common type is nodular BCC, which is described here
- sun-exposed sites, especially the head and neck account for the majority of lesions
- initially a pearly, flesh-coloured papule with telangiectasia
- may later ulcerate leaving a central 'crater'

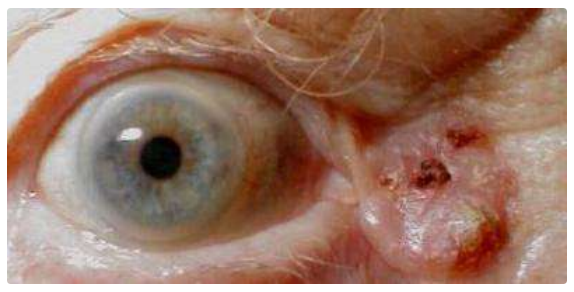

Referral

- generally, if a BCC is suspected, a routine referral should be made

Management options:

- surgical removal
- curettage
- cryotherapy
- topical cream: imiquimod, fluorouracil
- radiotherapy

123

Next question

**Textbooks**

High-yield textbook

Extended textbook

## Links

DermNet NZ 21 7

Basal cell carcinoma

Suggest link Report broken link

## Media

Skin cancers

Osmosis - YouTube 4 2

Report broken media

Score: **28%**

| | |
|---|---|
| 1 | ✗ |
| **2** | ✓ |
| 3 | ✓ |
| 4 | ✗ |
| 5 | ✗ |
| 6 | ✗ |
| 7 | ✗ |
| 8 | ✗ |
| 9 | ✗ |
| 10 | ✗ |
| 11 | ✗ |
| 12 | ✗ |
| 13 | ✓ |
| 14 | ✓ |
| 15 | ✓ |

| | |
|---|---|
| 16 | ✗ |
| 17 | ✓ |
| 18 | ✓ |
| 19 | ✗ |
| 20 | ✗ |
| 21 | ✗ |
| 22 | ✗ |
| 23 | ✗ |
| 24 | ✓ |
| 25 | ✗ |
| 26 | ✓ |
| 27 | ✗ |
| 28 | ✗ |
| 29 | ✗ |
| 30 | ✓ |
| 31 | ✗ |
| 32 | ✗ |
| 33 | ✗ |
| 34 | ✗ |
| 35 | ✓ |
| 36 | ✗ |
| 37 | ✗ |
| 38 | ✗ |
| 39 | ✗ |
| 40 | ✗ |
| 41 | ✗ |
| 42 | ✓ |
| 43 | ✗ |
| 44 | ✗ |
| 45 | ✓ |
| 46 | ✓ |
| 47 | ✗ |
| 48 | ✗ |
| 49 | ✗ |
| 50 | ✗ |

All contents of this site are © 2024 Passmedicine Limited

A 45 year old man with mild learning difficulties and newly diagnosed advanced HIV (CD4 count 65 /mm3) attends A&E from his residential home. He has an intensely itchy rash on his hands, arms, groin, legs and feet. He was recently commenced on Atripla ( Emtritcitabine, Tenofavir, Efavirenz) and co-trimoxazole.

© Image used on license from DermNet NZ

There is extensive crusted scaling on his arms, groins and hands. On closer examination there are grey burrow marks between the webs of his fingers and toes. There are itchy nodules extensively over the palms and backs of his hands.

What is the most appropriate treatment?

- Isolate and apply topical malathion cream for 24 hours
- Isolate and stop co-trimoxazole
- Discharge with topical steroids
- Change his antiretroviral therapy to a second line regimen
- Isolate and give ivermectin orally

Submit answer

Reference ranges

Score: **0%**

1 -
2 -
**3** -

All contents of this site are © 2024 Passmedicine Limited

A 45 year old man with mild learning difficulties and newly diagnosed advanced HIV (CD4 count 65 /mm3) attends A&E from his residential home. He has an intensely itchy rash on his hands, arms, groin, legs and feet. He was recently commenced on Atripla ( Emtritcitabine, Tenofavir, Efavirenz) and co-trimoxazole.

© Image used on license from DermNet NZ

There is extensive crusted scaling on his arms, groins and hands. On closer examination there are grey burrow marks between the webs of his fingers and toes. There are itchy nodules extensively over the palms and backs of his hands.

What is the most appropriate treatment?

| | |
|---|---|
| Isolate and apply topical malathion cream for 24 hours | 44% |
| Isolate and stop co-trimoxazole | 1% |
| Discharge with topical steroids | 1% |
| Change his antiretroviral therapy to a second line regimen | 2% |
| Isolate and give ivermectin orally | 52% |

The correct answer is **Isolate and give ivermectin orally**. This patient has a clinical presentation consistent with scabies, which is caused by the mite *Sarcoptes scabiei*. Immunocompromised patients are at risk of developing crusted scabies (formerly known as Norwegian scabies). It typically begins as poorly defined red patches that then develop into thicker, scaly plaques between the fingers, under the nails, or diffusely over palms and soles. Mites can also potentially

collect in nail beds, causing the nail plates to split.

In patients with advanced HIV, such as this patient with a CD4 count of 65/mm3, scabies can be more severe and difficult to treat. Ivermectin is an effective oral treatment for scabies and is particularly useful in cases where topical treatments may be less effective or challenging to apply.

**Isolate and apply topical malathion cream for 24 hours** would be an appropriate treatment option for uncomplicated scabies in an immunocompetent individual. However, given the severity of this patient's infection and his immunocompromised state due to advanced HIV, oral ivermectin would be a more suitable choice.

**Isolate and stop co-trimoxazole** is not an appropriate management plan because stopping co-trimoxazole will not address the underlying cause of the rash - scabies. Co-trimoxazole was likely prescribed as prophylaxis against opportunistic infections due to the patient's low CD4 count.

**Discharge with topical steroids** would not effectively treat the underlying scabies infection. Topical steroids may provide temporary relief from itching but do not eradicate the mites causing the infection.

**Change his antiretroviral therapy to a second-line regimen** is not indicated in this scenario. There is no evidence to suggest that changing antiretroviral therapy would impact this patient's scabies infection or improve his symptoms. The focus should be on treating the scabies infection with appropriate medication, such as oral ivermectin.

Discuss (4) Improve

Next question

## Scabies

Scabies is caused by the mite *Sarcoptes scabiei* and is spread by prolonged skin contact. It typically affects children and young adults.

The scabies mite burrows into the skin, laying its eggs in the stratum corneum. The intense pruritus associated with scabies is due to a delayed-type IV hypersensitivity reaction to mites/eggs which occurs about 30 days after the initial infection.

Features

- widespread pruritus
- linear burrows on the side of fingers, interdigital webs and flexor aspects of the wrist
- in infants, the face and scalp may also be affected

- secondary features are seen due to scratching: excoriation, infection

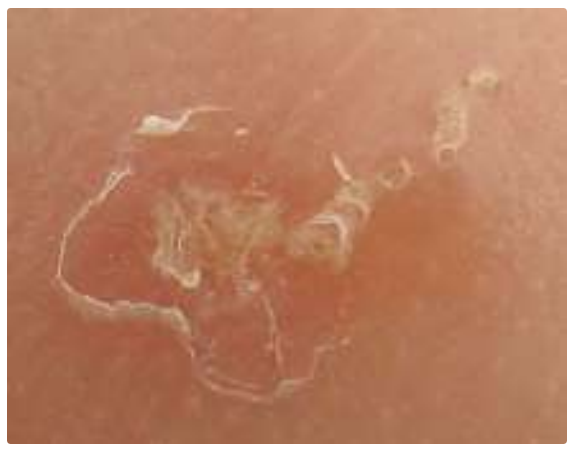

Management
- permethrin 5% is first-line
- malathion 0.5% is second-line
- give appropriate guidance on use (see below)
- pruritus persists for up to 4-6 weeks post eradication

Patient guidance on treatment
- avoid close physical contact with others until treatment is complete
- all household and close physical contacts should be treated at the same time, even if asymptomatic
- launder, iron or tumble dry clothing, bedding, towels, etc., on the first day of treatment to kill off mites.

The BNF advises to apply the insecticide to all areas, including the face and scalp, contrary to the manufacturer's recommendation. Patients should be given the following instructions:
- apply the insecticide cream or liquid to cool, dry skin
- pay close attention to areas between fingers and toes, under nails, armpit area, creases of the skin such as at the wrist and elbow
- allow to dry and leave on the skin for 8-12 hours for permethrin, or for 24 hours for malathion, before washing off
- reapply if insecticide is removed during the treatment period, e.g. If wash hands, change nappy, etc
- repeat treatment 7 days later

## Crusted (Norwegian) scabies

Crusted scabies is seen in patients with suppressed immunity, especially HIV.

© Image used on license from DermNet NZ

The crusted skin will be teeming with hundreds of thousands of organisms.

Ivermectin is the treatment of choice and isolation is essential

+ Q 123

Next question >

## Textbooks

High-yield textbook

Extended textbook

## Links

Clinical Knowledge Summaries 19 14

Scabies guidelines

Score: **28%**

| | |
|---|---|
| 1 | ✗ |
| 2 | ✓ |
| **3** | ✓ |
| 4 | ✗ |
| 5 | ✗ |
| 6 | ✗ |
| 7 | ✗ |
| 8 | ✗ |
| 9 | ✗ |
| 10 | ✗ |
| 11 | ✗ |
| 12 | ✗ |
| 13 | ✓ |
| 14 | ✓ |
| 15 | ✓ |
| 16 | ✗ |
| 17 | ✓ |
| 18 | ✓ |
| 19 | ✗ |
| 20 | ✗ |
| 21 | ✗ |
| 22 | ✗ |
| 23 | ✗ |
| 24 | ✓ |
| 25 | ✗ |
| 26 | ✓ |
| 27 | ✗ |
| 28 | ✗ |
| 29 | ✗ |

| | |
|---|---|
| 30 | ✓ |
| 31 | ✗ |
| 32 | ✗ |
| 33 | ✗ |
| 34 | ✗ |
| 35 | ✓ |
| 36 | ✗ |
| 37 | ✗ |
| 38 | ✗ |
| 39 | ✗ |
| 40 | ✗ |
| 41 | ✗ |
| 42 | ✓ |
| 43 | ✗ |
| 44 | ✗ |
| 45 | ✓ |
| 46 | ✓ |
| 47 | ✗ |
| 48 | ✗ |
| 49 | ✗ |
| 50 | ✗ |

All contents of this site are © 2024 Passmedicine Limited

Back to top

A 52-year-old gentleman presents with a lesion on his tongue. He has noticed feeling 'something odd'in his tongue and noticed a white rash on the side of the tongue which he is unable to wipe away. He has a past medical history of recurrent herpes simplex sores, HIV, hypertension and an ankle fracture requiring surgery. He takes only losartan. On examination, there is a thickly furrowed white lesion on the side of his tongue. What is the most appropriate treatment that would help resolve the lesion?

- Antifungal treatment
- Antiretroviral treatment
- Long-term antibiotics
- Oral steroids
- Surgical resection

Submit answer

Reference ranges

Score: **0%**

1 -
2 -
3 -
**4** -

All contents of this site are © 2024 Passmedicine Limited

Back to top

A 52-year-old gentleman presents with a lesion on his tongue. He has noticed feeling 'something odd'in his tongue and noticed a white rash on the side of the tongue which he is unable to wipe away. He has a past medical history of recurrent herpes simplex sores, HIV, hypertension and an ankle fracture requiring surgery. He takes only losartan. On examination, there is a thickly furrowed white lesion on the side of his tongue. What is the most appropriate treatment that would help resolve the lesion?

| | |
|---|---|
| Antifungal treatment | 22% |
| Antiretroviral treatment | 35% |
| Long-term antibiotics | 1% |
| Oral steroids | 16% |
| Surgical resection | 26% |

The correct answer is antiretroviral treatment. This patient with is described as having leukoplakia. A white lesion on the side of the tongue is most commonly candida or lichen planus, but the fact that the lesion can't be rubbed off makes leukoplakia a more likely diagnosis, especially in the context of HIV. A biopsy should be done to exclude a squamous cell cancer. Despite the lesion being caused by EBV, treating the underlying HIV causes improvement.

Discuss (7) Improve

Next question

## Leukoplakia

Leukoplakia is a premalignant condition which presents as white, hard spots on the mucous membranes of the mouth. It is more common in smokers.

Leukoplakia is said to be a diagnosis of exclusion. Candidiasis and lichen planus should be considered, especially if the lesions can be 'rubbed off'

Biopsies are usually performed to exclude alternative diagnoses such as squamous cell carcinoma and regular follow-up is required to exclude malignant transformation to squamous cell carcinoma, which occurs in around 1% of patients.

+ Q 123

Next question >

### Textbooks

High-yield textbook

Extended textbook

### Links

DermNet NZ 10 0

Oral leukoplakia

Suggest link Report broken link

Score: **28%**

| | |
|---|---|
| 1 | ✗ |
| 2 | ✓ |
| 3 | ✓ |
| **4** | ✗ |
| 5 | ✗ |
| 6 | ✗ |
| 7 | ✗ |
| 8 | ✗ |
| 9 | ✗ |
| 10 | ✗ |
| 11 | ✗ |
| 12 | ✗ |
| 13 | ✓ |
| 14 | ✓ |
| 15 | ✓ |
| 16 | ✗ |
| 17 | ✓ |
| 18 | ✓ |
| 19 | ✗ |
| 20 | ✗ |
| 21 | ✗ |
| 22 | ✗ |
| 23 | ✗ |
| 24 | ✓ |
| 25 | ✗ |
| 26 | ✓ |
| 27 | ✗ |
| 28 | ✗ |
| 29 | ✗ |
| 30 | ✓ |
| 31 | ✗ |
| 32 | ✗ |
| 33 | ✗ |
| 34 | ✗ |
| 35 | ✓ |

| | |
|---|---|
| 36 | ✗ |
| 37 | ✗ |
| 38 | ✗ |
| 39 | ✗ |
| 40 | ✗ |
| 41 | ✗ |
| 42 | ✓ |
| 43 | ✗ |
| 44 | ✗ |
| 45 | ✓ |
| 46 | ✓ |
| 47 | ✗ |
| 48 | ✗ |
| 49 | ✗ |
| 50 | ✗ |

All contents of this site are © 2024 Passmedicine Limited

A 55-year-old gentleman was referred to the urgent outpatient dermatology clinic with a flare up of long standing psoriasis. HIs GP had diagnosed him with psoriasis five years ago. It usually affected the extensor surfaces of his elbows and was well controlled with a combination of topical vitamin D analogue and topical corticosteroid. For the last four weeks, however, the rash had become extensive across his chest and back. Despite an intensive trial of topical high potency corticosteroid and further topical vitamin D analogue, his rash had seemed to be worsening, leading to his referral.

His past medical history comprised hypercholesterolaemia and hypertension which were diagnosed at a well man check by his GP three months ago. As he also suffered from palpitations which were thought to be induced by anxiety, he was commenced on propranolol modified release 80mg OD, as well as simvastatin 40mg OD. He also suffered from chronic low back pain for the last few years and used naproxen 500mg BD with lansoprazole 30mg OD for the last five years with good effect. He also admitted to using over the counter aspirin 75 mg OD for the last nine years as his friend was prescribed this by her doctor.

Examination revealed a widespread rash comprising of multiple scaly erythematous discrete plaques across his chest, abdomen, back and extensor surfaces of his elbows and knees. He was otherwise systemically well.

Which is the single most likely causative agent responsible for the deterioration?

- Propranolol
- Simvastatin
- Naproxen
- Lansoprazole
- Aspirin

Submit answer

Reference ranges

Score: **0%**

1 -
2 -
3 -
4 -
**5** -

All contents of this site are © 2024 Passmedicine Limited

Back to top

A 55-year-old gentleman was referred to the urgent outpatient dermatology clinic with a flare up of long standing psoriasis. HIs GP had diagnosed him with psoriasis five years ago. It usually affected the extensor surfaces of his elbows and was well controlled with a combination of topical vitamin D analogue and topical corticosteroid. For the last four weeks, however, the rash had become extensive across his chest and back. Despite an intensive trial of topical high potency corticosteroid and further topical vitamin D analogue, his rash had seemed to be worsening, leading to his referral.

His past medical history comprised hypercholesterolaemia and hypertension which were diagnosed at a well man check by his GP three months ago. As he also suffered from palpitations which were thought to be induced by anxiety, he was commenced on propranolol modified release 80mg OD, as well as simvastatin 40mg OD. He also suffered from chronic low back pain for the last few years and used naproxen 500mg BD with lansoprazole 30mg OD for the last five years with good effect. He also admitted to using over the counter aspirin 75 mg OD for the last nine years as his friend was prescribed this by her doctor.

Examination revealed a widespread rash comprising of multiple scaly erythematous discrete plaques across his chest, abdomen, back and extensor surfaces of his elbows and knees. He was otherwise systemically well.

Which is the single most likely causative agent responsible for the deterioration?

- Propranolol 77%
- Simvastatin 4%
- Naproxen 11%
- Lansoprazole 2%
- Aspirin 6%

Beta-blockers are known to exacerbate plaque psoriasis

Important for me Less important

Psoriasis may be exacerbated by a variety of causes. With respect to drugs, the most common suspects are lithium and beta blockers. Other agents include antimalarials, ACE inhibitors and non-

steroidal anti-inflammatories. The patient was indeed using naproxen and aspirin. However, he was commenced on propranolol recently with a subsequent exacerbation of his psoriasis. The most suitable answer, therefore, is propranolol.

Discuss (6) Improve

Next question

## Psoriasis: exacerbating factors

The following factors may exacerbate psoriasis:

- trauma
- alcohol
- drugs: beta blockers, lithium, antimalarials (chloroquine and hydroxychloroquine), NSAIDs and ACE inhibitors, infliximab
- withdrawal of systemic steroids

Streptococcal infection may trigger guttate psoriasis.

Next question

**Textbooks**

High-yield textbook

Extended textbook

## Links

DermNet NZ 21 7

Psoriasis

Suggest link Report broken link

## Media

Psoriasis

Osmosis - YouTube 2 0

Report broken media

Score: **28%**

| | |
|---|---|
| 1 | ✗ |
| 2 | ✓ |
| 3 | ✓ |
| 4 | ✗ |
| **5** | ✗ |
| 6 | ✗ |
| 7 | ✗ |
| 8 | ✗ |
| 9 | ✗ |
| 10 | ✗ |
| 11 | ✗ |
| 12 | ✗ |
| 13 | ✓ |
| 14 | ✓ |
| 15 | ✓ |

| | |
|---|---|
| 16 | ✗ |
| 17 | ✓ |
| 18 | ✓ |
| 19 | ✗ |
| 20 | ✗ |
| 21 | ✗ |
| 22 | ✗ |
| 23 | ✗ |
| 24 | ✓ |
| 25 | ✗ |
| 26 | ✓ |
| 27 | ✗ |
| 28 | ✗ |
| 29 | ✗ |
| 30 | ✓ |
| 31 | ✗ |
| 32 | ✗ |
| 33 | ✗ |
| 34 | ✗ |
| 35 | ✓ |
| 36 | ✗ |
| 37 | ✗ |
| 38 | ✗ |
| 39 | ✗ |
| 40 | ✗ |
| 41 | ✗ |
| 42 | ✓ |
| 43 | ✗ |
| 44 | ✗ |
| 45 | ✓ |
| 46 | ✓ |
| 47 | ✗ |
| 48 | ✗ |
| 49 | ✗ |
| 50 | ✗ |

All contents of this site are © 2024 Passmedicine Limited

A 49-year-old woman complains of 'spots' on her cheeks. She has tried using her daughter's 'Clearasil' but this has had no effect.

© Image used on license from DermNet NZ

What is the most likely diagnosis?

- Seborrhoeic dermatitis
- Systemic lupus erythematous
- Perioral dermatitis
- Late-onset acne vulgaris
- Acne rosacea

Submit answer

Reference ranges

Score: **0%**

1 -
2 -
3 -
4 -
5 -
**6** -

All contents of this site are © 2024 Passmedicine Limited

A 49-year-old woman complains of 'spots' on her cheeks. She has tried using her daughter's 'Clearasil' but this has had no effect.

© Image used on license from DermNet NZ

What is the most likely diagnosis?

- Seborrhoeic dermatitis 3%
- Systemic lupus erythematous 4%
- Perioral dermatitis 1%
- Late-onset acne vulgaris 9%
- Acne rosacea 83%

Rosacea features:

- nose, cheeks and forehead
- flushing, erythema, telangiectasia → papules and pustules

Important for me Less important

The correct answer to this question is **Acne rosacea**. This condition, also known as rosacea, is a common skin disease that often begins with a tendency to blush or flush more easily than other people. The redness can slowly spread beyond the nose and cheeks to the forehead and chin. Even the ears, chest, and back can be red all the time. The image shows typical features of Acne rosacea: erythema (redness) of the cheeks with some papules (small bumps) and pustules. It's important to note that this condition is different from acne, which typically includes blackheads and whiteheads - these are not present in rosacea.

**Seborrhoeic dermatitis** is an incorrect option because it usually presents with greasy-looking, flaky skin in areas rich in sebaceous glands such as the scalp, eyebrows, sides of the nose, behind the ears and middle of the chest. It does not typically present with spots on cheeks.

**Systemic lupus erythematosus (SLE)** could potentially cause a malar rash ('butterfly' rash) on cheeks but this would usually also involve the bridge of the nose which isn't mentioned in this case. Additionally, SLE-related rashes are photosensitive and there was no mention of sunlight exacerbating symptoms in this scenario.

**Perioral dermatitis**, as its name suggests, tends to occur around the mouth area (although sometimes it can affect areas around the eyes or nose). It presents as groups of itchy or tender small red papules. It's unlikely in this case due to the location being described as 'cheeks'.

Lastly, **Late-onset acne vulgaris**, while possible at any age including adulthood ('late-onset'), would typically include comedones (blackheads & whiteheads), which were not mentioned here. Furthermore, over-the-counter treatments like Clearasil often have some effect on acne vulgaris but none on rosacea according to the patient's history.

Discuss (4) | Improve

Next question

## Rosacea

Rosacea (sometimes referred to as acne rosacea) is a chronic skin disease of unknown aetiology.

Features
- typically affects nose, cheeks and forehead
- flushing is often first symptom
- telangiectasia are common
- later develops into persistent erythema with papules and pustules
- rhinophyma

- ocular involvement: blepharitis
- sunlight may exacerbate symptoms

Management

- simple measures
  - recommend daily application of a high-factor sunscreen
  - camouflage creams may help conceal redness
- predominant erythema/flushing
  - topical brimonidine gel may be considered for patients with predominant flushing but limited telangiectasia
  - brimonidine is a topical alpha-adrenergic agonist
  - this can be used on an 'as required basis' to temporarily reduce redness
  - it typically reduces redness within 30 minutes, reaching peak action at 3-6 hours, after which the redness returns to the baseline
- mild-to-moderate papules and/or pustules
  - topical ivermectin is first-line
  - alternatives include: topical metronidazole or topical azelaic acid
- moderate-to-severe papules and/or pustules
  - combination of topical ivermectin + oral doxycycline

Referral should be considered if

- symptoms have not improved with optimal management in primary care
  - laser therapy may be appropriate for patients with prominent telangiectasia
- patients with a rhinophyma

123

Next question

## Textbooks

High-yield textbook

Extended textbook

## Links

DermNet NZ 11 17

Rhinophyma

BNF 10 11

Acne rosacea

Dermnet NZ 23 13

Acne rosacea

Clinical Knowledge Summaries 19 10

Acne rosacea guidelines

Primary Care Dermatology Society 27 9

Rosacea review

Suggest link

Report broken link

Score: **28%**

1 ✗
2 ✓
3 ✓

| | |
|---|---|
| 4 | ✗ |
| 5 | ✗ |
| **6** | ✗ |
| 7 | ✗ |
| 8 | ✗ |
| 9 | ✗ |
| 10 | ✗ |
| 11 | ✗ |
| 12 | ✗ |
| 13 | ✓ |
| 14 | ✓ |
| 15 | ✓ |
| 16 | ✗ |
| 17 | ✓ |
| 18 | ✓ |
| 19 | ✗ |
| 20 | ✗ |
| 21 | ✗ |
| 22 | ✗ |
| 23 | ✗ |
| 24 | ✓ |
| 25 | ✗ |
| 26 | ✓ |
| 27 | ✗ |
| 28 | ✗ |
| 29 | ✗ |
| 30 | ✓ |
| 31 | ✗ |
| 32 | ✗ |
| 33 | ✗ |
| 34 | ✗ |
| 35 | ✓ |
| 36 | ✗ |
| 37 | ✗ |
| 38 | ✗ |
| 39 | ✗ |

| | |
|---|---|
| 40 | ✗ |
| 41 | ✗ |
| 42 | ✓ |
| 43 | ✗ |
| 44 | ✗ |
| 45 | ✓ |
| 46 | ✓ |
| 47 | ✗ |
| 48 | ✗ |
| 49 | ✗ |
| 50 | ✗ |

All contents of this site are © 2024 Passmedicine Limited

A 19-year-old man is referred to the dermatology clinic by his GP with a 2-week history of a rash over his torso. He has tried applying topical emollients but has seen no improvement in his symptoms. The rash is not painful and only mildly itchy. He denies any preceding illness or recent travel and there is no past medical history of note and no known allergies.

On examination, his observations are recorded within normal limits. His rash is examined, as shown below:

© Image used on license from DermNet NZ

Given the likely diagnosis, what is the recommended management for this patient?

- Oral phenoxymethylpenicillin
- Reassurance and discharge

- Topical 1% hydrocortisone
- Topical ketoconazole
- UVB phototherapy

Submit answer

Reference ranges

Score: **0%**

1 -
2 -
3 -
4 -
5 -
6 -
**7** -

All contents of this site are © 2024 Passmedicine Limited

A 19-year-old man is referred to the dermatology clinic by his GP with a 2-week history of a rash over his torso. He has tried applying topical emollients but has seen no improvement in his symptoms. The rash is not painful and only mildly itchy. He denies any preceding illness or recent travel and there is no past medical history of note and no known allergies.

On examination, his observations are recorded within normal limits. His rash is examined, as shown below:

© Image used on license from DermNet NZ

Given the likely diagnosis, what is the recommended management for this patient?

| | |
|---|---|
| Oral phenoxymethylpenicillin | 2% |
| Reassurance and discharge | 65% |

| | |
|---|---|
| Topical 1% hydrocortisone | 10% |
| Topical ketoconazole | 20% |
| UVB phototherapy | 3% |

**Reassurance and discharge** is correct. This patient has multiple small, oval-shaped, red plaques that are located on the trunk. Looking closely at these lesions, some appear to have a fine peripheral scale. This patient has a diagnosis of pityriasis rosea, a self-limiting rash that is characterised by a large round 'herald patch', usually found on the chest, abdomen, or back. It mostly affects children and young adults and is thought to be precipitated by bacterial and viral infections (e.g. human herpes virus 6 and 7).

**Oral phenoxymethylpenicillin** is incorrect. This is used in the treatment of Streptococcal infections (e.g. tonsillitis). Streptococcal infections are associated with guttate psoriasis that presents as an eruption of teardrop-shaped erythematous, scaly lesions. In contrast, the lesions of pityriasis rosea have a fine scale confined to the peripheries of the lesion. Furthermore, given the lack of signs of a streptococcal throat infection, phenoxymethylpenicillin is unlikely to be of any benefit.

**Topical 1% hydrocortisone** is incorrect. Topical corticosteroids are usually used in the treatment of eczematous diseases that typically present as a dry, itchy and scaly rash which is not seen here. They can also be used in the management of localised chronic plaque psoriasis. However, it plays no role in the management of pityriasis rosea.

**Topical ketoconazole** is incorrect. Topical ketoconazole is used in the treatment of fungal infections such as pityriasis versicolor. The rash is mostly seen on the trunk, neck and upper limbs. The patches can vary in colour from pink, brown to pale (typically paler than the surrounding skin). They are usually asymptomatic but can occasionally be itchy. Heat and moisture are risk factors for developing the rash.

**UVB phototherapy** is incorrect. This is used in the management of chronic plaque psoriasis and guttate psoriasis that cannot be controlled with initial topical management. However, it is not used in the management of pityriasis rosea.



## Pityriasis rosea

Pityriasis rosea describes an acute, self-limiting rash which tends to affect young adults. The aetiology is not fully understood but is thought that herpes hominis virus 7 (HHV-7) may play a role.

Features

- in the majority of patients there is no prodrome, but a minority may give a history of a recent viral infection
- herald patch (usually on trunk)
- followed by erythematous, oval, scaly patches which follow a characteristic distribution with the longitudinal diameters of the oval lesions running parallel to the line of Langer. This may produce a 'fir-tree' appearance

Management

- self-limiting - usually disappears after 6-12 weeks

## Differentiating guttate psoriasis and pityriasis rosea

| | Guttate psoriasis | Pityriasis rosea |
|---|---|---|
| **Prodrome** | Classically preceded by a streptococcal sore throat 2-4 weeks | Many patients report recent respiratory tract infections but this is not common in questions |
| **Appearance** | 'Tear drop', scaly papules on the trunk and limbs | Herald patch followed 1-2 weeks later by multiple erythematous, slightly raised oval lesions with a fine scale confined to the outer aspects of the lesions. |

| | Guttate psoriasis | Pityriasis rosea |
|---|---|---|
| | | May follow a characteristic distribution with the longitudinal diameters of the oval lesions running parallel to the line of Langer. This may produce a 'fir-tree' appearance |
| **Treatment / natural history** | Most cases resolve spontaneously within 2-3 months<br>Topical agents as per psoriasis<br>UVB phototherapy | Self-limiting, resolves after around 6 weeks |

+ Q 123

Next question >

## Textbooks

High-yield textbook

Extended textbook

## Links

Clinical Knowledge Summaries 9 6

Pityriasis rosea

DermNet NZ 11 4

Pityriasis rosea

Score: **28%**

| | |
|---|---|
| 1 | ✗ |
| 2 | ✓ |
| 3 | ✓ |
| 4 | ✗ |
| 5 | ✗ |
| 6 | ✗ |
| **7** | ✗ |
| 8 | ✗ |
| 9 | ✗ |
| 10 | ✗ |
| 11 | ✗ |
| 12 | ✗ |
| 13 | ✓ |
| 14 | ✓ |
| 15 | ✓ |
| 16 | ✗ |
| 17 | ✓ |
| 18 | ✓ |
| 19 | ✗ |
| 20 | ✗ |
| 21 | ✗ |
| 22 | ✗ |
| 23 | ✗ |
| 24 | ✓ |
| 25 | ✗ |
| 26 | ✓ |
| 27 | ✗ |
| 28 | ✗ |
| 29 | ✗ |

| | |
|---|---|
| 30 | ✓ |
| 31 | ✗ |
| 32 | ✗ |
| 33 | ✗ |
| 34 | ✗ |
| 35 | ✓ |
| 36 | ✗ |
| 37 | ✗ |
| 38 | ✗ |
| 39 | ✗ |
| 40 | ✗ |
| 41 | ✗ |
| 42 | ✓ |
| 43 | ✗ |
| 44 | ✗ |
| 45 | ✓ |
| 46 | ✓ |
| 47 | ✗ |
| 48 | ✗ |
| 49 | ✗ |
| 50 | ✗ |

All contents of this site are © 2024 Passmedicine Limited

Back to top

A 34-year-old man with a long history of back pain asks you to have a look at his back. His wife has noticed a rash.

© Image used on license from DermNet NZ

What is the most likely diagnosis?

- Pityriasis rosea
- Erythema multiforme
- Erythema ab igne
- Pityriasis versicolor
- Cold urticaria

Submit answer

Reference ranges

Score: **0%**

1 -
2 -
3 -
4 -
5 -
6 -
7 -
**8** -

All contents of this site are © 2024 Passmedicine Limited

A 34-year-old man with a long history of back pain asks you to have a look at his back. His wife has noticed a rash.

© Image used on license from DermNet NZ

What is the most likely diagnosis?

| | |
|---|---|
| Pityriasis rosea | 2% |
| Erythema multiforme | 2% |
| Erythema ab igne | 91% |
| Pityriasis versicolor | 5% |
| Cold urticaria | 1% |

This is a typical erythema ab igne rash. He may have been applying a hot water bottle to his lower back to try and relieve the pain.

Discuss (2) Improve

Next question

## Erythema ab igne

Erythema ab igne is a skin disorder caused by over exposure to infrared radiation. Characteristic features include reticulated, erythematous patches with hyperpigmentation and telangiectasia. A typical history would be an elderly women who always sits next to an open fire.

If the cause is not treated then patients may go on to develop squamous cell skin cancer.

© Image used on license from DermNet NZ

Erythema ab igne

© Image used on license from DermNet NZ

Erythema ab igne

123

Next question

## Textbooks

High-yield textbook

Extended textbook

## Links

DermNet NZ 7 5

Erythema ab igne

Suggest link

Report broken link

Score: **28%**

| | |
|---|---|
| 1 | ✗ |
| 2 | ✓ |
| 3 | ✓ |
| 4 | ✗ |
| 5 | ✗ |
| 6 | ✗ |
| 7 | ✗ |
| **8** | ✗ |
| 9 | ✗ |
| 10 | ✗ |
| 11 | ✗ |
| 12 | ✗ |
| 13 | ✓ |
| 14 | ✓ |
| 15 | ✓ |
| 16 | ✗ |
| 17 | ✓ |
| 18 | ✓ |
| 19 | ✗ |
| 20 | ✗ |
| 21 | ✗ |
| 22 | ✗ |
| 23 | ✗ |
| 24 | ✓ |
| 25 | ✗ |
| 26 | ✓ |
| 27 | ✗ |
| 28 | ✗ |
| 29 | ✗ |
| 30 | ✓ |
| 31 | ✗ |
| 32 | ✗ |

| | |
|---|---|
| 33 | ✗ |
| 34 | ✗ |
| 35 | ✓ |
| 36 | ✗ |
| 37 | ✗ |
| 38 | ✗ |
| 39 | ✗ |
| 40 | ✗ |
| 41 | ✗ |
| 42 | ✓ |
| 43 | ✗ |
| 44 | ✗ |
| 45 | ✓ |
| 46 | ✓ |
| 47 | ✗ |
| 48 | ✗ |
| 49 | ✗ |
| 50 | ✗ |

All contents of this site are © 2024 Passmedicine Limited
Back to top

A 22-year-old female with a background history of iron deficient anaemia and eczema presents with a skin rash. She takes ferrous sulphate 200mg twice daily but no other medication. On examination, she has an itchy bullous rash consisting of papules and blisters on the knees and elbows. Direct immunofluorescence of a skin biopsy shows immunoglobulin A (IgA) deposition in a granular pattern within the upper dermis. Which of the following would be the most appropriate treatment?

- Emollients and topical hydrocortisone
- Dapsone and a gluten-free diet
- Oral steroids
- Emollients and a vitamin D analogue
- A gluten-free diet and topical hydrocortisone

Submit answer

Reference ranges

Score: **0%**

1 -
2 -
3 -
4 -
5 -
6 -
7 -
8 -

| | |
|---|---|
| **9** | - |

All contents of this site are © 2024 Passmedicine Limited

Back to top

A 22-year-old female with a background history of iron deficient anaemia and eczema presents with a skin rash. She takes ferrous sulphate 200mg twice daily but no other medication. On examination, she has an itchy bullous rash consisting of papules and blisters on the knees and elbows. Direct immunofluorescence of a skin biopsy shows immunoglobulin A (IgA) deposition in a granular pattern within the upper dermis. Which of the following would be the most appropriate treatment?

| | |
|---|---|
| Emollients and topical hydrocortisone | 3% |
| Dapsone and a gluten-free diet | 78% |
| Oral steroids | 5% |
| Emollients and a vitamin D analogue | 1% |
| A gluten-free diet and topical hydrocortisone | 13% |

Dermatitis herpetiformis is typically treated with a gluten-free diet and topical dapsone

Important for me Less important

The clue here is the history of a young person who is iron-deficient and develops a rash which is not typical of eczema or psoriasis. Coeliac disease can often present with iron deficiency and no bowel manifestations and practitioners are lucky if their patient develops the characteristic rash of dermatitis herpetiformis, pointing them to the diagnosis.

Discuss Improve

Next question

## Dermatitis herpetiformis

Dermatitis herpetiformis is an autoimmune blistering skin disorder associated with coeliac disease. It is caused by deposition of IgA in the dermis. More than 90% of patients exhibit small bowel biopsy findings consistent with some degree of gluten-sensitive enteropathy.

Features

- itchy, vesicular skin lesions on the extensor surfaces (e.g. elbows, knees, buttocks)

Diagnosis

- skin biopsy: direct immunofluorescence shows deposition of IgA in a granular pattern in the upper dermis

Management

- gluten-free diet
- dapsone

123

Next question

**Textbooks**

High-yield textbook

Extended textbook

**Links**

DermNet NZ 👍 34 👎 6

Dermatitis herpetiformis

Suggest link | Report broken link

Score: **28%**

| | |
|---|---|
| 1 | ✗ |
| 2 | ✓ |
| 3 | ✓ |
| 4 | ✗ |
| 5 | ✗ |
| 6 | ✗ |
| 7 | ✗ |
| 8 | ✗ |
| **9** | ✗ |
| 10 | ✗ |
| 11 | ✗ |
| 12 | ✗ |
| 13 | ✓ |
| 14 | ✓ |
| 15 | ✓ |
| 16 | ✗ |
| 17 | ✓ |
| 18 | ✓ |
| 19 | ✗ |
| 20 | ✗ |
| 21 | ✗ |
| 22 | ✗ |
| 23 | ✗ |
| 24 | ✓ |
| 25 | ✗ |

| | |
|---|---|
| 26 | ✓ |
| 27 | ✗ |
| 28 | ✗ |
| 29 | ✗ |
| 30 | ✓ |
| 31 | ✗ |
| 32 | ✗ |
| 33 | ✗ |
| 34 | ✗ |
| 35 | ✓ |
| 36 | ✗ |
| 37 | ✗ |
| 38 | ✗ |
| 39 | ✗ |
| 40 | ✗ |
| 41 | ✗ |
| 42 | ✓ |
| 43 | ✗ |
| 44 | ✗ |
| 45 | ✓ |
| 46 | ✓ |
| 47 | ✗ |
| 48 | ✗ |
| 49 | ✗ |
| 50 | ✗ |

All contents of this site are © 2024 Passmedicine Limited

Back to top

A 82-year-old female is brought into hospital after she was witnessed by her carer to 'twitch all 4 limbs' and lose consciousness for about 5 minutes. She is known to have previously had a stroke, resulting in mild right sided weakness 5 years previously and is a type 2 diabetic. She is diagnosed with a first generalised seizure and is prescribed lamotrigine. Four days after her admission, whilst awaiting a new package of care, she complains of a sore throat. The next day, you note peeling skin from her bottom lip and a new erythematous, well-defined macule on her trunk. What is the most likely diagnosis?

- Stevens-Johnson syndrome
- MRSA cellulitis
- Impetigo
- Scabies
- Necrobiosis lipoidica

Submit answer

Reference ranges

Score: **0%**

1 -
2 -
3 -
4 -
5 -
6 -
7 -
8 -

| | |
|---|---|
| 9 | - |
| **10** | - |

All contents of this site are © 2024 Passmedicine Limited

A 82-year-old female is brought into hospital after she was witnessed by her carer to 'twitch all 4 limbs' and lose consciousness for about 5 minutes. She is known to have previously had a stroke, resulting in mild right sided weakness 5 years previously and is a type 2 diabetic. She is diagnosed with a first generalised seizure and is prescribed lamotrigine. Four days after her admission, whilst awaiting a new package of care, she complains of a sore throat. The next day, you note peeling skin from her bottom lip and a new erythematous, well-defined macule on her trunk. What is the most likely diagnosis?

| | |
|---|---|
| Stevens-Johnson syndrome | 91% |
| MRSA cellulitis | 1% |
| Impetigo | 4% |
| Scabies | 0% |
| Necrobiosis lipoidica | 4% |

The clinical syndrome of a sore throat, macular erythematous rash and mucous involvement is suggestive of Stevens-Johnson/ toxic epidermal necrolysis spectrum disorder.

Although Stevens-Johnson syndrome is a classic, well-recognised side effect of lamotrigine, it must be remembered that rashes commonly occur in up to 7% of all patients starting lamotrigine but only a small proportion develop Stevens-Johnson syndrome.

Discuss (4) Improve

Next question

## Stevens-Johnson syndrome

Stevens-Johnson syndrome is a severe systemic reaction affecting the skin and mucosa that is almost always caused by a drug reaction.

Previously it was thought that Stevens-Johnson syndrome (SJS) was a severe form of erythema multiforme. They are now however considered as separate entities.

Causes

- penicillin
- sulphonamides
- lamotrigine, carbamazepine, phenytoin
- allopurinol
- NSAIDs
- oral contraceptive pill

Features

- the rash is typically maculopapular with target lesions being characteristic
  - may develop into vesicles or bullae
  - Nikolsky sign is positive in erythematous areas - blisters and erosions appear when the skin is rubbed gently
- mucosal involvement
- systemic symptoms: fever, arthralgia

Management

- hospital admission is required for supportive treatment

+ Q 123

Next question >

B I A

Textbooks

High-yield textbook

Extended textbook

## Links

British Association of Dermatologists 5 7

2016 UK guidelines for the management of Stevens-Johnson syndrome/toxic epidermal necrolysis

Suggest link Report broken link

## Media

Stevensâ€"Johnson Syndrome & Toxic Epidermal Necrolysis

Osmosis - YouTube 2 0

Understanding Stevens-Johnson Syndrome and Toxic Epidermal Necrolysis

Osmosis - YouTube 0 0

Report broken media

Score: **28%**

1 ✗
2 ✓
3 ✓
4 ✗
5 ✗
6 ✗
7 ✗
8 ✗
9 ✗

| | |
|---|---|
| **10** | ✗ |
| 11 | ✗ |
| 12 | ✗ |
| 13 | ✓ |
| 14 | ✓ |
| 15 | ✓ |
| 16 | ✗ |
| 17 | ✓ |
| 18 | ✓ |
| 19 | ✗ |
| 20 | ✗ |
| 21 | ✗ |
| 22 | ✗ |
| 23 | ✗ |
| 24 | ✓ |
| 25 | ✗ |
| 26 | ✓ |
| 27 | ✗ |
| 28 | ✗ |
| 29 | ✗ |
| 30 | ✓ |
| 31 | ✗ |
| 32 | ✗ |
| 33 | ✗ |
| 34 | ✗ |
| 35 | ✓ |
| 36 | ✗ |
| 37 | ✗ |
| 38 | ✗ |
| 39 | ✗ |
| 40 | ✗ |
| 41 | ✗ |
| 42 | ✓ |
| 43 | ✗ |
| 44 | ✗ |
| 45 | ✓ |

46 ✓
47 ✗
48 ✗
49 ✗
50 ✗

All contents of this site are © 2024 Passmedicine Limited

PassMedicine

A 67-year-old man presents with a rough, scaly lesion on his nose. He has a long history of sun-related damage to his skin and has had similar lesions on his temples treated previously:

© Image used on license from DermNet NZ and with the kind permission of Prof Raimo Suhonen

Which one of the following is he at an increased risk of developing if the lesion is not treated?

- Pyoderma gangrenosum
- Seborrhoeic keratosis
- Malignant melanoma
- Basal cell carcinoma
- Squamous cell carcinoma

Submit answer

Reference ranges

Score: **0%**

| | |
|---|---|
| 1 | - |
| 2 | - |
| 3 | - |
| 4 | - |
| 5 | - |
| 6 | - |
| 7 | - |
| 8 | - |
| 9 | - |
| 10 | - |
| **11** | - |

All contents of this site are © 2024 Passmedicine Limited

A 67-year-old man presents with a rough, scaly lesion on his nose. He has a long history of sun-related damage to his skin and has had similar lesions on his temples treated previously:

© Image used on license from DermNet NZ and with the kind permission of Prof Raimo Suhonen

Which one of the following is he at an increased risk of developing if the lesion is not treated?

- Pyoderma gangrenosum 1%
- Seborrhoeic keratosis 13%
- Malignant melanoma 2%
- Basal cell carcinoma 13%
- Squamous cell carcinoma 72%

Actinic keratoses are premalignant lesions which may develop into squamous cell carcinomas if not treated.

Discuss Improve

Next question

# Actinic keratoses

Actinic, or solar, keratoses (AK) is a common premalignant skin lesion that develops as a consequence of chronic sun exposure

Features

- small, crusty or scaly, lesions
- may be pink, red, brown or the same colour as the skin
- typically on sun-exposed areas e.g. temples of head
- multiple lesions may be present

Management options include

- prevention of further risk: e.g. sun avoidance, sun cream
- fluorouracil cream: typically a 2 to 3 week course. The skin will become red and inflamed - sometimes topical hydrocortisone is given following fluorouracil to help settle the inflammation
- topical diclofenac: may be used for mild AKs. Moderate efficacy but much fewer side-effects
- topical imiquimod: trials have shown good efficacy
- cryotherapy
- curettage and cautery

123

Next question

### Textbooks

High-yield textbook

Extended textbook

### Links

British Association of Dermatologists 9 9

2017 Actinic keratoses guidelines

DermNet NZ 27 11

Actinic keratoses

Primary Care Dermatology Society 14 5

Actinic keratosis

Suggest link | Report broken link

Score: **28%**

| | |
|---|---|
| 1 | ✗ |
| 2 | ✓ |
| 3 | ✓ |
| 4 | ✗ |
| 5 | ✗ |
| 6 | ✗ |
| 7 | ✗ |
| 8 | ✗ |
| 9 | ✗ |
| 10 | ✗ |
| **11** | ✗ |
| 12 | ✗ |

| | |
|---|---|
| 13 | ✓ |
| 14 | ✓ |
| 15 | ✓ |
| 16 | ✗ |
| 17 | ✓ |
| 18 | ✓ |
| 19 | ✗ |
| 20 | ✗ |
| 21 | ✗ |
| 22 | ✗ |
| 23 | ✗ |
| 24 | ✓ |
| 25 | ✗ |
| 26 | ✓ |
| 27 | ✗ |
| 28 | ✗ |
| 29 | ✗ |
| 30 | ✓ |
| 31 | ✗ |
| 32 | ✗ |
| 33 | ✗ |
| 34 | ✗ |
| 35 | ✓ |
| 36 | ✗ |
| 37 | ✗ |
| 38 | ✗ |
| 39 | ✗ |
| 40 | ✗ |
| 41 | ✗ |
| 42 | ✓ |
| 43 | ✗ |
| 44 | ✗ |
| 45 | ✓ |
| 46 | ✓ |
| 47 | ✗ |
| 48 | ✗ |

49 ✕

50 ✕

All contents of this site are © 2024 Passmedicine Limited

A 45-year-old woman is admitted with hallucinations. She has a long history of alcohol dependency and is being treated by her GP for hypothyroidism. Further questioning of her husband reveals a 3-month history of diarrhoea, difficulty swallowing and an itchy rash on her arms. Prior to this she had been irritable and suffered from regular bouts of vomiting.

The examination is limited as the patient is aggressive . There is a pigmented, scaly rash on her arms and neck. Heart sounds are normal, her chest is clear and her abdomen soft. Neurological examination reveals generalised weakness.

Blood tests show:

| | |
|---|---|
| Hb | 142 g/l |
| Platelets | 200 * $10^9$/l |
| WBC | 5.3 * $10^9$/l |

| | |
|---|---|
| $Na^+$ | 140 mmol/l |
| $K^+$ | 4.2 mmol/l |
| Urea | 6 mmol/l |
| Creatinine | 84 µmol/l |

| | |
|---|---|
| TSH | 4.0 U/mL |
| Free T3 | 3.1 pg/mL |
| Free T4 | 1.5 ng/L |

What is the most likely diagnosis?

- Beriberi
- Thyroxine toxicity
- Systemic lupus erythematosus (SLE)
- Pellagra

Darier's disease

Submit answer

Reference ranges

Score: **0%**

1 -
2 -
3 -
4 -
5 -
6 -
7 -
8 -
9 -
10 -
11 -
**12** -

All contents of this site are © 2024 Passmedicine Limited

A 45-year-old woman is admitted with hallucinations. She has a long history of alcohol dependency and is being treated by her GP for hypothyroidism. Further questioning of her husband reveals a 3-month history of diarrhoea, difficulty swallowing and an itchy rash on her arms. Prior to this she had been irritable and suffered from regular bouts of vomiting.

The examination is limited as the patient is aggressive . There is a pigmented, scaly rash on her arms and neck. Heart sounds are normal, her chest is clear and her abdomen soft. Neurological examination reveals generalised weakness.

Blood tests show:

| | |
|---|---|
| Hb | 142 g/l |
| Platelets | 200 * $10^9$/l |
| WBC | 5.3 * $10^9$/l |

| | |
|---|---|
| $Na^+$ | 140 mmol/l |
| $K^+$ | 4.2 mmol/l |
| Urea | 6 mmol/l |
| Creatinine | 84 µmol/l |

| | |
|---|---|
| TSH | 4.0 U/mL |
| Free T3 | 3.1 pg/mL |
| Free T4 | 1.5 ng/L |

What is the most likely diagnosis?

- Beriberi 8%
- Thyroxine toxicity 1%
- Systemic lupus erythematosus (SLE) 1%
- Pellagra 86%

Darier's disease 4%

Niacin (B3) deficiency is characterised by dermatitis, diarrhoea and dementia, a condition known as pellagra

Important for me Less important

This lady has pellagra, caused by niacin (vitamin B3) deficiency. It occurs primarily in countries such as India and China, in which corn is a staple food. In the UK it is uncommon, and largely seen in patients with alcohol dependency or anorexia nervosa. Niacin is absorbed from foods such as beans and eggs and is also converted from amino acid tryptophan. Pellagra may manifest in carcinoid syndrome, in which tryptophan is converted to serotonin.

Over-treatment or deliberate overdose of thyroxine could cause some of this patient's symptoms, but her thyroid function tests are normal. SLE and Darier's disease both cause a light-sensitive rash, but would not cause the gastrointestinal symptoms. Cognitive disturbance may be seen in SLE.

Pellagra is distinguished from beriberi by the presence of a rash and gastrointestinal symptoms. Like beriberi, it can lead to confusion and memory deficits. Alcoholic patients may, of course, present with both. Other signs include dilated cardiomyopathy, oesophagitis and ataxia.

Discuss (3) Improve

Next question >

## Pellagra

Pellagra is a caused by nicotinic acid (niacin) deficiency. The classical features are the 3 D's - dermatitis, diarrhoea and dementia.

Pellagra may occur as a consequence of isoniazid therapy (isoniazid inhibits the conversion of tryptophan to niacin) and it is more common in alcoholics.

Features

- dermatitis (brown scaly rash on sun-exposed sites - termed Casal's necklace if around neck)
- diarrhoea
- dementia, depression
- death if not treated

123

Next question

## Textbooks

High-yield textbook

Extended textbook

## Links

DermNet NZ 8 2

Pellagra

Suggest link Report broken link

Score: **28%**

| | |
|---|---|
| 1 | ✗ |
| 2 | ✓ |
| 3 | ✓ |
| 4 | ✗ |
| 5 | ✗ |
| 6 | ✗ |
| 7 | ✗ |
| 8 | ✗ |

| | |
|---|---|
| 9 | ✗ |
| 10 | ✗ |
| 11 | ✗ |
| **12** | ✗ |
| 13 | ✓ |
| 14 | ✓ |
| 15 | ✓ |
| 16 | ✗ |
| 17 | ✓ |
| 18 | ✓ |
| 19 | ✗ |
| 20 | ✗ |
| 21 | ✗ |
| 22 | ✗ |
| 23 | ✗ |
| 24 | ✓ |
| 25 | ✗ |
| 26 | ✓ |
| 27 | ✗ |
| 28 | ✗ |
| 29 | ✗ |
| 30 | ✓ |
| 31 | ✗ |
| 32 | ✗ |
| 33 | ✗ |
| 34 | ✗ |
| 35 | ✓ |
| 36 | ✗ |
| 37 | ✗ |
| 38 | ✗ |
| 39 | ✗ |
| 40 | ✗ |
| 41 | ✗ |
| 42 | ✓ |
| 43 | ✗ |
| 44 | ✗ |

| | |
|---|---|
| 45 | ✓ |
| 46 | ✓ |
| 47 | ✗ |
| 48 | ✗ |
| 49 | ✗ |
| 50 | ✗ |

All contents of this site are © 2024 Passmedicine Limited

A 60-year-old man presents with a lesion on his back which has increased in size over the past year. His past medical history includes ischaemic heart disease and spinal stenosis. There is no personal or family history of skin cancer.

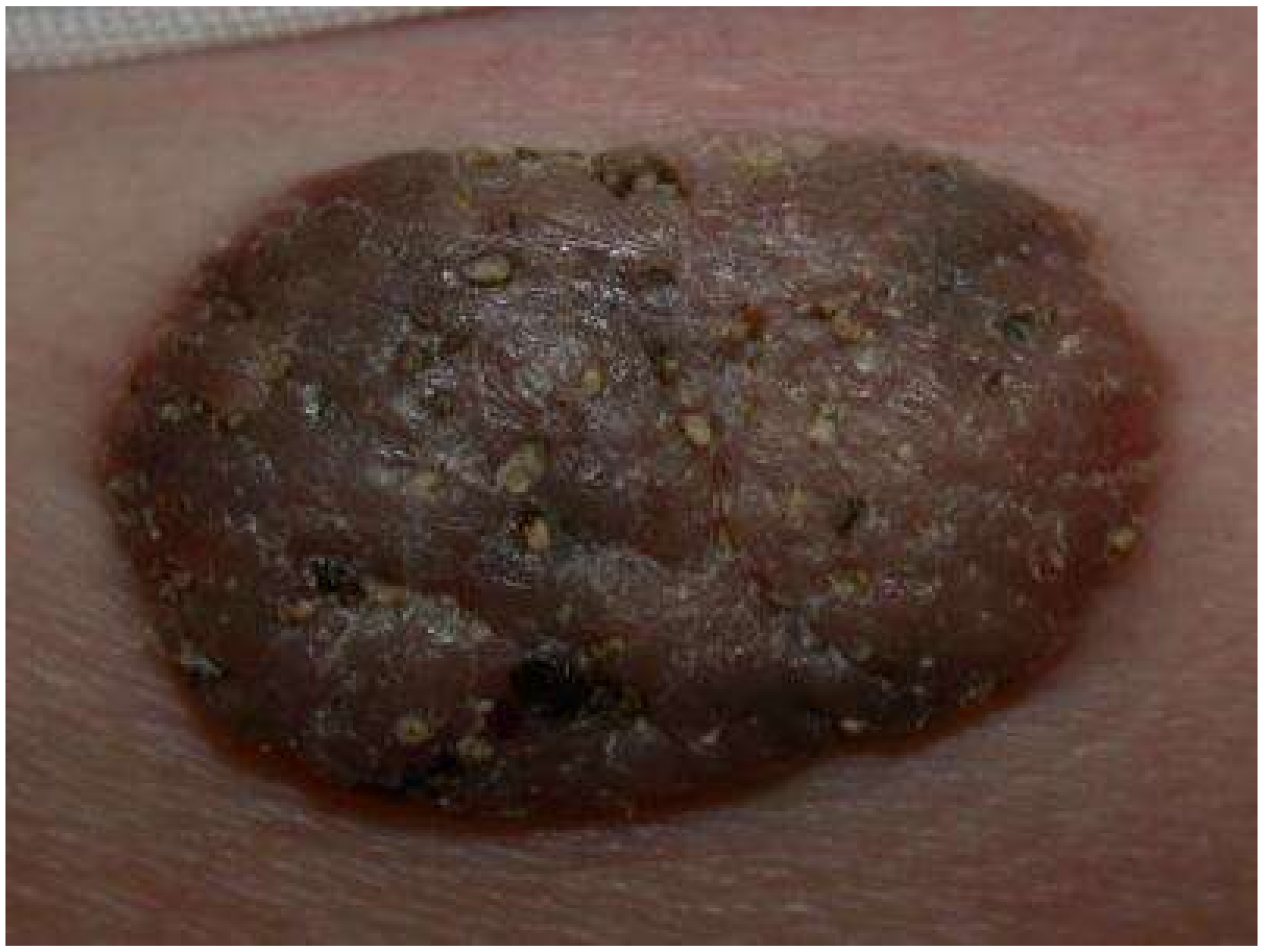

© Image used on license from DermNet NZ

What is the most likely diagnosis?

- Malignant melanoma
- Seborrhoeic keratosis
- Bowen's disease
- Dermatosis papulosa nigra
- Actinic keratosis

Submit answer

Reference ranges

Score: **0%**

1 -
2 -
3 -
4 -
5 -
6 -
7 -
8 -
9 -
10 -
11 -
12 -
**13** -

All contents of this site are © 2024 Passmedicine Limited

A 60-year-old man presents with a lesion on his back which has increased in size over the past year. His past medical history includes ischaemic heart disease and spinal stenosis. There is no personal or family history of skin cancer.

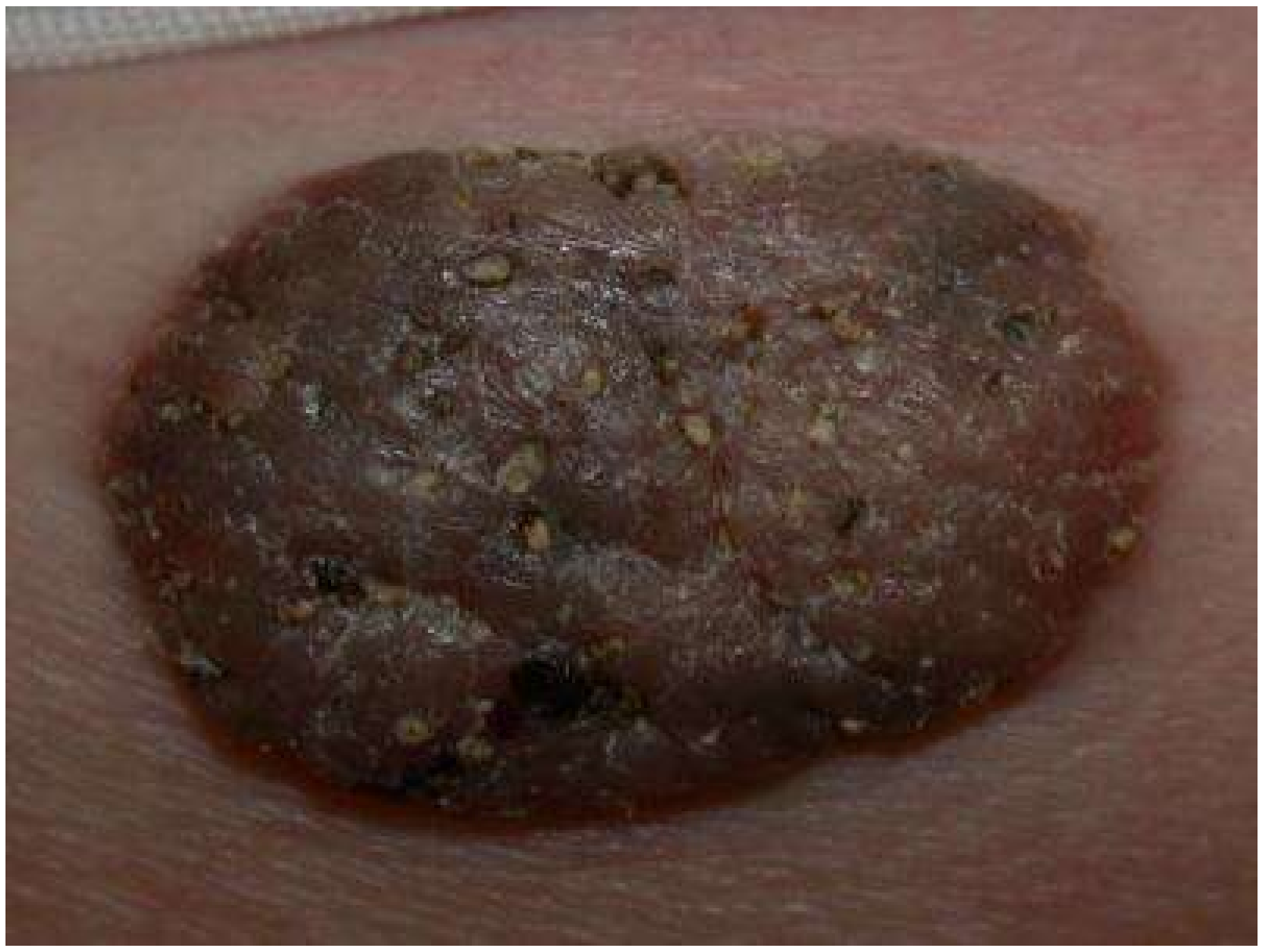

© Image used on license from DermNet NZ

What is the most likely diagnosis?

- Malignant melanoma 12%
- **Seborrhoeic keratosis 58%**
- Bowen's disease 7%
- Dermatosis papulosa nigra 18%
- Actinic keratosis 5%

Discuss (2) Improve

Next question

# Seborrhoeic keratoses

Seborrhoeic keratoses are benign epidermal skin lesions seen in older people.

Features
- large variation in colour from flesh to light-brown to black
- have a 'stuck-on' appearance
- keratotic plugs may be seen on the surface

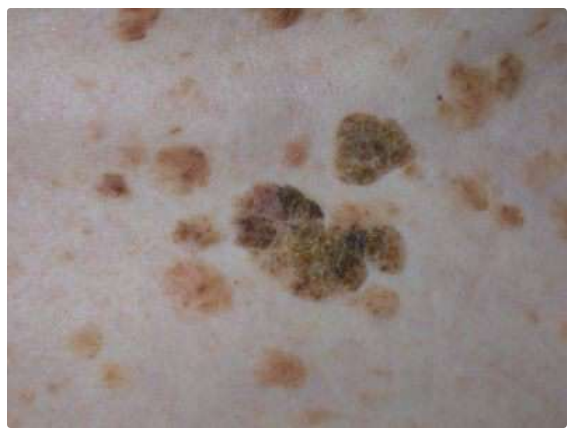

Management
- reassurance about the benign nature of the lesion is an option
- options for removal include curettage, cryosurgery and shave biopsy

AI + Q 123

Next question

**Textbooks**

High-yield textbook

Extended textbook

**Links**

DermNet NZ 5 5

Seborrhoeic keratoses

Suggest link Report broken link

Score: **28%**

| | |
|---|---|
| 1 | ✗ |
| 2 | ✓ |
| 3 | ✓ |
| 4 | ✗ |
| 5 | ✗ |
| 6 | ✗ |
| 7 | ✗ |
| 8 | ✗ |
| 9 | ✗ |
| 10 | ✗ |
| 11 | ✗ |
| 12 | ✗ |
| **13** | ✓ |
| 14 | ✓ |
| 15 | ✓ |
| 16 | ✗ |
| 17 | ✓ |
| 18 | ✓ |
| 19 | ✗ |
| 20 | ✗ |
| 21 | ✗ |
| 22 | ✗ |
| 23 | ✗ |
| 24 | ✓ |
| 25 | ✗ |
| 26 | ✓ |

| | |
|---|---|
| 27 | ✗ |
| 28 | ✗ |
| 29 | ✗ |
| 30 | ✓ |
| 31 | ✗ |
| 32 | ✗ |
| 33 | ✗ |
| 34 | ✗ |
| 35 | ✓ |
| 36 | ✗ |
| 37 | ✗ |
| 38 | ✗ |
| 39 | ✗ |
| 40 | ✗ |
| 41 | ✗ |
| 42 | ✓ |
| 43 | ✗ |
| 44 | ✗ |
| 45 | ✓ |
| 46 | ✓ |
| 47 | ✗ |
| 48 | ✗ |
| 49 | ✗ |
| 50 | ✗ |

All contents of this site are © 2024 Passmedicine Limited

Back to top

A 36-year-old presents with a 4 months history of episodic generalised abdominal discomfort, nausea and vomiting. He reports no gastrointestinal symptoms prior to this period. He denies eating any unusual foods or recent travel within the past 2 years. His diarrhoea appears to be watery and he denies any blood stools. Eight months ago, he underwent a bone densimetry scan after breaking his hip and both femurs playing football, revealing a T-score of <-2.8. On examination, you notice brown papules, measuring 2 to 3 mm on each lower leg. When you press along the lesion and the surrounding skin, you note a red raised line is elicited. Abdominal examination reveals hepatosplenomegaly. His admission blood tests are as follows:

| | |
|---|---|
| Hb | 98 g/l |
| Platelets | 195 * $10^9$/l |
| WBC | 4.9 * $10^9$/l |
| ESR | 70 mm/hr |

| | |
|---|---|
| $Na^+$ | 138 mmol/l |
| $K^+$ | 4.6 mmol/l |
| Adjusted calcium | 2.81 mmol/l |
| Phosphate | 1.3 mmol/l |
| CRP | 22 mg/l |
| Serum tryptase 379 ng/ml (< 20) | |
| Complement | normal |
| C1 inhibitor | normal |
| Serum gastrin | normal |
| 24 hour urinary 5-HIAA | normal |

What is the most likely unifying diagnosis?

- Zollinger-Ellison syndrome
- Carcinoid syndrome
- Hereditary angioedema

- Cutaneous mastocytosis
- Systemic mastocytosis

Submit answer

Reference ranges

Score: **0%**

| | |
|---|---|
| 1 | - |
| 2 | - |
| 3 | - |
| 4 | - |
| 5 | - |
| 6 | - |
| 7 | - |
| 8 | - |
| 9 | - |
| 10 | - |
| 11 | - |
| 12 | - |
| 13 | - |
| **14** | - |

All contents of this site are © 2024 Passmedicine Limited

A 36-year-old presents with a 4 months history of episodic generalised abdominal discomfort, nausea and vomiting. He reports no gastrointestinal symptoms prior to this period. He denies eating any unusual foods or recent travel within the past 2 years. His diarrhoea appears to be watery and he denies any blood stools. Eight months ago, he underwent a bone densimetry scan after breaking his hip and both femurs playing football, revealing a T-score of <-2.8. On examination, you notice brown papules, measuring 2 to 3 mm on each lower leg. When you press along the lesion and the surrounding skin, you note a red raised line is elicited. Abdominal examination reveals hepatosplenomegaly. His admission blood tests are as follows:

| | |
|---|---|
| Hb | 98 g/l |
| Platelets | 195 * $10^9$/l |
| WBC | 4.9 * $10^9$/l |
| ESR | 70 mm/hr |

| | |
|---|---|
| $Na^+$ | 138 mmol/l |
| $K^+$ | 4.6 mmol/l |
| Adjusted calcium | 2.81 mmol/l |
| Phosphate | 1.3 mmol/l |
| CRP | 22 mg/l |
| Serum tryptase 379 ng/ml (< 20) | |
| Complement | normal |
| C1 inhibitor | normal |
| Serum gastrin | normal |
| 24 hour urinary 5-HIAA | normal |

What is the most likely unifying diagnosis?

- Zollinger-Ellison syndrome 5%
- Carcinoid syndrome 6%
- Hereditary angioedema 4%

Cutaneous mastocytosis 12%

Systemic mastocytosis 72%

Localised erythema and urticaria on scratching, rubbing or stroking of the skin as described is classically known as Darier's sign, a manifestation of mast cell mediator release following physical irritation, classically seen in mastocytosis, a disorder of excessive mast cells. The next distinction is whether this represents symptoms limited to the skin or involves extracutaneous sites, hence the classification of cutaneous and systemic mastocytosis respectively. Systemic symptoms are a result of mast cell mediator and IgE release, which can cause gastrointestinal, neuropsychiatric and anaphylactic symptoms. A mild anaemia, as in this patient, is common in half of all systemic mastocytosis patients. Infiltration of spleen, liver and lymph nodes are noted in physical examinations as organomegaly. Excessive bleeding can also be an issue as a result of excess heparin release from mast cells. Osteoporosis in young patients should make you suspicious of bone marrow involvement.

Diagnosis of cutaneous mastocytosis is made upon signs and symptoms alone. Systemic mastocytosis is diagnosed according to a WHO criteria of major and minor symptoms: the major criterion involves the presence of mast cells in extracutaneous organs such as the liver and bone marrow, while minor criteria relies on serum tryptase over 20, surface markers of mast cells, atypical bone marrow mast cell morphology and a specific kit mutation. In the case of this patient, serum tryptase is significantly elevated in association with systemic involvement.

An important differential is that of hereditary angioedema, caused by a deficiency of C1 inhibitor deficiency and transient painful episodes of skin, laryngeal and bowel oedema. In this case, C1 inhibitor and complement are normal. Similarly, carcinoid syndrome should produce increased levels of urinary 24 hour 5HIAA secondary to excessive serotonin release. Lastly, Zollinger-Ellison syndrome only rarely presents with diarrhoea. Serum tryptase is almost always normal with elevated gastrin levels.

Discuss (2) | Improve

Next question

# Systemic mastocytosis

Systemic mastocytosis results from a neoplastic proliferation of mast cells

Features

- urticaria pigmentosa - produces a wheal on rubbing (Darier's sign)

- flushing
- abdominal pain
- monocytosis on the blood film

Diagnosis

- raised serum tryptase levels
- urinary histamine

123

Next question >

**Textbooks**

High-yield textbook

Extended textbook

Score: **28%**

| | |
|---|---|
| 1 | ✗ |
| 2 | ✓ |
| 3 | ✓ |
| 4 | ✗ |
| 5 | ✗ |
| 6 | ✗ |
| 7 | ✗ |
| 8 | ✗ |

| | |
|---|---|
| 9 | ✗ |
| 10 | ✗ |
| 11 | ✗ |
| 12 | ✗ |
| 13 | ✓ |
| **14** | ✓ |
| 15 | ✓ |
| 16 | ✗ |
| 17 | ✓ |
| 18 | ✓ |
| 19 | ✗ |
| 20 | ✗ |
| 21 | ✗ |
| 22 | ✗ |
| 23 | ✗ |
| 24 | ✓ |
| 25 | ✗ |
| 26 | ✓ |
| 27 | ✗ |
| 28 | ✗ |
| 29 | ✗ |
| 30 | ✓ |
| 31 | ✗ |
| 32 | ✗ |
| 33 | ✗ |
| 34 | ✗ |
| 35 | ✓ |
| 36 | ✗ |
| 37 | ✗ |
| 38 | ✗ |
| 39 | ✗ |
| 40 | ✗ |
| 41 | ✗ |
| 42 | ✓ |
| 43 | ✗ |
| 44 | ✗ |

| | |
|---|---|
| 45 | ✓ |
| 46 | ✓ |
| 47 | ✗ |
| 48 | ✗ |
| 49 | ✗ |
| 50 | ✗ |

All contents of this site are © 2024 Passmedicine Limited

PassMedicine



A 27-year-old woman who is 34 weeks pregnant presents with an itchy, blistering rash over her abdomen. Initially she had a red rash around her umbilicus but it later spread.

© Image used on license from DermNet NZ

What is the most likely diagnosis?

- Pemphigoid gestationis
- Seborrhoeic dermatitis
- Polymorphic eruption of pregnancy
- HELLP syndrome
- Pompholyx

Submit answer

Reference ranges

Score: **0%**

| | |
|---|---|
| 1 | - |
| 2 | - |
| 3 | - |
| 4 | - |
| 5 | - |
| 6 | - |
| 7 | - |
| 8 | - |
| 9 | - |
| 10 | - |
| 11 | - |
| 12 | - |
| 13 | - |
| 14 | - |
| **15** | - |

All contents of this site are © 2024 Passmedicine Limited

Back to top

A 27-year-old woman who is 34 weeks pregnant presents with an itchy, blistering rash over her abdomen. Initially she had a red rash around her umbilicus but it later spread.

© Image used on license from DermNet NZ

What is the most likely diagnosis?

| | |
|---|---|
| Pemphigoid gestationis | 70% |
| Seborrhoeic dermatitis | 1% |
| Polymorphic eruption of pregnancy | 28% |
| HELLP syndrome | 0% |
| Pompholyx | 2% |

The correct diagnosis for this patient is **Pemphigoid gestationis**. This condition, also known as Herpes gestationis, is a rare autoimmune blistering disorder that occurs in pregnancy. It typically presents during the second or third trimester with pruritic, urticarial plaques and tense vesicles or bullae. The rash often starts around the umbilicus and then spreads to other parts of the body, which matches the description provided in the question. There may be remissions and exacerbations throughout pregnancy, with flares often occurring at delivery.

**Seborrhoeic dermatitis** is an incorrect answer. While it can cause an itchy rash, it typically affects

areas of the body rich in sebaceous glands such as the scalp, eyebrows, sides of the nose and behind ears rather than the abdomen. Moreover, its presentation does not include blisters.

**Polymorphic eruption of pregnancy**, formerly known as PUPPP (pruritic urticarial papules and plaques of pregnancy), is another incorrect option. Although it does present with intense itching during late pregnancy, its distinguishing feature is that it usually spares the umbilical area - unlike in this case where the rash started from around the umbilicus.

**HELLP syndrome** (Hemolysis Elevated Liver enzymes Low Platelet count) is also not correct. HELLP syndrome is a severe form of pre-eclampsia characterised by haemolysis, elevated liver enzymes and low platelet count. It may sometimes present with epigastric or right upper quadrant pain due to liver swelling but a blistering rash would not be a typical presentation.

Lastly, **Pompholyx**, also known as dyshidrotic eczema, primarily affects hands and feet causing small blisters along the sides of fingers or toes as well as palms or soles - not the abdomen or around the umbilicus which makes it an unlikely diagnosis for this case scenario.

Discuss (1) Improve

Next question

## Skin disorders associated with pregnancy

Atopic eruption of pregnancy

- is the commonest skin disorder found in pregnancy
- it typically presents as an eczematous, itchy red rash.
- no specific treatment is needed

Polymorphic eruption of pregnancy

- pruritic condition associated with last trimester
- lesions often first appear in abdominal striae
- management depends on severity: emollients, mild potency topical steroids and oral steroids may be used

© Image used on license from DermNet NZ

Polymorphic eruption of pregnancy

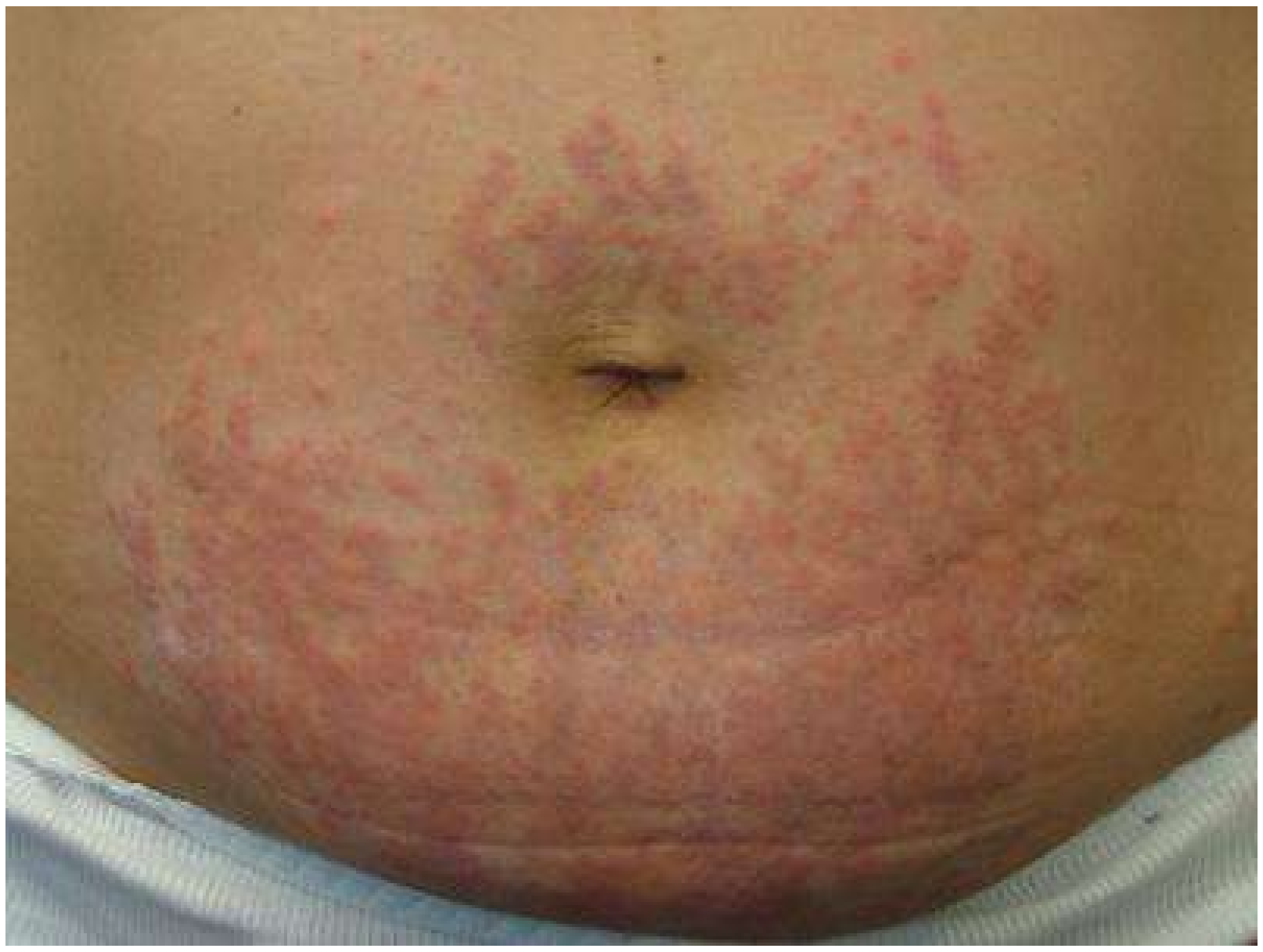

© Image used on license from DermNet NZ

Polymorphic eruption of pregnancy

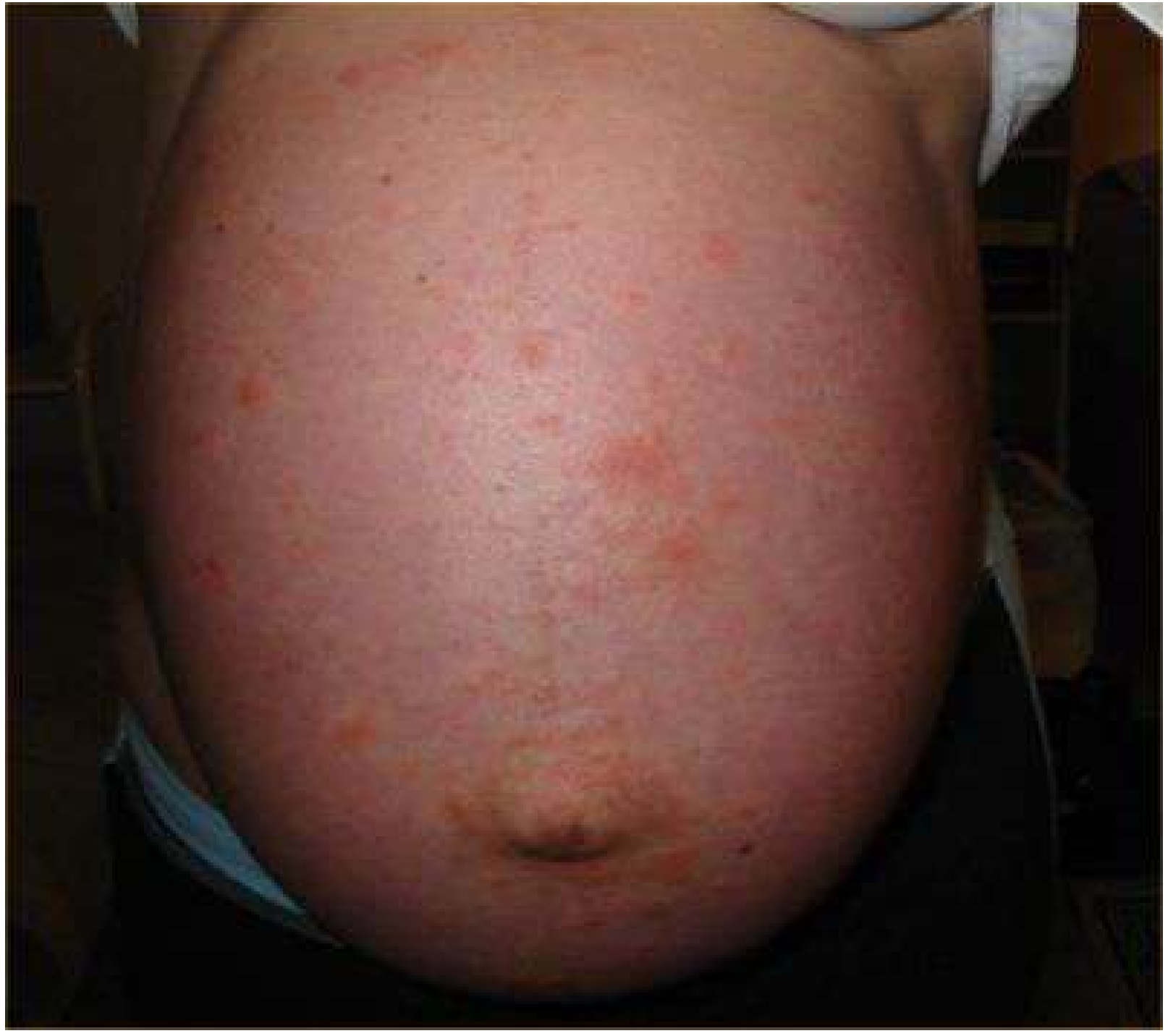

Polymorphic eruption of pregnancy

Pemphigoid gestationis

- pruritic blistering lesions
- often develop in peri-umbilical region, later spreading to the trunk, back, buttocks and arms
- usually presents 2nd or 3rd trimester and is rarely seen in the first pregnancy
- oral corticosteroids are usually required

© Image used on license from DermNet NZ

Pemphigoid gestationis

© Image used on license from DermNet NZ

Pemphigoid gestationis

123

Next question

## Textbooks

High-yield textbook

Extended textbook

## Links

DermNet NZ 13 5

Pemphigoid gestationis

DermNet NZ 11 4

Polymorphic eruption of pregnancy

Suggest link | Report broken link

Score: **28%**

| | |
|---|---|
| 1 | ✗ |
| 2 | ✓ |
| 3 | ✓ |
| 4 | ✗ |
| 5 | ✗ |
| 6 | ✗ |
| 7 | ✗ |
| 8 | ✗ |
| 9 | ✗ |
| 10 | ✗ |
| 11 | ✗ |
| 12 | ✗ |
| 13 | ✓ |
| 14 | ✓ |
| **15** | ✓ |
| 16 | ✗ |
| 17 | ✓ |
| 18 | ✓ |
| 19 | ✗ |
| 20 | ✗ |
| 21 | ✗ |
| 22 | ✗ |
| 23 | ✗ |
| 24 | ✓ |
| 25 | ✗ |
| 26 | ✓ |
| 27 | ✗ |
| 28 | ✗ |

| | |
|---|---|
| 29 | ✗ |
| 30 | ✓ |
| 31 | ✗ |
| 32 | ✗ |
| 33 | ✗ |
| 34 | ✗ |
| 35 | ✓ |
| 36 | ✗ |
| 37 | ✗ |
| 38 | ✗ |
| 39 | ✗ |
| 40 | ✗ |
| 41 | ✗ |
| 42 | ✓ |
| 43 | ✗ |
| 44 | ✗ |
| 45 | ✓ |
| 46 | ✓ |
| 47 | ✗ |
| 48 | ✗ |
| 49 | ✗ |
| 50 | ✗ |

All contents of this site are © 2024 Passmedicine Limited

Back to top

Please look at the image below:

© Image used on license from DermNet NZ

Which one of the following is LEAST likely to have a role in the management of this patient?

- Sun block
- Topical tacrolimus
- Phototherapy
- Topical ketoconazole
- Topical corticosteroids

Submit answer

Reference ranges

Score: **0%**

| | |
|---|---|
| 1 | - |
| 2 | - |
| 3 | - |
| 4 | - |
| 5 | - |
| 6 | - |
| 7 | - |
| 8 | - |
| 9 | - |
| 10 | - |
| 11 | - |
| 12 | - |
| 13 | - |
| 14 | - |
| 15 | - |
| **16** | - |

All contents of this site are © 2024 Passmedicine Limited

Back to top

Please look at the image below:

© Image used on license from DermNet NZ

Which one of the following is LEAST likely to have a role in the management of this patient?

| | |
|---|---|
| Sun block | 5% |
| Topical tacrolimus | 6% |
| Phototherapy | 12% |
| Topical ketoconazole | 70% |
| Topical corticosteroids | 7% |

There is no role for antifungal therapy in vitiligo.

Discuss (2) Improve

Next question

# Vitiligo

Vitiligo is an autoimmune condition which results in the loss of melanocytes and consequent depigmentation of the skin. It is thought to affect around 1% of the population and symptoms typically develop by the age of 20-30 years.

Associated conditions

- type 1 diabetes mellitus
- Addison's disease
- autoimmune thyroid disorders
- pernicious anaemia
- alopecia areata

Features

- well-demarcated patches of depigmented skin
- the peripheries tend to be most affected
- trauma may precipitate new lesions (Koebner phenomenon)

Management

- sunblock for affected areas of skin
- camouflage make-up
- topical corticosteroids may reverse the changes if applied early
- there may also be a role for topical tacrolimus and phototherapy, although caution needs to be exercised with light-skinned patients

123

Next question

## Textbooks

High-yield textbook

Extended textbook

## Links

DermNet NZ 8 3

Vitiligo

Suggest link Report broken link

## Media

Vitiligo

Osmosis - YouTube 0 1

Report broken media

Score: **28%**

| | |
|---|---|
| 1 | ✗ |
| 2 | ✓ |
| 3 | ✓ |
| 4 | ✗ |
| 5 | ✗ |
| 6 | ✗ |
| 7 | ✗ |

| | |
|---|---|
| 8 | ✗ |
| 9 | ✗ |
| 10 | ✗ |
| 11 | ✗ |
| 12 | ✗ |
| 13 | ✓ |
| 14 | ✓ |
| 15 | ✓ |
| **16** | ✗ |
| 17 | ✓ |
| 18 | ✓ |
| 19 | ✗ |
| 20 | ✗ |
| 21 | ✗ |
| 22 | ✗ |
| 23 | ✗ |
| 24 | ✓ |
| 25 | ✗ |
| 26 | ✓ |
| 27 | ✗ |
| 28 | ✗ |
| 29 | ✗ |
| 30 | ✓ |
| 31 | ✗ |
| 32 | ✗ |
| 33 | ✗ |
| 34 | ✗ |
| 35 | ✓ |
| 36 | ✗ |
| 37 | ✗ |
| 38 | ✗ |
| 39 | ✗ |
| 40 | ✗ |
| 41 | ✗ |
| 42 | ✓ |
| 43 | ✗ |

| | |
|---|---|
| 44 | ✗ |
| 45 | ✓ |
| 46 | ✓ |
| 47 | ✗ |
| 48 | ✗ |
| 49 | ✗ |
| 50 | ✗ |

All contents of this site are © 2024 Passmedicine Limited

A 63-year-old woman presents with an itchy rash on her arms and legs and also mentions that she has a white discolouration on her tongue and cheeks. The rash has been present for the last 2 months and over-the-counter emollients have not helped. This woman works in a bakery and wears gloves but she took the last 2 weeks off work. Also, she has been in a stable relationship since her divorce 10 years ago.

© Image used on license from DermNet NZ

What is the most likely diagnosis?

- Eczema
- Lichen planus
- Lichen simplex
- Prurigo nodularis
- Syphilis

Submit answer

Reference ranges

Score: **0%**

| | |
|---|---|
| 1 | - |
| 2 | - |
| 3 | - |
| 4 | - |
| 5 | - |
| 6 | - |
| 7 | - |
| 8 | - |
| 9 | - |
| 10 | - |
| 11 | - |
| 12 | - |
| 13 | - |
| 14 | - |
| 15 | - |
| 16 | - |
| **17** | - |

All contents of this site are © 2024 Passmedicine Limited

A 63-year-old woman presents with an itchy rash on her arms and legs and also mentions that she has a white discolouration on her tongue and cheeks. The rash has been present for the last 2 months and over-the-counter emollients have not helped. This woman works in a bakery and wears gloves but she took the last 2 weeks off work. Also, she has been in a stable relationship since her divorce 10 years ago.

© Image used on license from DermNet NZ

What is the most likely diagnosis?

| | |
|---|---|
| Eczema | 1% |
| Lichen planus | 74% |
| Lichen simplex | 7% |
| Prurigo nodularis | 17% |
| Syphilis | 2% |

The image shows a typical lichen planus rash. The image shows a plaque-like erythematous rash distributed on the hand, arm, and leg. There are some small areas of desquamation where the skin

appears peeled and exposes the dermal layer (most prominently here on the proximal arm). Lichen planus can also be described as having shiny red or purple papules although it is difficult to tell if any lesions are raised in this image.

**Lichen planus** - this is the correct answer. This typically affects people over 40 years old and about 50% of cases affect the oral mucosa. Fine white or grey lines or dots may be seen overlying the rash and oral mucosal lesions, otherwise named Wickham's striae. The cause is not well understood but it is thought to be a T-cell-mediated immune disorder. The diagnosis is mainly clinical but a skin biopsy will show globular deposits and T-cell infiltration. Most cases resolve spontaneously within a year but topical steroids can help with symptoms.

**Eczema** - this is incorrect as eczema can appear with excoriations and lichenification, there is often more involvement on the flexor surfaces. Topical steroids and emollients are the treatment. It might be expected that emollient use or staying away from working at the bakery would help (contact allergen) instead of the history in the stem.

**Lichen simplex** - this is incorrect. In lichen simplex, one or more plaques with lichenification will appear in an area that is heavily scratched. The itch/scratch cycle perpetuates the rash. Topical steroids and scratch avoidance are the treatment.

**Prurigo nodularis** - this is incorrect as this will appear as pruritic nodules often on the extremities. This is a chronic skin condition characterised by very itchy firm lumps. It can appear anywhere on the body but is most common in a symmetrical distribution on the arms, legs, back, and torso. There is a correlation between prurigo nodularis with atopy and internal disease.

**Syphilis** - this is incorrect. Syphilis is caused by the spirochete *Treponema pallidum*. It is primarily sexually transmitted and can cause many signs and symptoms similar to other diseases and so is nicknamed 'the great imitator'. This kind of rash is more typical of secondary infection which follows an incubation period of 10-90 days. One would expect other symptoms to accompany this stage like fever, headache, malaise, myalgia, arthralgia, and lymphadenopathy. There is no likely history of any sexual transmission or other systemic symptoms in the stem, making this answer less likely.

Discuss Improve

Next question

## Lichen planus

Lichen planus is a skin disorder of unknown aetiology, most probably being immune-mediated.

Features

- itchy, papular rash most common on the palms, soles, genitalia and flexor surfaces of arms
- rash often polygonal in shape, with a 'white-lines' pattern on the surface (Wickham's striae)
- Koebner phenomenon may be seen (new skin lesions appearing at the site of trauma)
- oral involvement in around 50% of patients: typically a white-lace pattern on the buccal mucosa
- nails: thinning of nail plate, longitudinal ridging

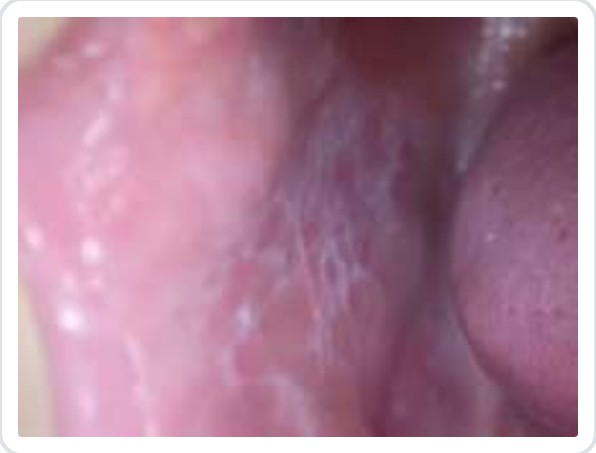

Lichenoid drug eruptions - causes:

- gold
- quinine
- thiazides

Management

- potent topical steroids are the mainstay of treatment
- benzydamine mouthwash or spray is recommended for oral lichen planus
- extensive lichen planus may require oral steroids or immunosuppression

123

Next question

## Textbooks

High-yield textbook

Extended textbook

## Links

Primary Care Dermatology Society 21 7

Lichen planus

DermNet NZ 22 3

Lichen planus

Suggest link Report broken link

## Media

Lichen planus

Osmosis - YouTube 5 1

Report broken media

Score: **28%**

1 ✗
2 ✓
3 ✓
4 ✗
5 ✗

| | |
|---|---|
| 6 | ✗ |
| 7 | ✗ |
| 8 | ✗ |
| 9 | ✗ |
| 10 | ✗ |
| 11 | ✗ |
| 12 | ✗ |
| 13 | ✓ |
| 14 | ✓ |
| 15 | ✓ |
| 16 | ✗ |
| **17** | ✓ |
| 18 | ✓ |
| 19 | ✗ |
| 20 | ✗ |
| 21 | ✗ |
| 22 | ✗ |
| 23 | ✗ |
| 24 | ✓ |
| 25 | ✗ |
| 26 | ✓ |
| 27 | ✗ |
| 28 | ✗ |
| 29 | ✗ |
| 30 | ✓ |
| 31 | ✗ |
| 32 | ✗ |
| 33 | ✗ |
| 34 | ✗ |
| 35 | ✓ |
| 36 | ✗ |
| 37 | ✗ |
| 38 | ✗ |
| 39 | ✗ |
| 40 | ✗ |
| 41 | ✗ |

| | |
|---|---|
| 42 | ✓ |
| 43 | ✗ |
| 44 | ✗ |
| 45 | ✓ |
| 46 | ✓ |
| 47 | ✗ |
| 48 | ✗ |
| 49 | ✗ |
| 50 | ✗ |

All contents of this site are © 2024 Passmedicine Limited

Back to top

A 57-year-old man has returned to the emergency department after struggling to cope with pain from shingles, diagnosed two days ago. He was started on aciclovir, paracetamol and codeine, but was still struggling and therefore yesterday was started on neuropathic analgesia with gabapentin, but has found this to be ineffective. He has a past medical history of oesophagitis, atrial fibrillations and gout. He normally takes omeprazole, warfarin, bisoprolol and allopurinol. What would be the most appropriate plan?

- Admit for IV aciclovir
- Admit for IV ganciclovir
- Stop all opiates
- Add an NSAID
- Add prednisolone

Submit answer

Reference ranges

Score: **0%**

1 -
2 -
3 -
4 -
5 -
6 -
7 -
8 -
9 -

| | |
|---|---|
| 10 | - |
| 11 | - |
| 12 | - |
| 13 | - |
| 14 | - |
| 15 | - |
| 16 | - |
| 17 | - |
| **18** | - |

All contents of this site are © 2024 Passmedicine Limited

A 57-year-old man has returned to the emergency department after struggling to cope with pain from shingles, diagnosed two days ago. He was started on aciclovir, paracetamol and codeine, but was still struggling and therefore yesterday was started on neuropathic analgesia with gabapentin, but has found this to be ineffective. He has a past medical history of oesophagitis, atrial fibrillations and gout. He normally takes omeprazole, warfarin, bisoprolol and allopurinol. What would be the most appropriate plan?

| | |
|---|---|
| Admit for IV aciclovir | 20% |
| Admit for IV ganciclovir | 6% |
| Stop all opiates | 10% |
| Add an NSAID | 12% |
| Add prednisolone | 52% |

Corticosteroids can be used in refractory pain in shingles if simple analgesia and neuropathic analgesia do not help, but only for acute shingles

Important for me Less important

This patient has been suffering with severe pain due to acute shingles despite management with paracetamol, codeine and neuropathic agent. Adding an NSAID would be inappropriate due to this history of gastritis, whilst IV antiviral treatment would not make any difference in regards to the pain management. NICE suggests prednisolone can be used to help in the management of pain in acute shingles, and this can be offered for this patient.

Discuss (9) Improve

Next question

## Shingles

Shingles (herpes zoster infection) is an acute, unilateral, painful blistering rash caused by reactivation of the varicella-zoster virus (VZV). Following primary infection with VZV (chickenpox), the virus lies dormant in the dorsal root or cranial nerve ganglia.

Risk factors

- increasing age
- HIV: strong risk factor, 15 times more common
- other immunosuppressive conditions (e.g. steroids, chemotherapy)

The most commonly affected dermatomes are T1-L2.

Features

- prodromal period
  - burning pain over the affected dermatome for 2-3 days
  - pain may be severe and interfere with sleep
  - around 20% of patients will experience fever, headache, lethargy
- rash
  - initially erythematous, macular rash over the affected dermatome
  - quickly becomes vesicular
  - characteristically is well demarcated by the dermatome and does not cross the midline. However, some 'bleeding' into adjacent areas may be seen

The diagnosis is usually clinical.

Management

- remind patients they are potentially infectious
  - may need to avoid pregnant women and the immunosuppressed
  - should be advised that they are infectious until the vesicles have crusted over, usually 5-7 days following onset
  - covering lesions reduces the risk
- analgesia
  - paracetamol and NSAIDs are first-line
  - if not responding then use of neuropathic agents (e.g. amitriptyline) can be considered
  - oral corticosteroids may be considered in the first 2 weeks in immunocompetent adults with localized shingles if the pain is severe and not responding to the above treatments

- antivirals
    - NICE makes recommendations on when to use antivirals
    - in practice, they recommend antivirals within 72 hours for the majority of patients, unless the patient is < 50 years and has a 'mild' truncal rash associated with mild pain and no underlying risk factors
    - one of the benefits of prescribing antivirals is a reduced incidence of post-herpetic neuralgia, particularly in older people
    - aciclovir, famciclovir, or valaciclovir are recommended

Complications
- post-herpetic neuralgia
    - the most common complications
    - more common in older patients
    - affects between 5%-30% of patients depending on age
    - most commonly resolves with 6 months but may last longer
- herpes zoster ophthalmicus (shingles affecting affecting the ocular division of the trigeminal nerve) is associated with a variety of ocular complications
- herpes zoster oticus (Ramsay Hunt syndrome): may result in ear lesions and facial paralysis

AI + Q 123

Next question >

**Textbooks**

High-yield textbook

Extended textbook

**Links**

Clinical Knowledge Summaries 8 7

Shingles guidelines

Suggest link | Report broken link

## Media

Spinal Cord - Clinical Anatomy and Physiology (dermatomes, blood supply, shingles, lumbar puncture)

Armando Hasudungan - YouTube 2 1

Report broken media

Score: **28%**

| | |
|---|---|
| 1 | ✗ |
| 2 | ✓ |
| 3 | ✓ |
| 4 | ✗ |
| 5 | ✗ |
| 6 | ✗ |
| 7 | ✗ |
| 8 | ✗ |
| 9 | ✗ |
| 10 | ✗ |
| 11 | ✗ |
| 12 | ✗ |
| 13 | ✓ |
| 14 | ✓ |
| 15 | ✓ |
| 16 | ✗ |
| 17 | ✓ |
| **18** | ✓ |
| 19 | ✗ |

| | |
|---|---|
| 20 | ✗ |
| 21 | ✗ |
| 22 | ✗ |
| 23 | ✗ |
| 24 | ✓ |
| 25 | ✗ |
| 26 | ✓ |
| 27 | ✗ |
| 28 | ✗ |
| 29 | ✗ |
| 30 | ✓ |
| 31 | ✗ |
| 32 | ✗ |
| 33 | ✗ |
| 34 | ✗ |
| 35 | ✓ |
| 36 | ✗ |
| 37 | ✗ |
| 38 | ✗ |
| 39 | ✗ |
| 40 | ✗ |
| 41 | ✗ |
| 42 | ✓ |
| 43 | ✗ |
| 44 | ✗ |
| 45 | ✓ |
| 46 | ✓ |
| 47 | ✗ |
| 48 | ✗ |
| 49 | ✗ |
| 50 | ✗ |

All contents of this site are © 2024 Passmedicine Limited

A 52-year-old man asks you to look at the side of his tongue. The white patches have been present for the past few months and are asymptomatic. He is a smoker who is known to have type 2 diabetes mellitus.

© Image used on license from DermNet NZ

What is the most likely diagnosis?

- Candidiasis
- Squamous cell carcinoma
- Lichen sclerosus
- Oral leukoplakia
- Geographic tongue

Submit answer

Reference ranges

Score: **0%**

| | |
|---|---|
| 1 | - |
| 2 | - |
| 3 | - |
| 4 | - |
| 5 | - |
| 6 | - |
| 7 | - |
| 8 | - |
| 9 | - |
| 10 | - |
| 11 | - |
| 12 | - |
| 13 | - |
| 14 | - |
| 15 | - |
| 16 | - |
| 17 | - |
| 18 | - |
| **19** | - |

All contents of this site are © 2024 Passmedicine Limited

Back to top

A 52-year-old man asks you to look at the side of his tongue. The white patches have been present for the past few months and are asymptomatic. He is a smoker who is known to have type 2 diabetes mellitus.

© Image used on license from DermNet NZ

What is the most likely diagnosis?

| | |
|---|---|
| Candidiasis | 10% |
| Squamous cell carcinoma | 1% |
| Lichen sclerosus | 9% |
| Oral leukoplakia | 79% |
| Geographic tongue | 2% |

The asymptomatic and prolonged nature of the symptoms goes against a diagnosis of candidiasis. Lichen planus (rather then sclerosus) is a differential diagnosis but tends to have a slightly different appearance - typically a symmetrical white lace-like pattern on the buccal mucosa. Squamous cell carcinoma is not the most likely diagnosis as only around 1% of oral leukoplakias become malignant.

This patient should be referred for a biopsy to confirm the diagnosis.

Discuss (3) Improve

Next question

# Leukoplakia

Leukoplakia is a premalignant condition which presents as white, hard spots on the mucous membranes of the mouth. It is more common in smokers.

Leukoplakia is said to be a diagnosis of exclusion. Candidiasis and lichen planus should be considered, especially if the lesions can be 'rubbed off'

Biopsies are usually performed to exclude alternative diagnoses such as squamous cell carcinoma and regular follow-up is required to exclude malignant transformation to squamous cell carcinoma, which occurs in around 1% of patients.

+ Q 123

Next question

## Textbooks

High-yield textbook

Extended textbook

## Links

DermNet NZ 10 0

Oral leukoplakia

Suggest link Report broken link

Score: **28%**

| | |
|---|---|
| 1 | ✗ |
| 2 | ✓ |
| 3 | ✓ |
| 4 | ✗ |
| 5 | ✗ |
| 6 | ✗ |
| 7 | ✗ |
| 8 | ✗ |
| 9 | ✗ |
| 10 | ✗ |
| 11 | ✗ |
| 12 | ✗ |
| 13 | ✓ |
| 14 | ✓ |
| 15 | ✓ |
| 16 | ✗ |
| 17 | ✓ |
| 18 | ✓ |
| **19** | ✗ |
| 20 | ✗ |
| 21 | ✗ |
| 22 | ✗ |

| | |
|---|---|
| 23 | ✗ |
| 24 | ✓ |
| 25 | ✗ |
| 26 | ✓ |
| 27 | ✗ |
| 28 | ✗ |
| 29 | ✗ |
| 30 | ✓ |
| 31 | ✗ |
| 32 | ✗ |
| 33 | ✗ |
| 34 | ✗ |
| 35 | ✓ |
| 36 | ✗ |
| 37 | ✗ |
| 38 | ✗ |
| 39 | ✗ |
| 40 | ✗ |
| 41 | ✗ |
| 42 | ✓ |
| 43 | ✗ |
| 44 | ✗ |
| 45 | ✓ |
| 46 | ✓ |
| 47 | ✗ |
| 48 | ✗ |
| 49 | ✗ |
| 50 | ✗ |

All contents of this site are © 2024 Passmedicine Limited

A 42-year-old female originally presents to her GP with a small skin lesion on her forearm after being bitten by her new kitten 4 days previous. There was some redness with minimal discharge at the site, but the patient denied any systemic symptoms. Her GP send off a swab of the area and started the patient on a course of amoxicillin.

Initial the patient felt the wound appeared to be healing but after a few further days, she became systemically unwell with fever, sweating and feeling weak. She noticed her skin appeared to be peeling all over her body (see below) and her considered family rushed her into hospital. On review of her GP records, the wound swab culture grew *Staphylococcal aureus*.

© Image used on license from DermNet NZ

Other than supportive care what other management has been shown to have the most benefit for this patient's condition long term?

- Corticosteroids
- IV antibiotics
- Intravenous immunoglobulin
- Skin graft
- Surgical debridement

Submit answer

Reference ranges

Score: **0%**

| | |
|---|---|
| 1 | - |
| 2 | - |
| 3 | - |
| 4 | - |
| 5 | - |
| 6 | - |
| 7 | - |
| 8 | - |
| 9 | - |
| 10 | - |
| 11 | - |
| 12 | - |
| 13 | - |
| 14 | - |
| 15 | - |
| 16 | - |
| 17 | - |
| 18 | - |
| 19 | - |
| **20** | - |

All contents of this site are © 2024 Passmedicine Limited

Back to top

A 42-year-old female originally presents to her GP with a small skin lesion on her forearm after being bitten by her new kitten 4 days previous. There was some redness with minimal discharge at the site, but the patient denied any systemic symptoms. Her GP send off a swab of the area and started the patient on a course of amoxicillin.

Initial the patient felt the wound appeared to be healing but after a few further days, she became systemically unwell with fever, sweating and feeling weak. She noticed her skin appeared to be peeling all over her body (see below) and her considered family rushed her into hospital. On review of her GP records, the wound swab culture grew *Staphylococcal aureus*.

© Image used on license from DermNet NZ

Other than supportive care what other management has been shown to have the most benefit for this patient's condition long term?

| | |
|---|---|
| Corticosteroids | 29% |
| IV antibiotics | 21% |
| Intravenous immunoglobulin | 38% |
| Skin graft | 4% |
| Surgical debridement | 9% |

This patient has presented with toxic epidermal necrolysis (TEN) most likely secondary to

amoxicillin started by her GP. The specific pathophysiology of TEN is unknown but it is thought to be due to an immune response and a drug precipitate is attributed to 80-95% of cases. Patients are systemically unwell and the epidermis separates resulting in a peeling like appearance as seen in this case. Management involves stopping the precipitating drug and supportive care, often requiring intensive care. Recent research has shown intravenous immunoglobulin therapy is effective in reducing mortality and morbidity and so is commonly used as first-line management. Other treatments options including immunosuppressive agents and plasmapheresis have also be used but are normally second-line.

Although the patient had a previous skin infection it is not the cause of their acute deterioration. The rapid onset following starting a new drug (in this case an antibiotic) is in keeping with a TEN reaction. IV antibiotics would be required in the differential diagnosis of staphylococcal scaled skin syndrome (SSSS) however this is less likely in this case despite the patients confirmed *Staphylococcal aureus* infection. SSSS is rarely seen in adults and is less severe than TEN. Also in SSSS the cleavage site is the intraepidermal as opposed to the TEN which involves necrosis of the full epidermal layer as seen in this patient. Antibiotics are sometimes used prophylactically in TEN and are often required later as patients are at high risk of infection, but they are not required initially.

Immunosuppressive medication such as corticosteroids have been used in TEN but intravenous immunoglobulin is more effective and therefore is commonly used as first-line.

Skin grafts may be required much later in the course of TEN to promote healing if there is extensive skin disruption however it is not required in all cases and the benefits on mortality and morbidity are unclear.

Surgical debridement is not commonly required as TEN is not due to an infection. Secondary infection can occur but again debridement is rarely required.

Discuss (5) | Improve

Next question

## Toxic epidermal necrolysis

Toxic epidermal necrolysis (TEN) is a potentially life-threatening skin disorder that is most commonly seen secondary to a drug reaction. In this condition, the skin develops a scalded appearance over an extensive area. Some authors consider TEN to be the severe end of a spectrum of skin disorders which includes erythema multiforme and Stevens-Johnson syndrome,

Features

- systemically unwell e.g. pyrexia, tachycardic
- positive Nikolsky's sign: the epidermis separates with mild lateral pressure

Drugs known to induce TEN

- phenytoin
- sulphonamides
- allopurinol
- penicillins
- carbamazepine
- NSAIDs

Management

- stop precipitating factor
- supportive care
  - often in an intensive care unit
  - volume loss and electrolyte derangement are potential complications
- intravenous immunoglobulin has been shown to be effective and is now commonly used first-line
- other treatment options include: immunosuppressive agents (ciclosporin and cyclophosphamide), plasmapheresis

AI + Q 123

Next question >

**Textbooks**

High-yield textbook

Extended textbook

## Links

British Association of Dermatologists 4 7

2016 UK guidelines for the management of Stevens-Johnson syndrome/toxic epidermal necrolysis

DermNet NZ 9 2

Toxic epidermal necrolysis

Suggest link

Report broken link

## Media

Nikolsky's sign

Individual - YouTube 3 0

Understanding Stevens-Johnson Syndrome and Toxic Epidermal Necrolysis

Osmosis - YouTube 1 0

Stevensâ€"Johnson Syndrome & Toxic Epidermal Necrolysis

Osmosis - YouTube 3 1

Report broken media

Score: **28%**

| | |
|---|---|
| 1 | ✗ |
| 2 | ✓ |
| 3 | ✓ |
| 4 | ✗ |
| 5 | ✗ |
| 6 | ✗ |
| 7 | ✗ |
| 8 | ✗ |
| 9 | ✗ |
| 10 | ✗ |
| 11 | ✗ |
| 12 | ✗ |
| 13 | ✓ |
| 14 | ✓ |
| 15 | ✓ |
| 16 | ✗ |
| 17 | ✓ |
| 18 | ✓ |
| 19 | ✗ |
| **20** | ✗ |
| 21 | ✗ |
| 22 | ✗ |
| 23 | ✗ |
| 24 | ✓ |
| 25 | ✗ |
| 26 | ✓ |
| 27 | ✗ |
| 28 | ✗ |
| 29 | ✗ |
| 30 | ✓ |

| | |
|---|---|
| 31 | ✗ |
| 32 | ✗ |
| 33 | ✗ |
| 34 | ✗ |
| 35 | ✓ |
| 36 | ✗ |
| 37 | ✗ |
| 38 | ✗ |
| 39 | ✗ |
| 40 | ✗ |
| 41 | ✗ |
| 42 | ✓ |
| 43 | ✗ |
| 44 | ✗ |
| 45 | ✓ |
| 46 | ✓ |
| 47 | ✗ |
| 48 | ✗ |
| 49 | ✗ |
| 50 | ✗ |

All contents of this site are © 2024 Passmedicine Limited

Back to top

An 18-year-old male university student presents to the emergency department due to itching. He has been experiencing worsening itching of his hands and arms after two months of living in student accommodation with two other students. He has found the itching to be progressively worse and not manageable with over the counter chlorphenamine. He has had no other medical problems and takes no regular medications. He is an economics student and has no exposure to any chemicals. On examination there are linear burrows on the sides of some of his fingers on both right and left sides. In additions, there is evidence of lots of scratching, but does not appear infected. He is prescribed permethrin 5% as treatment. What advise should be given in its application?

- Apply once to whole body
- Apply once to whole body and repeat in one week
- Apply once to whole body and repeat in one week and advise household contacts to do same
- Apply daily to whole body for one week
- Apply daily to whole body for one week and advise household contacts to do same

Submit answer

Reference ranges

Score: **0%**

1 -
2 -
3 -
4 -
5 -

6 -
7 -
8 -
9 -
10 -
11 -
12 -
13 -
14 -
15 -
16 -
17 -
18 -
19 -
20 -
**21** -

All contents of this site are © 2024 Passmedicine Limited
Back to top

An 18-year-old male university student presents to the emergency department due to itching. He has been experiencing worsening itching of his hands and arms after two months of living in student accommodation with two other students. He has found the itching to be progressively worse and not manageable with over the counter chlorphenamine. He has had no other medical problems and takes no regular medications. He is an economics student and has no exposure to any chemicals. On examination there are linear burrows on the sides of some of his fingers on both right and left sides. In additions, there is evidence of lots of scratching, but does not appear infected. He is prescribed permethrin 5% as treatment. What advise should be given in its application?

| | |
|---|---|
| Apply once to whole body | 0% |
| Apply once to whole body and repeat in one week | 5% |
| Apply once to whole body and repeat in one week and advise household contacts to do same | 85% |
| Apply daily to whole body for one week | 1% |
| Apply daily to whole body for one week and advise household contacts to do same | 8% |

In scabies, advise all close contacts to be treated as well as the patient twice, with applications one week apart

Important for me Less important

This patient likely has scabies. Scabies is more common in unkempt environments, which can occur in student housing. The diagnosis is strongly supported by severe, persisting pruritus in the presence of linear burrows. Treatment is with permethrin 5% but care must be given to ensure that the patient understands the treatment protocol or treatment failure is likely.

Discuss (2) Improve

Next question

# Scabies

Scabies is caused by the mite *Sarcoptes scabiei* and is spread by prolonged skin contact. It typically affects children and young adults.

The scabies mite burrows into the skin, laying its eggs in the stratum corneum. The intense pruritus associated with scabies is due to a delayed-type IV hypersensitivity reaction to mites/eggs which occurs about 30 days after the initial infection.

Features
- widespread pruritus
- linear burrows on the side of fingers, interdigital webs and flexor aspects of the wrist
- in infants, the face and scalp may also be affected
- secondary features are seen due to scratching: excoriation, infection

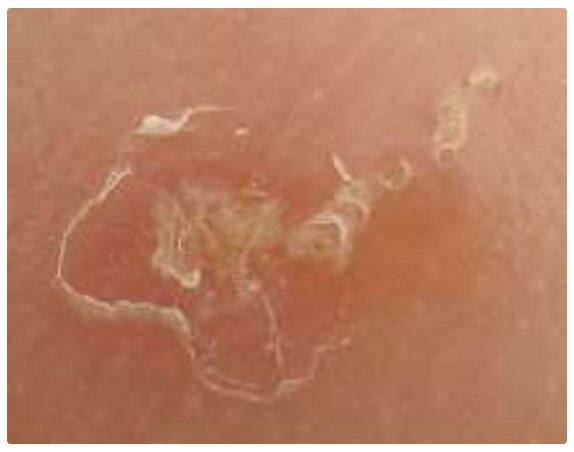

Management
- permethrin 5% is first-line
- malathion 0.5% is second-line
- give appropriate guidance on use (see below)
- pruritus persists for up to 4-6 weeks post eradication

Patient guidance on treatment
- avoid close physical contact with others until treatment is complete
- all household and close physical contacts should be treated at the same time, even if asymptomatic
- launder, iron or tumble dry clothing, bedding, towels, etc., on the first day of treatment to kill off mites.

The BNF advises to apply the insecticide to all areas, including the face and scalp, contrary to the manufacturer's recommendation. Patients should be given the following instructions:

- apply the insecticide cream or liquid to cool, dry skin
- pay close attention to areas between fingers and toes, under nails, armpit area, creases of the skin such as at the wrist and elbow
- allow to dry and leave on the skin for 8-12 hours for permethrin, or for 24 hours for malathion, before washing off
- reapply if insecticide is removed during the treatment period, e.g. If wash hands, change nappy, etc
- repeat treatment 7 days later

## Crusted (Norwegian) scabies

Crusted scabies is seen in patients with suppressed immunity, especially HIV.

© Image used on license from DermNet NZ

The crusted skin will be teeming with hundreds of thousands of organisms.

Ivermectin is the treatment of choice and isolation is essential

AI + Q 123

Next question >

## Textbooks

High-yield textbook

Extended textbook

## Links

Clinical Knowledge Summaries 19 14

Scabies guidelines

Suggest link Report broken link

Score: **28%**

| | |
|---|---|
| 1 | ✗ |
| 2 | ✓ |
| 3 | ✓ |
| 4 | ✗ |
| 5 | ✗ |
| 6 | ✗ |
| 7 | ✗ |
| 8 | ✗ |
| 9 | ✗ |
| 10 | ✗ |
| 11 | ✗ |
| 12 | ✗ |
| 13 | ✓ |
| 14 | ✓ |
| 15 | ✓ |
| 16 | ✗ |
| 17 | ✓ |
| 18 | ✓ |

19 ✗
20 ✗
**21** ✗
22 ✗
23 ✗
24 ✓
25 ✗
26 ✓
27 ✗
28 ✗
29 ✗
30 ✓
31 ✗
32 ✗
33 ✗
34 ✗
35 ✓
36 ✗
37 ✗
38 ✗
39 ✗
40 ✗
41 ✗
42 ✓
43 ✗
44 ✗
45 ✓
46 ✓
47 ✗
48 ✗
49 ✗
50 ✗

All contents of this site are © 2024 Passmedicine Limited

A 32-year-old lady attends with a facial rash for several weeks. She has an erythematous rash which looks greasy and has a fine scale over her face affecting her cheeks, nasolabial folds, eyebrows, nasal bridge and scalp. What is the most likely diagnosis?

- Acne rosacea
- Systemic lupus erythematous (SLE)
- Eczema
- Seborrhoeic dermatitis
- Psoriasis

Submit answer

Reference ranges

Score: **0%**

| | |
|---|---|
| 1 | - |
| 2 | - |
| 3 | - |
| 4 | - |
| 5 | - |
| 6 | - |
| 7 | - |
| 8 | - |
| 9 | - |
| 10 | - |
| 11 | - |
| 12 | - |

13 -
14 -
15 -
16 -
17 -
18 -
19 -
20 -
21 -
**22** -

All contents of this site are © 2024 Passmedicine Limited

Back to top

A 32-year-old lady attends with a facial rash for several weeks. She has an erythematous rash which looks greasy and has a fine scale over her face affecting her cheeks, nasolabial folds, eyebrows, nasal bridge and scalp. What is the most likely diagnosis?

| | |
|---|---|
| Acne rosacea | 23% |
| Systemic lupus erythematous (SLE) | 4% |
| Eczema | 1% |
| Seborrhoeic dermatitis | 68% |
| Psoriasis | 4% |

An itchy rash affecting the face and scalp distribution is commonly caused by seborrhoeic dermatitis

Important for me Less important

The description describes seborrhoeic dermatitis. The involvement of the nasolabial folds differentiates it from acne rosacea which typically spares this area and tends to include telangiectasia and pustules.

Discuss (3) Improve

Next question

## Seborrhoeic dermatitis in adults

Seborrhoeic dermatitis in adults is a chronic dermatitis thought to be caused by an inflammatory reaction related to a proliferation of a normal skin inhabitant, a fungus called *Malassezia furfur* (formerly known as *Pityrosporum ovale*). It is common, affecting around 2% of the general population.

Features

- eczematous lesions on the sebum-rich areas: scalp (may cause dandruff), periorbital, auricular and nasolabial folds
- otitis externa and blepharitis may develop

Associated conditions include

- HIV
- Parkinson's disease

Scalp disease management

- the first-line treatment is ketoconazole 2% shampoo
- over the counter preparations containing zinc pyrithione ('Head & Shoulders') and tar ('Neutrogena T/Gel') may be used if ketoconazole is not appropriate or acceptable to the person
- selenium sulphide and topical corticosteroid may also be useful

Face and body management

- topical antifungals: e.g. ketoconazole
- topical steroids: best used for short periods
- difficult to treat - recurrences are common

123

Next question

**Textbooks**

High-yield textbook

Extended textbook

## Links

Clinical Knowledge Summaries 20 11

Seborrhoeic dermatitis guidelines

DermNet NZ 24 4

Overview and pictures of seborrhoeic dermatitis

Suggest link Report broken link

Score: **28%**

| | |
|---|---|
| 1 | ✗ |
| 2 | ✓ |
| 3 | ✓ |
| 4 | ✗ |
| 5 | ✗ |
| 6 | ✗ |
| 7 | ✗ |
| 8 | ✗ |
| 9 | ✗ |
| 10 | ✗ |
| 11 | ✗ |
| 12 | ✗ |
| 13 | ✓ |
| 14 | ✓ |
| 15 | ✓ |
| 16 | ✗ |

| | |
|---|---|
| 17 | ✓ |
| 18 | ✓ |
| 19 | ✗ |
| 20 | ✗ |
| 21 | ✗ |
| **22** | ✗ |
| 23 | ✗ |
| 24 | ✓ |
| 25 | ✗ |
| 26 | ✓ |
| 27 | ✗ |
| 28 | ✗ |
| 29 | ✗ |
| 30 | ✓ |
| 31 | ✗ |
| 32 | ✗ |
| 33 | ✗ |
| 34 | ✗ |
| 35 | ✓ |
| 36 | ✗ |
| 37 | ✗ |
| 38 | ✗ |
| 39 | ✗ |
| 40 | ✗ |
| 41 | ✗ |
| 42 | ✓ |
| 43 | ✗ |
| 44 | ✗ |
| 45 | ✓ |
| 46 | ✓ |
| 47 | ✗ |
| 48 | ✗ |
| 49 | ✗ |
| 50 | ✗ |

All contents of this site are © 2024 Passmedicine Limited

A 26-year-old man presents with a lesion on his leg that he thinks has been present for a couple of weeks. It is somewhat itchy. He is otherwise fit and well, has no significant past medical history and takes no regular medications. The rash is shown below:

© Image used on license from DermNet NZ

Given the likely diagnosis, what is the definitive management?

- Oral doxycycline
- Topical emollient
- Topical fusidic acid
- Topical hydrocortisone
- Topical ketoconazole

Submit answer

Reference ranges

Score: **0%**

| | |
|---|---|
| 1 | - |
| 2 | - |
| 3 | - |
| 4 | - |
| 5 | - |
| 6 | - |
| 7 | - |
| 8 | - |
| 9 | - |
| 10 | - |
| 11 | - |
| 12 | - |
| 13 | - |
| 14 | - |
| 15 | - |
| 16 | - |
| 17 | - |
| 18 | - |
| 19 | - |
| 20 | - |
| 21 | - |
| 22 | - |
| **23** | - |

All contents of this site are © 2024 Passmedicine Limited

Back to top

A 26-year-old man presents with a lesion on his leg that he thinks has been present for a couple of weeks. It is somewhat itchy. He is otherwise fit and well, has no significant past medical history and takes no regular medications. The rash is shown below:

© Image used on license from DermNet NZ

Given the likely diagnosis, what is the definitive management?

| | |
|---|---|
| Oral doxycycline | 21% |
| Topical emollient | 4% |
| Topical fusidic acid | 4% |
| Topical hydrocortisone | 11% |
| Topical ketoconazole | 60% |

The rash here is characteristic of tinea corporis, colloquially known as ringworm. This is a fungal infection affecting the trunk and limbs. It has a characteristic appearance of a circular red patch with a raised edge and central hyperpigmentation as seen here, leading to the 'ring' appearance. Given its fungal nature, the most appropriate treatment is therefore topical ketoconazole. If the

rash were significantly widespread, an oral antifungal agent may be more appropriate.

Oral doxycycline would be an appropriate treatment for Lyme disease. There was no history of a tick bite in this question, and the lesions are much more indicative of ringworm than of erythema migrans, which would instead present with a red papule or macule that gradually enlarges to form a bull's eye-like ring.

Topical emollient is insufficient. Whilst this may relieve the itch associated with the rash, it will not treat the fungal cause of ringworm.

Topical fusidic acid is inappropriate. This is an antibiotic and would be used for bacterial infections, such as mild impetigo or a mildly infected wound. It would not help in treating ringworm.

Topical hydrocortisone may be used short-term to relieve inflammation. The lesion in this photo does not look particularly inflamed. It is not the definitive management for this condition; an antifungal cream is required. In fact, prolonged use of steroid creams can actually worsen fungal rashes.

Discuss (1) | Improve

Next question

## Tinea

Tinea is a term given to dermatophyte fungal infections. Three main types of infection are described depending on what part of the body is infected

- tinea capitis - scalp
- tinea corporis - trunk, legs or arms
- tinea pedis - feet

Tinea capitis (scalp ringworm)

- a cause of scarring alopecia mainly seen in children
- if untreated a raised, pustular, spongy/boggy mass called a kerion may form
- most common cause is *Trichophyton tonsurans* in the UK and the USA
- may also be caused by *Microsporum canis* acquired from cats or dogs
- diagnosis: lesions due to *Microsporum canis* green fluorescence under Wood's lamp*. However the most useful investigation is scalp scrapings
- management (based on NICE guidelines): oral antifungals: terbinafine for *Trichophyton tonsurans* infections and griseofulvin for *Microsporum* infections. Topical ketoconazole shampoo should be given for the first two weeks to reduce transmission

Tinea corporis (ringworm)

- causes include *Trichophyton rubrum* and *Trichophyton verrucosum* (e.g. From contact with cattle)
- well-defined annular, erythematous lesions with pustules and papules
- may be treated with oral fluconazole

Tinea pedis (athlete's foot)

- characterised by itchy, peeling skin between the toes
- common in adolescence

*lesions due to *Trichophyton* species do not readily fluoresce under Wood's lamp

123

Next question

**Textbooks**

High-yield textbook

Extended textbook

**Links**

Clinical Knowledge Summaries 6 11

Fungal skin infection - scalp

Suggest link Report broken link

Score: **28%**

| | |
|---|---|
| 1 | ✗ |
| 2 | ✓ |
| 3 | ✓ |
| 4 | ✗ |
| 5 | ✗ |
| 6 | ✗ |
| 7 | ✗ |
| 8 | ✗ |
| 9 | ✗ |
| 10 | ✗ |
| 11 | ✗ |
| 12 | ✗ |
| 13 | ✓ |
| 14 | ✓ |
| 15 | ✓ |
| 16 | ✗ |
| 17 | ✓ |
| 18 | ✓ |
| 19 | ✗ |
| 20 | ✗ |

| | |
|---|---|
| 21 | ✗ |
| 22 | ✗ |
| **23** | ✗ |
| 24 | ✓ |
| 25 | ✗ |
| 26 | ✓ |
| 27 | ✗ |
| 28 | ✗ |
| 29 | ✗ |
| 30 | ✓ |
| 31 | ✗ |
| 32 | ✗ |
| 33 | ✗ |
| 34 | ✗ |
| 35 | ✓ |
| 36 | ✗ |
| 37 | ✗ |
| 38 | ✗ |
| 39 | ✗ |
| 40 | ✗ |
| 41 | ✗ |
| 42 | ✓ |
| 43 | ✗ |
| 44 | ✗ |
| 45 | ✓ |
| 46 | ✓ |
| 47 | ✗ |
| 48 | ✗ |
| 49 | ✗ |
| 50 | ✗ |

All contents of this site are © 2024 Passmedicine Limited

A 24-year-old woman presents with new skin lesions.

She was the recipient of a renal transplant a year ago following IgA nephropathy. After several modifications to her immunosuppressive therapy, her graft function is stable with an eGFR of 80ml/min/1.73m$^2$. She also has a past history of hypothyroidism for which she takes levothyroxine.

She had first noticed the lesions 3 months ago. She had noted them a few years previously but on that occasion, they had disappeared of their own accord. They are not itchy.

On examination she has well demarcated depigmented patches on her arm, her shoulders and her upper back; the lesions shine a yellow-green colour under Woods lamp.

What is the most likely diagnosis?

- Vitiligo
- Pityriasis alba
- Idiopathic guttate hypomelanosis
- Pityriasis versicolor
- Seborrhoeic dermatitis

Submit answer

Reference ranges

3 -
4 -
5 -
6 -
7 -
8 -
9 -
10 -
11 -
12 -
13 -
14 -
15 -
16 -
17 -
18 -
19 -
20 -
21 -
22 -
23 -
**24** -

All contents of this site are © 2024 Passmedicine Limited
Back to top

A 24-year-old woman presents with new skin lesions.

She was the recipient of a renal transplant a year ago following IgA nephropathy. After several modifications to her immunosuppressive therapy, her graft function is stable with an eGFR of 80ml/min/1.73m$^2$. She also has a past history of hypothyroidism for which she takes levothyroxine.

She had first noticed the lesions 3 months ago. She had noted them a few years previously but on that occasion, they had disappeared of their own accord. They are not itchy.

On examination she has well demarcated depigmented patches on her arm, her shoulders and her upper back; the lesions shine a yellow-green colour under Woods lamp.

What is the most likely diagnosis?

| | |
|---|---|
| Vitiligo | 22% |
| Pityriasis alba | 14% |
| Idiopathic guttate hypomelanosis | 7% |
| Pityriasis versicolor | 55% |
| Seborrhoeic dermatitis | 2% |

The yellow-green fluorescence under Woods lamp is the key factor here; none of the other answers fluoresces in this way. Hence vitiligo is not correct and the history of hypothyroidism ( an autoimmune illness that may be associated with vitiligo) is irrelevant. The description is not consistent with seborrhoeic dermatitis, and the distribution of the rash is not consistent with either pityriasis alba or seborrhoeic dermatitis which typically affect the face.

Discuss (5) Improve

Next question

# Pityriasis versicolor

Pityriasis versicolor, also called tinea versicolor, is a superficial cutaneous fungal infection caused by *Malassezia furfur* (formerly termed *Pityrosporum ovale*)

Features

- most commonly affects trunk
- patches may be hypopigmented, pink or brown (hence versicolor). May be more noticeable following a suntan
- scale is common
- mild pruritus

Predisposing factors

- occurs in healthy individuals
- immunosuppression
- malnutrition
- Cushing's

Management

- topical antifungal. NICE advises ketoconazole shampoo as this is more cost effective for large areas
- if failure to respond to topical treatment then consider alternative diagnoses (e.g. send scrapings to confirm the diagnosis) + oral itraconazole

123

Next question

## Textbooks

High-yield textbook

Extended textbook

## Links

Clinical Knowledge Summaries — 12 👍 8 👎

Pityriasis versicolor guidelines

DermNet NZ — 19 👍 0 👎

Pityriasis versicolor

Suggest link

Report broken link

Score: **28%**

1 ✗
2 ✓
3 ✓
4 ✗
5 ✗
6 ✗
7 ✗
8 ✗
9 ✗
10 ✗
11 ✗
12 ✗
13 ✓
14 ✓

| | |
|---|---|
| 15 | ✓ |
| 16 | ✗ |
| 17 | ✓ |
| 18 | ✓ |
| 19 | ✗ |
| 20 | ✗ |
| 21 | ✗ |
| 22 | ✗ |
| 23 | ✗ |
| **24** | ✓ |
| 25 | ✗ |
| 26 | ✓ |
| 27 | ✗ |
| 28 | ✗ |
| 29 | ✗ |
| 30 | ✓ |
| 31 | ✗ |
| 32 | ✗ |
| 33 | ✗ |
| 34 | ✗ |
| 35 | ✓ |
| 36 | ✗ |
| 37 | ✗ |
| 38 | ✗ |
| 39 | ✗ |
| 40 | ✗ |
| 41 | ✗ |
| 42 | ✓ |
| 43 | ✗ |
| 44 | ✗ |
| 45 | ✓ |
| 46 | ✓ |
| 47 | ✗ |
| 48 | ✗ |
| 49 | ✗ |
| 50 | ✗ |

All contents of this site are © 2024 Passmedicine Limited

A 33-year-old woman presents with several days of tender lesions overlying her shins. She feels generally well in herself, aside from feeling slightly feverish. She has a past medical history of depression, anxiety, acid reflux, and ulcerative colitis, including a recent exacerbation that required oral prednisolone. She recently completed a course of doxycycline for a chest infection. Her regular medications include sertraline, azathioprine, and the combined oral contraceptive pill.

Her rash appears as follows:

© Image used on license from DermNet NZ

Given the likely diagnosis, which of the following is the most likely cause?

- Azathioprine
- Combined oral contraceptive pill
- Doxycycline

- Prednisolone
- Sertraline

Submit answer

Reference ranges

Score: **0%**

| | |
|---|---|
| 1 | - |
| 2 | - |
| 3 | - |
| 4 | - |
| 5 | - |
| 6 | - |
| 7 | - |
| 8 | - |
| 9 | - |
| 10 | - |
| 11 | - |
| 12 | - |
| 13 | - |
| 14 | - |
| 15 | - |
| 16 | - |
| 17 | - |
| 18 | - |
| 19 | - |
| 20 | - |
| 21 | - |
| 22 | - |
| 23 | - |
| 24 | - |
| **25** | - |

All contents of this site are © 2024 Passmedicine Limited

PassMedicine



A 33-year-old woman presents with several days of tender lesions overlying her shins. She feels generally well in herself, aside from feeling slightly feverish. She has a past medical history of depression, anxiety, acid reflux, and ulcerative colitis, including a recent exacerbation that required oral prednisolone. She recently completed a course of doxycycline for a chest infection. Her regular medications include sertraline, azathioprine, and the combined oral contraceptive pill.

Her rash appears as follows:

© Image used on license from DermNet NZ

Given the likely diagnosis, which of the following is the most likely cause?

| | |
|---|---|
| Azathioprine | 4% |
| Combined oral contraceptive pill | 80% |
| Doxycycline | 10% |

| | |
|---|---|
| Prednisolone | 5% |
| Sertraline | 2% |

The diagnosis here is erythema nodosum. This patient has the typical appearance of multiple erythematous, nodular lesions over the shins which appear inflamed. They are also described as being tender. These usually resolve within 6 weeks without scarring. There are several causes, including some medications - of the list above, the combined oral contraceptive pill is most strongly associated with the development of erythema nodosum.

Erythema nodosum is associated with inflammatory bowel disease. There have been a few case studies of azathioprine hypersensitivity being one possible explanation for this association. However, the combined oral contraceptive pill remains a much more likely option.

Doxycycline is not known to trigger erythema nodosum. Many antibiotics are, however, implicated in the condition, including penicillins and sulphonamides.

Prednisolone is not linked to the development of erythema nodosum. It is sometimes used to aid the resolution of the condition if symptoms persist.

Sertraline is a selective serotonin reuptake inhibitor used for anxiety and depression. Newer antidepressants are rarely linked to erythema nodosum, with fluoxetine, paroxetine, and venlafaxine being more strongly implicated than sertraline (although still relatively rarely linked compared to the combined pill).

Discuss (2) Improve

Next question

## Erythema nodosum

Overview

- inflammation of subcutaneous fat
- typically causes tender, erythematous, nodular lesions
- usually occurs over shins, may also occur elsewhere (e.g. forearms, thighs)
- usually resolves within 6 weeks
- lesions heal without scarring

Causes

- infection
    - streptococci
    - tuberculosis
    - brucellosis
- systemic disease
    - sarcoidosis
    - inflammatory bowel disease
    - Behcet's
- malignancy/lymphoma
- drugs
    - penicillins
    - sulphonamides
    - combined oral contraceptive pill
- pregnancy

123

Next question

**Textbooks**

High-yield textbook

Extended textbook

## Links

DermNet NZ 30 14

Erythema nodosum

Suggest link Report broken link

Score: **28%**

| | |
|---|---|
| 1 | ✗ |
| 2 | ✓ |
| 3 | ✓ |
| 4 | ✗ |
| 5 | ✗ |
| 6 | ✗ |
| 7 | ✗ |
| 8 | ✗ |
| 9 | ✗ |
| 10 | ✗ |
| 11 | ✗ |
| 12 | ✗ |
| 13 | ✓ |
| 14 | ✓ |
| 15 | ✓ |
| 16 | ✗ |
| 17 | ✓ |
| 18 | ✓ |
| 19 | ✗ |
| 20 | ✗ |

| | |
|---|---|
| 21 | ✗ |
| 22 | ✗ |
| 23 | ✗ |
| 24 | ✓ |
| **25** | ✗ |
| 26 | ✓ |
| 27 | ✗ |
| 28 | ✗ |
| 29 | ✗ |
| 30 | ✓ |
| 31 | ✗ |
| 32 | ✗ |
| 33 | ✗ |
| 34 | ✗ |
| 35 | ✓ |
| 36 | ✗ |
| 37 | ✗ |
| 38 | ✗ |
| 39 | ✗ |
| 40 | ✗ |
| 41 | ✗ |
| 42 | ✓ |
| 43 | ✗ |
| 44 | ✗ |
| 45 | ✓ |
| 46 | ✓ |
| 47 | ✗ |
| 48 | ✗ |
| 49 | ✗ |
| 50 | ✗ |

All contents of this site are © 2024 Passmedicine Limited

A 17-year-old male presents with a new skin condition which his mum noticed when they were on holiday in Spain. On examination, he has skin type V, with multiple small patches of depigmentation to the upper back. The patches appear mildly flaky but they are asymptomatic. He is usually well and has never had this condition before. Which of the following is the most likely diagnosis?

- Pityriasis rosea
- Atopic eczema
- Vitiligo
- Guttate psoriasis
- Pityriasis versicolor

Submit answer

Reference ranges

Score: **0%**

1 -
2 -
3 -
4 -
5 -
6 -
7 -
8 -
9 -
10 -

| | |
|---|---|
| 11 | - |
| 12 | - |
| 13 | - |
| 14 | - |
| 15 | - |
| 16 | - |
| 17 | - |
| 18 | - |
| 19 | - |
| 20 | - |
| 21 | - |
| 22 | - |
| 23 | - |
| 24 | - |
| 25 | - |
| **26** | - |

All contents of this site are © 2024 Passmedicine Limited

Back to top

A 17-year-old male presents with a new skin condition which his mum noticed when they were on holiday in Spain. On examination, he has skin type V, with multiple small patches of depigmentation to the upper back. The patches appear mildly flaky but they are asymptomatic. He is usually well and has never had this condition before. Which of the following is the most likely diagnosis?

- Pityriasis rosea 7%
- Atopic eczema 1%
- Vitiligo 6%
- Guttate psoriasis 2%
- Pityriasis versicolor 84%

This is a typical history of pityriasis versicolor, a skin condition caused by an overgrowth of Malassezia yeast. It is most common in young people, especially males. It causes multiple patches of skin discoloration, mainly to the trunk. The patches may appear pale brown, pink, or may appear depigmented especially in patients with dark skin. They may also be mildly flaky and itchy. The condition can often present after spending time in sunny, humid environments. It is treated with topical antifungals eg. ketoconazole shampoo.



## Pityriasis versicolor

Pityriasis versicolor, also called tinea versicolor, is a superficial cutaneous fungal infection caused by *Malassezia furfur* (formerly termed *Pityrosporum ovale*)

Features

- most commonly affects trunk

- patches may be hypopigmented, pink or brown (hence versicolor). May be more noticeable following a suntan
- scale is common
- mild pruritus

Predisposing factors
- occurs in healthy individuals
- immunosuppression
- malnutrition
- Cushing's

Management
- topical antifungal. NICE advises ketoconazole shampoo as this is more cost effective for large areas
- if failure to respond to topical treatment then consider alternative diagnoses (e.g. send scrapings to confirm the diagnosis) + oral itraconazole

AI + Q 123

Next question >

**Textbooks**

High-yield textbook

Extended textbook

**Links**

Clinical Knowledge Summaries 12 8

Pityriasis versicolor guidelines

DermNet NZ 19 0

Pityriasis versicolor

Suggest link Report broken link

Score: **28%**

| | |
|---|---|
| 1 | ✗ |
| 2 | ✓ |
| 3 | ✓ |
| 4 | ✗ |
| 5 | ✗ |
| 6 | ✗ |
| 7 | ✗ |
| 8 | ✗ |
| 9 | ✗ |
| 10 | ✗ |
| 11 | ✗ |
| 12 | ✗ |
| 13 | ✓ |
| 14 | ✓ |
| 15 | ✓ |
| 16 | ✗ |
| 17 | ✓ |
| 18 | ✓ |
| 19 | ✗ |
| 20 | ✗ |
| 21 | ✗ |

| | |
|---|---|
| 22 | ✗ |
| 23 | ✗ |
| 24 | ✓ |
| 25 | ✗ |
| **26** | ✓ |
| 27 | ✗ |
| 28 | ✗ |
| 29 | ✗ |
| 30 | ✓ |
| 31 | ✗ |
| 32 | ✗ |
| 33 | ✗ |
| 34 | ✗ |
| 35 | ✓ |
| 36 | ✗ |
| 37 | ✗ |
| 38 | ✗ |
| 39 | ✗ |
| 40 | ✗ |
| 41 | ✗ |
| 42 | ✓ |
| 43 | ✗ |
| 44 | ✗ |
| 45 | ✓ |
| 46 | ✓ |
| 47 | ✗ |
| 48 | ✗ |
| 49 | ✗ |
| 50 | ✗ |

All contents of this site are © 2024 Passmedicine Limited

Back to top

A 32-year-old woman presents with a rash over her shins. It has gradually been getting worse, despite moisturising. The rash is shown below:

© Image used on license from DermNet NZ

She is otherwise fit and well and has no significant past medical history. She takes the combined oral contraceptive pill and uses a salbutamol inhaler for asthma.

Which of the following is the most likely diagnosis?

- Chronic plaque psoriasis
- Discoid lupus
- Erythema nodosum
- Lichen planus
- Tinea corporis

Submit answer

Reference ranges

Score: **0%**

| | |
|---|---|
| 1 | - |
| 2 | - |
| 3 | - |
| 4 | - |
| 5 | - |
| 6 | - |
| 7 | - |
| 8 | - |
| 9 | - |
| 10 | - |
| 11 | - |
| 12 | - |
| 13 | - |
| 14 | - |
| 15 | - |
| 16 | - |
| 17 | - |
| 18 | - |
| 19 | - |
| 20 | - |
| 21 | - |
| 22 | - |
| 23 | - |
| 24 | - |
| 25 | - |
| 26 | - |
| **27** | - |

All contents of this site are © 2024 Passmedicine Limited

A 32-year-old woman presents with a rash over her shins. It has gradually been getting worse, despite moisturising. The rash is shown below:

© Image used on license from DermNet NZ

She is otherwise fit and well and has no significant past medical history. She takes the combined oral contraceptive pill and uses a salbutamol inhaler for asthma.

Which of the following is the most likely diagnosis?

| | |
|---|---|
| Chronic plaque psoriasis | 51% |
| Discoid lupus | 5% |
| Erythema nodosum | 12% |
| Lichen planus | 32% |
| Tinea corporis | 1% |

The correct answer is chronic plaque psoriasis, which is the most common presentation of psoriasis. The photo demonstrates a typical example of this condition - erythematous plaques covered with a silvery-white scale. There is a clear delineation between the plaques and the surrounding normal skin. What is slightly atypical about this photo is the location - generally, it presents on extensor surfaces such as elbows and knees. These lesions appear to be on the shins.

Discoid lupus would appear somewhat similar, but lesions would be less scaly and more regularly shaped. It is localised to above the neck in 80% of patients, or generalised across the body in the remaining 20% - unlike this presentation on the shins.

Erythema nodosum is inflammation of subcutaneous fat, presenting as tender red nodules on the shins - whilst the location here is correct, the appearance is not. The combined oral contraceptive pill is a known causative factor but, although this patient is taking the pill, the appearance is far more likely to be psoriasis.

Lichen planus is characterised by shiny, flat-topped, violaceous papules which are often clustered around the wrists and ankles. Rather than appearing scaly as in this photo, the papules are crossed by fine white lines called Wickham striae.

Tinea corporis is a fungal infection of the skin, affecting any part of the body. It is colloquially known as ringworm. Its appearance differs from the photo here - rather than scaly plaques, it has a red, ring-shaped appearance with central hypopigmentation.

Discuss (1) | Improve

Next question

## Chronic plaque psoriasis

Chronic plaque psoriasis is the most common form of psoriasis seen in clinical practice, accounting for around 80% of presentations.

Features

- erythematous plaques covered with a silvery-white scale
- typically on the extensor surfaces such as the elbows and knees. Also common on the scalp, trunk, buttocks and periumbilical area
- clear delineation between normal and affected skin
- plaques typically range from 1 to 10 cm in size
- if the scale is removed, a red membrane with pinpoint bleeding points may be seen (Auspitz's sign)

123

Next question

## Textbooks

High-yield textbook

Extended textbook

Score: **28%**

| | |
|---|---|
| 1 | ✗ |
| 2 | ✓ |
| 3 | ✓ |
| 4 | ✗ |
| 5 | ✗ |
| 6 | ✗ |
| 7 | ✗ |
| 8 | ✗ |
| 9 | ✗ |
| 10 | ✗ |
| 11 | ✗ |
| 12 | ✗ |
| 13 | ✓ |
| 14 | ✓ |
| 15 | ✓ |

| | |
|---|---|
| 16 | ✗ |
| 17 | ✓ |
| 18 | ✓ |
| 19 | ✗ |
| 20 | ✗ |
| 21 | ✗ |
| 22 | ✗ |
| 23 | ✗ |
| 24 | ✓ |
| 25 | ✗ |
| 26 | ✓ |
| **27** | ✗ |
| 28 | ✗ |
| 29 | ✗ |
| 30 | ✓ |
| 31 | ✗ |
| 32 | ✗ |
| 33 | ✗ |
| 34 | ✗ |
| 35 | ✓ |
| 36 | ✗ |
| 37 | ✗ |
| 38 | ✗ |
| 39 | ✗ |
| 40 | ✗ |
| 41 | ✗ |
| 42 | ✓ |
| 43 | ✗ |
| 44 | ✗ |
| 45 | ✓ |
| 46 | ✓ |
| 47 | ✗ |
| 48 | ✗ |
| 49 | ✗ |
| 50 | ✗ |

All contents of this site are © 2024 Passmedicine Limited 

A 54-year-old female presented to the dermatology clinic with a history of worsening itchy rash. She has a history of psoriasis which had been quite well controlled but had worsened significantly in the last week. On examination, there are multiple well-demarcated oval, red/pink elevated lesions with overlying silvery scales over her elbows, knees, legs and scalp. She revealed that her GP had started her on a new tablet 2 weeks ago. Which of the following drugs is likely to have resulted in the above presentation?

- Citalopram
- Lithium
- Omeprazole
- Ranitidine
- Cimetidine

Submit answer

Reference ranges

Score: **0%**

1 -
2 -
3 -
4 -
5 -
6 -
7 -
8 -
9 -

10 -
11 -
12 -
13 -
14 -
15 -
16 -
17 -
18 -
19 -
20 -
21 -
22 -
23 -
24 -
25 -
26 -
27 -
**28** -

All contents of this site are © 2024 Passmedicine Limited

Back to top

A 54-year-old female presented to the dermatology clinic with a history of worsening itchy rash. She has a history of psoriasis which had been quite well controlled but had worsened significantly in the last week. On examination, there are multiple well-demarcated oval, red/pink elevated lesions with overlying silvery scales over her elbows, knees, legs and scalp. She revealed that her GP had started her on a new tablet 2 weeks ago. Which of the following drugs is likely to have resulted in the above presentation?

| | |
|---|---|
| Citalopram | 15% |
| Lithium | 64% |
| Omeprazole | 12% |
| Ranitidine | 3% |
| Cimetidine | 5% |

Psoriasis: lithium may trigger an exacerbation

Important for me Less important

Psoriasis can be exacerbated by certain drugs such as:

- lithium
- beta blockers
- antimalarials
- non-steroidal anti-inflammatory drugs
- ACE-inhibitors
- antibiotics such as tetracycline and penicillin

Withdrawal of systemic steroids can also exacerbate psoriasis.

Discuss (3) Improve

Next question

# Psoriasis: exacerbating factors

The following factors may exacerbate psoriasis:

- trauma
- alcohol
- drugs: beta blockers, lithium, antimalarials (chloroquine and hydroxychloroquine), NSAIDs and ACE inhibitors, infliximab
- withdrawal of systemic steroids

Streptococcal infection may trigger guttate psoriasis.

AI + Q 123

Next question >

## Textbooks

High-yield textbook

Extended textbook

## Links

DermNet NZ 21 7

Psoriasis

Suggest link Report broken link

## Media

Psoriasis

Osmosis - YouTube 👍 2 👎 0

Report broken media

Score: **28%**

| | |
|---|---|
| 1 | ✗ |
| 2 | ✓ |
| 3 | ✓ |
| 4 | ✗ |
| 5 | ✗ |
| 6 | ✗ |
| 7 | ✗ |
| 8 | ✗ |
| 9 | ✗ |
| 10 | ✗ |
| 11 | ✗ |
| 12 | ✗ |
| 13 | ✓ |
| 14 | ✓ |
| 15 | ✓ |
| 16 | ✗ |
| 17 | ✓ |
| 18 | ✓ |
| 19 | ✗ |
| 20 | ✗ |
| 21 | ✗ |
| 22 | ✗ |
| 23 | ✗ |

| | |
|---|---|
| 24 | ✓ |
| 25 | ✗ |
| 26 | ✓ |
| 27 | ✗ |
| **28** | ✗ |
| 29 | ✗ |
| 30 | ✓ |
| 31 | ✗ |
| 32 | ✗ |
| 33 | ✗ |
| 34 | ✗ |
| 35 | ✓ |
| 36 | ✗ |
| 37 | ✗ |
| 38 | ✗ |
| 39 | ✗ |
| 40 | ✗ |
| 41 | ✗ |
| 42 | ✓ |
| 43 | ✗ |
| 44 | ✗ |
| 45 | ✓ |
| 46 | ✓ |
| 47 | ✗ |
| 48 | ✗ |
| 49 | ✗ |
| 50 | ✗ |

All contents of this site are © 2024 Passmedicine Limited

Back to top

PassMedicine



This 21-year-old woman has a history of recurrent epistaxis:

© Image used on license from DermNet NZ

What is the most likely underlying diagnosis?

- Idiopathic thrombocytopenic purpura
- Peutz-Jeghers syndrome
- Anorexia nervosa
- Combined oral contraceptive pill use
- Hereditary haemorrhagic telangiectasia

Submit answer

Reference ranges

Score: **0%**

| | |
|---|---|
| 1 | - |
| 2 | - |
| 3 | - |
| 4 | - |
| 5 | - |
| 6 | - |
| 7 | - |
| 8 | - |
| 9 | - |
| 10 | - |
| 11 | - |
| 12 | - |
| 13 | - |
| 14 | - |
| 15 | - |
| 16 | - |
| 17 | - |
| 18 | - |
| 19 | - |
| 20 | - |
| 21 | - |
| 22 | - |
| 23 | - |
| 24 | - |
| 25 | - |
| 26 | - |
| 27 | - |
| 28 | - |
| **29** | - |

All contents of this site are © 2024 Passmedicine Limited

Back to top

This 21-year-old woman has a history of recurrent epistaxis:

© Image used on license from DermNet NZ

What is the most likely underlying diagnosis?

| | |
|---|---|
| Idiopathic thrombocytopenic purpura | 3% |
| Peutz-Jeghers syndrome | 7% |
| Anorexia nervosa | 0% |
| Combined oral contraceptive pill use | 0% |
| Hereditary haemorrhagic telangiectasia | 89% |

The correct answer is **Hereditary haemorrhagic telangiectasia**. This condition, also known as Osler-Weber-Rendu syndrome, is a genetic disorder that leads to abnormal blood vessel formation in the skin, mucous membranes and often in organs such as the lungs, liver and brain. Recurrent epistaxis (nosebleeds) are a common symptom because of the fragile blood vessels in the nasal lining.

**Idiopathic thrombocytopenic purpura** is incorrect. It's an autoimmune disorder where platelets are destroyed by antibodies leading to purpura (small red or purple spots caused by bleeding into the skin), but not typically recurrent nosebleeds. Epistaxis can occur but it's usually accompanied

by other signs of bleeding like petechiae or ecchymosis.

**Peutz-Jeghers syndrome** is also incorrect. This genetic condition results in the development of polyps in the digestive tract and hyperpigmented macules on lips, oral mucosa and digits. While these patients have an increased risk for intestinal bleeding, they do not typically present with recurrent epistaxis.

Next, **Anorexia nervosa** doesn't fit this clinical picture either. Although patients with anorexia nervosa may experience nosebleeds due to dry nasal passages from dehydration, it is not a characteristic feature of this eating disorder.

Lastly, **Combined oral contraceptive pill use** can increase risk of thromboembolic events due to increased oestrogen levels which promote coagulation but it does not cause recurrent epistaxis.

Discuss (1) Improve

Next question

## Hereditary haemorrhagic telangiectasia

Also known as Osler-Weber-Rendu syndrome, hereditary haemorrhagic telangiectasia (HHT) is an autosomal dominant condition characterised by (as the name suggests) multiple telangiectasia over the skin and mucous membranes. Twenty percent of cases occur spontaneously without prior family history.

There are 4 main diagnostic criteria. If the patient has 2 then they are said to have a possible diagnosis of HHT. If they meet 3 or more of the criteria they are said to have a definite diagnosis of HHT:

- epistaxis : spontaneous, recurrent nosebleeds
- telangiectases: multiple at characteristic sites (lips, oral cavity, fingers, nose)
- visceral lesions: for example gastrointestinal telangiectasia (with or without bleeding), pulmonary arteriovenous malformations (AVM), hepatic AVM, cerebral AVM, spinal AVM
- family history: a first-degree relative with HHT

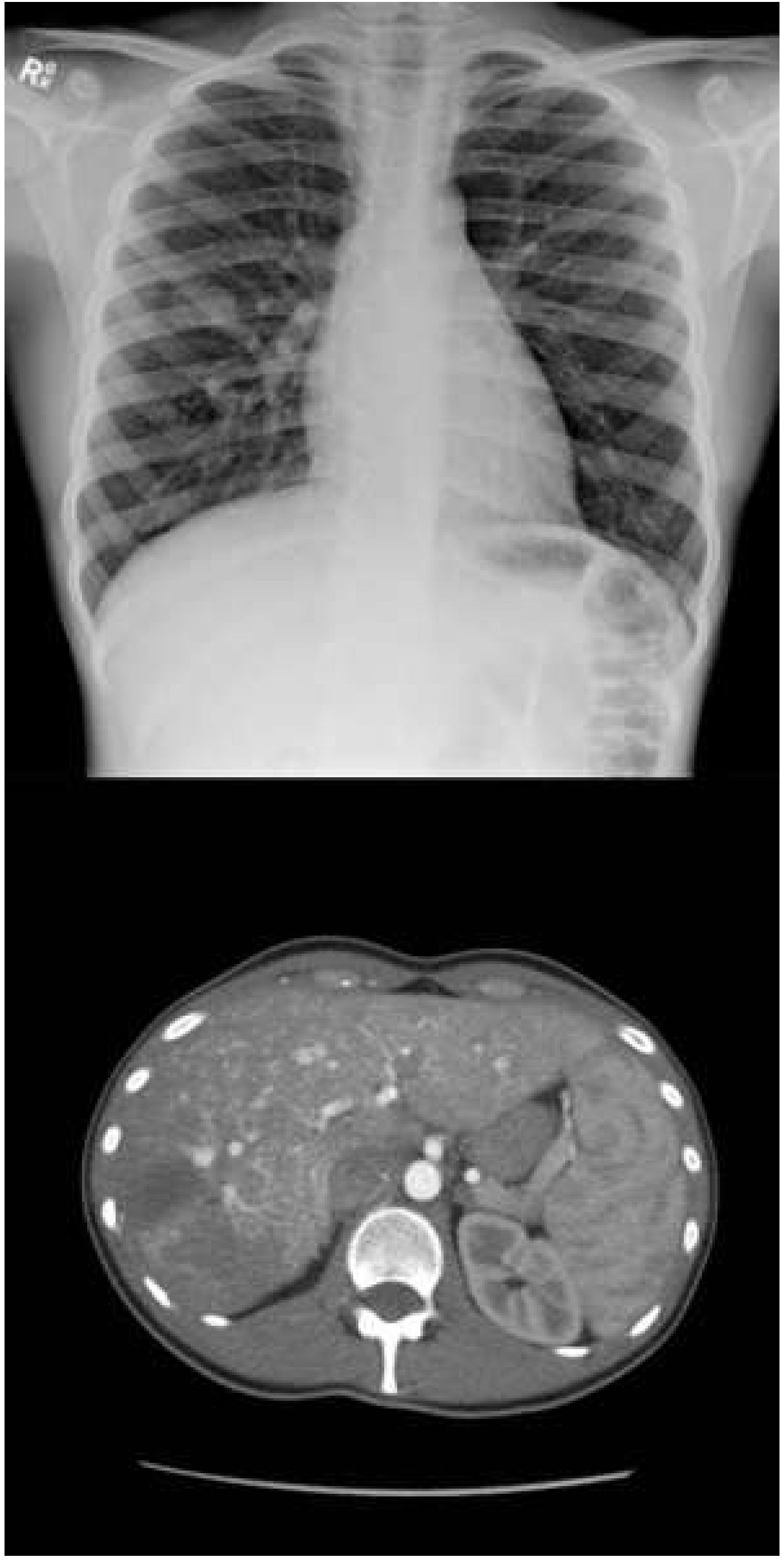

© Image used on license from Radiopaedia

The chest x-ray shows multiple pulmonary nodules representing arteriovenous malformations, the largest in the right mid-zone. The CT scan shows multiple hepatic arteriovenous malformations

123

Next question

## Textbooks

High-yield textbook

Extended textbook

## Links

DermNet NZ 5 6

Hereditary haemorrhagic telangiectasia

Postgraduate Medical Journal 5 1

Review of HHT

Suggest link

Report broken link

Score: **28%**

| | |
|---|---|
| 1 | ✗ |
| 2 | ✓ |
| 3 | ✓ |
| 4 | ✗ |
| 5 | ✗ |
| 6 | ✗ |
| 7 | ✗ |
| 8 | ✗ |
| 9 | ✗ |
| 10 | ✗ |
| 11 | ✗ |
| 12 | ✗ |
| 13 | ✓ |
| 14 | ✓ |
| 15 | ✓ |
| 16 | ✗ |

| | |
|---|---|
| 17 | ✓ |
| 18 | ✓ |
| 19 | ✗ |
| 20 | ✗ |
| 21 | ✗ |
| 22 | ✗ |
| 23 | ✗ |
| 24 | ✓ |
| 25 | ✗ |
| 26 | ✓ |
| 27 | ✗ |
| 28 | ✗ |
| **29** | ✗ |
| 30 | ✓ |
| 31 | ✗ |
| 32 | ✗ |
| 33 | ✗ |
| 34 | ✗ |
| 35 | ✓ |
| 36 | ✗ |
| 37 | ✗ |
| 38 | ✗ |
| 39 | ✗ |
| 40 | ✗ |
| 41 | ✗ |
| 42 | ✓ |
| 43 | ✗ |
| 44 | ✗ |
| 45 | ✓ |
| 46 | ✓ |
| 47 | ✗ |
| 48 | ✗ |
| 49 | ✗ |
| 50 | ✗ |

All contents of this site are © 2024 Passmedicine Limited

PassMedicine



A 43-year-old man presents with a three week history of an itchy rash on the flexor surfaces of his arms. He is generally fit and well and has no history of skin problems.

© Image used on license from DermNet NZ

What is the most likely diagnosis?

- Morphea
- Lichen sclerosus
- Lichen planus
- Psoriasis
- Idiopathic urticaria

Submit answer

Reference ranges

Score: **0%**

All contents of this site are © 2024 Passmedicine Limited

A 43-year-old man presents with a three week history of an itchy rash on the flexor surfaces of his arms. He is generally fit and well and has no history of skin problems.

© Image used on license from DermNet NZ

What is the most likely diagnosis?

| | |
|---|---|
| Morphea | 3% |
| Lichen sclerosus | 7% |
| Lichen planus | 78% |
| Psoriasis | 9% |
| Idiopathic urticaria | 4% |

Discuss Improve

Next question

## Lichen planus

Lichen planus is a skin disorder of unknown aetiology, most probably being immune-mediated.

Features

- itchy, papular rash most common on the palms, soles, genitalia and flexor surfaces of arms
- rash often polygonal in shape, with a 'white-lines' pattern on the surface (Wickham's striae)
- Koebner phenomenon may be seen (new skin lesions appearing at the site of trauma)
- oral involvement in around 50% of patients: typically a white-lace pattern on the buccal mucosa
- nails: thinning of nail plate, longitudinal ridging

Lichenoid drug eruptions - causes:

- gold
- quinine
- thiazides

Management

- potent topical steroids are the mainstay of treatment
- benzydamine mouthwash or spray is recommended for oral lichen planus
- extensive lichen planus may require oral steroids or immunosuppression

123

Next question >

## Textbooks

High-yield textbook

Extended textbook

## Links

Primary Care Dermatology Society 21 7

Lichen planus

DermNet NZ 22 3

Lichen planus

Suggest link Report broken link

## Media

Lichen planus

Osmosis - YouTube 5 1

Report broken media

Score: **28%**

1 ✕

| | |
|---|---|
| 2 | ✓ |
| 3 | ✓ |
| 4 | ✗ |
| 5 | ✗ |
| 6 | ✗ |
| 7 | ✗ |
| 8 | ✗ |
| 9 | ✗ |
| 10 | ✗ |
| 11 | ✗ |
| 12 | ✗ |
| 13 | ✓ |
| 14 | ✓ |
| 15 | ✓ |
| 16 | ✗ |
| 17 | ✓ |
| 18 | ✓ |
| 19 | ✗ |
| 20 | ✗ |
| 21 | ✗ |
| 22 | ✗ |
| 23 | ✗ |
| 24 | ✓ |
| 25 | ✗ |
| 26 | ✓ |
| 27 | ✗ |
| 28 | ✗ |
| 29 | ✗ |
| **30** | ✓ |
| 31 | ✗ |
| 32 | ✗ |
| 33 | ✗ |
| 34 | ✗ |
| 35 | ✓ |
| 36 | ✗ |
| 37 | ✗ |

| | |
|---|---|
| 38 | ✗ |
| 39 | ✗ |
| 40 | ✗ |
| 41 | ✗ |
| 42 | ✓ |
| 43 | ✗ |
| 44 | ✗ |
| 45 | ✓ |
| 46 | ✓ |
| 47 | ✗ |
| 48 | ✗ |
| 49 | ✗ |
| 50 | ✗ |

All contents of this site are © 2024 Passmedicine Limited

Back to top

A 17-year-old boy presents to the dermatology clinic with a facial rash. He reports that the rash has been worsening over the past 6 weeks despite regular facial washing and multiple treatments including topical benzoyl peroxide and clindamycin. He now feels uncomfortable going outside due to feeling uncomfortable with his appearance. His current medications include oral lymecycline which was prescribed by his GP that he has been taking for the last 3 months.

His rash is examined, as shown below:

© Image used on license from DermNet NZ

Given the underlying diagnosis, what is the first-line recommended management for this patient?

- Continue oral lymecycline for further 3 months
- Oral isotretinoin
- Topical corticosteroids
- Topical fusidic acid
- Topical isotretinoin

Submit answer

Reference ranges

Score: **0%**

| | |
|---|---|
| 1 | - |
| 2 | - |
| 3 | - |
| 4 | - |
| 5 | - |
| 6 | - |
| 7 | - |
| 8 | - |
| 9 | - |
| 10 | - |
| 11 | - |
| 12 | - |
| 13 | - |
| 14 | - |
| 15 | - |
| 16 | - |
| 17 | - |
| 18 | - |
| 19 | - |
| 20 | - |
| 21 | - |
| 22 | - |
| 23 | - |
| 24 | - |
| 25 | - |
| 26 | - |
| 27 | - |
| 28 | - |
| 29 | - |

| | |
|---|---|
| 30 | - |
| 31 | - |

All contents of this site are © 2024 Passmedicine Limited

PassMedicine



A 17-year-old boy presents to the dermatology clinic with a facial rash. He reports that the rash has been worsening over the past 6 weeks despite regular facial washing and multiple treatments including topical benzoyl peroxide and clindamycin. He now feels uncomfortable going outside due to feeling uncomfortable with his appearance. His current medications include oral lymecycline which was prescribed by his GP that he has been taking for the last 3 months.

His rash is examined, as shown below:

© Image used on license from DermNet NZ

Given the underlying diagnosis, what is the first-line recommended management for this patient?

| | |
|---|---|
| Continue oral lymecycline for further 3 months | 5% |
| Oral isotretinoin | 53% |
| Topical corticosteroids | 2% |
| Topical fusidic acid | 5% |
| Topical isotretinoin | 34% |

**Oral isotretinoin** is correct. This patient has a diagnosis of acne vulgaris given the presence of

inflammatory macules, papules and pustules in the photograph of this young male. Acne vulgaris is very common, particularly in adolescence. Associated features include comedones which are skin-coloured papules that can either be open (blackheads) or closed (whiteheads). Comedones are associated with increased sebum production and are formed when sebaceous ducts and hair follicles become blocked by debris. Looking closely at this patient's face, the areas of erythema are localised around a pilosebaceous unit. In those with acne vulgaris that has not responded to first-line measures and that are at risk of scarring, NICE guidelines recommend the use of oral isotretinoin.

**Continue oral lymecycline for further 3 months** is incorrect. Guidelines recommend that oral antibiotics should only be continued in the management of acne if the patient is seeing some improvement in their symptoms. As this patient is seeing a progression of symptoms despite antibiotics, an alternative treatment is needed.

**Topical corticosteroids** is incorrect. This is used in the management of inflammatory skin lesions such as eczema or psoriasis. It is not used in the management of acne vulgaris.

**Topical fusidic acid** is incorrect. This is used in the management of superficial bacterial infections such as impetigo and mild cellulitis. Although topical antibiotics can be used in the management of acne vulgaris, fusidic acid is not recommended as per NICE guidelines.

**Topical isotretinoin** is incorrect. This is used in the initial stages of acne management and would not be recommended for the clearance of severe acne that has failed to respond to topical and oral antibiotics.

Discuss (2) | Improve

Next question

## Acne vulgaris: features

Acne is a disease of the pilosebaceous unit. Several different types of acne lesions are usually seen in each patient

Comedones are due to a dilated sebaceous follicle

- if the top is closed a whitehead is seen
- if the top opens a blackhead forms

Inflammatory lesions form when the follicle bursts releasing irritants

- papules

- pustules

An excessive inflammatory response may result in:
- nodules
- cysts

This sequence of events can ultimately cause scarring
- ice-pick scars
- hypertrophic scars

In contrast, **drug-induced acne** is often monomorphic (e.g. pustules are characteristically seen in steroid use)

**Acne fulminans** is very severe acne associated with systemic upset (e.g. fever). Hospital admission is often required and the condition usually responds to oral steroids

+ Q 123

Next question

## Textbooks

High-yield textbook

Extended textbook

## Media

Acne vulgaris

Osmosis - YouTube 👍 1 👎 0

Report broken media

Score: **28%**

| | |
|---|---|
| 1 | ✗ |
| 2 | ✓ |
| 3 | ✓ |
| 4 | ✗ |
| 5 | ✗ |
| 6 | ✗ |
| 7 | ✗ |
| 8 | ✗ |
| 9 | ✗ |
| 10 | ✗ |
| 11 | ✗ |
| 12 | ✗ |
| 13 | ✓ |
| 14 | ✓ |
| 15 | ✓ |
| 16 | ✗ |
| 17 | ✓ |
| 18 | ✓ |
| 19 | ✗ |
| 20 | ✗ |
| 21 | ✗ |
| 22 | ✗ |

| | |
|---|---|
| 23 | ✗ |
| 24 | ✓ |
| 25 | ✗ |
| 26 | ✓ |
| 27 | ✗ |
| 28 | ✗ |
| 29 | ✗ |
| 30 | ✓ |
| **31** | ✗ |
| 32 | ✗ |
| 33 | ✗ |
| 34 | ✗ |
| 35 | ✓ |
| 36 | ✗ |
| 37 | ✗ |
| 38 | ✗ |
| 39 | ✗ |
| 40 | ✗ |
| 41 | ✗ |
| 42 | ✓ |
| 43 | ✗ |
| 44 | ✗ |
| 45 | ✓ |
| 46 | ✓ |
| 47 | ✗ |
| 48 | ✗ |
| 49 | ✗ |
| 50 | ✗ |

All contents of this site are © 2024 Passmedicine Limited

A 78-year-old woman presents with a raised skin lesion on her face:

© Image used on license from DermNet NZ

What is the most likely diagnosis?

- Keratoacanthoma
- Basal cell carcinoma
- Actinic keratosis
- Squamous cell carcinoma
- Malignant melanoma

Submit answer

Reference ranges

Score: **0%**

| | |
|---|---|
| 1 | - |
| 2 | - |
| 3 | - |
| 4 | - |
| 5 | - |
| 6 | - |
| 7 | - |
| 8 | - |
| 9 | - |
| 10 | - |
| 11 | - |
| 12 | - |
| 13 | - |
| 14 | - |
| 15 | - |
| 16 | - |
| 17 | - |
| 18 | - |
| 19 | - |
| 20 | - |
| 21 | - |
| 22 | - |
| 23 | - |
| 24 | - |
| 25 | - |
| 26 | - |
| 27 | - |
| 28 | - |
| 29 | - |
| 30 | - |
| 31 | - |
| **32** | - |

All contents of this site are © 2024 Passmedicine Limited

Back to top

A 78-year-old woman presents with a raised skin lesion on her face:

© Image used on license from DermNet NZ

What is the most likely diagnosis?

| | |
|---|---|
| Keratoacanthoma | 15% |
| Basal cell carcinoma | 48% |
| Actinic keratosis | 20% |
| Squamous cell carcinoma | 16% |
| Malignant melanoma | 2% |

The correct answer is **Basal cell carcinoma**. It is the most common type of skin cancer and typically presents in elderly individuals on sun-exposed areas, such as the face.

**Keratoacanthoma** is an incorrect choice. Although it can appear similar to basal cell carcinoma, Keratoacanthomas tend to grow rapidly over weeks to months and then involute, leaving a scar. They also often have a central keratin-filled crater which is not apparent in this image.

The option **Actinic keratosis** is also incorrect. Actinic keratoses are precancerous lesions that result from chronic sun exposure and present as rough, scaly patches on sun-exposed skin. They

are typically flat rather than raised and lack the pearly appearance seen in this image.

**Squamous cell carcinoma** would be an incorrect answer too. While Squamous cell carcinomas can present as raised lesions on sun-exposed skin, they more commonly appear as erythematous scaly plaques or ulcerated nodules rather than the pearly nodule shown here.

Finally, **Malignant melanoma** is unlikely given this presentation. Malignant melanomas generally present as pigmented lesions with asymmetry, irregular borders, colour variation and diameter greater than 6mm (the 'ABCD' criteria). This lesion does not exhibit these characteristics.

Discuss (3) | Improve

Next question

## Basal cell carcinoma

Basal cell carcinoma (BCC) is one of the three main types of skin cancer. Lesions are also known as rodent ulcers and are characterised by slow-growth and local invasion. Metastases are extremely rare. BCC is the most common type of cancer in the Western world.

Features

- many types of BCC are described. The most common type is nodular BCC, which is described here
- sun-exposed sites, especially the head and neck account for the majority of lesions
- initially a pearly, flesh-coloured papule with telangiectasia
- may later ulcerate leaving a central 'crater'

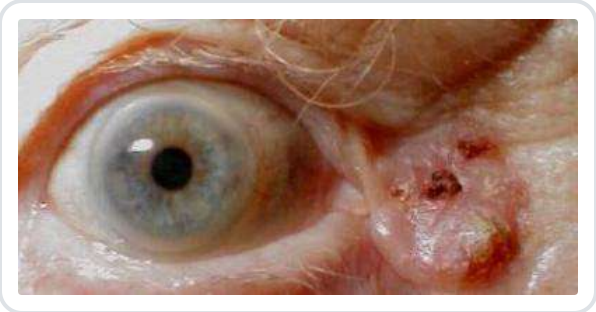

Referral

- generally, if a BCC is suspected, a routine referral should be made

Management options:

- surgical removal
- curettage
- cryotherapy
- topical cream: imiquimod, fluorouracil
- radiotherapy

+ Q 123

Next question >

## Textbooks

High-yield textbook

Extended textbook

## Links

DermNet NZ 21 7

Basal cell carcinoma

Suggest link Report broken link

## Media

Skin cancers

Osmosis - YouTube 4 2

Report broken media

Score: **28%**

| | |
|---|---|
| 1 | ✗ |
| 2 | ✓ |
| 3 | ✓ |
| 4 | ✗ |
| 5 | ✗ |
| 6 | ✗ |
| 7 | ✗ |
| 8 | ✗ |
| 9 | ✗ |
| 10 | ✗ |
| 11 | ✗ |
| 12 | ✗ |
| 13 | ✓ |
| 14 | ✓ |
| 15 | ✓ |
| 16 | ✗ |
| 17 | ✓ |
| 18 | ✓ |
| 19 | ✗ |
| 20 | ✗ |
| 21 | ✗ |
| 22 | ✗ |
| 23 | ✗ |

| | |
|---|---|
| 24 | ✓ |
| 25 | ✗ |
| 26 | ✓ |
| 27 | ✗ |
| 28 | ✗ |
| 29 | ✗ |
| 30 | ✓ |
| 31 | ✗ |
| **32** | ✗ |
| 33 | ✗ |
| 34 | ✗ |
| 35 | ✓ |
| 36 | ✗ |
| 37 | ✗ |
| 38 | ✗ |
| 39 | ✗ |
| 40 | ✗ |
| 41 | ✗ |
| 42 | ✓ |
| 43 | ✗ |
| 44 | ✗ |
| 45 | ✓ |
| 46 | ✓ |
| 47 | ✗ |
| 48 | ✗ |
| 49 | ✗ |
| 50 | ✗ |

All contents of this site are © 2024 Passmedicine Limited

Back to top

A 30-year-old cleaner presents with a four-week history of recurrent vesicular lesions on her hands. She describes these lesions as initially appearing on the sides of her fingers before progressing to more generalised vesicles on her palms. They then break down and become intensely itchy, dry and cracked. She has tried using over the counter moisturisers but these have not helped.

She finds that the cleaning products she works with makes the rash worse and has been wearing rubber gloves to try and avoid this happening. She has also taken the past two weeks off work due to the cracked and inflamed skin on her hands.

She has no past medical history of note but does describe an allergy to nickel at the age of 14 around the time of her first ear piercings.

She currently takes the oral contraceptive pill.

On examination, you find linear 1-2mm vesicles along most of her digits with evidence of lichenification, cracking and inflamed skin. There is no evidence of any other skin rash elsewhere.

What is the most likely diagnosis?

- Digital Herpes Simplex
- Irritant contact dermatitis
- Pompholyx
- Pustular psoriasis
- Allergic contact dermatitis

Submit answer

Reference ranges

Score: **0%**

| | |
|---|---|
| 1 | - |
| 2 | - |
| 3 | - |
| 4 | - |
| 5 | - |
| 6 | - |
| 7 | - |
| 8 | - |
| 9 | - |
| 10 | - |
| 11 | - |
| 12 | - |
| 13 | - |
| 14 | - |
| 15 | - |
| 16 | - |
| 17 | - |
| 18 | - |
| 19 | - |
| 20 | - |
| 21 | - |
| 22 | - |
| 23 | - |
| 24 | - |
| 25 | - |
| 26 | - |
| 27 | - |
| 28 | - |
| 29 | - |
| 30 | - |
| 31 | - |
| 32 | - |
| **33** | - |

All contents of this site are © 2024 Passmedicine Limited

Back to top

A 30-year-old cleaner presents with a four-week history of recurrent vesicular lesions on her hands. She describes these lesions as initially appearing on the sides of her fingers before progressing to more generalised vesicles on her palms. They then break down and become intensely itchy, dry and cracked. She has tried using over the counter moisturisers but these have not helped.

She finds that the cleaning products she works with makes the rash worse and has been wearing rubber gloves to try and avoid this happening. She has also taken the past two weeks off work due to the cracked and inflamed skin on her hands.

She has no past medical history of note but does describe an allergy to nickel at the age of 14 around the time of her first ear piercings.

She currently takes the oral contraceptive pill.

On examination, you find linear 1-2mm vesicles along most of her digits with evidence of lichenification, cracking and inflamed skin. There is no evidence of any other skin rash elsewhere.

What is the most likely diagnosis?

| | |
|---|---|
| Digital Herpes Simplex | 2% |
| Irritant contact dermatitis | 44% |
| Pompholyx | 37% |
| Pustular psoriasis | 3% |
| Allergic contact dermatitis | 15% |

This is a classic history of pompholyx eczema. It typically affects the hands (80% of the time) or the feet (12%), or both and presents with small vesicles along the digits and palms/soles. These then de-roof causing intense itching and drying of the skin.

Pompholyx eczema has been associated with a nickel allergy.

The other answers can also present with vesicular eruptions on the hands but the clinical presentations are different.

Herpetic whitlow would lead to a painful outcrop of vesicles and would be unlikely to cause lesions at multiple sites in an immunocompetent person.

Pustular psoriasis is an acute form of psoriasis which leads to widespread pustules with systemic upset.

Irritant and allergic contact dermatitis can present similarly to pompholyx eczema but are as a result of contact with an irritant or allergen. As a cleaner and with a nickel allergy she could be susceptible to both these conditions. However the fact that she has been wearing rubber gloves and has removed herself from potential contacts suggests that a specific chemical is unlikely to be the cause of her symptoms.

Discuss (5) | Improve

Next question

## Pompholyx

Pompholyx is a type of eczema which affects both the hands (cheiropompholyx) and the feet (pedopompholyx). It is also known as dyshidrotic eczema.

Pompholyx eczema may be precipitated by humidity (e.g. sweating) and high temperatures.

Features
- small blisters on the palms and soles
- pruritic
  - often intensely itchy
  - sometimes burning sensation
- once blisters burst skin may become dry and crack

Management
- cool compresses
- emollients
- topical steroids

123

Next question

## Textbooks

High-yield textbook

Extended textbook

## Links

Dermnet NZ 18 4

Photos of pompholyx

Suggest link

Report broken link

Score: **28%**

1 ✗
2 ✓
3 ✓
4 ✗
5 ✗
6 ✗
7 ✗
8 ✗

| | |
|---|---|
| 9 | ✗ |
| 10 | ✗ |
| 11 | ✗ |
| 12 | ✗ |
| 13 | ✓ |
| 14 | ✓ |
| 15 | ✓ |
| 16 | ✗ |
| 17 | ✓ |
| 18 | ✓ |
| 19 | ✗ |
| 20 | ✗ |
| 21 | ✗ |
| 22 | ✗ |
| 23 | ✗ |
| 24 | ✓ |
| 25 | ✗ |
| 26 | ✓ |
| 27 | ✗ |
| 28 | ✗ |
| 29 | ✗ |
| 30 | ✓ |
| 31 | ✗ |
| 32 | ✗ |
| **33** | ✗ |
| 34 | ✗ |
| 35 | ✓ |
| 36 | ✗ |
| 37 | ✗ |
| 38 | ✗ |
| 39 | ✗ |
| 40 | ✗ |
| 41 | ✗ |
| 42 | ✓ |
| 43 | ✗ |
| 44 | ✗ |

| | |
|---|---|
| 45 | ✓ |
| 46 | ✓ |
| 47 | ✗ |
| 48 | ✗ |
| 49 | ✗ |
| 50 | ✗ |

All contents of this site are © 2024 Passmedicine Limited

A 27-year-old man presents as he is feeling generally unwell. Around 5 days ago he started having a sore throat associated with myalgia and lethargy. Yesterday he developed a fever and over the course of the past 24 hours a rash has appeared. His past medical history includes anxiety and atopic eczema. On examination he has a widespread erythematous rash, with many of the lesions having a 'target' appearance. Some of the lesions are becoming bullous. His pulse is 120/min and temperature 38.4º. He also has conjunctivitis and some ulceration and sloughing around the mouth:

© Image used on license from DermNet NZ

What is the most likely diagnosis?

- Eczema herpeticum
- Pemphigus vulgaris
- Erythema multiforme major
- Impetigo
- Necrotizing fasciitis

Submit answer

Reference ranges

Score: **0%**

| | |
|---|---|
| 1 | - |
| 2 | - |
| 3 | - |
| 4 | - |
| 5 | - |
| 6 | - |
| 7 | - |
| 8 | - |
| 9 | - |
| 10 | - |
| 11 | - |
| 12 | - |
| 13 | - |
| 14 | - |
| 15 | - |
| 16 | - |
| 17 | - |
| 18 | - |
| 19 | - |
| 20 | - |
| 21 | - |
| 22 | - |
| 23 | - |
| 24 | - |
| 25 | - |
| 26 | - |
| 27 | - |
| 28 | - |
| 29 | - |
| 30 | - |
| 31 | - |
| 32 | - |
| 33 | - |

| | |
|---|---|
| **34** | - |

All contents of this site are © 2024 Passmedicine Limited

A 27-year-old man presents as he is feeling generally unwell. Around 5 days ago he started having a sore throat associated with myalgia and lethargy. Yesterday he developed a fever and over the course of the past 24 hours a rash has appeared. His past medical history includes anxiety and atopic eczema. On examination he has a widespread erythematous rash, with many of the lesions having a 'target' appearance. Some of the lesions are becoming bullous. His pulse is 120/min and temperature 38.4º. He also has conjunctivitis and some ulceration and sloughing around the mouth:

© Image used on license from DermNet NZ

What is the most likely diagnosis?

- Eczema herpeticum 6%
- Pemphigus vulgaris 18%
- Erythema multiforme major 72%
- Impetigo 2%
- Necrotizing fasciitis 2%

The correct answer in this case is **Erythema multiforme major**. Erythema multiforme is an acute, immune-mediated skin condition that typically presents with target-like lesions on the skin and mucous membranes. In this patient, the history of a sore throat followed by fever, myalgia, and

lethargy along with the appearance of a widespread erythematous rash with target lesions and mucosal involvement (conjunctivitis and oral ulceration) strongly suggest erythema multiforme major. This condition can be triggered by infections (commonly herpes simplex virus or mycoplasma pneumoniae) or medications.

**Eczema herpeticum** is an incorrect option as it is a complication of atopic eczema where there is an extensive infection with herpes simplex virus. It presents with clusters of painful vesicles on an erythematous base that may rupture and form erosions. Although the patient has a history of atopic eczema, the presentation with target lesions and mucosal involvement makes erythema multiforme major more likely.

**Pemphigus vulgaris** is an autoimmune blistering disorder characterized by intraepidermal blisters involving both the skin and mucous membranes. The clinical presentation may include bullae that rupture easily, leaving painful erosions. However, the sudden onset of symptoms following a sore throat and fever in this case make it less likely than erythema multiforme major.

**Impetigo** is a superficial bacterial skin infection caused mainly by *Staphylococcus aureus* or *Streptococcus pyogenes*. It presents as honey-colored crusted lesions or small fluid-filled blisters that may rupture. The widespread rash involving multiple areas of the body along with systemic symptoms such as fever and myalgia make erythema multiforme major a more appropriate diagnosis.

Lastly, **necrotizing fasciitis** is a rapidly progressive bacterial infection involving the subcutaneous tissue and fascia. It presents with severe pain, erythema, and edema that rapidly progress to necrosis and systemic symptoms such as fever and hypotension. The presence of target lesions, mucosal involvement, and the absence of severe pain or rapid progression of symptoms in this case make erythema multiforme major more likely than necrotizing fasciitis.

Discuss (4) | Improve

Next question ›

## Erythema multiforme ★

Erythema multiforme is a hypersensitivity reaction that is most commonly triggered by infections. It may be divided into minor and major forms.

Previously it was thought that Stevens-Johnson syndrome (SJS) was a severe form of erythema multiforme. They are now however considered as separate entities.

Features

- target lesions
- initially seen on the back of the hands / feet before spreading to the torso
- upper limbs are more commonly affected than the lower limbs
- pruritus is occasionally seen and is usually mild

Causes

- viruses: herpes simplex virus (the most common cause), Orf*
- idiopathic
- bacteria: *Mycoplasma*, *Streptococcus*
- drugs: penicillin, sulphonamides, carbamazepine, allopurinol, NSAIDs, oral contraceptive pill, nevirapine
- connective tissue disease e.g. Systemic lupus erythematosus
- sarcoidosis
- malignancy

## Erythema multiforme major

The more severe form, erythema multiforme major is associated with mucosal involvement.

*Orf is a skin disease of sheep and goats caused by a parapox virus

123

Next question

## Textbooks

High-yield textbook

Extended textbook

## Links

DermNet NZ 18 10

Erythema multiforme

Suggest link

Report broken link

## Media

Erythema multiforme

Osmosis - YouTube 1 0

Report broken media

Score: **28%**

| | |
|---|---|
| 1 | ✗ |
| 2 | ✓ |
| 3 | ✓ |
| 4 | ✗ |
| 5 | ✗ |
| 6 | ✗ |
| 7 | ✗ |
| 8 | ✗ |
| 9 | ✗ |
| 10 | ✗ |
| 11 | ✗ |
| 12 | ✗ |
| 13 | ✓ |
| 14 | ✓ |
| 15 | ✓ |
| 16 | ✗ |
| 17 | ✓ |
| 18 | ✓ |
| 19 | ✗ |
| 20 | ✗ |
| 21 | ✗ |
| 22 | ✗ |
| 23 | ✗ |
| 24 | ✓ |
| 25 | ✗ |
| 26 | ✓ |
| 27 | ✗ |
| 28 | ✗ |
| 29 | ✗ |
| 30 | ✓ |
| 31 | ✗ |
| 32 | ✗ |
| 33 | ✗ |
| **34** | ✗ |

| | |
|---|---|
| 35 | ✓ |
| 36 | ✗ |
| 37 | ✗ |
| 38 | ✗ |
| 39 | ✗ |
| 40 | ✗ |
| 41 | ✗ |
| 42 | ✓ |
| 43 | ✗ |
| 44 | ✗ |
| 45 | ✓ |
| 46 | ✓ |
| 47 | ✗ |
| 48 | ✗ |
| 49 | ✗ |
| 50 | ✗ |

All contents of this site are © 2024 Passmedicine Limited

Back to top

A 12-year-old boy is brought with a persistent 'scab' above his right ear. His mother reports that it has slowly developed over the past few weeks and initially started out as a patch of 'dandruff'. He is systemically well and their is no past medical history of note. The lesion is shown below:

© Image used on license from DermNet NZ

What is the most likely diagnosis?

- Seborrhoeic dermatitis
- Trichotillomania
- Impetigo
- Scalp psoriasis
- Kerion

Submit answer

Reference ranges

Score: **0%**

| | |
|---|---|
| 1 | - |
| 2 | - |
| 3 | - |
| 4 | - |
| 5 | - |
| 6 | - |
| 7 | - |
| 8 | - |
| 9 | - |
| 10 | - |
| 11 | - |
| 12 | - |
| 13 | - |
| 14 | - |
| 15 | - |
| 16 | - |
| 17 | - |
| 18 | - |
| 19 | - |
| 20 | - |
| 21 | - |
| 22 | - |
| 23 | - |
| 24 | - |
| 25 | - |
| 26 | - |
| 27 | - |
| 28 | - |
| 29 | - |
| 30 | - |
| 31 | - |
| 32 | - |
| 33 | - |
| 34 | - |

| | |
|---|---|
| **35** | - |

All contents of this site are © 2024 Passmedicine Limited 

A 12-year-old boy is brought with a persistent 'scab' above his right ear. His mother reports that it has slowly developed over the past few weeks and initially started out as a patch of 'dandruff'. He is systemically well and their is no past medical history of note. The lesion is shown below:

© Image used on license from DermNet NZ

What is the most likely diagnosis?

| | |
|---|---|
| Seborrhoeic dermatitis | 29% |
| Trichotillomania | 6% |
| Impetigo | 5% |
| Scalp psoriasis | 12% |
| Kerion | 47% |

The kerion has developed as a result of an untreated tinea capitis infection. Systemic antifungals are usually required.

Discuss (2) Improve

Next question

# Tinea

Tinea is a term given to dermatophyte fungal infections. Three main types of infection are described depending on what part of the body is infected

- tinea capitis - scalp
- tinea corporis - trunk, legs or arms
- tinea pedis - feet

Tinea capitis (scalp ringworm)

- a cause of scarring alopecia mainly seen in children
- if untreated a raised, pustular, spongy/boggy mass called a kerion may form
- most common cause is *Trichophyton tonsurans* in the UK and the USA
- may also be caused by *Microsporum canis* acquired from cats or dogs
- diagnosis: lesions due to *Microsporum canis* green fluorescence under Wood's lamp*. However the most useful investigation is scalp scrapings
- management (based on NICE guidelines): oral antifungals: terbinafine for *Trichophyton tonsurans* infections and griseofulvin for *Microsporum* infections. Topical ketoconazole shampoo should be given for the first two weeks to reduce transmission

Tinea corporis (ringworm)

- causes include *Trichophyton rubrum* and *Trichophyton verrucosum* (e.g. From contact with cattle)
- well-defined annular, erythematous lesions with pustules and papules
- may be treated with oral fluconazole

Tinea pedis (athlete's foot)

- characterised by itchy, peeling skin between the toes
- common in adolescence

*lesions due to *Trichophyton* species do not readily fluoresce under Wood's lamp

123

Next question

## Textbooks

High-yield textbook

Extended textbook

## Links

Clinical Knowledge Summaries 6 11

Fungal skin infection - scalp

Suggest link Report broken link

Score: **28%**

| | |
|---|---|
| 1 | ✗ |
| 2 | ✓ |
| 3 | ✓ |
| 4 | ✗ |
| 5 | ✗ |
| 6 | ✗ |
| 7 | ✗ |
| 8 | ✗ |
| 9 | ✗ |
| 10 | ✗ |
| 11 | ✗ |
| 12 | ✗ |
| 13 | ✓ |
| 14 | ✓ |
| 15 | ✓ |
| 16 | ✗ |
| 17 | ✓ |
| 18 | ✓ |
| 19 | ✗ |
| 20 | ✗ |
| 21 | ✗ |
| 22 | ✗ |
| 23 | ✗ |
| 24 | ✓ |
| 25 | ✗ |
| 26 | ✓ |
| 27 | ✗ |
| 28 | ✗ |
| 29 | ✗ |
| 30 | ✓ |
| 31 | ✗ |
| 32 | ✗ |
| 33 | ✗ |

| | |
|---|---|
| 34 | ✗ |
| **35** | ✓ |
| 36 | ✗ |
| 37 | ✗ |
| 38 | ✗ |
| 39 | ✗ |
| 40 | ✗ |
| 41 | ✗ |
| 42 | ✓ |
| 43 | ✗ |
| 44 | ✗ |
| 45 | ✓ |
| 46 | ✓ |
| 47 | ✗ |
| 48 | ✗ |
| 49 | ✗ |
| 50 | ✗ |

All contents of this site are © 2024 Passmedicine Limited

Back to top

A 64-year-old man presents with a 'rash' on his legs which has developed over the past few days:

© Image used on license from DermNet NZ

He complains of feeling generally 'run-down' but review of systems is unremarkable. What is the most likely underlying cause?

- Vasculitis
- Erythema multiforme
- Necrotising fasciitis
- Kaposi sarcoma
- Venous eczema

Submit answer

Reference ranges

Score: **0%**

| | |
|---|---|
| 1 | - |
| 2 | - |
| 3 | - |
| 4 | - |
| 5 | - |
| 6 | - |
| 7 | - |
| 8 | - |
| 9 | - |
| 10 | - |
| 11 | - |
| 12 | - |
| 13 | - |
| 14 | - |
| 15 | - |
| 16 | - |
| 17 | - |
| 18 | - |
| 19 | - |
| 20 | - |
| 21 | - |
| 22 | - |
| 23 | - |
| 24 | - |
| 25 | - |
| 26 | - |
| 27 | - |
| 28 | - |
| 29 | - |
| 30 | - |
| 31 | - |
| 32 | - |
| 33 | - |
| 34 | - |

| | |
|---|---|
| 35 | - |
| **36** | - |

All contents of this site are © 2024 Passmedicine Limited

A 64-year-old man presents with a 'rash' on his legs which has developed over the past few days:

© Image used on license from DermNet NZ

He complains of feeling generally 'run-down' but review of systems is unremarkable. What is the most likely underlying cause?

| | |
|---|---|
| Vasculitis | 60% |
| Erythema multiforme | 7% |
| Necrotising fasciitis | 3% |
| Kaposi sarcoma | 10% |
| Venous eczema | 20% |

Kaposi sarcoma may cause similar skin changes to the larger lesions but would not typically cause petechiae.

Vasculitis is commonly limited to the skin and may be caused by infections, drugs, autoimmune disorders and malignancy.

Discuss (2) Improve

Next question

## Vasculitides

Large vessel
- temporal arteritis
- Takayasu's arteritis

Medium vessel
- polyarteritis nodosa
- Kawasaki disease

Small vessel
- ANCA-associated vasculitides
  - granulomatosis with polyangiitis (Wegener's granulomatosis)
  - eosinophilic granulomatosis with polyangiitis (Churg-Strauss syndrome)
  - microscopic polyangiitis
- immune complex small-vessel vasculitis
  - Henoch-Schonlein purpura
  - Goodpasture's syndrome (anti-glomerular basement membrane disease)
  - cryoglobulinaemic vasculitis
  - hypocomplementemic urticarial vasculitis (anti-C1q vasculitis)

+ Q 123

Next question

## Textbooks

High-yield textbook

Extended textbook

## Links

DermNet NZ 4 2

Cutaneous vasculitis

Patient.info 5 0

Vasculitis review

Suggest link

Report broken link

## Media

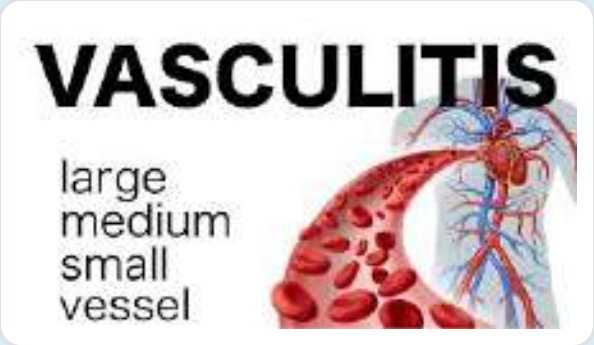


Vasculitis

Dirty USMLE - YouTube 6 0

Vasculitis

Osmosis - YouTube 1 0

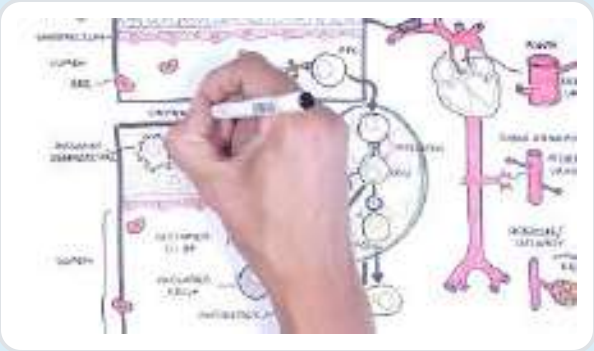

[Vasculitis Pathophysiology Overview]

Armando Hasudungan - YouTube 👍 2 👎 1

Report broken media

Score: **28%**

| | |
|---|---|
| 1 | ✗ |
| 2 | ✓ |
| 3 | ✓ |
| 4 | ✗ |
| 5 | ✗ |
| 6 | ✗ |
| 7 | ✗ |
| 8 | ✗ |
| 9 | ✗ |
| 10 | ✗ |
| 11 | ✗ |
| 12 | ✗ |
| 13 | ✓ |
| 14 | ✓ |
| 15 | ✓ |
| 16 | ✗ |
| 17 | ✓ |
| 18 | ✓ |
| 19 | ✗ |
| 20 | ✗ |
| 21 | ✗ |
| 22 | ✗ |
| 23 | ✗ |

| | |
|---|---|
| 24 | ✓ |
| 25 | ✗ |
| 26 | ✓ |
| 27 | ✗ |
| 28 | ✗ |
| 29 | ✗ |
| 30 | ✓ |
| 31 | ✗ |
| 32 | ✗ |
| 33 | ✗ |
| 34 | ✗ |
| 35 | ✓ |
| **36** | ✗ |
| 37 | ✗ |
| 38 | ✗ |
| 39 | ✗ |
| 40 | ✗ |
| 41 | ✗ |
| 42 | ✓ |
| 43 | ✗ |
| 44 | ✗ |
| 45 | ✓ |
| 46 | ✓ |
| 47 | ✗ |
| 48 | ✗ |
| 49 | ✗ |
| 50 | ✗ |

All contents of this site are © 2024 Passmedicine Limited

Back to top

PassMedicine



A 20-year-old woman presents to the medical clinic for review. She had been started by her GP on bisoprolol following an episode of palpitations and has subsequently developed a rash affecting her elbows, knees, navel genital area. It has been itchy but not painful, and she has not had any further episodes of palpitations. She has previously had eczema as a young child but this disappeared before the age of five. She has no allergies as far as she knows. On examination, she has a well defined erythematous rash of extensor surfaces of her elbows, knees, umbilicus and groin. What is the most likely diagnosis?

- Allergy to bisoprolol
- Psoriasis
- Topical dermatitis
- Eczema
- Cellulitis

Submit answer

Reference ranges

Score: **0%**

1 -
2 -
3 -
4 -
5 -
6 -
7 -
8 -

9 -
10 -
11 -
12 -
13 -
14 -
15 -
16 -
17 -
18 -
19 -
20 -
21 -
22 -
23 -
24 -
25 -
26 -
27 -
28 -
29 -
30 -
31 -
32 -
33 -
34 -
35 -
36 -
**37** -

All contents of this site are © 2024 Passmedicine Limited
Back to top

A 20-year-old woman presents to the medical clinic for review. She had been started by her GP on bisoprolol following an episode of palpitations and has subsequently developed a rash affecting her elbows, knees, navel genital area. It has been itchy but not painful, and she has not had any further episodes of palpitations. She has previously had eczema as a young child but this disappeared before the age of five. She has no allergies as far as she knows. On examination, she has a well defined erythematous rash of extensor surfaces of her elbows, knees, umbilicus and groin. What is the most likely diagnosis?

| | |
|---|---|
| Allergy to bisoprolol | 9% |
| Psoriasis | 76% |
| Topical dermatitis | 5% |
| Eczema | 10% |
| Cellulitis | 0% |

Flexural psoriasis is characterised by well defined, erythematous, non-painful rash

Important for me Less important

This is a patient who has developed a well-defined erythematous and pruritic rash of extensor surfaces following the use of a beta-blocker. The most likely explanation is psoriasis. In the progression of the condition, the typical plaques can form. For this patient, the first presentation has been triggered by beta-blockers; this is a known effect of beta-blockers which limits their use for people with psoriasis.

This is a very unlikely description of a drug allergy. The onset is faster with a systemic rash involving the trunk which is macular and poorly defined.

In topical dermatitis, there are defined areas of inflammation in areas of contact with an irritant.

Eczema is also unlikely; eczema affects flexural rather than extensor surfaces.

Discuss (3) Improve

Next question >

# Psoriasis

Psoriasis is a common (prevalence around 2%) and chronic skin disorder. It generally presents with red, scaly patches on the skin although it is now recognised that patients with psoriasis are at increased risk of arthritis and cardiovascular disease.

Pathophysiology

- multifactorial and not yet fully understood
- genetic: associated HLA-B13, -B17, and -Cw6. Strong concordance (70%) in identical twins
- immunological: abnormal T cell activity stimulates keratinocyte proliferation. There is increasing evidence this may be mediated by a novel group of T helper cells producing IL-17, designated Th17. These cells seem to be a third T-effector cell subset in addition to Th1 and Th2
- environmental: it is recognised that psoriasis may be worsened (e.g. Skin trauma, stress), triggered (e.g. Streptococcal infection) or improved (e.g. Sunlight) by environmental factors

Recognised subtypes of psoriasis

- plaque psoriasis: the most common sub-type resulting in the typical well-demarcated red, scaly patches affecting the extensor surfaces, sacrum and scalp
- flexural psoriasis: in contrast to plaque psoriasis the skin is smooth
- guttate psoriasis: transient psoriatic rash frequently triggered by a streptococcal infection. Multiple red, teardrop lesions appear on the body
- pustular psoriasis: commonly occurs on the palms and soles

Other features

- nail signs: pitting, onycholysis
- arthritis

Complications

- psoriatic arthropathy (around 10%)
- increased incidence of metabolic syndrome
- increased incidence of cardiovascular disease
- increased incidence of venous thromboembolism
- psychological distress

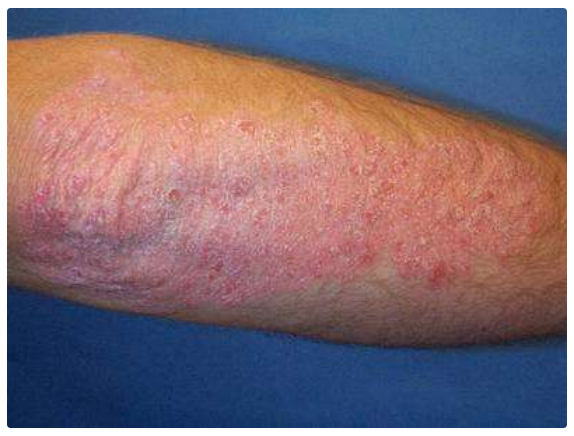

123

Next question

## Textbooks

High-yield textbook

Extended textbook

## Links

DermNet NZ 3 3

Scalp psoriasis

SIGN 4 0

2010 Psoriasis guidelines

Suggest link Report broken link

## Media

[Psoriasis]

Osmosis - YouTube 2 0

Report broken media

Score: **28%**

| | |
|---|---|
| 1 | ✗ |
| 2 | ✓ |
| 3 | ✓ |
| 4 | ✗ |
| 5 | ✗ |
| 6 | ✗ |
| 7 | ✗ |
| 8 | ✗ |
| 9 | ✗ |
| 10 | ✗ |
| 11 | ✗ |
| 12 | ✗ |
| 13 | ✓ |
| 14 | ✓ |
| 15 | ✓ |
| 16 | ✗ |
| 17 | ✓ |
| 18 | ✓ |
| 19 | ✗ |
| 20 | ✗ |
| 21 | ✗ |
| 22 | ✗ |
| 23 | ✗ |

| | |
|---|---|
| 24 | ✓ |
| 25 | ✗ |
| 26 | ✓ |
| 27 | ✗ |
| 28 | ✗ |
| 29 | ✗ |
| 30 | ✓ |
| 31 | ✗ |
| 32 | ✗ |
| 33 | ✗ |
| 34 | ✗ |
| 35 | ✓ |
| 36 | ✗ |
| **37** | ✗ |
| 38 | ✗ |
| 39 | ✗ |
| 40 | ✗ |
| 41 | ✗ |
| 42 | ✓ |
| 43 | ✗ |
| 44 | ✗ |
| 45 | ✓ |
| 46 | ✓ |
| 47 | ✗ |
| 48 | ✗ |
| 49 | ✗ |
| 50 | ✗ |

All contents of this site are © 2024 Passmedicine Limited

Back to top

A 24-year-old man with a history of ulcerative colitis presents due to an expanding 'blood blister' on his lower leg:

© Image used on license from DermNet NZ

What is the most likely diagnosis?

- Pyogenic granuloma
- Arterial leg ulcer
- Necrotising fasciitis
- Venous leg ulcer
- Pyoderma gangrenosum

Submit answer

Reference ranges

Score: **0%**

1 -
2 -
3 -
4 -
5 -
6 -
7 -
8 -
9 -
10 -
11 -
12 -
13 -
14 -
15 -
16 -
17 -
18 -
19 -
20 -
21 -
22 -
23 -
24 -
25 -
26 -
27 -
28 -
29 -
30 -
31 -
32 -
33 -
34 -
35 -
36 -
37 -

| | |
|---|---|
| **38** | - |

All contents of this site are © 2024 Passmedicine Limited

A 24-year-old man with a history of ulcerative colitis presents due to an expanding 'blood blister' on his lower leg:

© Image used on license from DermNet NZ

What is the most likely diagnosis?

- Pyogenic granuloma 12%
- Arterial leg ulcer 1%
- Necrotising fasciitis 2%
- Venous leg ulcer 2%
- Pyoderma gangrenosum 83%

The correct answer is **Pyoderma gangrenosum**. Pyoderma gangrenosum is a rare, inflammatory skin condition often associated with systemic diseases such as inflammatory bowel disease (IBD), which includes ulcerative colitis. The patient's history of ulcerative colitis and the appearance of the lesion - a rapidly enlarging, painful ulcer with a violaceous border - are characteristic features of pyoderma gangrenosum. It is also important to note that pyoderma gangrenosum can be precipitated by minor trauma or surgical procedures.

**Pyogenic granuloma**, although it can appear similar to pyoderma gangrenosum, typically

presents as a small, red, vascular lesion that bleeds easily. They are usually solitary and occur after minor trauma. While they can occur anywhere on the body, they most commonly appear on the hands and face.

An **Arterial leg ulcer** would be an unusual presentation in such a young patient without risk factors for peripheral arterial disease (PAD). These ulcers typically present on the lateral aspect of the ankle or foot and are characterised by severe pain, especially at night or with elevation of the limb. Additionally, there would often be signs of peripheral arterial disease such as absence of pulses or claudication.

**Necrotising fasciitis** is a life-threatening soft tissue infection causing rapidly progressive skin necrosis and systemic toxicity. Although it could theoretically present similarly to this case, it would likely have been accompanied by severe systemic symptoms like fever and hypotension which are not mentioned in the scenario.

A **Venous leg ulcer** tends to occur in older patients with a history of chronic venous insufficiency or deep vein thrombosis (DVT). The ulcers usually develop around the medial malleolus and are often accompanied by other signs of chronic venous insufficiency such as varicose veins, oedema and skin changes like hyperpigmentation or lipodermatosclerosis.

Discuss | Improve

Next question

## Pyoderma gangrenosum

Pyoderma gangrenosum is a rare, non-infectious, inflammatory disorder. It is an uncommon cause of very painful skin ulceration. It may affect any part of the skin, but the lower legs are the most common site.

Pathophysiology
- pyoderma gangrenosum is classified as a neutrophilic dermatosis
- neutrophilic dermatoses are skin conditions characterised by dense infiltration of neutrophils in the affected tissue and this is often seen on biopsy

Causes
- idiopathic in 50%
- inflammatory bowel disease in 10-15%
  - ulcerative colitis
  - Crohn's

- rheumatological
  - rheumatoid arthritis
  - SLE
- haematological
  - myeloproliferative disorders
  - lymphoma
  - myeloid leukaemias
  - monoclonal gammopathy (IgA)
- granulomatosis with polyangiitis
- primary biliary cirrhosis

Features
- location
  - typically on the lower limb
  - soften at the site of a minor injury as in this patient's case and this is known as pathergy
- initially features:
  - usually starts quite suddenly
  - small pustule, red bump or blood-blister
- later features:
  - the skin then breaks down resulting in an ulcer which is often painful
  - the edge of the ulcer is often described as purple, violaceous and undermined.
  - the ulcer itself may be deep and necrotic
- may be accompanied by systemic symptoms
  - fever
  - myalgia

Diagnosis
- often made by the characteristic appearance, associations with other diseases, the presence of pathergy, histology results and when other diseases have been ruled out
- histology is not specific and can vary depending on the time and site of the specimen but may be helpful in ruling out other causes of an ulcer.

Management
- the potential for rapid progression is high in most patients and most doctors advocate oral steroids as first-line treatment

- other immunosuppressive therapy, for example, ciclosporin and infliximab, have a role in difficult cases
- any surgery should be postponed until the disease process is controlled on immunosuppression to risk worsening of the disease (pathergy)

+ Q 123

Next question >

## Textbooks

High-yield textbook

Extended textbook

## Links

DermNet NZ 10 9

Stoma skin problems

DermNet NZ 19 6

Pyoderma gangrenosum

Suggest link Report broken link

Score: **28%**

1 ×

| | |
|---|---|
| 2 | ✓ |
| 3 | ✓ |
| 4 | ✗ |
| 5 | ✗ |
| 6 | ✗ |
| 7 | ✗ |
| 8 | ✗ |
| 9 | ✗ |
| 10 | ✗ |
| 11 | ✗ |
| 12 | ✗ |
| 13 | ✓ |
| 14 | ✓ |
| 15 | ✓ |
| 16 | ✗ |
| 17 | ✓ |
| 18 | ✓ |
| 19 | ✗ |
| 20 | ✗ |
| 21 | ✗ |
| 22 | ✗ |
| 23 | ✗ |
| 24 | ✓ |
| 25 | ✗ |
| 26 | ✓ |
| 27 | ✗ |
| 28 | ✗ |
| 29 | ✗ |
| 30 | ✓ |
| 31 | ✗ |
| 32 | ✗ |
| 33 | ✗ |
| 34 | ✗ |
| 35 | ✓ |
| 36 | ✗ |
| 37 | ✗ |

| | |
|---|---|
| **38** | ✗ |
| 39 | ✗ |
| 40 | ✗ |
| 41 | ✗ |
| 42 | ✓ |
| 43 | ✗ |
| 44 | ✗ |
| 45 | ✓ |
| 46 | ✓ |
| 47 | ✗ |
| 48 | ✗ |
| 49 | ✗ |
| 50 | ✗ |

All contents of this site are © 2024 Passmedicine Limited

A 20-year-old man is reviewed in dermatology clinic. He has been suffering from severe worsening of his eczema symptoms. He normally manages with emollients and topical steroids of moderate to severe strength. Recently he has had a severe flare, which has not even responded to a trial of oral prednisolone over one week. He is suffering from severe pruritus and irritation of his skin. On examination, his flexural surfaces on his arms and legs are inflamed and show evidence of scratch marks. What non-steroidal option may help control his flare?

- Alitretinoin
- Topical tacrolimus
- Oral tacrolimus
- IV tacrolimus
- Topical salicylic acid

Submit answer

Reference ranges

| | |
|---|---|
| 10 | - |
| 11 | - |
| 12 | - |
| 13 | - |
| 14 | - |
| 15 | - |
| 16 | - |
| 17 | - |
| 18 | - |
| 19 | - |
| 20 | - |
| 21 | - |
| 22 | - |
| 23 | - |
| 24 | - |
| 25 | - |
| 26 | - |
| 27 | - |
| 28 | - |
| 29 | - |
| 30 | - |
| 31 | - |
| 32 | - |
| 33 | - |
| 34 | - |
| 35 | - |
| 36 | - |
| 37 | - |
| 38 | - |
| **39** | - |

All contents of this site are © 2024 Passmedicine Limited
Back to top

A 20-year-old man is reviewed in dermatology clinic. He has been suffering from severe worsening of his eczema symptoms. He normally manages with emollients and topical steroids of moderate to severe strength. Recently he has had a severe flare, which has not even responded to a trial of oral prednisolone over one week. He is suffering from severe pruritus and irritation of his skin. On examination, his flexural surfaces on his arms and legs are inflamed and show evidence of scratch marks. What non-steroidal option may help control his flare?

| | |
|---|---|
| Alitretinoin | 7% |
| Topical tacrolimus | 65% |
| Oral tacrolimus | 21% |
| IV tacrolimus | 1% |
| Topical salicylic acid | 6% |

Calcineurin inhibitors are an alternative to topical steroids in eczema

Important for me Less important

This patient has a severe flare of eczema not responding to emollients and strong steroid therapy as evidence by failure of response to prednisolone. Calcineurin inhibitors, such as tacrolimus, can be used by dermatologists for this. Topical tacrolimus is preferred, as oral and IV tacrolimus are used to prevent and treat organ rejection rather than to treat eczema. Salicylic acid is used for scales in psoriasis, whilst alitretinoin would only be used for severe refractory hand eczema.

Discuss (5) Improve

Next question

## Eczema: management

### Management

Avoidance of triggers and skin care education

- Key components include avoiding known irritants, allergens, and providing guidance on gentle skin care routines.

Emollients

- Integral to all treatment plans, regardless of eczema severity.
- Advise on liberal and regular use, even when the skin is clear, to maintain skin hydration and barrier function.
- Selection of emollient should be based on patient preference to improve adherence
  - Creams are generally preferred by most people - adherence is key so
  - Ointments provide the strongest emollient effect and may be more effective. However, they are greasy and so may be more suitable for use at night.

Topical therapies

- Topical corticosteroids
  - Vital for managing flare-ups, with potency tailored to the severity and lesion location
  - Example treatments recommended by NICE:
  - Mild eczema: hydrocortisone 1%
  - Moderate eczema: betamethasone valerate 0.025% or clobetasone butyrate 0.05%
  - Severe eczema: betamethasone valerate 0.1%
- Topical calcineurin inhibitors
  - Suitable for sensitive skin regions; include agents like tacrolimus and pimecrolimus.
- Topical antimicrobials
  - Used when there is clinical evidence of secondary infection.

Systemic therapies

- Indicated for severe or unresponsive cases.
- Oral corticosteroids:
  - Employed cautiously for acute severe exacerbations.
- Immunosuppressants:
  - Ciclosporin, methotrexate, or azathioprine are reserved for chronic, severe eczema.
- Biologic therapies:
  - Dupilumab is an advanced option for cases unresponsive to conventional therapy.

Phototherapy

- Considered for extensive eczema

## Prognosis

Prognostic markers associated with severe disease include:

- onset at age 3-6 months
- severe disease in childhood
- associated asthma or hay fever
- small family size
- high IgE serum levels

+ Q 123

Next question

## Textbooks

High-yield textbook

Extended textbook

## Links

British Association of Dermatologists 1 1

Atopic eczema guidelines

Clinical Knowledge Summaries 0 0

Atopic eczema

Suggest link Report broken link

## Media

Eczema

Osmosis - YouTube 2 0

Report broken media

Score: **28%**

| | |
|---|---|
| 1 | ✗ |
| 2 | ✓ |
| 3 | ✓ |
| 4 | ✗ |
| 5 | ✗ |
| 6 | ✗ |
| 7 | ✗ |
| 8 | ✗ |
| 9 | ✗ |
| 10 | ✗ |
| 11 | ✗ |
| 12 | ✗ |
| 13 | ✓ |
| 14 | ✓ |
| 15 | ✓ |
| 16 | ✗ |
| 17 | ✓ |
| 18 | ✓ |
| 19 | ✗ |
| 20 | ✗ |
| 21 | ✗ |
| 22 | ✗ |
| 23 | ✗ |

| | |
|---|---|
| 24 | ✓ |
| 25 | ✗ |
| 26 | ✓ |
| 27 | ✗ |
| 28 | ✗ |
| 29 | ✗ |
| 30 | ✓ |
| 31 | ✗ |
| 32 | ✗ |
| 33 | ✗ |
| 34 | ✗ |
| 35 | ✓ |
| 36 | ✗ |
| 37 | ✗ |
| 38 | ✗ |
| **39** | ✗ |
| 40 | ✗ |
| 41 | ✗ |
| 42 | ✓ |
| 43 | ✗ |
| 44 | ✗ |
| 45 | ✓ |
| 46 | ✓ |
| 47 | ✗ |
| 48 | ✗ |
| 49 | ✗ |
| 50 | ✗ |

All contents of this site are © 2024 Passmedicine Limited

Back to top

The lesion below started as a small red papule which grew in size before starting to ulcerate:

© Image used on license from DermNet NZ

Which one of the following conditions is most associated with this skin condition?

- Rheumatoid arthritis
- Sarcoidosis
- Primary herpes simplex virus infection
- Tuberculosis
- Thyrotoxicosis

Submit answer

Reference ranges

Score: **0%**

| | |
|---|---|
| 1 | - |
| 2 | - |
| 3 | - |
| 4 | - |
| 5 | - |
| 6 | - |
| 7 | - |
| 8 | - |
| 9 | - |
| 10 | - |
| 11 | - |
| 12 | - |
| 13 | - |
| 14 | - |
| 15 | - |
| 16 | - |
| 17 | - |
| 18 | - |
| 19 | - |
| 20 | - |
| 21 | - |
| 22 | - |
| 23 | - |
| 24 | - |
| 25 | - |
| 26 | - |
| 27 | - |
| 28 | - |
| 29 | - |
| 30 | - |
| 31 | - |
| 32 | - |
| 33 | - |
| 34 | - |
| 35 | - |
| 36 | - |
| 37 | - |
| 38 | - |

| | |
|---|---|
| 39 | - |
| **40** | - |

All contents of this site are © 2024 Passmedicine Limited

The lesion below started as a small red papule which grew in size before starting to ulcerate:

© Image used on license from DermNet NZ

Which one of the following conditions is most associated with this skin condition?

| | |
|---|---|
| Rheumatoid arthritis | 49% |
| Sarcoidosis | 27% |
| Primary herpes simplex virus infection | 7% |
| Tuberculosis | 11% |
| Thyrotoxicosis | 6% |

Discuss (1) Improve

Next question

## Pyoderma gangrenosum

Pyoderma gangrenosum is a rare, non-infectious, inflammatory disorder. It is an uncommon cause of very painful skin ulceration. It may affect any part of the skin, but the lower legs are the most common site.

Pathophysiology
- pyoderma gangrenosum is classified as a neutrophilic dermatosis
- neutrophilic dermatoses are skin conditions characterised by dense infiltration of neutrophils in the affected tissue and this is often seen on biopsy

Causes
- idiopathic in 50%
- inflammatory bowel disease in 10-15%
  - ulcerative colitis
  - Crohn's
- rheumatological
  - rheumatoid arthritis
  - SLE
- haematological
  - myeloproliferative disorders
  - lymphoma
  - myeloid leukaemias
  - monoclonal gammopathy (IgA)
- granulomatosis with polyangiitis
- primary biliary cirrhosis

Features
- location
  - typically on the lower limb
  - soften at the site of a minor injury as in this patient's case and this is known as pathergy
- initially features:
  - usually starts quite suddenly
  - small pustule, red bump or blood-blister
- later features:
  - the skin then breaks down resulting in an ulcer which is often painful
  - the edge of the ulcer is often described as purple, violaceous and undermined.
  - the ulcer itself may be deep and necrotic
- may be accompanied by systemic symptoms
  - fever
  - myalgia

Diagnosis

- often made by the characteristic appearance, associations with other diseases, the presence of pathergy, histology results and when other diseases have been ruled out
- histology is not specific and can vary depending on the time and site of the specimen but may be helpful in ruling out other causes of an ulcer.

Management

- the potential for rapid progression is high in most patients and most doctors advocate oral steroids as first-line treatment
- other immunosuppressive therapy, for example, ciclosporin and infliximab, have a role in difficult cases
- any surgery should be postponed until the disease process is controlled on immunosuppression to risk worsening of the disease (pathergy)

AI + Q 123

Next question >

## Textbooks

High-yield textbook

Extended textbook

## Links

DermNet NZ 10 9

Stoma skin problems

DermNet NZ 👍 19 👎 6

Pyoderma gangrenosum

Suggest link Report broken link

Score: **28%**

| | |
|---|---|
| 1 | ✗ |
| 2 | ✓ |
| 3 | ✓ |
| 4 | ✗ |
| 5 | ✗ |
| 6 | ✗ |
| 7 | ✗ |
| 8 | ✗ |
| 9 | ✗ |
| 10 | ✗ |
| 11 | ✗ |
| 12 | ✗ |
| 13 | ✓ |
| 14 | ✓ |
| 15 | ✓ |
| 16 | ✗ |
| 17 | ✓ |
| 18 | ✓ |
| 19 | ✗ |
| 20 | ✗ |
| 21 | ✗ |
| 22 | ✗ |
| 23 | ✗ |
| 24 | ✓ |
| 25 | ✗ |

| | |
|---|---|
| 26 | ✓ |
| 27 | ✗ |
| 28 | ✗ |
| 29 | ✗ |
| 30 | ✓ |
| 31 | ✗ |
| 32 | ✗ |
| 33 | ✗ |
| 34 | ✗ |
| 35 | ✓ |
| 36 | ✗ |
| 37 | ✗ |
| 38 | ✗ |
| 39 | ✗ |
| **40** | ✗ |
| 41 | ✗ |
| 42 | ✓ |
| 43 | ✗ |
| 44 | ✗ |
| 45 | ✓ |
| 46 | ✓ |
| 47 | ✗ |
| 48 | ✗ |
| 49 | ✗ |
| 50 | ✗ |

All contents of this site are © 2024 Passmedicine Limited

Back to top

A 50-year-old male patient with a history of severe psoriasis has previously tried treatment with topical corticosteroids, vitamin D analogue therapy and phototherapy with little effect.

On examination he has multiple well circumscribed indurated erythematous plaques with overlying white scale over the majority of the trunk and forearms.

Blood tests reveal:

| | |
|---|---|
| Hb | 135 g/l |
| Platelets | 405 * $10^9$/l |
| WBC | 8.2 * $10^9$/l |
| Bilirubin | 12 µmol/l |
| ALP | 70 u/l |
| ALT | 27 u/l |
| Albumin | 35 g/l |
| $Na^+$ | 140 mmol/l |
| $K^+$ | 5.1 mmol/l |
| Urea | 8.2 mmol/l |
| Creatinine | 112 µmol/l |

What is the most appropriate therapy?

- Infliximab
- Adalimumab
- Ciclosporin
- Methotrexate
- Etanercept

Submit answer

Reference ranges

Score: **0%**

| | |
|---|---|
| 1 | - |
| 2 | - |
| 3 | - |
| 4 | - |
| 5 | - |
| 6 | - |
| 7 | - |
| 8 | - |
| 9 | - |
| 10 | - |
| 11 | - |
| 12 | - |
| 13 | - |
| 14 | - |
| 15 | - |
| 16 | - |
| 17 | - |
| 18 | - |
| 19 | - |
| 20 | - |
| 21 | - |
| 22 | - |
| 23 | - |
| 24 | - |
| 25 | - |
| 26 | - |
| 27 | - |
| 28 | - |
| 29 | - |
| 30 | - |
| 31 | - |
| 32 | - |
| 33 | - |
| 34 | - |

| | |
|---|---|
| 35 | - |
| 36 | - |
| 37 | - |
| 38 | - |
| 39 | - |
| 40 | - |
| **41** | - |

All contents of this site are © 2024 Passmedicine Limited

Back to top

A 50-year-old male patient with a history of severe psoriasis has previously tried treatment with topical corticosteroids, vitamin D analogue therapy and phototherapy with little effect.

On examination he has multiple well circumscribed indurated erythematous plaques with overlying white scale over the majority of the trunk and forearms.

Blood tests reveal:

| | |
|---|---|
| Hb | 135 g/l |
| Platelets | 405 * $10^9$/l |
| WBC | 8.2 * $10^9$/l |
| Bilirubin | 12 µmol/l |
| ALP | 70 u/l |
| ALT | 27 u/l |
| Albumin | 35 g/l |
| $Na^+$ | 140 mmol/l |
| $K^+$ | 5.1 mmol/l |
| Urea | 8.2 mmol/l |
| Creatinine | 112 µmol/l |

What is the most appropriate therapy?

- Infliximab 10%
- Adalimumab 6%
- Ciclosporin 19%
- Methotrexate 58%
- Etanercept 6%

NICE CG154 addresses the approach to systemic therapy for psoriasis and is outlined below:

Offer systemic non-biological therapy to people with any type of psoriasis if:

- It cannot be controlled with topical therapy and
- It has a significant impact on physical, psychological or social wellbeing and one or more of the following apply:

psoriasis is extensive (for example, more than 10% of body surface area affected or a PASI score of more than 10) or
psoriasis is localised and associated with significant functional impairment and/or high levels of distress (for example severe nail disease or involvement at high-impact sites) or
phototherapy has been ineffective, cannot be used or has resulted in rapid relapse (rapid relapse is defined as greater than 50% of baseline disease severity within 3 months).

Choice of drugs:

- Offer methotrexate as the first choice of systemic agent for people with psoriasis who fulfil the criteria for systemic therapy (above)
- Offer ciclosporin as the first choice of systemic agent for people who fulfil the criteria for systemic therapy (above) and who:

need rapid or short-term disease control (for example a psoriasis flare) or
have palmoplantar pustulosis or
are considering conception (both men and women) and systemic therapy cannot be avoided.

- Consider changing from methotrexate to ciclosporin (or vice-versa) when response to the first-choice systemic treatment is inadequate.
- Consider acitretin for adults, and in exceptional cases only for children and young people, in the following circumstances:

if methotrexate and ciclosporin are not appropriate or have failed or
for people with pustular forms of psoriasis.

Discuss (5) | Improve

Next question

## Psoriasis: management

NICE released guidelines in 2012 on the management of psoriasis and psoriatic arthropathy. Please see the link for more details.

### Chronic plaque psoriasis management

NICE recommend a step-wise approach for chronic plaque psoriasis

- regular emollients may help to reduce scale loss and reduce pruritus
- first-line: NICE recommend:
  - a potent corticosteroid applied once daily plus vitamin D analogue applied once daily
  - should be applied separately, one in the morning and the other in the evening)
  - for up to 4 weeks as initial treatment
- second-line: if no improvement after 8 weeks then offer:
  - a vitamin D analogue twice daily
- third-line: if no improvement after 8-12 weeks then offer either:
  - a potent corticosteroid applied twice daily for up to 4 weeks, or
  - a coal tar preparation applied once or twice daily
- short-acting dithranol can also be used

**Secondary care management**

Phototherapy

- narrowband ultraviolet B light is now the treatment of choice. If possible this should be given 3 times a week
- photochemotherapy is also used - psoralen + ultraviolet A light (PUVA)
- adverse effects: skin ageing, squamous cell cancer (not melanoma)

Systemic therapy

- oral methotrexate is used first-line. It is particularly useful if there is associated joint disease
- ciclosporin
- systemic retinoids
- biological agents: infliximab, etanercept and adalimumab
- ustekinumab (IL-12 and IL-23 blocker) is showing promise in early trials

## Scalp psoriasis management

Outline

- NICE recommend the use of potent topical corticosteroids used once daily for 4 weeks
- if no improvement after 4 weeks then either use a different formulation of the potent corticosteroid (for example, a shampoo or mousse) and/or a topical agents to remove

adherent scale (for example, agents containing salicylic acid, emollients and oils) before application of the potent corticosteroid

## Face, flexural and genital psoriasis management

Outline

- NICE recommend offering a mild or moderate potency corticosteroid applied once or twice daily for a maximum of 2 weeks

## Notes on medication

Using topical steroids in psoriasis

- as we know topical corticosteroid therapy may lead to skin atrophy, striae and rebound symptoms
  - the scalp, face and flexures are particularly prone to steroid atrophy so topical steroids should not be used for more than 1-2 weeks/month
- systemic side-effects may be seen when potent corticosteroids are used on large areas e.g. > 10% of the body surface area
- NICE recommend that we aim for a 4-week break before starting another course of topical corticosteroids
- they also recommend using potent corticosteroids for no longer than 8 weeks at a time and very potent corticosteroids for no longer than 4 weeks at a time

Vitamin D analogues

- examples of vitamin D analogues include calcipotriol (Dovonex), calcitriol and tacalcitol
- they work by ↓ cell division and differentiation → ↓ epidermal proliferation
- adverse effects are uncommon
- unlike corticosteroids they may be used long-term
- unlike coal tar and dithranol they do not smell or stain
- they tend to reduce the scale and thickness of plaques but not the erythema
- they should be avoided in pregnancy
- the maximum weekly amount for adults is 100g

© Image used on license from DermNet NZ

A 'before and after' image showing the effect of 6 weeks of calcipotriol therapy on a large plaque. Note how the scale has improved but the erythema remains

Dithranol

- inhibits DNA synthesis
- wash off after 30 mins
- adverse effects include burning, staining

Coal tar

- mechanism of action not fully understood - probably inhibit DNA synthesis

AI + Q 123

Next question >

## Textbooks

High-yield textbook

Extended textbook

## Links

SIGN 14 13

2010 Psoriasis guidelines

British Association of Dermatologists 14 11

2017 Guidelines for biologic therapy for psoriasis

NICE 21 16

2012 Psoriasis guidelines

Suggest link

Report broken link

## Media

Psoriasis

Osmosis - YouTube 1 1

Report broken media

Score: **28%**

1 ✗

2 ✓

| | |
|---|---|
| 3 | ✓ |
| 4 | ✗ |
| 5 | ✗ |
| 6 | ✗ |
| 7 | ✗ |
| 8 | ✗ |
| 9 | ✗ |
| 10 | ✗ |
| 11 | ✗ |
| 12 | ✗ |
| 13 | ✓ |
| 14 | ✓ |
| 15 | ✓ |
| 16 | ✗ |
| 17 | ✓ |
| 18 | ✓ |
| 19 | ✗ |
| 20 | ✗ |
| 21 | ✗ |
| 22 | ✗ |
| 23 | ✗ |
| 24 | ✓ |
| 25 | ✗ |
| 26 | ✓ |
| 27 | ✗ |
| 28 | ✗ |
| 29 | ✗ |
| 30 | ✓ |
| 31 | ✗ |
| 32 | ✗ |
| 33 | ✗ |
| 34 | ✗ |
| 35 | ✓ |
| 36 | ✗ |
| 37 | ✗ |
| 38 | ✗ |

| | |
|---|---|
| 39 | ✗ |
| 40 | ✗ |
| **41** | ✗ |
| 42 | ✓ |
| 43 | ✗ |
| 44 | ✗ |
| 45 | ✓ |
| 46 | ✓ |
| 47 | ✗ |
| 48 | ✗ |
| 49 | ✗ |
| 50 | ✗ |

All contents of this site are © 2024 Passmedicine Limited

Back to top

You are reviewing a 33-year-old woman with a lesion on her finger. The lesion has been present for 6 weeks, initially starting small before quickly growing in size. There is no history of trauma.

There is no past medical history and her only regular medication is folic acid. She is 28 weeks pregnant with her second child and has had no complications during her pregnancy.

An image of the lesion is shown below.

© Image used on license from DermNet NZ

What is the most appropriate management for the lesion?

- Cauterisation
- Cryotherapy
- Curettage
- Excision
- Watch and wait

Submit answer

Reference ranges

Score: **0%**

1 -
2 -
3 -
4 -
5 -
6 -
7 -
8 -
9 -
10 -
11 -
12 -
13 -
14 -
15 -
16 -
17 -
18 -
19 -
20 -
21 -
22 -
23 -
24 -
25 -
26 -
27 -
28 -
29 -
30 -
31 -
32 -
33 -
34 -

| | |
|---|---|
| 35 | - |
| 36 | - |
| 37 | - |
| 38 | - |
| 39 | - |
| 40 | - |
| 41 | - |
| **42** | - |

All contents of this site are © 2024 Passmedicine Limited

You are reviewing a 33-year-old woman with a lesion on her finger. The lesion has been present for 6 weeks, initially starting small before quickly growing in size. There is no history of trauma.

There is no past medical history and her only regular medication is folic acid. She is 28 weeks pregnant with her second child and has had no complications during her pregnancy.

An image of the lesion is shown below.

© Image used on license from DermNet NZ

What is the most appropriate management for the lesion?

| | |
|---|---|
| Cauterisation | 7% |
| Cryotherapy | 10% |
| Curettage | 7% |
| Excision | 18% |
| Watch and wait | 57% |

The image shows a well-defined, ulcerated papule alongside a history of rapid growth, in keeping with a pyogenic granuloma. These are found to be more common after trauma, in pregnancy, and in young adults. Given that the above scenario does not allude to any trauma, the likely cause for this lesion is pregnancy.

Traumatic pyogenic granulomas can be treated with cauterisation, cryotherapy, curettage, or excision.

The above scenario is a non-traumatic pyogenic granuloma likely secondary to pregnancy and so the most appropriate initial step in management is 'watch and wait' as lesions often self-resolve in pregnancy.

Discuss Improve

Next question

## Pyogenic granuloma

Pyogenic granuloma is a relatively common benign skin lesion. The name is confusing as they are neither true granulomas nor pyogenic in nature. There are multiple alternative names but perhaps 'eruptive haemangioma' is the most useful.

The cause of pyogenic granuloma is not known but a number of factors are linked:

- trauma
- pregnancy
- more common in women and young adults

Features

- most common sites are head/neck, upper trunk and hands. Lesions in the oral mucosa are common in pregnancy
- initially small red/brown spot
- rapidly progress within days to weeks forming raised, red/brown lesions which are often spherical in shape
- the lesions may bleed profusely or ulcerate

Management

- lesions associated with pregnancy often resolve spontaneously post-partum
- other lesions usually persist. Removal methods include curettage and cauterisation, cryotherapy, excision

123

Next question

## Textbooks

High-yield textbook

Extended textbook

## Links

DermNet NZ 8 3

Pyogenic granuloma

Suggest link

Report broken link

Score: **28%**

| | |
|---|---|
| 1 | ✗ |
| 2 | ✓ |
| 3 | ✓ |
| 4 | ✗ |
| 5 | ✗ |
| 6 | ✗ |

| | |
|---|---|
| 7 | ✗ |
| 8 | ✗ |
| 9 | ✗ |
| 10 | ✗ |
| 11 | ✗ |
| 12 | ✗ |
| 13 | ✓ |
| 14 | ✓ |
| 15 | ✓ |
| 16 | ✗ |
| 17 | ✓ |
| 18 | ✓ |
| 19 | ✗ |
| 20 | ✗ |
| 21 | ✗ |
| 22 | ✗ |
| 23 | ✗ |
| 24 | ✓ |
| 25 | ✗ |
| 26 | ✓ |
| 27 | ✗ |
| 28 | ✗ |
| 29 | ✗ |
| 30 | ✓ |
| 31 | ✗ |
| 32 | ✗ |
| 33 | ✗ |
| 34 | ✗ |
| 35 | ✓ |
| 36 | ✗ |
| 37 | ✗ |
| 38 | ✗ |
| 39 | ✗ |
| 40 | ✗ |
| 41 | ✗ |
| **42** | ✓ |

| | |
|---|---|
| 43 | ✗ |
| 44 | ✗ |
| 45 | ✓ |
| 46 | ✓ |
| 47 | ✗ |
| 48 | ✗ |
| 49 | ✗ |
| 50 | ✗ |

All contents of this site are © 2024 Passmedicine Limited

Back to top

A 32-year-old man presents to the dermatology clinic with a rash on his lower legs. He reports that an initial lesion appeared 2 weeks ago, followed by further smaller lesions over his body. There is no history of itch or pain and he denies having a fever. His past medical history includes anxiety for which he takes propranolol and he has no known allergies.

His rash is examined, as shown below:

What is the recommended management for this patient?

- Reassurance and discharge
- Topical 1% hydrocortisone
- Topical fusidic acid
- Topical ketoconazole
- UVB phototherapy

Submit answer

Reference ranges

Score: **0%**

| | |
|---|---|
| 1 | - |
| 2 | - |
| 3 | - |
| 4 | - |
| 5 | - |
| 6 | - |
| 7 | - |
| 8 | - |
| 9 | - |
| 10 | - |
| 11 | - |
| 12 | - |
| 13 | - |
| 14 | - |
| 15 | - |
| 16 | - |
| 17 | - |
| 18 | - |
| 19 | - |
| 20 | - |
| 21 | - |
| 22 | - |
| 23 | - |
| 24 | - |
| 25 | - |
| 26 | - |
| 27 | - |
| 28 | - |
| 29 | - |

30 -
31 -
32 -
33 -
34 -
35 -
36 -
37 -
38 -
39 -
40 -
41 -
42 -
**43** -

All contents of this site are © 2024 Passmedicine Limited
Back to top

PassMedicine



A 32-year-old man presents to the dermatology clinic with a rash on his lower legs. He reports that an initial lesion appeared 2 weeks ago, followed by further smaller lesions over his body. There is no history of itch or pain and he denies having a fever. His past medical history includes anxiety for which he takes propranolol and he has no known allergies.

His rash is examined, as shown below:

What is the recommended management for this patient?

| | |
|---|---|
| Reassurance and discharge | 42% |
| Topical 1% hydrocortisone | 25% |
| Topical fusidic acid | 4% |
| Topical ketoconazole | 25% |
| UVB phototherapy | 4% |

This patient has multiple small, oval-shaped, red plaques that are located on the lower limbs.

Looking closely at these lesions, some appear to have a fine peripheral scale. This patient has a diagnosis of pityriasis rosea, a self-limiting rash that is characterised by a large round 'herald patch', usually found on the chest, abdomen, or back. It mostly affects children and young adults and is thought to be precipitated by bacterial and viral infections (e.g. human herpes virus 6 and 7) although this has not definitely been proved yet.

**Reassurance and discharge** is correct. Pityriasis rosea is a self-limiting rash and treatment is not usually required.

**Topical 1% hydrocortisone** is incorrect. Topical corticosteroids are usually used in the treatment of eczematous diseases that typically present as a dry, itchy and scaly rash which is not seen here. They can also be used in the management of localised chronic plaque psoriasis. However, it plays no role in the management of pityriasis rosea.

**Topical fusidic acid** is incorrect. This is used in treating superficial bacterial infections including insect bites, stings and impetigo. However, there is no surrounding erythema or pustular discharge to suggest that this rash is bacterial in nature.

**Topical ketoconazole** is incorrect. Topical ketoconazole is used in the treatment of fungal infections such as pityriasis versicolor. The rash is mostly seen on the trunk, neck and upper limbs. The patches can vary in colour from pink, brown to pale (typically paler than the surrounding skin). They are usually asymptomatic but can occasionally be itchy. Heat and moisture are risk factors for developing the rash.

**UVB phototherapy** is incorrect. This is used in the management of chronic plaque psoriasis and guttate psoriasis that cannot be controlled with initial topical management. Importantly, this patient is taking propranolol which is known to exacerbate psoriasis. Psoriasis has a similar appearance to pityriasis rosea. However, psoriasis has a coarser silvery scale with surrounding lichenification. However, the history of an isolated herald patch before the onset of the remaining rash is suggestive for pityriasis rosea for which UVB phototherapy is not a treatment.

Discuss (2) | Improve

Next question

## Pityriasis rosea

Pityriasis rosea describes an acute, self-limiting rash which tends to affect young adults. The aetiology is not fully understood but is thought that herpes hominis virus 7 (HHV-7) may play a role.

Features

- in the majority of patients there is no prodrome, but a minority may give a history of a recent viral infection
- herald patch (usually on trunk)
- followed by erythematous, oval, scaly patches which follow a characteristic distribution with the longitudinal diameters of the oval lesions running parallel to the line of Langer. This may produce a 'fir-tree' appearance

Management

- self-limiting - usually disappears after 6-12 weeks

## Differentiating guttate psoriasis and pityriasis rosea

| | Guttate psoriasis | Pityriasis rosea |
|---|---|---|
| **Prodrome** | Classically preceded by a streptococcal sore throat 2-4 weeks | Many patients report recent respiratory tract infections but this is not common in questions |

| | Guttate psoriasis | Pityriasis rosea |
|---|---|---|
| **Appearance** | 'Tear drop', scaly papules on the trunk and limbs | Herald patch followed 1-2 weeks later by multiple erythematous, slightly raised oval lesions with a fine scale confined to the outer aspects of the lesions.<br><br>May follow a characteristic distribution with the longitudinal diameters of the oval lesions running parallel to the line of Langer. This may produce a 'fir-tree' appearance |
| **Treatment / natural history** | Most cases resolve spontaneously within 2-3 months<br>Topical agents as per psoriasis<br>UVB phototherapy | Self-limiting, resolves after around 6 weeks |

123

Next question

### Textbooks

High-yield textbook

Extended textbook

### Links

Clinical Knowledge Summaries 9 6

Pityriasis rosea

DermNet NZ

👍 11 👎 4

Pityriasis rosea

Suggest link | Report broken link

Score: **28%**

| | |
|---|---|
| 1 | ✗ |
| 2 | ✓ |
| 3 | ✓ |
| 4 | ✗ |
| 5 | ✗ |
| 6 | ✗ |
| 7 | ✗ |
| 8 | ✗ |
| 9 | ✗ |
| 10 | ✗ |
| 11 | ✗ |
| 12 | ✗ |
| 13 | ✓ |
| 14 | ✓ |
| 15 | ✓ |
| 16 | ✗ |
| 17 | ✓ |
| 18 | ✓ |
| 19 | ✗ |
| 20 | ✗ |
| 21 | ✗ |
| 22 | ✗ |
| 23 | ✗ |
| 24 | ✓ |
| 25 | ✗ |

| | |
|---|---|
| 26 | ✓ |
| 27 | ✗ |
| 28 | ✗ |
| 29 | ✗ |
| 30 | ✓ |
| 31 | ✗ |
| 32 | ✗ |
| 33 | ✗ |
| 34 | ✗ |
| 35 | ✓ |
| 36 | ✗ |
| 37 | ✗ |
| 38 | ✗ |
| 39 | ✗ |
| 40 | ✗ |
| 41 | ✗ |
| 42 | ✓ |
| **43** | ✗ |
| 44 | ✗ |
| 45 | ✓ |
| 46 | ✓ |
| 47 | ✗ |
| 48 | ✗ |
| 49 | ✗ |
| 50 | ✗ |

All contents of this site are © 2024 Passmedicine Limited

PassMedicine



A 59-year-old man presents with a new skin lesion which has developed over the past few months:

© Image used on license from DermNet NZ

You plan to refer the patient to dermatology. What is the most likely diagnosis?

- Malignant melanoma
- Actinic keratosis
- Bowen's disease
- Basal cell carcinoma
- Seborrhoeic keratosis

Submit answer

Reference ranges

Score: **0%**

1 -
2 -
3 -
4 -
5 -
6 -
7 -
8 -
9 -
10 -
11 -
12 -
13 -
14 -
15 -
16 -
17 -
18 -
19 -
20 -
21 -
22 -
23 -
24 -
25 -
26 -
27 -
28 -
29 -
30 -
31 -
32 -
33 -
34 -
35 -
36 -
37 -
38 -

| | |
|---|---|
| 39 | - |
| 40 | - |
| 41 | - |
| 42 | - |
| 43 | - |
| **44** | - |

All contents of this site are © 2024 Passmedicine Limited

A 59-year-old man presents with a new skin lesion which has developed over the past few months:

© Image used on license from DermNet NZ

You plan to refer the patient to dermatology. What is the most likely diagnosis?

| | |
|---|---|
| Malignant melanoma | 22% |
| Actinic keratosis | 10% |
| Bowen's disease | 51% |
| Basal cell carcinoma | 14% |
| Seborrhoeic keratosis | 3% |

Discuss (1) Improve

Next question

# Bowen's disease

Bowen's disease is a type of precancerous dermatosis that is a precursor to squamous cell carcinoma. It is more common in elderly patients. There is around a 5-10% chance of developing invasive skin cancer if left untreated.

Features

- red, scaly patches
  - often 10-15 mm in size
  - slow-growing
  - often occur on sun-exposed areas such as the head (e.g. temples) and neck, lower limbs

Management options:

- may sometimes be diagnosed and managed in primary care if clear diagnosis or repeat episode
- topical 5-fluorouracil
  - typically used twice daily for 4 weeks
  - often results in significant inflammation/erythema. Topical steroids are often given to control this
- cryotherapy
- excision

+ Q 123

Next question >

**Textbooks**

High-yield textbook

Extended textbook

**Links**

DermNet NZ 9 9

Bowen's disease

Suggest link Report broken link

Score: **28%**

| | |
|---|---|
| 1 | ✗ |
| 2 | ✓ |
| 3 | ✓ |
| 4 | ✗ |
| 5 | ✗ |
| 6 | ✗ |
| 7 | ✗ |
| 8 | ✗ |
| 9 | ✗ |
| 10 | ✗ |
| 11 | ✗ |
| 12 | ✗ |
| 13 | ✓ |
| 14 | ✓ |
| 15 | ✓ |
| 16 | ✗ |
| 17 | ✓ |
| 18 | ✓ |
| 19 | ✗ |
| 20 | ✗ |

| | |
|---|---|
| 21 | ✗ |
| 22 | ✗ |
| 23 | ✗ |
| 24 | ✓ |
| 25 | ✗ |
| 26 | ✓ |
| 27 | ✗ |
| 28 | ✗ |
| 29 | ✗ |
| 30 | ✓ |
| 31 | ✗ |
| 32 | ✗ |
| 33 | ✗ |
| 34 | ✗ |
| 35 | ✓ |
| 36 | ✗ |
| 37 | ✗ |
| 38 | ✗ |
| 39 | ✗ |
| 40 | ✗ |
| 41 | ✗ |
| 42 | ✓ |
| 43 | ✗ |
| **44** | ✗ |
| 45 | ✓ |
| 46 | ✓ |
| 47 | ✗ |
| 48 | ✗ |
| 49 | ✗ |
| 50 | ✗ |

All contents of this site are © 2024 Passmedicine Limited

Back to top

You review a 31-year-old woman who has had Crohn's disease for the past 12 years. She is currently on infliximab therapy.

© Image used on license from DermNet NZ

What is the most likely diagnosis?

- Pyoderma gangrenosum
- Acute febrile neutrophilic dermatosis
- Squamous cell carcinoma
- Pyogenic granuloma
- Behcet's disease

Submit answer

Reference ranges

Score: **0%**

1 -
2 -
3 -
4 -
5 -
6 -
7 -
8 -
9 -
10 -
11 -
12 -
13 -
14 -
15 -
16 -
17 -
18 -
19 -
20 -
21 -
22 -
23 -
24 -
25 -
26 -
27 -
28 -
29 -
30 -
31 -
32 -
33 -
34 -
35 -
36 -
37 -

| | |
|---|---|
| 38 | - |
| 39 | - |
| 40 | - |
| 41 | - |
| 42 | - |
| 43 | - |
| 44 | - |
| **45** | - |

All contents of this site are © 2024 Passmedicine Limited

Back to top

You review a 31-year-old woman who has had Crohn's disease for the past 12 years. She is currently on infliximab therapy.

© Image used on license from DermNet NZ

What is the most likely diagnosis?

| | |
|---|---|
| Pyoderma gangrenosum | 77% |
| Acute febrile neutrophilic dermatosis | 13% |
| Squamous cell carcinoma | 1% |
| Pyogenic granuloma | 8% |
| Behcet's disease | 0% |

The correct answer is **Pyoderma gangrenosum**. Pyoderma gangrenosum is a neutrophilic dermatosis that commonly occurs in patients with inflammatory bowel disease, such as Crohn's. It presents as painful, necrotic ulcers often found on the lower extremities. The pathophysiology involves an abnormal immune response leading to neutrophil infiltration of the skin, resulting in ulceration. Management typically involves systemic corticosteroids and immunosuppressants like infliximab.

**Acute febrile neutrophilic dermatosis**, also known as Sweet's syndrome, is incorrect. Although it

is also a neutrophilic dermatosis like pyoderma gangrenosum, it usually presents with fever and elevated inflammatory markers alongside the abrupt onset of tender erythematous skin lesions. It can be associated with malignancies and infections but less commonly with Crohn's disease.

**Squamous cell carcinoma** is not the most likely diagnosis in this case. While patients with chronic inflammatory conditions may have an increased risk for squamous cell carcinoma over time, the acute presentation of painful necrotic ulcers is more indicative of pyoderma gangrenosum.

The option **Pyogenic granuloma** is incorrect as well. Pyogenic granulomas are benign vascular lesions that present as rapidly growing red papules or nodules, often after minor trauma or during pregnancy. They do not typically present with ulceration and are not associated with Crohn's disease.

Finally, **Behcet's disease** could potentially cause similar skin lesions due to its vasculitis component; however, other symptoms such as oral aphthous ulcers, genital ulcers and ocular inflammation would likely be present too. Furthermore, Behcet's disease has no established association with Crohn's disease, unlike pyoderma gangrenosum.

Discuss (2) Improve

Next question

## Pyoderma gangrenosum

Pyoderma gangrenosum is a rare, non-infectious, inflammatory disorder. It is an uncommon cause of very painful skin ulceration. It may affect any part of the skin, but the lower legs are the most common site.

Pathophysiology
- pyoderma gangrenosum is classified as a neutrophilic dermatosis
- neutrophilic dermatoses are skin conditions characterised by dense infiltration of neutrophils in the affected tissue and this is often seen on biopsy

Causes
- idiopathic in 50%
- inflammatory bowel disease in 10-15%
  - ulcerative colitis
  - Crohn's
- rheumatological

- rheumatoid arthritis
  - SLE
- haematological
  - myeloproliferative disorders
  - lymphoma
  - myeloid leukaemias
  - monoclonal gammopathy (IgA)
- granulomatosis with polyangiitis
- primary biliary cirrhosis

Features
- location
  - typically on the lower limb
  - soften at the site of a minor injury as in this patient's case and this is known as pathergy
- initially features:
  - usually starts quite suddenly
  - small pustule, red bump or blood-blister
- later features:
  - the skin then breaks down resulting in an ulcer which is often painful
  - the edge of the ulcer is often described as purple, violaceous and undermined.
  - the ulcer itself may be deep and necrotic
- may be accompanied by systemic symptoms
  - fever
  - myalgia

Diagnosis
- often made by the characteristic appearance, associations with other diseases, the presence of pathergy, histology results and when other diseases have been ruled out
- histology is not specific and can vary depending on the time and site of the specimen but may be helpful in ruling out other causes of an ulcer.

Management
- the potential for rapid progression is high in most patients and most doctors advocate oral steroids as first-line treatment

- other immunosuppressive therapy, for example, ciclosporin and infliximab, have a role in difficult cases
- any surgery should be postponed until the disease process is controlled on immunosuppression to risk worsening of the disease (pathergy)

+ Q 123

Next question ›

## Textbooks

High-yield textbook

Extended textbook

## Links

DermNet NZ 10 9

Stoma skin problems

DermNet NZ 19 6

Pyoderma gangrenosum

Suggest link Report broken link

Score: **28%**

1 ✕

| | |
|---|---|
| 2 | ✓ |
| 3 | ✓ |
| 4 | ✗ |
| 5 | ✗ |
| 6 | ✗ |
| 7 | ✗ |
| 8 | ✗ |
| 9 | ✗ |
| 10 | ✗ |
| 11 | ✗ |
| 12 | ✗ |
| 13 | ✓ |
| 14 | ✓ |
| 15 | ✓ |
| 16 | ✗ |
| 17 | ✓ |
| 18 | ✓ |
| 19 | ✗ |
| 20 | ✗ |
| 21 | ✗ |
| 22 | ✗ |
| 23 | ✗ |
| 24 | ✓ |
| 25 | ✗ |
| 26 | ✓ |
| 27 | ✗ |
| 28 | ✗ |
| 29 | ✗ |
| 30 | ✓ |
| 31 | ✗ |
| 32 | ✗ |
| 33 | ✗ |
| 34 | ✗ |
| 35 | ✓ |
| 36 | ✗ |
| 37 | ✗ |

| | |
|---|---|
| 38 | ✗ |
| 39 | ✗ |
| 40 | ✗ |
| 41 | ✗ |
| 42 | ✓ |
| 43 | ✗ |
| 44 | ✗ |
| **45** | ✓ |
| 46 | ✓ |
| 47 | ✗ |
| 48 | ✗ |
| 49 | ✗ |
| 50 | ✗ |

All contents of this site are © 2024 Passmedicine Limited

Back to top

A 21-year-old woman presents to the emergency department with an itchy rash. It developed over the course of the day which she spent at the beach with friends.

She complains of an itching and burning sensation on her upper arms, trunk and thighs.

On examination there are crops of 3mm pink papules over the symptomatic areas, sparing her face and her hands.

What is the most likely diagnosis?

- Scabies
- Systemic lupus erythematosus
- Xeroderma pigmentosum
- Photoallergic contact dermatitis
- Polymorphic light eruption

Submit answer

Reference ranges

```
-
-
-
-
-
-
-
-
-
-
-
-
-
-
-
-
-
-
-
-
-
-
-
-
-
-
-
-
-
-
-
-
-
-
-
-
-
-
-
-
```

All contents of this site are © 2024 Passmedicine Limited

A 21-year-old woman presents to the emergency department with an itchy rash. It developed over the course of the day which she spent at the beach with friends.

She complains of an itching and burning sensation on her upper arms, trunk and thighs.

On examination there are crops of 3mm pink papules over the symptomatic areas, sparing her face and her hands.

What is the most likely diagnosis?

| | |
|---|---|
| Scabies | 4% |
| Systemic lupus erythematosus | 1% |
| Xeroderma pigmentosum | 7% |
| Photoallergic contact dermatitis | 32% |
| Polymorphic light eruption | 55% |

Photoallergic contact dermatitis is a toxic or allergic reaction that occurs when certain chemicals are applied to the skin and subsequently exposed to the sun. It is unlikely to spare the hands and face.

Xeroderma pigmentosum is a rare hereditary defect of the enzyme system that repairs DNA after damage from ultraviolet rays, resulting in extreme sensitivity to sunlight and a tendency to develop skin cancer. It typically presents in youth with multiple basal cell carcinomas and other skin malignancies.

The photosensitive rash of systemic lupus erythematosus classically includes the the butterfly-shaped rash that appears over the bridge of the nose and both cheeks.

The rash associated with scabies often appears as erythematous papules on the trunk and limbs with vesicles on palms and soles and irregular tracks in the web spaces between the fingers.

Discuss (5) Improve

Next question

# Polymorphic light eruption

Polymorphic light eruption (PLE) is a common form of primary photosensitivity that mainly occurs in young adult women in temperate climates during spring and summer.

The name polymorphic refers to the fact that the rash can take many forms, although in one individual it usually looks the same every time it appears.

In most affected individuals, it occurs each spring, provoked by several hours outside on a sunny day. If further sun exposure is avoided, the rash settles in a few days.

The arms, the back of the hands, the V of the neck, the chest and lower legs/feet may be affected, but the face is usually spared.

AI + Q 123

Next question

**Textbooks**

High-yield textbook

Extended textbook

Score: **28%**

1 ✕

| | |
|---|---|
| 2 | ✓ |
| 3 | ✓ |
| 4 | ✗ |
| 5 | ✗ |
| 6 | ✗ |
| 7 | ✗ |
| 8 | ✗ |
| 9 | ✗ |
| 10 | ✗ |
| 11 | ✗ |
| 12 | ✗ |
| 13 | ✓ |
| 14 | ✓ |
| 15 | ✓ |
| 16 | ✗ |
| 17 | ✓ |
| 18 | ✓ |
| 19 | ✗ |
| 20 | ✗ |
| 21 | ✗ |
| 22 | ✗ |
| 23 | ✗ |
| 24 | ✓ |
| 25 | ✗ |
| 26 | ✓ |
| 27 | ✗ |
| 28 | ✗ |
| 29 | ✗ |
| 30 | ✓ |
| 31 | ✗ |
| 32 | ✗ |
| 33 | ✗ |
| 34 | ✗ |
| 35 | ✓ |
| 36 | ✗ |
| 37 | ✗ |

| | |
|---|---|
| 38 | ✗ |
| 39 | ✗ |
| 40 | ✗ |
| 41 | ✗ |
| 42 | ✓ |
| 43 | ✗ |
| 44 | ✗ |
| 45 | ✓ |
| **46** | ✓ |
| 47 | ✗ |
| 48 | ✗ |
| 49 | ✗ |
| 50 | ✗ |

All contents of this site are © 2024 Passmedicine Limited

A 27-year-old man was seen in the dermatology clinic with an itchy, vesicular rash over buttocks and proximal forearms. He was otherwise well.

A subsequent skin biopsy and direct immunofluorescence demonstrate granular IgA at the dermal-epidermal junction. Given the most likely diagnosis, he was started on dapsone and given specific diary advice.

Six weeks later he complains of worsening fatigue.

What is the most important investigation?

- Full blood count
- Echocardiogram
- ECG
- Urine protein:creatinine ratio
- Creatine kinase

Submit answer

Reference ranges

Score: **0%**

1 -
2 -
3 -
4 -
5 -

```
-
-
-
-
-
-
-
-
-
-
-
-
-
-
-
-
-
-
-
-
-
-
-
-
-
-
-
-
-
-
-
-
-
-
-
-
-
-
-
-
```

| | |
|---|---|
| 46 | - |
| 47 | - |

All contents of this site are © 2024 Passmedicine Limited

A 27-year-old man was seen in the dermatology clinic with an itchy, vesicular rash over buttocks and proximal forearms. He was otherwise well.

A subsequent skin biopsy and direct immunofluorescence demonstrate granular IgA at the dermal-epidermal junction. Given the most likely diagnosis, he was started on dapsone and given specific diary advice.

Six weeks later he complains of worsening fatigue.

What is the most important investigation?

| | |
|---|---|
| Full blood count | 82% |
| Echocardiogram | 3% |
| ECG | 2% |
| Urine protein:creatinine ratio | 6% |
| Creatine kinase | 7% |

The patient has dermatitis herpetiformis - an inflammatory cutaneous condition closely associated with gluten sensitive enteropathy (coeliac disease).

Dapsone is an antibacterial agent that can provide temporary symptomatic relief as a gluten-free diet is established. The main side effect is that of haemolytic anaemia - so regular full blood counts are essential. Other side effects include peripheral neuropathy and rarely agranulocytosis.

The remaining options are clearly not correct if the candidate is aware of the side effects of dapsone - a MRCP favourite - as is the presentation of dermatitis herpetiformis without overt diarrhoea.

Further reading:
BMJ Easily Missed: Dermatitis Herpetiformis
http://www.bmj.com/content/348/bmj.g2557

Discuss (5) Improve

Next question

# Dermatitis herpetiformis

Dermatitis herpetiformis is an autoimmune blistering skin disorder associated with coeliac disease. It is caused by deposition of IgA in the dermis. More than 90% of patients exhibit small bowel biopsy findings consistent with some degree of gluten-sensitive enteropathy.

Features
- itchy, vesicular skin lesions on the extensor surfaces (e.g. elbows, knees, buttocks)

Diagnosis
- skin biopsy: direct immunofluorescence shows deposition of IgA in a granular pattern in the upper dermis

Management
- gluten-free diet
- dapsone

123

Next question

## Textbooks

High-yield textbook

Extended textbook

## Links

DermNet NZ

Dermatitis herpetiformis

34 6

Suggest link

Report broken link

Score: **28%**

| | |
|---|---|
| 1 | ✗ |
| 2 | ✓ |
| 3 | ✓ |
| 4 | ✗ |
| 5 | ✗ |
| 6 | ✗ |
| 7 | ✗ |
| 8 | ✗ |
| 9 | ✗ |
| 10 | ✗ |
| 11 | ✗ |
| 12 | ✗ |
| 13 | ✓ |
| 14 | ✓ |
| 15 | ✓ |
| 16 | ✗ |
| 17 | ✓ |
| 18 | ✓ |

| | |
|---|---|
| 19 | ✗ |
| 20 | ✗ |
| 21 | ✗ |
| 22 | ✗ |
| 23 | ✗ |
| 24 | ✓ |
| 25 | ✗ |
| 26 | ✓ |
| 27 | ✗ |
| 28 | ✗ |
| 29 | ✗ |
| 30 | ✓ |
| 31 | ✗ |
| 32 | ✗ |
| 33 | ✗ |
| 34 | ✗ |
| 35 | ✓ |
| 36 | ✗ |
| 37 | ✗ |
| 38 | ✗ |
| 39 | ✗ |
| 40 | ✗ |
| 41 | ✗ |
| 42 | ✓ |
| 43 | ✗ |
| 44 | ✗ |
| 45 | ✓ |
| 46 | ✓ |
| **47** | ✗ |
| 48 | ✗ |
| 49 | ✗ |
| 50 | ✗ |

All contents of this site are © 2024 Passmedicine Limited

Back to top

This woman complains of a 'rash' on her cheeks. She has recently started taking hormone replacement therapy for menopausal symptoms.

© Image used on license from DermNet NZ

What is the most likely diagnosis?

- Vitiligo
- Seborrhoeic dermatitis
- Acne rosacea
- Melasma
- Systemic lupus erythematosus

Submit answer

Reference ranges

Score: **0%**

| | |
|---|---|
| 1 | - |
| 2 | - |
| 3 | - |
| 4 | - |
| 5 | - |
| 6 | - |
| 7 | - |
| 8 | - |
| 9 | - |
| 10 | - |
| 11 | - |
| 12 | - |
| 13 | - |
| 14 | - |
| 15 | - |
| 16 | - |
| 17 | - |
| 18 | - |
| 19 | - |
| 20 | - |
| 21 | - |
| 22 | - |
| 23 | - |
| 24 | - |
| 25 | - |
| 26 | - |
| 27 | - |
| 28 | - |
| 29 | - |
| 30 | - |
| 31 | - |
| 32 | - |
| 33 | - |
| 34 | - |
| 35 | - |
| 36 | - |
| 37 | - |

38 -
39 -
40 -
41 -
42 -
43 -
44 -
45 -
46 -
47 -
**48** -

All contents of this site are © 2024 Passmedicine Limited
Back to top

This woman complains of a 'rash' on her cheeks. She has recently started taking hormone replacement therapy for menopausal symptoms.

© Image used on license from DermNet NZ

What is the most likely diagnosis?

| | |
|---|---|
| Vitiligo | 8% |
| Seborrhoeic dermatitis | 1% |
| Acne rosacea | 8% |
| Melasma | 81% |
| Systemic lupus erythematosus | 2% |

The correct answer is **Melasma**. Melasma, also known as chloasma, is a common skin condition of adults in which light to dark brown or greyish pigmentation develops, mainly on the face. The image shows hyperpigmented patches on the cheeks, a typical presentation of melasma. It is more common in women and often related to hormonal changes such as pregnancy or hormone treatments like hormone replacement therapy (HRT).

**Vitiligo** is incorrectly identified here because it presents with depigmented patches rather than hyperpigmented. Vitiligo is an autoimmune condition that causes loss of melanocytes leading to

white patches on the skin.

**Seborrhoeic dermatitis** would be incorrect as well. Seborrhoeic dermatitis typically presents with a red, scaly, itchy rash usually located on the scalp, eyebrows, nasolabial folds and chest. It does not cause hyperpigmentation.

The diagnosis of **Acne rosacea** would be unlikely given the absence of papules, pustules or rhinophyma which are characteristic for this condition. Rosacea generally affects middle-aged women and presents with flushing and persistent erythema along with telangiectasia.

Lastly, **Systemic lupus erythematosus (SLE)** can indeed present with a facial rash known as malar rash or 'butterfly' rash but this tends to be erythematous and sparing nasolabial folds, unlike melasma which often involves these areas. Additionally, SLE usually comes with other systemic symptoms like joint pain and fatigue which were not mentioned in this scenario.

Discuss (1) Improve

Next question

## Melasma

Melasma is a condition associated with the development of hyperpigmented macules in sun-exposed areas, particularly the face. The term chloasma is sometimes used interchangeably but more specifically describes the appearance of melasma during pregnancy.

Epidemiology
- more common in women
- more common in people with darker skin

Causes
- pregnancy
- combined oral contraceptive pill, hormone replacement therapy

© Image used on license from DermNet NZ

123

Next question

## Textbooks

High-yield textbook

Extended textbook

## Links

DermNet NZ 4 0

Melasma

Suggest link

Report broken link

Score: **28%**

| | |
|---|---|
| 1 | ✗ |
| 2 | ✓ |
| 3 | ✓ |
| 4 | ✗ |
| 5 | ✗ |
| 6 | ✗ |
| 7 | ✗ |
| 8 | ✗ |
| 9 | ✗ |
| 10 | ✗ |
| 11 | ✗ |
| 12 | ✗ |
| 13 | ✓ |
| 14 | ✓ |
| 15 | ✓ |
| 16 | ✗ |
| 17 | ✓ |
| 18 | ✓ |
| 19 | ✗ |
| 20 | ✗ |
| 21 | ✗ |
| 22 | ✗ |
| 23 | ✗ |
| 24 | ✓ |
| 25 | ✗ |
| 26 | ✓ |
| 27 | ✗ |
| 28 | ✗ |
| 29 | ✗ |
| 30 | ✓ |
| 31 | ✗ |
| 32 | ✗ |
| 33 | ✗ |

34 ✗
35 ✓
36 ✗
37 ✗
38 ✗
39 ✗
40 ✗
41 ✗
42 ✓
43 ✗
44 ✗
45 ✓
46 ✓
47 ✗
**48** ✗
49 ✗
50 ✗

All contents of this site are © 2024 Passmedicine Limited
Back to top

A 74-year-old male presents to the acute medical take with left sided chest pain, worse on inspiration. On examination, you note his nails are yellow and clubbed with bilateral non-pitting oedema. Examination of his chest reveals reduced air entry of his left lung to mid zone, dull to percussion, with no wheeze.

He has a known past medical history of bronchiectasis diagnosed 2 years ago, for which he has been admitted 3 times in the past 5 months. He reports weight loss of about 8kg in the past 9 months. He last underwent an echocardiogram 2 years ago, during which a left ventricular ejection fraction of 56% was demonstrated.

A chest radiograph demonstrates a large left pleural effusion and a mark has been made by ultrasound for a pleural tap.

Pleural fluid analysis results are as follows:

| | |
|---|---|
| pH | 7.42 |
| Protein | 40 g/L (serum 58) |
| LDH | 130 IU/L (serum 181) |
| Glucose | 3.5 mmol/l (serum 6.2) |
| Amylase | 22 u/l (serum 32) |
| Triglycerides | 1.90 mmol/L (serum 2.2) |
| Cytology | awaited |
| AFB | awaited |

What is the unifying diagnosis?

- Parapneumonic effusion
- Yellow nail syndrome
- Malignant pleural effusion
- Oesophageal rupture
- Congestive cardiac failure

Submit answer

Reference ranges

Score: **0%**

| | |
|---|---|
| 1 | - |
| 2 | - |
| 3 | - |
| 4 | - |
| 5 | - |
| 6 | - |
| 7 | - |
| 8 | - |
| 9 | - |
| 10 | - |
| 11 | - |
| 12 | - |
| 13 | - |
| 14 | - |
| 15 | - |
| 16 | - |
| 17 | - |
| 18 | - |
| 19 | - |
| 20 | - |
| 21 | - |
| 22 | - |
| 23 | - |
| 24 | - |
| 25 | - |
| 26 | - |
| 27 | - |
| 28 | - |
| 29 | - |

30 -
31 -
32 -
33 -
34 -
35 -
36 -
37 -
38 -
39 -
40 -
41 -
42 -
43 -
44 -
45 -
46 -
47 -
48 -
49 -

All contents of this site are © 2024 Passmedicine Limited

Back to top

A 74-year-old male presents to the acute medical take with left sided chest pain, worse on inspiration. On examination, you note his nails are yellow and clubbed with bilateral non-pitting oedema. Examination of his chest reveals reduced air entry of his left lung to mid zone, dull to percussion, with no wheeze.

He has a known past medical history of bronchiectasis diagnosed 2 years ago, for which he has been admitted 3 times in the past 5 months. He reports weight loss of about 8kg in the past 9 months. He last underwent an echocardiogram 2 years ago, during which a left ventricular ejection fraction of 56% was demonstrated.

A chest radiograph demonstrates a large left pleural effusion and a mark has been made by ultrasound for a pleural tap.

Pleural fluid analysis results are as follows:

| | |
|---|---|
| pH | 7.42 |
| Protein | 40 g/L (serum 58) |
| LDH | 130 IU/L (serum 181) |
| Glucose | 3.5 mmol/l (serum 6.2) |
| Amylase | 22 u/l (serum 32) |
| Triglycerides | 1.90 mmol/L (serum 2.2) |
| Cytology | awaited |
| AFB | awaited |

What is the unifying diagnosis?

- Parapneumonic effusion 5%
- Yellow nail syndrome 75%
- Malignant pleural effusion 18%
- Oesophageal rupture 1%
- Congestive cardiac failure 1%

Diagnosis here is dependent on subtle details in the history and pleural fluid analysis: the patient has bronchiectasis, pleural effusion (exudate), lymphoedema (not pitting oedema), chylothorax (note the significantly raised triglycerides in the pleural fluid) and of course, yellow nails! The patient has yellow nail syndrome, characterised by nail dystrophy or discolouration, lymphoedema and pleural effusions. A parapneumonic and malignant effusion are reasonable differentials but do not explain the triglycerides. Oesophageal rupture classically increases pleural amylase. Lastly, congestive cardiac failure classically produces a transudate.

Discuss (11) Improve

Next question

## Yellow nail syndrome

Slowing of the nail growth leads to the characteristic thickened and discoloured nails seen in yellow nail syndrome.

Associations

- congenital lymphoedema
- pleural effusions
- bronchiectasis
- chronic sinus infections

123

Next question

### Textbooks

High-yield textbook

Extended textbook

## Links

Dermnet NZ 3 1

Yellow Nail Syndrome

Suggest link Report broken link

Score: **28%**

| | |
|---|---|
| 1 | ✗ |
| 2 | ✓ |
| 3 | ✓ |
| 4 | ✗ |
| 5 | ✗ |
| 6 | ✗ |
| 7 | ✗ |
| 8 | ✗ |
| 9 | ✗ |
| 10 | ✗ |
| 11 | ✗ |
| 12 | ✗ |
| 13 | ✓ |
| 14 | ✓ |
| 15 | ✓ |
| 16 | ✗ |
| 17 | ✓ |
| 18 | ✓ |
| 19 | ✗ |
| 20 | ✗ |
| 21 | ✗ |
| 22 | ✗ |

| | |
|---|---|
| 23 | ✗ |
| 24 | ✓ |
| 25 | ✗ |
| 26 | ✓ |
| 27 | ✗ |
| 28 | ✗ |
| 29 | ✗ |
| 30 | ✓ |
| 31 | ✗ |
| 32 | ✗ |
| 33 | ✗ |
| 34 | ✗ |
| 35 | ✓ |
| 36 | ✗ |
| 37 | ✗ |
| 38 | ✗ |
| 39 | ✗ |
| 40 | ✗ |
| 41 | ✗ |
| 42 | ✓ |
| 43 | ✗ |
| 44 | ✗ |
| 45 | ✓ |
| 46 | ✓ |
| 47 | ✗ |
| 48 | ✗ |
| **49** | ✗ |
| 50 | ✗ |

All contents of this site are © 2024 Passmedicine Limited

Back to top

A 34-year-old woman presents to the general practitioner with a 2-day history of an erythematous rash over her upper limbs. She describes waking up yesterday morning with multiple lesions over her arms. The rash is not itchy or painful and has not resolved despite regular emollient use. She has no past medical history of note.

On examination, she appears well. There is a crusted cold sore on her top lip. Her chest is clear and her heart sounds are normal. She has a soft abdomen.

Her rash is examined and appears as shown below:

© Image used on license from DermNet NZ

What is the most likely diagnosis?

- Eosinophilic granulomatosis with polyangiitis
- Erythema marginatum
- Erythema multiforme
- Plaque psoriasis
- Urticaria

Submit answer

Reference ranges

Score: **0%**

| | |
|---|---|
| 1 | - |
| 2 | - |
| 3 | - |
| 4 | - |
| 5 | - |
| 6 | - |
| 7 | - |
| 8 | - |
| 9 | - |
| 10 | - |
| 11 | - |
| 12 | - |
| 13 | - |
| 14 | - |
| 15 | - |
| 16 | - |
| 17 | - |
| 18 | - |
| 19 | - |
| 20 | - |
| 21 | - |
| 22 | - |
| 23 | - |
| 24 | - |
| 25 | - |
| 26 | - |
| 27 | - |
| 28 | - |
| 29 | - |

30 -
31 -
32 -
33 -
34 -
35 -
36 -
37 -
38 -
39 -
40 -
41 -
42 -
43 -
44 -
45 -
46 -
47 -
48 -
49 -
**50** -

All contents of this site are © 2024 Passmedicine Limited
Back to top

A 34-year-old woman presents to the general practitioner with a 2-day history of an erythematous rash over her upper limbs. She describes waking up yesterday morning with multiple lesions over her arms. The rash is not itchy or painful and has not resolved despite regular emollient use. She has no past medical history of note.

On examination, she appears well. There is a crusted cold sore on her top lip. Her chest is clear and her heart sounds are normal. She has a soft abdomen.

Her rash is examined and appears as shown below:

© Image used on license from DermNet NZ

What is the most likely diagnosis?

- Eosinophilic granulomatosis with polyangiitis 1%
- Erythema marginatum 13%
- Erythema multiforme 77%
- Plaque psoriasis 7%
- Urticaria 3%

This patient has multiple well-demarcated, round target lesions with an outermost erythematous ring and paler centre in keeping with a diagnosis of erythema multiforme. Erythema multiforme is an acute, self-limiting skin eruption most commonly secondary to an infective trigger (e.g. herpes simplex virus or *Mycoplasma pneumoniae*). The rash appears abruptly and affects the upper limbs most often before spreading down towards the trunk. One of this patient's examination findings included a cold sore, suggesting a recent infection with herpes simplex virus, the likely trigger of her rash.

Urticaria presents as an itchy rash with multiple weals over the skin. They usually appear pale or light pink and may be surrounded by a red flare. The most common trigger is an allergic reaction, although viral infections may also precipitate urticaria. Urticaria does not cause the target lesions seen in the above image, making it an unlikely diagnosis.

Eosinophilic granulomatosis with polyangiitis is a small-vessel vasculitis with symptoms including asthma, allergic rhinitis and constitutional symptoms of weight loss, fevers and night sweats. Skin involvement can manifest in up to 50% of patients and include blisters, petechiae and ulceration. This is not seen in the image above. Furthermore, there is nothing in this patient's clinical history to suggest an underlying diagnosis of vasculitis.

Erythema marginatum is a manifestation of acute rheumatic fever. It is most commonly seen in children and is rare in adults. It presents as annular erythematous macules or papules that spread outwards with central clearance. The lesions are not itchy or painful and may be asymptomatic.

Plaque psoriasis is a chronic inflammatory skin condition that gives rise to well-defined red plaques with an overlying silver scale. Common features include itch and painful fissures. The rash in the image does not show the presence of erythematous plaques. Furthermore, this patient's rash has had an acute onset which is atypical of psoriasis that has a much slower onset.

Discuss (2) Improve

Next question >

## Erythema multiforme

Erythema multiforme is a hypersensitivity reaction that is most commonly triggered by infections. It may be divided into minor and major forms.

Previously it was thought that Stevens-Johnson syndrome (SJS) was a severe form of erythema multiforme. They are now however considered as separate entities.

Features

- target lesions
- initially seen on the back of the hands / feet before spreading to the torso
- upper limbs are more commonly affected than the lower limbs
- pruritus is occasionally seen and is usually mild

Causes

- viruses: herpes simplex virus (the most common cause), Orf*
- idiopathic
- bacteria: *Mycoplasma*, *Streptococcus*
- drugs: penicillin, sulphonamides, carbamazepine, allopurinol, NSAIDs, oral contraceptive pill, nevirapine
- connective tissue disease e.g. Systemic lupus erythematosus
- sarcoidosis
- malignancy

## Erythema multiforme major

The more severe form, erythema multiforme major is associated with mucosal involvement.

*Orf is a skin disease of sheep and goats caused by a parapox virus

123

Next question

## Textbooks

High-yield textbook

Extended textbook

## Links

DermNet NZ 18 10

Erythema multiforme

Suggest link

Report broken link

## Media

Erythema multiforme

Osmosis - YouTube 1 0

Report broken media

Score: **28%**

| | |
|---|---|
| 1 | ✗ |
| 2 | ✓ |
| 3 | ✓ |
| 4 | ✗ |
| 5 | ✗ |
| 6 | ✗ |
| 7 | ✗ |
| 8 | ✗ |
| 9 | ✗ |
| 10 | ✗ |
| 11 | ✗ |
| 12 | ✗ |
| 13 | ✓ |
| 14 | ✓ |
| 15 | ✓ |
| 16 | ✗ |
| 17 | ✓ |
| 18 | ✓ |
| 19 | ✗ |
| 20 | ✗ |
| 21 | ✗ |
| 22 | ✗ |
| 23 | ✗ |
| 24 | ✓ |
| 25 | ✗ |
| 26 | ✓ |
| 27 | ✗ |
| 28 | ✗ |
| 29 | ✗ |
| 30 | ✓ |
| 31 | ✗ |
| 32 | ✗ |
| 33 | ✗ |

| | |
|---|---|
| 34 | ✗ |
| 35 | ✓ |
| 36 | ✗ |
| 37 | ✗ |
| 38 | ✗ |
| 39 | ✗ |
| 40 | ✗ |
| 41 | ✗ |
| 42 | ✓ |
| 43 | ✗ |
| 44 | ✗ |
| 45 | ✓ |
| 46 | ✓ |
| 47 | ✗ |
| 48 | ✗ |
| 49 | ✗ |
| **50** | ✗ |

All contents of this site are © 2024 Passmedicine Limited

Back to top

A 72-year-old gentleman presents with a peeling and erythematous rash on both of his hands. He has noticed slight tingling in the same area but denies pain. He has a past medical history of colorectal cancer which was managed surgically with an anterior resection. He developed local recurrence of his cancer five months post-operatively. He is now on palliative chemotherapy with capecitabine and oxaliplatin every two weeks in order to control progression. His last treatment was one week ago. He has a history of type two diabetes mellitus, depression and has had a cholecystectomy when he was younger. On examination he appears frail and cachectic, but systemically well. His hands are shown to have patchy palmar erythema with mild desquamation. A similar rash is present on the soles of his feet.

Observations:

| | |
|---|---|
| Saturations | 97% |
| Respiratory rate | 17/min |
| Blood pressure | 132/73mmHg |
| Heart rate | 71/min |
| Temperature | 37.3°C |

What is the most likely diagnosis?

- Erythromelalgia
- Palmoplantar psoriasis
- Palmar-plantar erythrodysesthesia
- Paraneoplastic syndrome
- Cellulitis

Submit answer

Reference ranges

Score: **28%**

| | |
|---|---|
| 1 | ✗ |
| 2 | ✓ |
| 3 | ✓ |
| 4 | ✗ |
| 5 | ✗ |
| 6 | ✗ |
| 7 | ✗ |
| 8 | ✗ |
| 9 | ✗ |
| 10 | ✗ |
| 11 | ✗ |
| 12 | ✗ |
| 13 | ✓ |
| 14 | ✓ |
| 15 | ✓ |
| 16 | ✗ |
| 17 | ✓ |
| 18 | ✓ |
| 19 | ✗ |
| 20 | ✗ |
| 21 | ✗ |
| 22 | ✗ |
| 23 | ✗ |
| 24 | ✓ |
| 25 | ✗ |
| 26 | ✓ |
| 27 | ✗ |
| 28 | ✗ |
| 29 | ✗ |
| 30 | ✓ |
| 31 | ✗ |
| 32 | ✗ |
| 33 | ✗ |
| 34 | ✗ |

| | |
|---|---|
| 35 | ✓ |
| 36 | ✗ |
| 37 | ✗ |
| 38 | ✗ |
| 39 | ✗ |
| 40 | ✗ |
| 41 | ✗ |
| 42 | ✓ |
| 43 | ✗ |
| 44 | ✗ |
| 45 | ✓ |
| 46 | ✓ |
| 47 | ✗ |
| 48 | ✗ |
| 49 | ✗ |
| 50 | ✗ |
| **51** | - |

All contents of this site are © 2024 Passmedicine Limited

A 72-year-old gentleman presents with a peeling and erythematous rash on both of his hands. He has noticed slight tingling in the same area but denies pain. He has a past medical history of colorectal cancer which was managed surgically with an anterior resection. He developed local recurrence of his cancer five months post-operatively. He is now on palliative chemotherapy with capecitabine and oxaliplatin every two weeks in order to control progression. His last treatment was one week ago. He has a history of type two diabetes mellitus, depression and has had a cholecystectomy when he was younger. On examination he appears frail and cachectic, but systemically well. His hands are shown to have patchy palmar erythema with mild desquamation. A similar rash is present on the soles of his feet.

Observations:

| | |
|---|---|
| Saturations | 97% |
| Respiratory rate | 17/min |
| Blood pressure | 132/73mmHg |
| Heart rate | 71/min |
| Temperature | 37.3°C |

What is the most likely diagnosis?

- Erythromelalgia 6%
- Palmoplantar psoriasis 4%
- Palmar-plantar erythrodysesthesia 82%
- Paraneoplastic syndrome 8%
- Cellulitis 0%

The answer is palmar-planter erythrodysesthesia. The distribution of a dysesthesic erythematous rash with desquamation of the palms and soles is a classic description of palmar-plantar erythrodysesthesia during chemotherapy. Cellulitis, paraneoplastic syndromes, and erythromelalgia do not fit this distribution, and palmoplantar psoriasis is associated with itching.

Discuss (3) Improve

Next question

# Palmar-plantar erythrodysesthesia

Palmar-plantar erythrodysesthesia is a common side effect of many chemotherapy treatments, occurring from days to months into treatment. It usually presents with tingling or numbness first in the fingers and palms and then toes and soles of the feet. This is then followed by an erythematous rash which can desquamate, blister and ulcerate which can be associated with onycholysis. Management depends on severity; mild reactions with only dysesthesia and no pain can be managed with supportive care, but severe reactions with serious desquamation, blistering and ulceration will need to have treatment delayed and the dose of chemotherapy reduced.

Source:

Moos, Roger Von, Beat J.k. Thuerlimann, Matti Aapro, Daniel Rayson, Karen Harrold, Jalid Sehouli, Florian Scotte, Domenica Lorusso, Reinhard Dummer, Mario E. Lacouture, Jurgen Lademann, and Axel Hauschild. 'Pegylated Liposomal Doxorubicin-associated Handfoot Syndrome: Recommendations of an International Panel of Experts.' European Journal of Cancer 44.6 (2008): 781-90.

123

Next question

Textbooks

High-yield textbook

Extended textbook

Score: **25.6%**

| | |
|---|---|
| 1 | ✗ |
| 2 | ✓ |
| 3 | ✓ |
| 4 | ✗ |
| 5 | ✗ |
| 6 | ✗ |
| 7 | ✗ |
| 8 | ✗ |
| 9 | ✗ |
| 10 | ✗ |
| 11 | ✗ |
| 12 | ✗ |
| 13 | ✓ |
| 14 | ✓ |
| 15 | ✓ |
| 16 | ✗ |
| 17 | ✓ |
| 18 | ✓ |
| 19 | ✗ |
| 20 | ✗ |
| 21 | ✗ |
| 22 | ✗ |
| 23 | ✗ |
| 24 | ✓ |
| 25 | ✗ |
| 26 | ✓ |
| 27 | ✗ |
| 28 | ✗ |
| 29 | ✗ |
| 30 | ✓ |
| 31 | ✗ |
| 32 | ✗ |

| | |
|---|---|
| 33 | ✗ |
| 34 | ✗ |
| 35 | ✓ |
| 36 | ✗ |
| 37 | ✗ |
| 38 | ✗ |
| 39 | ✗ |
| 40 | ✗ |
| 41 | ✗ |
| 42 | ✓ |
| 43 | ✗ |
| 44 | ✗ |
| 45 | ✓ |
| 46 | ✓ |
| 47 | ✗ |
| 48 | ✗ |
| 49 | ✗ |
| 50 | ✗ |
| **51** | ✗ |
| 52 | ✗ |
| 53 | ✓ |
| 54 | ✗ |
| 55 | ✗ |
| 56 | ✗ |
| 57 | ✗ |
| 58 | ✗ |
| 59 | ✗ |
| 60 | ✗ |
| 61 | ✗ |
| 62 | ✓ |
| 63 | ✗ |
| 64 | ✓ |
| 65 | ✗ |
| 66 | ✓ |
| 67 | ✓ |
| 68 | ✗ |

| | |
|---|---|
| 69 | ✗ |
| 70 | ✗ |
| 71 | ✗ |
| 72 | ✗ |
| 73 | ✗ |
| 74 | ✗ |
| 75 | ✓ |
| 76 | ✗ |
| 77 | ✗ |
| 78 | ✗ |
| 79 | ✗ |
| 80 | ✗ |
| 81 | ✗ |
| 82 | ✓ |

All contents of this site are © 2024 Passmedicine Limited

Back to top

A 53-year-old woman is seen in the dermatology clinic with a 4-week history of an itchy rash on her lower legs. She has tried various antihistamines and a cold compress, but these have not relieved her symptoms. There is no history of pain or bleeding and she is systemically well. Her past medical history includes chronic hepatitis C infection. She takes no regular medication.

On examination, her rash appears as shown below.

© Image used on license from DermNet NZ

What is the most likely diagnosis?

- Bullous pemphigus
- Lichen planus
- Lichen sclerosus
- Molluscum contagiosum
- Pemphigus vulgaris

Submit answer

Reference ranges

Score: **28%**

| | |
|---|---|
| 1 | ✗ |
| 2 | ✓ |
| 3 | ✓ |
| 4 | ✗ |
| 5 | ✗ |
| 6 | ✗ |
| 7 | ✗ |
| 8 | ✗ |
| 9 | ✗ |
| 10 | ✗ |
| 11 | ✗ |
| 12 | ✗ |
| 13 | ✓ |
| 14 | ✓ |
| 15 | ✓ |
| 16 | ✗ |
| 17 | ✓ |
| 18 | ✓ |
| 19 | ✗ |
| 20 | ✗ |
| 21 | ✗ |
| 22 | ✗ |
| 23 | ✗ |
| 24 | ✓ |
| 25 | ✗ |
| 26 | ✓ |

| | |
|---|---|
| 27 | ✗ |
| 28 | ✗ |
| 29 | ✗ |
| 30 | ✓ |
| 31 | ✗ |
| 32 | ✗ |
| 33 | ✗ |
| 34 | ✗ |
| 35 | ✓ |
| 36 | ✗ |
| 37 | ✗ |
| 38 | ✗ |
| 39 | ✗ |
| 40 | ✗ |
| 41 | ✗ |
| 42 | ✓ |
| 43 | ✗ |
| 44 | ✗ |
| 45 | ✓ |
| 46 | ✓ |
| 47 | ✗ |
| 48 | ✗ |
| 49 | ✗ |
| 50 | ✗ |
| 51 | - |
| **52** | - |

All contents of this site are © 2024 Passmedicine Limited

Back to top

PassMedicine



A 53-year-old woman is seen in the dermatology clinic with a 4-week history of an itchy rash on her lower legs. She has tried various antihistamines and a cold compress, but these have not relieved her symptoms. There is no history of pain or bleeding and she is systemically well. Her past medical history includes chronic hepatitis C infection. She takes no regular medication.

On examination, her rash appears as shown below.

© Image used on license from DermNet NZ

What is the most likely diagnosis?

| | |
|---|---|
| Bullous pemphigus | 10% |
| Lichen planus | 47% |
| Lichen sclerosus | 5% |
| Molluscum contagiosum | 33% |
| Pemphigus vulgaris | 6% |

The photograph above shows multiple round, well-circumscribed, raised purple lesions. On closer inspection, subtle white markings can be visualised on top of the lesions, otherwise known as Wickham striae. The clinical history and appearance of the rash are in keeping with a diagnosis of lichen planus. Lichen planus is typically an itchy rash that appears as flat-topped plaques. The colour of the rash is dependent on skin tone. However, in fairer skin tones, the rash is more likely to look purple in colour. Rarely, nail involvement can be seen which includes thinning of the nail bed to onycholysis. Infection with hepatitis C is a risk factor for developing lichen planus. The treatment of choice is potent topical corticosteroids.

Bullous pemphigus is an autoimmune blistering disease commonly seen in those over 60 years. Typically a non-specific rash is seen for several weeks before the development of tense blisters between the dermis and epidermis. Any part of the skin can be affected, although the flexor aspects are more commonly affected.

Lichen sclerosus is most commonly diagnosed in women over the age of 50. It is a chronic dermatological disorder of the genital and peri-anal skin. It is possible for lichen sclerosus to overlap with other skin conditions such as lichen planus or psoriasis. However, the absence of vulval symptoms in this patient makes the diagnosis less likely.

Molluscum contagiosum is a viral condition that is commonly seen in childhood or the immunocompromised. It presents as clusters of round papules with an umbilicated centre and each papule contain a thick creamy material. There is nothing in this patient's history to suggest immunosuppression and therefore molluscum contagiosum is unlikely.

Pemphigus vulgaris is an autoimmune disease characterised by painful blisters and erosions on the skin. Mucous membranes are also involved and are usually the first site to be affected during the onset of the disease, followed by epidermal involvement. It typically arises in those aged between 30-60 years. Unlike bullous pemphigus, pemphigus vulgaris presents as flaccid blisters which easily rupture to cause painful erosions. These are not seen in the image above making the diagnosis less likely.

Discuss (2) Improve

Next question

## Lichen planus

Lichen planus is a skin disorder of unknown aetiology, most probably being immune-mediated.

Features

- itchy, papular rash most common on the palms, soles, genitalia and flexor surfaces of arms
- rash often polygonal in shape, with a 'white-lines' pattern on the surface (Wickham's striae)
- Koebner phenomenon may be seen (new skin lesions appearing at the site of trauma)
- oral involvement in around 50% of patients: typically a white-lace pattern on the buccal mucosa
- nails: thinning of nail plate, longitudinal ridging

Lichenoid drug eruptions - causes:

- gold
- quinine
- thiazides

Management

- potent topical steroids are the mainstay of treatment
- benzydamine mouthwash or spray is recommended for oral lichen planus
- extensive lichen planus may require oral steroids or immunosuppression

Next question

## Textbooks

High-yield textbook

Extended textbook

## Links

Primary Care Dermatology Society 21 7

Lichen planus

DermNet NZ 22 3

Lichen planus

Suggest link

Report broken link

## Media

Lichen planus

Osmosis - YouTube 5 1

Report broken media

Score: **25.6%**

1 ✗
2 ✓
3 ✓
4 ✗
5 ✗

| | |
|---|---|
| 6 | ✗ |
| 7 | ✗ |
| 8 | ✗ |
| 9 | ✗ |
| 10 | ✗ |
| 11 | ✗ |
| 12 | ✗ |
| 13 | ✓ |
| 14 | ✓ |
| 15 | ✓ |
| 16 | ✗ |
| 17 | ✓ |
| 18 | ✓ |
| 19 | ✗ |
| 20 | ✗ |
| 21 | ✗ |
| 22 | ✗ |
| 23 | ✗ |
| 24 | ✓ |
| 25 | ✗ |
| 26 | ✓ |
| 27 | ✗ |
| 28 | ✗ |
| 29 | ✗ |
| 30 | ✓ |
| 31 | ✗ |
| 32 | ✗ |
| 33 | ✗ |
| 34 | ✗ |
| 35 | ✓ |
| 36 | ✗ |
| 37 | ✗ |
| 38 | ✗ |
| 39 | ✗ |
| 40 | ✗ |
| 41 | ✗ |

| | |
|---|---|
| 42 | ✓ |
| 43 | ✗ |
| 44 | ✗ |
| 45 | ✓ |
| 46 | ✓ |
| 47 | ✗ |
| 48 | ✗ |
| 49 | ✗ |
| 50 | ✗ |
| 51 | ✗ |
| **52** | ✗ |
| 53 | ✓ |
| 54 | ✗ |
| 55 | ✗ |
| 56 | ✗ |
| 57 | ✗ |
| 58 | ✗ |
| 59 | ✗ |
| 60 | ✗ |
| 61 | ✗ |
| 62 | ✓ |
| 63 | ✗ |
| 64 | ✓ |
| 65 | ✗ |
| 66 | ✓ |
| 67 | ✓ |
| 68 | ✗ |
| 69 | ✗ |
| 70 | ✗ |
| 71 | ✗ |
| 72 | ✗ |
| 73 | ✗ |
| 74 | ✗ |
| 75 | ✓ |
| 76 | ✗ |
| 77 | ✗ |

| | |
|---|---|
| 78 | ✗ |
| 79 | ✗ |
| 80 | ✗ |
| 81 | ✗ |
| 82 | ✓ |

All contents of this site are © 2024 Passmedicine Limited

A 32-year-old man attends his GP with pruritus of the genital area. Additionally, he reports painful intercourse with his long-term partner. Examination reveals a whitish scarred meatus with a white plaque on phimotic foreskin.

What is the most likely diagnosis?

- Candidiasis
- Vitiligo
- Lichen planus
- Lichen sclerosus
- Erythroplasia of Queyrat

Submit answer

Reference ranges

Score: **28%**

| | |
|---|---|
| 1 | ✗ |
| 2 | ✓ |
| 3 | ✓ |
| 4 | ✗ |
| 5 | ✗ |
| 6 | ✗ |
| 7 | ✗ |
| 8 | ✗ |
| 9 | ✗ |

| | |
|---|---|
| 10 | ✗ |
| 11 | ✗ |
| 12 | ✗ |
| 13 | ✓ |
| 14 | ✓ |
| 15 | ✓ |
| 16 | ✗ |
| 17 | ✓ |
| 18 | ✓ |
| 19 | ✗ |
| 20 | ✗ |
| 21 | ✗ |
| 22 | ✗ |
| 23 | ✗ |
| 24 | ✓ |
| 25 | ✗ |
| 26 | ✓ |
| 27 | ✗ |
| 28 | ✗ |
| 29 | ✗ |
| 30 | ✓ |
| 31 | ✗ |
| 32 | ✗ |
| 33 | ✗ |
| 34 | ✗ |
| 35 | ✓ |
| 36 | ✗ |
| 37 | ✗ |
| 38 | ✗ |
| 39 | ✗ |
| 40 | ✗ |
| 41 | ✗ |
| 42 | ✓ |
| 43 | ✗ |
| 44 | ✗ |
| 45 | ✓ |

| | |
|---|---|
| 46 | ✓ |
| 47 | ✗ |
| 48 | ✗ |
| 49 | ✗ |
| 50 | ✗ |
| 51 | - |
| 52 | - |
| **53** | - |

All contents of this site are © 2024 Passmedicine Limited

A 32-year-old man attends his GP with pruritus of the genital area. Additionally, he reports painful intercourse with his long-term partner. Examination reveals a whitish scarred meatus with a white plaque on phimotic foreskin.

What is the most likely diagnosis?

| | |
|---|---|
| Candidiasis | 16% |
| Vitiligo | 0% |
| Lichen planus | 12% |
| Lichen sclerosus | 63% |
| Erythroplasia of Queyrat | 8% |

Candidiasis will typically cause erythema on the meatus and discharge.

Vitiligo would not be expected to cause painful intercourse or result in phimosis.

Penile lichen planus usually presents with purple papules in a ring around the glans. Comparatively, lichen sclerosus usually affects the glans and foreskin, resulting in white papules or plaques. It can cause phimosis.

Erythroplasia of Queyrat, also known as an in-situ squamous cell carcinoma of the penis, is a penile intraepithelial neoplasia. It typically occurs in men above 50 years of age, with symptoms including erythema, pain, bleeding and ulcers.

Discuss (2) Improve

Next question

## Lichen sclerosus

Lichen sclerosus was previously termed lichen sclerosus et atrophicus. It is an inflammatory condition that usually affects the genitalia and is more common in elderly females. Lichen sclerosus leads to atrophy of the epidermis with white plaques forming

Features

- white patches that may scar
- itch is prominent
- may result in pain during intercourse or urination

The diagnosis is usually made on clinical grounds but a biopsy may be performed if atypical features are present*

Management

- topical steroids and emollients

Follow-up:

- increased risk of vulval cancer

*the RCOG advise the following

> *Skin biopsy is not necessary when a diagnosis can be made on clinical examination. Biopsy is required if the woman fails to respond to treatment or there is clinical suspicion of VIN or cancer.*

and the British Association of Dermatologists state the following:

> *A confirmatory biopsy, although ideal, is not always practical, particularly in children. It is not always essential when the clinical features are typical. However, histological examination is advisable if there are atypical features or diagnostic uncertainty and is mandatory if there is any suspicion of neoplastic*
> *change. Patients under routine follow-up will need a biopsy if:*
>
> - *(i) there is a suspicion of neoplastic change, i.e. a persistent area of hyperkeratosis, erosion or erythema, or new warty or papular lesions;*

- *(ii) the disease fails to respond to adequate treatment;*
- *(iii) there is extragenital LS, with features suggesting an overlap with morphoea;*
- *(iv) there are pigmented areas, in order to exclude an abnormal melanocytic proliferation; and*
- *(v) second-line therapy is to be used.*

+ Q 123

Next question >

## Textbooks

High-yield textbook

Extended textbook

## Links

DermNet NZ 6 7

Lichen sclerosus

British Association for Sexual Health and HIV 4 5

2014 UK National Guideline on the Management of Vulval Conditions

British Association of Dermatologists 5 2

2018 Lichen sclerosus guidelines

Suggest link Report broken link

Score: **25.6%**

| | |
|---|---|
| 1 | ✗ |
| 2 | ✓ |
| 3 | ✓ |
| 4 | ✗ |
| 5 | ✗ |
| 6 | ✗ |
| 7 | ✗ |
| 8 | ✗ |
| 9 | ✗ |
| 10 | ✗ |
| 11 | ✗ |
| 12 | ✗ |
| 13 | ✓ |
| 14 | ✓ |
| 15 | ✓ |
| 16 | ✗ |
| 17 | ✓ |
| 18 | ✓ |
| 19 | ✗ |
| 20 | ✗ |
| 21 | ✗ |
| 22 | ✗ |
| 23 | ✗ |
| 24 | ✓ |
| 25 | ✗ |
| 26 | ✓ |
| 27 | ✗ |
| 28 | ✗ |
| 29 | ✗ |
| 30 | ✓ |
| 31 | ✗ |
| 32 | ✗ |

| | |
|---|---|
| 33 | ✗ |
| 34 | ✗ |
| 35 | ✓ |
| 36 | ✗ |
| 37 | ✗ |
| 38 | ✗ |
| 39 | ✗ |
| 40 | ✗ |
| 41 | ✗ |
| 42 | ✓ |
| 43 | ✗ |
| 44 | ✗ |
| 45 | ✓ |
| 46 | ✓ |
| 47 | ✗ |
| 48 | ✗ |
| 49 | ✗ |
| 50 | ✗ |
| 51 | ✗ |
| 52 | ✗ |
| **53** | ✓ |
| 54 | ✗ |
| 55 | ✗ |
| 56 | ✗ |
| 57 | ✗ |
| 58 | ✗ |
| 59 | ✗ |
| 60 | ✗ |
| 61 | ✗ |
| 62 | ✓ |
| 63 | ✗ |
| 64 | ✓ |
| 65 | ✗ |
| 66 | ✓ |
| 67 | ✓ |
| 68 | ✗ |

| | |
|---|---|
| 69 | ✗ |
| 70 | ✗ |
| 71 | ✗ |
| 72 | ✗ |
| 73 | ✗ |
| 74 | ✗ |
| 75 | ✓ |
| 76 | ✗ |
| 77 | ✗ |
| 78 | ✗ |
| 79 | ✗ |
| 80 | ✗ |
| 81 | ✗ |
| 82 | ✓ |

All contents of this site are © 2024 Passmedicine Limited

A 21-year-old man presents to the dermatology clinic with a 10-day history of a widespread rash over his torso, neck and upper limbs. He reports that the rash developed during a backpacking holiday in South East Asia. There is no history of fever, pain or itch and other than a mild gastrointestinal illness whilst abroad, has been well in himself. He thinks he may have had a similar rash before last summer on a family holiday to Portugal.

His rash is examined, as shown below:

© Image used on license from DermNet NZ

What is the most likely diagnosis?

- Guttate psoriasis
- Pityriasis rosea
- Pityriasis versicolor
- Tinea corporis
- Urticaria

Submit answer

Reference ranges

Score: **28%**

| | |
|---|---|
| 1 | ✗ |
| 2 | ✓ |
| 3 | ✓ |
| 4 | ✗ |
| 5 | ✗ |
| 6 | ✗ |
| 7 | ✗ |
| 8 | ✗ |
| 9 | ✗ |
| 10 | ✗ |
| 11 | ✗ |
| 12 | ✗ |
| 13 | ✓ |
| 14 | ✓ |
| 15 | ✓ |
| 16 | ✗ |
| 17 | ✓ |
| 18 | ✓ |
| 19 | ✗ |
| 20 | ✗ |
| 21 | ✗ |
| 22 | ✗ |
| 23 | ✗ |
| 24 | ✓ |
| 25 | ✗ |
| 26 | ✓ |
| 27 | ✗ |
| 28 | ✗ |
| 29 | ✗ |
| 30 | ✓ |

| | |
|---|---|
| 31 | ✗ |
| 32 | ✗ |
| 33 | ✗ |
| 34 | ✗ |
| 35 | ✓ |
| 36 | ✗ |
| 37 | ✗ |
| 38 | ✗ |
| 39 | ✗ |
| 40 | ✗ |
| 41 | ✗ |
| 42 | ✓ |
| 43 | ✗ |
| 44 | ✗ |
| 45 | ✓ |
| 46 | ✓ |
| 47 | ✗ |
| 48 | ✗ |
| 49 | ✗ |
| 50 | ✗ |
| 51 | - |
| 52 | - |
| 53 | - |
| **54** | - |

All contents of this site are © 2024 Passmedicine Limited

Back to top

A 21-year-old man presents to the dermatology clinic with a 10-day history of a widespread rash over his torso, neck and upper limbs. He reports that the rash developed during a backpacking holiday in South East Asia. There is no history of fever, pain or itch and other than a mild gastrointestinal illness whilst abroad, has been well in himself. He thinks he may have had a similar rash before last summer on a family holiday to Portugal.

His rash is examined, as shown below:

© Image used on license from DermNet NZ

What is the most likely diagnosis?

| | |
|---|---|
| Guttate psoriasis | 7% |
| Pityriasis rosea | 19% |
| Pityriasis versicolor | 66% |
| Tinea corporis | 7% |
| Urticaria | 1% |

This patient has a diffuse hyperpigmented rash consisting of multiple round lesions mostly over the trunk. This is consistent with the diagnosis of **pityriasis versicolor**, a superficial cutaneous fungal infection caused by *Malassezia furfur*. The patches can vary in colour from pink, brown to pale (typically paler than the surrounding skin) and therefore explains the name 'versicolor'. The upper limbs and neck are also commonly affected. The rash is usually asymptomatic but can

occasionally be itchy. Heat and moisture are risk factors for developing the rash, and the exposure to the heat seems to coincide with this patient's rash.

**Guttate psoriasis** is incorrect. Guttate psoriasis is a subtype of psoriasis that typically affects children and young adults following infection with *Streptococcus sp.*. The rash presents acutely with multiple small scaly and erythematous patches of skin appearing over the trunk and limbs.

**Pityriasis rosea** is incorrect. Pityriasis rosea is a self-limiting rash, characterised by a large round 'herald patch', usually found on the chest, abdomen, or back. It mostly affects children and young adults and is thought to be precipitated by bacterial and viral infections (e.g. human herpes virus 6 and 7).

**Tinea corporis** is incorrect. Tinea corporis is a superficial fungal infection of the skin that can affect any part of the body. However, the infection often spares the hands, feet, scalp, face and groin. The lesions associated with tinea corporis are characteristic ring-shaped lesions that are not seen here.

**Urticaria** is incorrect. Urticaria presents as an erythematous, raised rash that is often described as being intensely itchy. This is not in keeping with this patient's presentation.

Discuss Improve

Next question

## Pityriasis versicolor

Pityriasis versicolor, also called tinea versicolor, is a superficial cutaneous fungal infection caused by *Malassezia furfur* (formerly termed *Pityrosporum ovale*)

Features
- most commonly affects trunk
- patches may be hypopigmented, pink or brown (hence versicolor). May be more noticeable following a suntan
- scale is common
- mild pruritus

Predisposing factors

- occurs in healthy individuals
- immunosuppression
- malnutrition
- Cushing's

Management

- topical antifungal. NICE advises ketoconazole shampoo as this is more cost effective for large areas
- if failure to respond to topical treatment then consider alternative diagnoses (e.g. send scrapings to confirm the diagnosis) + oral itraconazole

AI + Q 123

Next question >

## Textbooks

High-yield textbook

Extended textbook

## Links

Clinical Knowledge Summaries 12 8

Pityriasis versicolor guidelines

DermNet NZ 19 0

Pityriasis versicolor

Suggest link Report broken link

Score: **25.6%**

| | |
|---|---|
| 1 | ✗ |
| 2 | ✓ |
| 3 | ✓ |
| 4 | ✗ |
| 5 | ✗ |
| 6 | ✗ |
| 7 | ✗ |
| 8 | ✗ |
| 9 | ✗ |
| 10 | ✗ |
| 11 | ✗ |
| 12 | ✗ |
| 13 | ✓ |
| 14 | ✓ |
| 15 | ✓ |
| 16 | ✗ |
| 17 | ✓ |
| 18 | ✓ |
| 19 | ✗ |
| 20 | ✗ |
| 21 | ✗ |
| 22 | ✗ |
| 23 | ✗ |
| 24 | ✓ |
| 25 | ✗ |
| 26 | ✓ |
| 27 | ✗ |
| 28 | ✗ |
| 29 | ✗ |

| | |
|---|---|
| 30 | ✓ |
| 31 | ✗ |
| 32 | ✗ |
| 33 | ✗ |
| 34 | ✗ |
| 35 | ✓ |
| 36 | ✗ |
| 37 | ✗ |
| 38 | ✗ |
| 39 | ✗ |
| 40 | ✗ |
| 41 | ✗ |
| 42 | ✓ |
| 43 | ✗ |
| 44 | ✗ |
| 45 | ✓ |
| 46 | ✓ |
| 47 | ✗ |
| 48 | ✗ |
| 49 | ✗ |
| 50 | ✗ |
| 51 | ✗ |
| 52 | ✗ |
| 53 | ✓ |
| **54** | ✗ |
| 55 | ✗ |
| 56 | ✗ |
| 57 | ✗ |
| 58 | ✗ |
| 59 | ✗ |
| 60 | ✗ |
| 61 | ✗ |
| 62 | ✓ |
| 63 | ✗ |
| 64 | ✓ |
| 65 | ✗ |

| | |
|---|---|
| 66 | ✓ |
| 67 | ✓ |
| 68 | ✗ |
| 69 | ✗ |
| 70 | ✗ |
| 71 | ✗ |
| 72 | ✗ |
| 73 | ✗ |
| 74 | ✗ |
| 75 | ✓ |
| 76 | ✗ |
| 77 | ✗ |
| 78 | ✗ |
| 79 | ✗ |
| 80 | ✗ |
| 81 | ✗ |
| 82 | ✓ |

All contents of this site are © 2024 Passmedicine Limited

Back to top

A 55-year-old man develops a rash two days after starting a new medication. The rash is mildly pruritic and mainly affects the arms, torso and neck. The palms of his hand are shown below:

© Image used on license from DermNet NZ

Which one of the following drugs is most likely to have been started?

- Levetiracetam
- Olanzapine
- Carbamazepine
- Fluoxetine
- Diazepam

Submit answer

Reference ranges

Score: **28%**

| | |
|---|---|
| 1 | ✗ |
| 2 | ✓ |
| 3 | ✓ |
| 4 | ✗ |
| 5 | ✗ |
| 6 | ✗ |
| 7 | ✗ |
| 8 | ✗ |
| 9 | ✗ |
| 10 | ✗ |
| 11 | ✗ |
| 12 | ✗ |
| 13 | ✓ |
| 14 | ✓ |
| 15 | ✓ |
| 16 | ✗ |
| 17 | ✓ |
| 18 | ✓ |
| 19 | ✗ |
| 20 | ✗ |
| 21 | ✗ |
| 22 | ✗ |
| 23 | ✗ |
| 24 | ✓ |
| 25 | ✗ |
| 26 | ✓ |
| 27 | ✗ |
| 28 | ✗ |
| 29 | ✗ |
| 30 | ✓ |
| 31 | ✗ |
| 32 | ✗ |
| 33 | ✗ |

| | |
|---|---|
| 34 | ✗ |
| 35 | ✓ |
| 36 | ✗ |
| 37 | ✗ |
| 38 | ✗ |
| 39 | ✗ |
| 40 | ✗ |
| 41 | ✗ |
| 42 | ✓ |
| 43 | ✗ |
| 44 | ✗ |
| 45 | ✓ |
| 46 | ✓ |
| 47 | ✗ |
| 48 | ✗ |
| 49 | ✗ |
| 50 | ✗ |
| 51 | - |
| 52 | - |
| 53 | - |
| 54 | - |
| **55** | - |

All contents of this site are © 2024 Passmedicine Limited

Back to top

A 55-year-old man develops a rash two days after starting a new medication. The rash is mildly pruritic and mainly affects the arms, torso and neck. The palms of his hand are shown below:

© Image used on license from DermNet NZ

Which one of the following drugs is most likely to have been started?

| | |
|---|---|
| Levetiracetam | 11% |
| Olanzapine | 4% |
| Carbamazepine | 82% |
| Fluoxetine | 4% |
| Diazepam | 0% |

This patient has developed erythema multiforme which is a known complication of carbamazepine use.

Discuss (2) | Improve

Next question

# Erythema multiforme

Erythema multiforme is a hypersensitivity reaction that is most commonly triggered by infections. It may be divided into minor and major forms.

Previously it was thought that Stevens-Johnson syndrome (SJS) was a severe form of erythema multiforme. They are now however considered as separate entities.

Features

- target lesions
- initially seen on the back of the hands / feet before spreading to the torso
- upper limbs are more commonly affected than the lower limbs
- pruritus is occasionally seen and is usually mild

Causes

- viruses: herpes simplex virus (the most common cause), Orf*
- idiopathic
- bacteria: *Mycoplasma*, *Streptococcus*
- drugs: penicillin, sulphonamides, carbamazepine, allopurinol, NSAIDs, oral contraceptive pill, nevirapine
- connective tissue disease e.g. Systemic lupus erythematosus
- sarcoidosis
- malignancy

## Erythema multiforme major

The more severe form, erythema multiforme major is associated with mucosal involvement.

*Orf is a skin disease of sheep and goats caused by a parapox virus

123

Next question

## Textbooks

High-yield textbook

Extended textbook

## Links

DermNet NZ 18 10

Erythema multiforme

Suggest link Report broken link

## Media

Erythema multiforme

Osmosis - YouTube 👍 1 👎 0

Report broken media

Score: **25.6%**

| | |
|---|---|
| 1 | ✗ |
| 2 | ✓ |
| 3 | ✓ |
| 4 | ✗ |
| 5 | ✗ |
| 6 | ✗ |
| 7 | ✗ |
| 8 | ✗ |
| 9 | ✗ |
| 10 | ✗ |
| 11 | ✗ |
| 12 | ✗ |
| 13 | ✓ |
| 14 | ✓ |
| 15 | ✓ |
| 16 | ✗ |
| 17 | ✓ |
| 18 | ✓ |
| 19 | ✗ |
| 20 | ✗ |
| 21 | ✗ |
| 22 | ✗ |
| 23 | ✗ |

| | |
|---|---|
| 24 | ✓ |
| 25 | ✗ |
| 26 | ✓ |
| 27 | ✗ |
| 28 | ✗ |
| 29 | ✗ |
| 30 | ✓ |
| 31 | ✗ |
| 32 | ✗ |
| 33 | ✗ |
| 34 | ✗ |
| 35 | ✓ |
| 36 | ✗ |
| 37 | ✗ |
| 38 | ✗ |
| 39 | ✗ |
| 40 | ✗ |
| 41 | ✗ |
| 42 | ✓ |
| 43 | ✗ |
| 44 | ✗ |
| 45 | ✓ |
| 46 | ✓ |
| 47 | ✗ |
| 48 | ✗ |
| 49 | ✗ |
| 50 | ✗ |
| 51 | ✗ |
| 52 | ✗ |
| 53 | ✓ |
| 54 | ✗ |
| **55** | ✗ |
| 56 | ✗ |
| 57 | ✗ |
| 58 | ✗ |
| 59 | ✗ |

| | |
|---|---|
| 60 | ✗ |
| 61 | ✗ |
| 62 | ✓ |
| 63 | ✗ |
| 64 | ✓ |
| 65 | ✗ |
| 66 | ✓ |
| 67 | ✓ |
| 68 | ✗ |
| 69 | ✗ |
| 70 | ✗ |
| 71 | ✗ |
| 72 | ✗ |
| 73 | ✗ |
| 74 | ✗ |
| 75 | ✓ |
| 76 | ✗ |
| 77 | ✗ |
| 78 | ✗ |
| 79 | ✗ |
| 80 | ✗ |
| 81 | ✗ |
| 82 | ✓ |

All contents of this site are © 2024 Passmedicine Limited

Back to top

An 8-year-old boy presents with his mother, who is concerned about a rash that has developed on her son's torso. It has gradually developed over the past few weeks. He is otherwise healthy and well, with no significant medical history, nor family history.

On examination, the rash appears as shown below:

© Image used on license from DermNet NZ

Given the likely diagnosis, what is the most appropriate management?

- Cryotherapy
- Piercing
- Reassurance

- Topical fusidic acid ×
- Topical hydrocortisone ×

Submit answer

Reference ranges

Score: **28%**

| | |
|---|---|
| 1 | ✗ |
| 2 | ✓ |
| 3 | ✓ |
| 4 | ✗ |
| 5 | ✗ |
| 6 | ✗ |
| 7 | ✗ |
| 8 | ✗ |
| 9 | ✗ |
| 10 | ✗ |
| 11 | ✗ |
| 12 | ✗ |
| 13 | ✓ |
| 14 | ✓ |
| 15 | ✓ |
| 16 | ✗ |
| 17 | ✓ |
| 18 | ✓ |
| 19 | ✗ |
| 20 | ✗ |
| 21 | ✗ |
| 22 | ✗ |
| 23 | ✗ |

| | |
|---|---|
| 24 | ✓ |
| 25 | ✗ |
| 26 | ✓ |
| 27 | ✗ |
| 28 | ✗ |
| 29 | ✗ |
| 30 | ✓ |
| 31 | ✗ |
| 32 | ✗ |
| 33 | ✗ |
| 34 | ✗ |
| 35 | ✓ |
| 36 | ✗ |
| 37 | ✗ |
| 38 | ✗ |
| 39 | ✗ |
| 40 | ✗ |
| 41 | ✗ |
| 42 | ✓ |
| 43 | ✗ |
| 44 | ✗ |
| 45 | ✓ |
| 46 | ✓ |
| 47 | ✗ |
| 48 | ✗ |
| 49 | ✗ |
| 50 | ✗ |
| 51 | - |
| 52 | - |
| 53 | - |
| 54 | - |
| 55 | - |
| **56** | - |

All contents of this site are © 2024 Passmedicine Limited
Back to top

An 8-year-old boy presents with his mother, who is concerned about a rash that has developed on her son's torso. It has gradually developed over the past few weeks. He is otherwise healthy and well, with no significant medical history, nor family history.

On examination, the rash appears as shown below:

© Image used on license from DermNet NZ

Given the likely diagnosis, what is the most appropriate management?

| | |
|---|---|
| Cryotherapy | 17% |
| Piercing | 3% |
| Reassurance | 71% |

Topical fusidic acid 8%

Topical hydrocortisone 2%

The image above depicts molluscum contagiosum in a child. The clustered lesions have the typical appearance of pearly papules with umbilicated centres. This is an incredibly common infection that is highly contagious and often spreads between children in close contact. The mother should be reassured that it is a self-limiting condition, and symptoms usually resolve within 18 months - and so reassurance is the most appropriate option.

Cryotherapy may be an option used in older children or adults, if lesions are concerning, for instance catching on clothing or in a cosmetically sensitive place. However, this is a young child, and the lesions and described as being limited to the torso.

Piercing with an orange stick, or squeezing with fingernails, may be tried following a bath. This should, however, be limited to a few lesions at one time. This is not generally recommended if lesions are not problematic - in a straightforward case such as this, reassurance should be given and the lesions left alone.

Topical fusidic acid would be used if there were any signs of secondary infection - oedema, erythema, or crusting. The photo above does not demonstrate any of these signs and so an antibiotic is not necessary.

If there are any signs of inflammation, or any itching, a mild topical steroid such as hydrocortisone may be used. Again, in this photo, the lesions do not appear inflamed, nor is any description given of problematic itching.

Discuss (1) Improve

Next question ›

## Molluscum contagiosum

Molluscum contagiosum is a common skin infection caused by molluscum contagiosum virus (MCV), a member of the Poxviridae family. Transmission occurs directly by close personal contact, or indirectly via fomites (contaminated surfaces) such as shared towels and flannels. The majority of cases occur in children (often in children with atopic eczema), with the maximum incidence in preschool children aged 1-4 years.

Typically, molluscum contagiosum presents with characteristic pinkish or pearly white papules with

a central umbilication, which are up to 5 mm in diameter. Lesions appear in clusters in areas anywhere on the body (except the palms of the hands and the soles of the feet). In children, lesions are commonly seen on the trunk and in flexures, but anogenital lesions may also occur. In adults, sexual contact may lead to lesions developing on the genitalia, pubis, thighs, and lower abdomen. Rarely, lesions can occur on the oral mucosa and on the eyelids.

Self-care advice:

- Reassure people that molluscum contagiosum is a self-limiting condition.
- Spontaneous resolution usually occurs within 18 months
- Explain that lesions are contagious, and it is sensible to avoid sharing towels, clothing, and baths with uninfected people (e.g. siblings)
- Encourage people not to scratch the lesions. If it is problematic, consider treatment to alleviate the itch
- Exclusion from school, gym, or swimming is not necessary

Treatment is not usually recommended. If lesions are troublesome or considered unsightly, use simple trauma or cryotherapy, depending on the parents' wishes and the child's age:

- Squeezing (with fingernails) or piercing (orange stick) lesions may be tried, following a bath. Treatment should be limited to a few lesions at one time
- Cryotherapy may be used in older children or adults, if the healthcare professional is experienced in the procedure
- Eczema or inflammation can develop around lesions prior to resolution. Treatment may be required if:
    - Itching is problematic; prescribe an emollient and a mild topical corticosteroid (e.g. hydrocortisone 1%)
    - The skin looks infected (e.g. oedema, crusting); prescribe a topical antibiotic (e.g. fusidic acid 2%)

Referral may be necessary in some circumstances:

- For people who are HIV-positive with extensive lesions urgent referral to a HIV specialist
- For people with eyelid-margin or ocular lesions and associated red eye urgent referral to an ophthalmologist
- Adults with anogenital lesions should be referred to genito-urinary medicine, for screening for other sexually transmitted infections

123

Next question

## Textbooks

High-yield textbook

Extended textbook

## Links

DermNet NZ 12 4

Molluscum contagiosum

Suggest link

Report broken link

Score: **25.6%**

| | |
|---|---|
| 1 | ✗ |
| 2 | ✓ |
| 3 | ✓ |
| 4 | ✗ |
| 5 | ✗ |
| 6 | ✗ |
| 7 | ✗ |
| 8 | ✗ |

| | |
|---|---|
| 9 | ✗ |
| 10 | ✗ |
| 11 | ✗ |
| 12 | ✗ |
| 13 | ✓ |
| 14 | ✓ |
| 15 | ✓ |
| 16 | ✗ |
| 17 | ✓ |
| 18 | ✓ |
| 19 | ✗ |
| 20 | ✗ |
| 21 | ✗ |
| 22 | ✗ |
| 23 | ✗ |
| 24 | ✓ |
| 25 | ✗ |
| 26 | ✓ |
| 27 | ✗ |
| 28 | ✗ |
| 29 | ✗ |
| 30 | ✓ |
| 31 | ✗ |
| 32 | ✗ |
| 33 | ✗ |
| 34 | ✗ |
| 35 | ✓ |
| 36 | ✗ |
| 37 | ✗ |
| 38 | ✗ |
| 39 | ✗ |
| 40 | ✗ |
| 41 | ✗ |
| 42 | ✓ |
| 43 | ✗ |
| 44 | ✗ |

| | |
|---|---|
| 45 | ✓ |
| 46 | ✓ |
| 47 | ✗ |
| 48 | ✗ |
| 49 | ✗ |
| 50 | ✗ |
| 51 | ✗ |
| 52 | ✗ |
| 53 | ✓ |
| 54 | ✗ |
| 55 | ✗ |
| **56** | ✗ |
| 57 | ✗ |
| 58 | ✗ |
| 59 | ✗ |
| 60 | ✗ |
| 61 | ✗ |
| 62 | ✓ |
| 63 | ✗ |
| 64 | ✓ |
| 65 | ✗ |
| 66 | ✓ |
| 67 | ✓ |
| 68 | ✗ |
| 69 | ✗ |
| 70 | ✗ |
| 71 | ✗ |
| 72 | ✗ |
| 73 | ✗ |
| 74 | ✗ |
| 75 | ✓ |
| 76 | ✗ |
| 77 | ✗ |
| 78 | ✗ |
| 79 | ✗ |
| 80 | ✗ |

81 ✗

82 ✓

All contents of this site are © 2024 Passmedicine Limited

Please look at the skin lesion shown below:

© Image used on license from DermNet NZ

What is the most likely diagnosis?

- Infected chalazion
- Actinic keratosis
- Indurated dacryocystitis
- Keratoacanthoma
- Basal cell carcinoma

Submit answer

Reference ranges

Score: **28%**

| | |
|---|---|
| 1 | ✗ |
| 2 | ✓ |
| 3 | ✓ |
| 4 | ✗ |
| 5 | ✗ |
| 6 | ✗ |
| 7 | ✗ |
| 8 | ✗ |
| 9 | ✗ |
| 10 | ✗ |
| 11 | ✗ |
| 12 | ✗ |
| 13 | ✓ |
| 14 | ✓ |
| 15 | ✓ |
| 16 | ✗ |
| 17 | ✓ |
| 18 | ✓ |
| 19 | ✗ |
| 20 | ✗ |
| 21 | ✗ |
| 22 | ✗ |
| 23 | ✗ |
| 24 | ✓ |
| 25 | ✗ |
| 26 | ✓ |
| 27 | ✗ |
| 28 | ✗ |
| 29 | ✗ |
| 30 | ✓ |
| 31 | ✗ |
| 32 | ✗ |
| 33 | ✗ |
| 34 | ✗ |

| | |
|---|---|
| 35 | ✓ |
| 36 | ✗ |
| 37 | ✗ |
| 38 | ✗ |
| 39 | ✗ |
| 40 | ✗ |
| 41 | ✗ |
| 42 | ✓ |
| 43 | ✗ |
| 44 | ✗ |
| 45 | ✓ |
| 46 | ✓ |
| 47 | ✗ |
| 48 | ✗ |
| 49 | ✗ |
| 50 | ✗ |
| 51 | - |
| 52 | - |
| 53 | - |
| 54 | - |
| 55 | - |
| 56 | - |
| **57** | - |

All contents of this site are © 2024 Passmedicine Limited

Back to top

Please look at the skin lesion shown below:

© Image used on license from DermNet NZ

What is the most likely diagnosis?

| | |
|---|---|
| Infected chalazion | 1% |
| Actinic keratosis | 1% |
| Indurated dacryocystitis | 4% |
| Keratoacanthoma | 4% |
| Basal cell carcinoma | 90% |

Discuss Improve

Next question

## Basal cell carcinoma

Basal cell carcinoma (BCC) is one of the three main types of skin cancer. Lesions are also known as rodent ulcers and are characterised by slow-growth and local invasion. Metastases are extremely rare. BCC is the most common type of cancer in the Western world.

Features

- many types of BCC are described. The most common type is nodular BCC, which is described here
- sun-exposed sites, especially the head and neck account for the majority of lesions
- initially a pearly, flesh-coloured papule with telangiectasia
- may later ulcerate leaving a central 'crater'

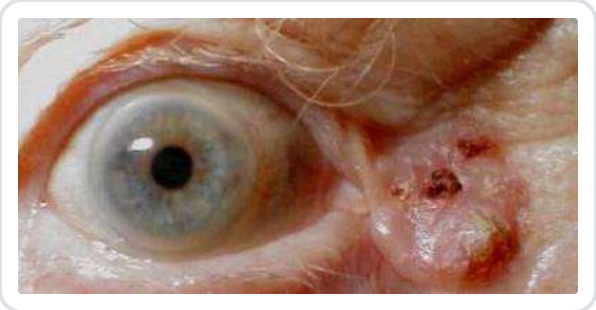

Referral

- generally, if a BCC is suspected, a routine referral should be made

Management options:

- surgical removal
- curettage
- cryotherapy
- topical cream: imiquimod, fluorouracil
- radiotherapy

123

Next question

## Textbooks

High-yield textbook

Extended textbook

## Links

DermNet NZ 21 7

Basal cell carcinoma

Suggest link Report broken link

## Media

Skin cancers

Osmosis - YouTube 4 2

Report broken media

Score: **25.6%**

1 ✗
2 ✓
3 ✓
4 ✗
5 ✗

| | |
|---|---|
| 6 | ✗ |
| 7 | ✗ |
| 8 | ✗ |
| 9 | ✗ |
| 10 | ✗ |
| 11 | ✗ |
| 12 | ✗ |
| 13 | ✓ |
| 14 | ✓ |
| 15 | ✓ |
| 16 | ✗ |
| 17 | ✓ |
| 18 | ✓ |
| 19 | ✗ |
| 20 | ✗ |
| 21 | ✗ |
| 22 | ✗ |
| 23 | ✗ |
| 24 | ✓ |
| 25 | ✗ |
| 26 | ✓ |
| 27 | ✗ |
| 28 | ✗ |
| 29 | ✗ |
| 30 | ✓ |
| 31 | ✗ |
| 32 | ✗ |
| 33 | ✗ |
| 34 | ✗ |
| 35 | ✓ |
| 36 | ✗ |
| 37 | ✗ |
| 38 | ✗ |
| 39 | ✗ |
| 40 | ✗ |
| 41 | ✗ |

| | |
|---|---|
| 42 | ✓ |
| 43 | ✗ |
| 44 | ✗ |
| 45 | ✓ |
| 46 | ✓ |
| 47 | ✗ |
| 48 | ✗ |
| 49 | ✗ |
| 50 | ✗ |
| 51 | ✗ |
| 52 | ✗ |
| 53 | ✓ |
| 54 | ✗ |
| 55 | ✗ |
| 56 | ✗ |
| **57** | ✗ |
| 58 | ✗ |
| 59 | ✗ |
| 60 | ✗ |
| 61 | ✗ |
| 62 | ✓ |
| 63 | ✗ |
| 64 | ✓ |
| 65 | ✗ |
| 66 | ✓ |
| 67 | ✓ |
| 68 | ✗ |
| 69 | ✗ |
| 70 | ✗ |
| 71 | ✗ |
| 72 | ✗ |
| 73 | ✗ |
| 74 | ✗ |
| 75 | ✓ |
| 76 | ✗ |
| 77 | ✗ |

| | |
|---|---|
| 78 | ✗ |
| 79 | ✗ |
| 80 | ✗ |
| 81 | ✗ |
| 82 | ✓ |

All contents of this site are © 2024 Passmedicine Limited

PassMedicine



A 23-year-old man presents as he is concerned about recent hair loss. Examination reveals the following:

What is the most likely diagnosis?

- Telogen effluvium
- Alopecia areata
- Tinea capitis
- Male-pattern baldness
- Discoid lupus erythematous

Submit answer

Reference ranges

Score: **28%**

| | |
|---|---|
| 1 | ✗ |
| 2 | ✓ |
| 3 | ✓ |
| 4 | ✗ |
| 5 | ✗ |
| 6 | ✗ |
| 7 | ✗ |
| 8 | ✗ |
| 9 | ✗ |
| 10 | ✗ |
| 11 | ✗ |
| 12 | ✗ |
| 13 | ✓ |
| 14 | ✓ |
| 15 | ✓ |
| 16 | ✗ |
| 17 | ✓ |
| 18 | ✓ |
| 19 | ✗ |
| 20 | ✗ |
| 21 | ✗ |
| 22 | ✗ |
| 23 | ✗ |
| 24 | ✓ |
| 25 | ✗ |
| 26 | ✓ |
| 27 | ✗ |
| 28 | ✗ |
| 29 | ✗ |
| 30 | ✓ |
| 31 | ✗ |
| 32 | ✗ |
| 33 | ✗ |
| 34 | ✗ |

| | |
|---|---|
| 35 | ✓ |
| 36 | ✗ |
| 37 | ✗ |
| 38 | ✗ |
| 39 | ✗ |
| 40 | ✗ |
| 41 | ✗ |
| 42 | ✓ |
| 43 | ✗ |
| 44 | ✗ |
| 45 | ✓ |
| 46 | ✓ |
| 47 | ✗ |
| 48 | ✗ |
| 49 | ✗ |
| 50 | ✗ |
| 51 | - |
| 52 | - |
| 53 | - |
| 54 | - |
| 55 | - |
| 56 | - |
| 57 | - |
| **58** | - |

All contents of this site are © 2024 Passmedicine Limited

Back to top

A 23-year-old man presents as he is concerned about recent hair loss. Examination reveals the following:

What is the most likely diagnosis?

| | |
|---|---|
| Telogen effluvium | 4% |
| Alopecia areata | 81% |
| Tinea capitis | 11% |
| Male-pattern baldness | 1% |
| Discoid lupus erythematous | 3% |

Discuss Improve

Next question

## Alopecia areata

Alopecia areata is a presumed autoimmune condition causing localised, well demarcated patches of hair loss. At the edge of the hair loss, there may be small, broken 'exclamation mark' hairs

Hair will regrow in 50% of patients by 1 year, and in 80-90% eventually. Careful explanation is therefore sufficient in many patients. Other treatment options include:
- topical or intralesional corticosteroids
- topical minoxidil
- phototherapy
- dithranol
- contact immunotherapy
- wigs

+ Q 123

Next question

## Textbooks

High-yield textbook

Extended textbook

## Links

British Assocaition of Dermatologists 4 8

Alopecia areata guidelines

Clinical Knowledge Summaries 6 7

Alopecia areata guidelines

Score: **25.6%**

| | |
|---|---|
| 1 | ✗ |
| 2 | ✓ |
| 3 | ✓ |
| 4 | ✗ |
| 5 | ✗ |
| 6 | ✗ |
| 7 | ✗ |
| 8 | ✗ |
| 9 | ✗ |
| 10 | ✗ |
| 11 | ✗ |
| 12 | ✗ |
| 13 | ✓ |
| 14 | ✓ |
| 15 | ✓ |
| 16 | ✗ |
| 17 | ✓ |
| 18 | ✓ |
| 19 | ✗ |
| 20 | ✗ |
| 21 | ✗ |
| 22 | ✗ |
| 23 | ✗ |
| 24 | ✓ |
| 25 | ✗ |
| 26 | ✓ |
| 27 | ✗ |
| 28 | ✗ |
| 29 | ✗ |

| | |
|---|---|
| 30 | ✓ |
| 31 | ✗ |
| 32 | ✗ |
| 33 | ✗ |
| 34 | ✗ |
| 35 | ✓ |
| 36 | ✗ |
| 37 | ✗ |
| 38 | ✗ |
| 39 | ✗ |
| 40 | ✗ |
| 41 | ✗ |
| 42 | ✓ |
| 43 | ✗ |
| 44 | ✗ |
| 45 | ✓ |
| 46 | ✓ |
| 47 | ✗ |
| 48 | ✗ |
| 49 | ✗ |
| 50 | ✗ |
| 51 | ✗ |
| 52 | ✗ |
| 53 | ✓ |
| 54 | ✗ |
| 55 | ✗ |
| 56 | ✗ |
| 57 | ✗ |
| **58** | ✗ |
| 59 | ✗ |
| 60 | ✗ |
| 61 | ✗ |
| 62 | ✓ |
| 63 | ✗ |
| 64 | ✓ |
| 65 | ✗ |

66 ✓
67 ✓
68 ✗
69 ✗
70 ✗
71 ✗
72 ✗
73 ✗
74 ✗
75 ✓
76 ✗
77 ✗
78 ✗
79 ✗
80 ✗
81 ✗
82 ✓

All contents of this site are © 2024 Passmedicine Limited
Back to top

A 73-year-old woman attended dermatology clinic for review of a skin lesion on her right cheek. The patient had recently returned to the United Kingdom having been resident in southern Spain for the previous 20 years. She described the development of a lump just under her right eye over approximately the past six months. She also recalled having a area of slightly dry and sore skin in a similar location prior to the emergence of the lesion, although she had not sought medical attention for this. The patient denied having any symptoms from the lesion, although was very concerned and upset about the unsightly appearance it caused.

The patient's medical history included rheumatoid arthritis, type 2 diabetes mellitus, hypertension and intermittent episodes of gout. She had no previous dermatological condition. Her regular medications were methotrexate 15 mg weekly, metformin 1000 mg twice daily, ramipril 2.5 mg daily and naproxen 500 mg as required. She denied any previous treatments for cancer.

Examination of the patient demonstrated an approximately spherical nodule 11 mm in diameter arising from the patient's cheek 15 mm inferior to her eyelid. Crusting was noted on the surface of the nodule, but there was no hyperkeratosis, induration or ulceration.

A biopsy of the lesion is taken during clinic assessment with histology demonstrating squamous cell carcinoma.

What is the appropriate technique for treatment of the patient's lesion?

- Electrodessiccation
- Wide local excision with 4 mm margin of normal skin
- Mohs micrographic surgery
- Wide local excision with 6 mm margin of normal skin
- Radiotherapy

Submit answer

Reference ranges

Score: **28%**

| | |
|---|---|
| 1 | ✗ |
| 2 | ✓ |
| 3 | ✓ |
| 4 | ✗ |
| 5 | ✗ |
| 6 | ✗ |
| 7 | ✗ |
| 8 | ✗ |
| 9 | ✗ |
| 10 | ✗ |
| 11 | ✗ |
| 12 | ✗ |
| 13 | ✓ |
| 14 | ✓ |
| 15 | ✓ |
| 16 | ✗ |
| 17 | ✓ |
| 18 | ✓ |
| 19 | ✗ |
| 20 | ✗ |
| 21 | ✗ |
| 22 | ✗ |
| 23 | ✗ |
| 24 | ✓ |
| 25 | ✗ |
| 26 | ✓ |
| 27 | ✗ |
| 28 | ✗ |
| 29 | ✗ |
| 30 | ✓ |
| 31 | ✗ |
| 32 | ✗ |
| 33 | ✗ |

| | |
|---|---|
| 34 | ✗ |
| 35 | ✓ |
| 36 | ✗ |
| 37 | ✗ |
| 38 | ✗ |
| 39 | ✗ |
| 40 | ✗ |
| 41 | ✗ |
| 42 | ✓ |
| 43 | ✗ |
| 44 | ✗ |
| 45 | ✓ |
| 46 | ✓ |
| 47 | ✗ |
| 48 | ✗ |
| 49 | ✗ |
| 50 | ✗ |
| 51 | - |
| 52 | - |
| 53 | - |
| 54 | - |
| 55 | - |
| 56 | - |
| 57 | - |
| 58 | - |
| **59** | - |

All contents of this site are © 2024 Passmedicine Limited

Back to top

A 73-year-old woman attended dermatology clinic for review of a skin lesion on her right cheek. The patient had recently returned to the United Kingdom having been resident in southern Spain for the previous 20 years. She described the development of a lump just under her right eye over approximately the past six months. She also recalled having a area of slightly dry and sore skin in a similar location prior to the emergence of the lesion, although she had not sought medical attention for this. The patient denied having any symptoms from the lesion, although was very concerned and upset about the unsightly appearance it caused.

The patient's medical history included rheumatoid arthritis, type 2 diabetes mellitus, hypertension and intermittent episodes of gout. She had no previous dermatological condition. Her regular medications were methotrexate 15 mg weekly, metformin 1000 mg twice daily, ramipril 2.5 mg daily and naproxen 500 mg as required. She denied any previous treatments for cancer.

Examination of the patient demonstrated an approximately spherical nodule 11 mm in diameter arising from the patient's cheek 15 mm inferior to her eyelid. Crusting was noted on the surface of the nodule, but there was no hyperkeratosis, induration or ulceration.

A biopsy of the lesion is taken during clinic assessment with histology demonstrating squamous cell carcinoma.

What is the appropriate technique for treatment of the patient's lesion?

- Electrodessiccation — 1%
- Wide local excision with 4 mm margin of normal skin — 23%
- Mohs micrographic surgery — 64%
- Wide local excision with 6 mm margin of normal skin — 12%
- Radiotherapy — 1%

The patient has a facial cutaneous squamous cell carcinoma in a functionally and cosmetically important region. Her history of immunosuppression with methotrexate could also lead to the tumour being considered high risk, although the increased risk of squamous cell carcinoma is most well characterised in those individuals highly immunosuppressed to prevent transplant rejection.

Mohs micrographic surgery is a specialised technique reserved for use in high risk tumours or those in functionally or cosmetically important areas. The technique involves histological examination of the tumour during the procedure to ensure adequate margins and complete tumour clearance. The technique provides a high cure rate and maximum tissue conservation.

In less sensitive areas of the body, wide local excision is the treatment of choice. Low risk tumours with diameter < 2 mm require margins of 4 mm, with 6 mm margins being required in high-risk or larger tumours.

Radiotherapy is an alternative treatment option for individuals not suitable for surgery but has a higher recurrence rate than surgical excision. Electrodessiccation (curettage and cautery) is occasionally used for low risk cutaneous squamous cell carcinomas on the extremities or trunk.

Aslam A, Patel A. Facial cutaneous squamous cell carcinoma. BMJ 2016;352:i1513.

Discuss (2) Improve

Next question

## Squamous cell carcinoma of the skin

Squamous cell carcinoma is a common variant of skin cancer. Metastases are rare but may occur in 2-5% of patients.

Risk factors include:

- excessive exposure to sunlight / psoralen UVA therapy
- actinic keratoses and Bowen's disease
- immunosuppression e.g. following renal transplant, HIV
- smoking
- long-standing leg ulcers (Marjolin's ulcer)
- genetic conditions e.g. xeroderma pigmentosum, oculocutaneous albinism

Features

- typically on sun-exposed sites such as the head and neck or dorsum of the hands and arms
- rapidly expanding painless, ulcerate nodules
- may have a cauliflower-like appearance
- there may be areas of bleeding

## Image gallery

## Treatment

Surgical excision with 4mm margins if lesion <20mm in diameter. If tumour >20mm then margins should be 6mm. Mohs micrographic surgery may be used in high-risk patients and in cosmetically important sites.

## Prognosis

| Good Prognosis | Poor prognosis |
|---|---|
| Well differentiated tumours | Poorly differentiated tumours |
| <20mm diameter | >20mm in diameter |
| <2mm deep | >4mm deep |
| No associated diseases | Immunosupression for whatever reason |

Next question

## Textbooks

High-yield textbook

Extended textbook

## Links

DermNet NZ 28 4

Squamous cell carcinoma

Suggest link Report broken link

## Media

Skin cancers

Osmosis - YouTube 4 1

Report broken media

Score: **25.6%**

1 ✗
2 ✓
3 ✓
4 ✗
5 ✗
6 ✗
7 ✗
8 ✗
9 ✗

| | |
|---|---|
| 10 | ✗ |
| 11 | ✗ |
| 12 | ✗ |
| 13 | ✓ |
| 14 | ✓ |
| 15 | ✓ |
| 16 | ✗ |
| 17 | ✓ |
| 18 | ✓ |
| 19 | ✗ |
| 20 | ✗ |
| 21 | ✗ |
| 22 | ✗ |
| 23 | ✗ |
| 24 | ✓ |
| 25 | ✗ |
| 26 | ✓ |
| 27 | ✗ |
| 28 | ✗ |
| 29 | ✗ |
| 30 | ✓ |
| 31 | ✗ |
| 32 | ✗ |
| 33 | ✗ |
| 34 | ✗ |
| 35 | ✓ |
| 36 | ✗ |
| 37 | ✗ |
| 38 | ✗ |
| 39 | ✗ |
| 40 | ✗ |
| 41 | ✗ |
| 42 | ✓ |
| 43 | ✗ |
| 44 | ✗ |
| 45 | ✓ |

46 ✓
47 ✗
48 ✗
49 ✗
50 ✗
51 ✗
52 ✗
53 ✓
54 ✗
55 ✗
56 ✗
57 ✗
58 ✗
**59** ✗
60 ✗
61 ✗
62 ✓
63 ✗
64 ✓
65 ✗
66 ✓
67 ✓
68 ✗
69 ✗
70 ✗
71 ✗
72 ✗
73 ✗
74 ✗
75 ✓
76 ✗
77 ✗
78 ✗
79 ✗
80 ✗
81 ✗

82 ✓

All contents of this site are © 2024 Passmedicine Limited

A 67-year-old man presents with a five week history of skin rash. He states that the rash erupted suddenly and progressed over five weeks.

His past medical history includes type 2 diabetes mellitus. He is obese with a BMI of 39kg/m$^2$ and drinks alcohol to excess. An ultrasound scan four years ago confirmed cirrhosis.

On examination, there are over 60 raised, oval lesions with tan pigmentation over his back and chest, ranging from 5mm to 25mm diameter, and have a warty texture and stuck-on appearance.

What would be the most appropriate next step for this patient?

- Cryotherapy
- Curettage
- Full malignancy screen
- Imiquimod
- Reassurance and discharge

Submit answer

Reference ranges

Score: **28%**

1 ✗
2 ✓
3 ✓
4 ✗
5 ✗

| | |
|---|---|
| 6 | ✗ |
| 7 | ✗ |
| 8 | ✗ |
| 9 | ✗ |
| 10 | ✗ |
| 11 | ✗ |
| 12 | ✗ |
| 13 | ✓ |
| 14 | ✓ |
| 15 | ✓ |
| 16 | ✗ |
| 17 | ✓ |
| 18 | ✓ |
| 19 | ✗ |
| 20 | ✗ |
| 21 | ✗ |
| 22 | ✗ |
| 23 | ✗ |
| 24 | ✓ |
| 25 | ✗ |
| 26 | ✓ |
| 27 | ✗ |
| 28 | ✗ |
| 29 | ✗ |
| 30 | ✓ |
| 31 | ✗ |
| 32 | ✗ |
| 33 | ✗ |
| 34 | ✗ |
| 35 | ✓ |
| 36 | ✗ |
| 37 | ✗ |
| 38 | ✗ |
| 39 | ✗ |
| 40 | ✗ |
| 41 | ✗ |

| | |
|---|---|
| 42 | ✓ |
| 43 | ✗ |
| 44 | ✗ |
| 45 | ✓ |
| 46 | ✓ |
| 47 | ✗ |
| 48 | ✗ |
| 49 | ✗ |
| 50 | ✗ |
| 51 | - |
| 52 | - |
| 53 | - |
| 54 | - |
| 55 | - |
| 56 | - |
| 57 | - |
| 58 | - |
| 59 | - |
| **60** | - |

All contents of this site are © 2024 Passmedicine Limited

A 67-year-old man presents with a five week history of skin rash. He states that the rash erupted suddenly and progressed over five weeks.

His past medical history includes type 2 diabetes mellitus. He is obese with a BMI of $39kg/m^2$ and drinks alcohol to excess. An ultrasound scan four years ago confirmed cirrhosis.

On examination, there are over 60 raised, oval lesions with tan pigmentation over his back and chest, ranging from 5mm to 25mm diameter, and have a warty texture and stuck-on appearance.

What would be the most appropriate next step for this patient?

| | |
|---|---|
| Cryotherapy | 5% |
| Curettage | 3% |
| Full malignancy screen | 36% |
| Imiquimod | 12% |
| Reassurance and discharge | 44% |

The abrupt appearance of multiple seborrhoeic keratoses suggests underlying cancer (Leser-Trelat sign)

Important for me Less important

The question gives a classic description of seborrhoeic keratoses.

These lesions are common and are benign although the rapid development of large numbers of them is cause for concern. This is termed the Leser-Trelat sign and is most commonly associated with gastrointestinal adenocarcinomas and hepatic cancers.

**Full malignancy screen**: a full malignancy screen is correct given the development of the Leser-Trelat sign. Bloods including cancer markers as well as endoscopy / further imaging would be recommended to investigate for underlying malignancy.

**Cryotherapy**: cryotherapy and curettage are options for improvement of cosmetic appearance, but seborrhoeic keratoses usually do not require any specific treatment.

**Imiquimod**: Imiquimod is used for actinic keratoses rather than seborrhoeic keratoses.

**Curettage**: is an option for the treatment of seborrhoeic keratoses but with such high numbers would be unsuitable. Also, given the 'Leser-Trelat' sign, this patient requires investigation for underlying malignancy.

**Reassurance and discharge**: this is not appropriate in this case as the Leser-Trelat is associated with malignancy. If there were fewer lesions, or they had developed over a much longer time scale, it may be appropriate to reassure your patient.

Discuss (1) Improve

Next question

## Seborrhoeic keratoses

Seborrhoeic keratoses are benign epidermal skin lesions seen in older people.

Features

- large variation in colour from flesh to light-brown to black
- have a 'stuck-on' appearance
- keratotic plugs may be seen on the surface

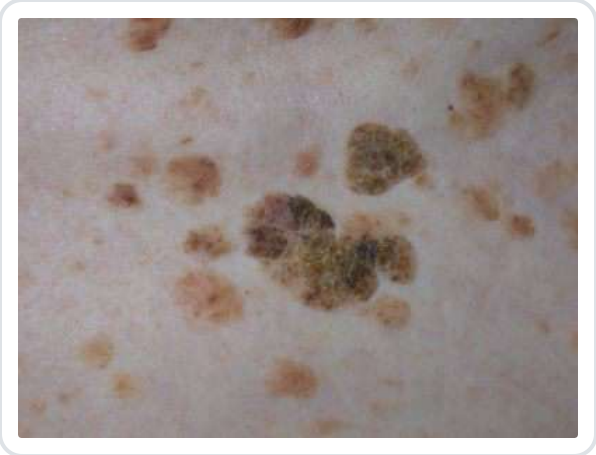

Management

- reassurance about the benign nature of the lesion is an option
- options for removal include curettage, cryosurgery and shave biopsy

123

Next question

## Textbooks

High-yield textbook

Extended textbook

## Links

DermNet NZ 5 5

Seborrhoeic keratoses

Suggest link Report broken link

Score: **25.6%**

1 ✗
2 ✓
3 ✓
4 ✗
5 ✗
6 ✗
7 ✗
8 ✗
9 ✗
10 ✗
11 ✗
12 ✗
13 ✓

| | |
|---|---|
| 14 | ✓ |
| 15 | ✓ |
| 16 | ✗ |
| 17 | ✓ |
| 18 | ✓ |
| 19 | ✗ |
| 20 | ✗ |
| 21 | ✗ |
| 22 | ✗ |
| 23 | ✗ |
| 24 | ✓ |
| 25 | ✗ |
| 26 | ✓ |
| 27 | ✗ |
| 28 | ✗ |
| 29 | ✗ |
| 30 | ✓ |
| 31 | ✗ |
| 32 | ✗ |
| 33 | ✗ |
| 34 | ✗ |
| 35 | ✓ |
| 36 | ✗ |
| 37 | ✗ |
| 38 | ✗ |
| 39 | ✗ |
| 40 | ✗ |
| 41 | ✗ |
| 42 | ✓ |
| 43 | ✗ |
| 44 | ✗ |
| 45 | ✓ |
| 46 | ✓ |
| 47 | ✗ |
| 48 | ✗ |
| 49 | ✗ |

50 ✗
51 ✗
52 ✗
53 ✓
54 ✗
55 ✗
56 ✗
57 ✗
58 ✗
59 ✗
**60** ✗
61 ✗
62 ✓
63 ✗
64 ✓
65 ✗
66 ✓
67 ✓
68 ✗
69 ✗
70 ✗
71 ✗
72 ✗
73 ✗
74 ✗
75 ✓
76 ✗
77 ✗
78 ✗
79 ✗
80 ✗
81 ✗
82 ✓

All contents of this site are © 2024 Passmedicine Limited

A 27-year-old man with a history of depression and coeliac disease presents with an itchy rash on his buttocks:

© Image used on license from DermNet NZ

What is the most likely diagnosis?

- Linear IgA dermatosis
- Neurotic excoriations
- Scabies
- Dermatitis herpetiformis
- SSRI-associated dermatitis

Submit answer

Reference ranges

Score: **28%**

| | |
|---|---|
| 1 | ✗ |
| 2 | ✓ |
| 3 | ✓ |
| 4 | ✗ |
| 5 | ✗ |
| 6 | ✗ |
| 7 | ✗ |
| 8 | ✗ |
| 9 | ✗ |
| 10 | ✗ |
| 11 | ✗ |
| 12 | ✗ |
| 13 | ✓ |
| 14 | ✓ |
| 15 | ✓ |
| 16 | ✗ |
| 17 | ✓ |
| 18 | ✓ |
| 19 | ✗ |
| 20 | ✗ |
| 21 | ✗ |
| 22 | ✗ |
| 23 | ✗ |
| 24 | ✓ |
| 25 | ✗ |
| 26 | ✓ |
| 27 | ✗ |
| 28 | ✗ |
| 29 | ✗ |
| 30 | ✓ |
| 31 | ✗ |
| 32 | ✗ |
| 33 | ✗ |

| | |
|---|---|
| 34 | ✗ |
| 35 | ✓ |
| 36 | ✗ |
| 37 | ✗ |
| 38 | ✗ |
| 39 | ✗ |
| 40 | ✗ |
| 41 | ✗ |
| 42 | ✓ |
| 43 | ✗ |
| 44 | ✗ |
| 45 | ✓ |
| 46 | ✓ |
| 47 | ✗ |
| 48 | ✗ |
| 49 | ✗ |
| 50 | ✗ |
| 51 | - |
| 52 | - |
| 53 | - |
| 54 | - |
| 55 | - |
| 56 | - |
| 57 | - |
| 58 | - |
| 59 | - |
| 60 | - |
| **61** | - |

All contents of this site are © 2024 Passmedicine Limited

Back to top

PassMedicine



A 27-year-old man with a history of depression and coeliac disease presents with an itchy rash on his buttocks:

© Image used on license from DermNet NZ

What is the most likely diagnosis?

| | |
|---|---|
| Linear IgA dermatosis | 5% |
| Neurotic excoriations | 1% |
| Scabies | 3% |
| Dermatitis herpetiformis | 91% |
| SSRI-associated dermatitis | 1% |

The correct answer is **Dermatitis herpetiformis**. Dermatitis herpetiformis is a chronic, intensely pruritic skin disease characterised by grouped erythematous papules, vesicles and bullae. It is associated with coeliac disease, which the patient has a history of. The rash typically involves extensor surfaces such as the buttocks, elbows and knees. The diagnosis can be confirmed by skin biopsy showing granular IgA deposits at the dermo-epidermal junction.

**Linear IgA dermatosis** is an uncommon autoimmune blistering disorder that presents with tense blisters on normal or erythematous skin. It is not specifically linked to coeliac disease and while it can affect any body site, it favours the trunk and lower extremities rather than specifically the buttocks.

**Neurotic excoriations** refer to self-inflicted skin lesions produced by repetitive scratching. They are often seen in patients with psychiatric conditions including depression but tend to be more widespread and do not have the characteristic appearance of dermatitis herpetiformis.

**Scabies** could present with an itching rash on the buttocks, however, scabies tends to cause more generalised itch especially in web spaces of fingers, wrists and ankles. The clinical picture would also usually include burrows or nodules which are not described here.

Lastly, **SSRI-associated dermatitis** refers to skin reactions related to selective serotonin reuptake inhibitors (SSRIs), a class of drugs commonly used in treating depression. While SSRIs can cause various skin reactions including rashes and pruritus, these tend to be more diffuse rather than localised solely on the buttocks as in this case scenario.

Therefore based on the clinical presentation and the patient's history of coeliac disease, Dermatitis herpetiformis represents the most likely diagnosis.

Discuss (1) | Improve

Next question

## Dermatitis herpetiformis

Dermatitis herpetiformis is an autoimmune blistering skin disorder associated with coeliac disease. It is caused by deposition of IgA in the dermis. More than 90% of patients exhibit small bowel biopsy findings consistent with some degree of gluten-sensitive enteropathy.

Features

- itchy, vesicular skin lesions on the extensor surfaces (e.g. elbows, knees, buttocks)

Diagnosis

- skin biopsy: direct immunofluorescence shows deposition of IgA in a granular pattern in the upper dermis

Management

- gluten-free diet
- dapsone

123

Next question

## Textbooks

High-yield textbook

Extended textbook

## Links

DermNet NZ 34 6

Dermatitis herpetiformis

Suggest link

Report broken link

Score: **25.6%**

| | |
|---|---|
| 1 | ✗ |
| 2 | ✓ |
| 3 | ✓ |
| 4 | ✗ |
| 5 | ✗ |
| 6 | ✗ |
| 7 | ✗ |
| 8 | ✗ |
| 9 | ✗ |
| 10 | ✗ |
| 11 | ✗ |
| 12 | ✗ |
| 13 | ✓ |
| 14 | ✓ |
| 15 | ✓ |
| 16 | ✗ |
| 17 | ✓ |
| 18 | ✓ |
| 19 | ✗ |
| 20 | ✗ |
| 21 | ✗ |
| 22 | ✗ |
| 23 | ✗ |
| 24 | ✓ |
| 25 | ✗ |
| 26 | ✓ |
| 27 | ✗ |
| 28 | ✗ |
| 29 | ✗ |
| 30 | ✓ |
| 31 | ✗ |
| 32 | ✗ |

| | |
|---|---|
| 33 | ✗ |
| 34 | ✗ |
| 35 | ✓ |
| 36 | ✗ |
| 37 | ✗ |
| 38 | ✗ |
| 39 | ✗ |
| 40 | ✗ |
| 41 | ✗ |
| 42 | ✓ |
| 43 | ✗ |
| 44 | ✗ |
| 45 | ✓ |
| 46 | ✓ |
| 47 | ✗ |
| 48 | ✗ |
| 49 | ✗ |
| 50 | ✗ |
| 51 | ✗ |
| 52 | ✗ |
| 53 | ✓ |
| 54 | ✗ |
| 55 | ✗ |
| 56 | ✗ |
| 57 | ✗ |
| 58 | ✗ |
| 59 | ✗ |
| 60 | ✗ |
| **61** | ✗ |
| 62 | ✓ |
| 63 | ✗ |
| 64 | ✓ |
| 65 | ✗ |
| 66 | ✓ |
| 67 | ✓ |
| 68 | ✗ |

| | |
|---|---|
| 69 | ✗ |
| 70 | ✗ |
| 71 | ✗ |
| 72 | ✗ |
| 73 | ✗ |
| 74 | ✗ |
| 75 | ✓ |
| 76 | ✗ |
| 77 | ✗ |
| 78 | ✗ |
| 79 | ✗ |
| 80 | ✗ |
| 81 | ✗ |
| 82 | ✓ |

All contents of this site are © 2024 Passmedicine Limited

Back to top

A 68-year-old woman presents with the lesion below on the forehead. She explains that it has been present for several years and slowly growing.

© Image used on license from DermNet NZ

It causes her no symptoms and she is otherwise well in herself. She has no significant past medical history except for hypertension, for which she takes ramipril.

Given the likely diagnosis, what is the most appropriate management?

- Conventional surgery
- Mohs surgery
- Reassurance
- Topical fluorouracil
- Topical imiquimod

Submit answer

Reference ranges

Score: **28%**

| | |
|---|---|
| 1 | ✗ |
| 2 | ✓ |
| 3 | ✓ |
| 4 | ✗ |
| 5 | ✗ |
| 6 | ✗ |
| 7 | ✗ |
| 8 | ✗ |
| 9 | ✗ |
| 10 | ✗ |
| 11 | ✗ |
| 12 | ✗ |
| 13 | ✓ |
| 14 | ✓ |
| 15 | ✓ |
| 16 | ✗ |
| 17 | ✓ |
| 18 | ✓ |
| 19 | ✗ |
| 20 | ✗ |
| 21 | ✗ |
| 22 | ✗ |
| 23 | ✗ |
| 24 | ✓ |
| 25 | ✗ |
| 26 | ✓ |
| 27 | ✗ |
| 28 | ✗ |
| 29 | ✗ |
| 30 | ✓ |
| 31 | ✗ |
| 32 | ✗ |
| 33 | ✗ |

| | |
|---|---|
| 34 | ✗ |
| 35 | ✓ |
| 36 | ✗ |
| 37 | ✗ |
| 38 | ✗ |
| 39 | ✗ |
| 40 | ✗ |
| 41 | ✗ |
| 42 | ✓ |
| 43 | ✗ |
| 44 | ✗ |
| 45 | ✓ |
| 46 | ✓ |
| 47 | ✗ |
| 48 | ✗ |
| 49 | ✗ |
| 50 | ✗ |
| 51 | - |
| 52 | - |
| 53 | - |
| 54 | - |
| 55 | - |
| 56 | - |
| 57 | - |
| 58 | - |
| 59 | - |
| 60 | - |
| 61 | - |
| **62** | - |

All contents of this site are © 2024 Passmedicine Limited

Back to top

A 68-year-old woman presents with the lesion below on the forehead. She explains that it has been present for several years and slowly growing.

© Image used on license from DermNet NZ

It causes her no symptoms and she is otherwise well in herself. She has no significant past medical history except for hypertension, for which she takes ramipril.

Given the likely diagnosis, what is the most appropriate management?

| | |
|---|---|
| Conventional surgery | 4% |
| Mohs surgery | 23% |
| Reassurance | 52% |
| Topical fluorouracil | 16% |
| Topical imiquimod | 5% |

The correct answer is reassurance. This lesion has the characteristic appearance of seborrhoeic keratosis. This is a benign epidermal lesion seen in older people. They vary significantly in appearance - some have a more raised, 'stuck-on' appearance akin to a barnacle stuck on the skin, whereas some appear flat. The one above appears somewhat flatter. The uniformity of its colour and regular, well-demarcated border point toward seborrhoeic keratosis rather than malignant

melanoma. For an asymptomatic patient, only reassurance is needed. If any itch, a topical corticosteroid may be used.

Conventional surgery is unwarranted. This would be used for a malignant lesion such as a melanoma, which would appear more irregular and have patchy colouring.

Mohs surgery is a technique used to remove malignant lesions from cosmetically-sensitive areas such as the face. This is often used for basal cell carcinomas of the face, which would not appear like the photo above - these are typically small, round, protruding lesions with pearly rolled edges and telangiectasia.

Topical fluorouracil may be used in the treatment of squamous cell carcinoma. These present as scaly, crusted, irregular lesions that often ulcerate and grow over weeks to months. For those in situ (known as Bowen's disease), topical treatments such as fluorouracil are a suitable initial option.

Topical imiquimod is an alternative to fluorouracil, also used in the treatment of squamous cell carcinoma in situ. It plays no role in the management of seborrhoeic keratosis, which is the most likely diagnosis given the picture above.

Discuss (3) Improve

Next question

## Seborrhoeic keratoses

Seborrhoeic keratoses are benign epidermal skin lesions seen in older people.

Features
- large variation in colour from flesh to light-brown to black
- have a 'stuck-on' appearance
- keratotic plugs may be seen on the surface

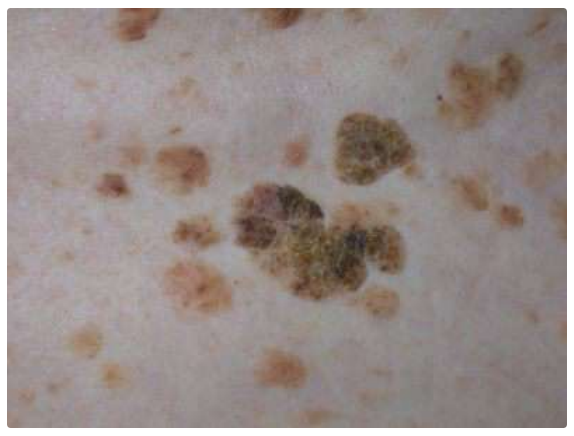

Management
- reassurance about the benign nature of the lesion is an option

- options for removal include curettage, cryosurgery and shave biopsy

123

Next question

## Textbooks

High-yield textbook

Extended textbook

## Links

DermNet NZ 5 5

Seborrhoeic keratoses

Suggest link Report broken link

Score: **25.6%**

| | |
|---|---|
| 1 | ✗ |
| 2 | ✓ |
| 3 | ✓ |
| 4 | ✗ |
| 5 | ✗ |
| 6 | ✗ |
| 7 | ✗ |

| | |
|---|---|
| 8 | ✗ |
| 9 | ✗ |
| 10 | ✗ |
| 11 | ✗ |
| 12 | ✗ |
| 13 | ✓ |
| 14 | ✓ |
| 15 | ✓ |
| 16 | ✗ |
| 17 | ✓ |
| 18 | ✓ |
| 19 | ✗ |
| 20 | ✗ |
| 21 | ✗ |
| 22 | ✗ |
| 23 | ✗ |
| 24 | ✓ |
| 25 | ✗ |
| 26 | ✓ |
| 27 | ✗ |
| 28 | ✗ |
| 29 | ✗ |
| 30 | ✓ |
| 31 | ✗ |
| 32 | ✗ |
| 33 | ✗ |
| 34 | ✗ |
| 35 | ✓ |
| 36 | ✗ |
| 37 | ✗ |
| 38 | ✗ |
| 39 | ✗ |
| 40 | ✗ |
| 41 | ✗ |
| 42 | ✓ |
| 43 | ✗ |

| | |
|---|---|
| 44 | ✗ |
| 45 | ✓ |
| 46 | ✓ |
| 47 | ✗ |
| 48 | ✗ |
| 49 | ✗ |
| 50 | ✗ |
| 51 | ✗ |
| 52 | ✗ |
| 53 | ✓ |
| 54 | ✗ |
| 55 | ✗ |
| 56 | ✗ |
| 57 | ✗ |
| 58 | ✗ |
| 59 | ✗ |
| 60 | ✗ |
| 61 | ✗ |
| **62** | ✓ |
| 63 | ✗ |
| 64 | ✓ |
| 65 | ✗ |
| 66 | ✓ |
| 67 | ✓ |
| 68 | ✗ |
| 69 | ✗ |
| 70 | ✗ |
| 71 | ✗ |
| 72 | ✗ |
| 73 | ✗ |
| 74 | ✗ |
| 75 | ✓ |
| 76 | ✗ |
| 77 | ✗ |
| 78 | ✗ |
| 79 | ✗ |

80 ✗
81 ✗
82 ✓

All contents of this site are © 2024 Passmedicine Limited

A 21-year-old university student presents with an itchy skin rash. The rash came on at the start of the new school year around his groin, and a few weeks later he developed an intense itch all over his body.

On examination, he had an erythematous rash in the distribution described with wheals and papules and a mild scale. He has excoriated areas all over his body.

His flatmate complains of a similar rash on his hands.

Given the likely diagnosis, what would be the treatment of choice?

- Malathion 0.5% to all skin for 12 hours, including the scalp, repeated after 14 days
- Malathion 0.5% to the scalp, and permethrin 5% to the rest of the skin, for 12 hours repeated after 7 days
- Permethrin 5% to all skin for 12 hours, including the scalp, repeated after 14 days
- Permethrin 5% to all skin for 12 hours, including the scalp, repeated after 7 days
- Permethrin 5% to all skin for 24 hours, excluding the scalp, repeated after 7 days

Submit answer

Reference ranges

Score: **28%**

1 ✗
2 ✓
3 ✓
4 ✗

| | |
|---|---|
| 5 | ✗ |
| 6 | ✗ |
| 7 | ✗ |
| 8 | ✗ |
| 9 | ✗ |
| 10 | ✗ |
| 11 | ✗ |
| 12 | ✗ |
| 13 | ✓ |
| 14 | ✓ |
| 15 | ✓ |
| 16 | ✗ |
| 17 | ✓ |
| 18 | ✓ |
| 19 | ✗ |
| 20 | ✗ |
| 21 | ✗ |
| 22 | ✗ |
| 23 | ✗ |
| 24 | ✓ |
| 25 | ✗ |
| 26 | ✓ |
| 27 | ✗ |
| 28 | ✗ |
| 29 | ✗ |
| 30 | ✓ |
| 31 | ✗ |
| 32 | ✗ |
| 33 | ✗ |
| 34 | ✗ |
| 35 | ✓ |
| 36 | ✗ |
| 37 | ✗ |
| 38 | ✗ |
| 39 | ✗ |
| 40 | ✗ |

| | |
|---|---|
| 41 | ✗ |
| 42 | ✓ |
| 43 | ✗ |
| 44 | ✗ |
| 45 | ✓ |
| 46 | ✓ |
| 47 | ✗ |
| 48 | ✗ |
| 49 | ✗ |
| 50 | ✗ |
| 51 | - |
| 52 | - |
| 53 | - |
| 54 | - |
| 55 | - |
| 56 | - |
| 57 | - |
| 58 | - |
| 59 | - |
| 60 | - |
| 61 | - |
| 62 | - |
| **63** | - |

All contents of this site are © 2024 Passmedicine Limited

Back to top

A 21-year-old university student presents with an itchy skin rash. The rash came on at the start of the new school year around his groin, and a few weeks later he developed an intense itch all over his body.

On examination, he had an erythematous rash in the distribution described with wheals and papules and a mild scale. He has excoriated areas all over his body.

His flatmate complains of a similar rash on his hands.

Given the likely diagnosis, what would be the treatment of choice?

- Malathion 0.5% to all skin for 12 hours, including the scalp, repeated after 14 days — 3%
- Malathion 0.5% to the scalp, and permethrin 5% to the rest of the skin, for 12 hours repeated after 7 days — 5%
- Permethrin 5% to all skin for 12 hours, including the scalp, repeated after 14 days — 9%
- Permethrin 5% to all skin for 12 hours, including the scalp, repeated after 7 days — 71%
- Permethrin 5% to all skin for 24 hours, excluding the scalp, repeated after 7 days — 12%

Scabies - permethrin treatment: all skin including scalp + leave for 12 hours + retreat in 7 days

Important for me    Less important

The likely diagnosis here is scabies. The delayed itching is due to the delayed type IV hypersensitivity reaction to the mites and eggs. The rash is commonly found on the hands, flexor aspects of the wrists, groin, and around the genitals. It is spread by skin contact and so is common in households.

**Permethrin 5% to all skin for 12 hours, including the scalp, repeated after 7 days** is the correct answer. Permethrin should be applied to all the skin including the scalp and left for 12 hours before washing off. Patients should be advised to make sure their skin is clean and dry before applying and to ensure coverage in difficult-to-reach areas and skin creases. This process should then be repeated after 7 days.

**Malathion 0.5% to all skin for 12 hours, including the scalp, repeated after 14 days** is incorrect. Malathion 0.5% would be a second-line treatment option.

**Permethrin 5% to all skin for 12 hours, including the scalp, repeated after 14 days** is incorrect. According to the BNF, the treatment should be reapplied after 7 days.

**Permethrin 5% to all skin for 24 hours, excluding the scalp, repeated after 7 days** is incorrect. According to the BNF, the treatment should be washed off after 12 hours, the treatment area should also include the scalp.

**Malathion 0.5% to the scalp, and permethrin 5% to the rest of the skin, for 12 hours repeated after 7 days** is incorrect. Combination therapy like this is not recommended. If permethrin 5% was not successful in clearing the infestation, malathion 0.5% could be tried.

Discuss Improve

Next question

## Scabies

Scabies is caused by the mite *Sarcoptes scabiei* and is spread by prolonged skin contact. It typically affects children and young adults.

The scabies mite burrows into the skin, laying its eggs in the stratum corneum. The intense pruritus associated with scabies is due to a delayed-type IV hypersensitivity reaction to mites/eggs which occurs about 30 days after the initial infection.

Features
- widespread pruritus
- linear burrows on the side of fingers, interdigital webs and flexor aspects of the wrist
- in infants, the face and scalp may also be affected
- secondary features are seen due to scratching: excoriation, infection

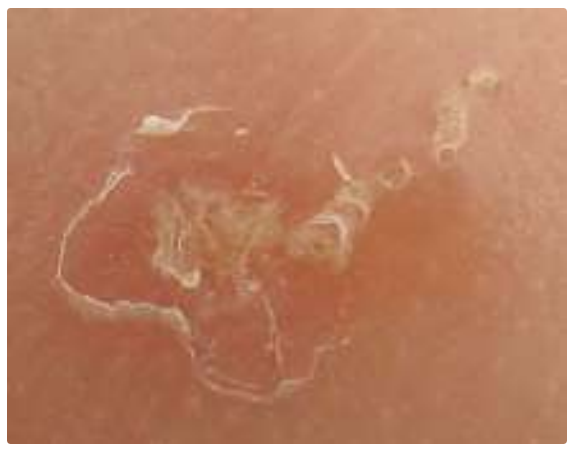

Management

- permethrin 5% is first-line
- malathion 0.5% is second-line
- give appropriate guidance on use (see below)
- pruritus persists for up to 4-6 weeks post eradication

Patient guidance on treatment

- avoid close physical contact with others until treatment is complete
- all household and close physical contacts should be treated at the same time, even if asymptomatic
- launder, iron or tumble dry clothing, bedding, towels, etc., on the first day of treatment to kill off mites.

The BNF advises to apply the insecticide to all areas, including the face and scalp, contrary to the manufacturer's recommendation. Patients should be given the following instructions:

- apply the insecticide cream or liquid to cool, dry skin
- pay close attention to areas between fingers and toes, under nails, armpit area, creases of the skin such as at the wrist and elbow
- allow to dry and leave on the skin for 8-12 hours for permethrin, or for 24 hours for malathion, before washing off
- reapply if insecticide is removed during the treatment period, e.g. If wash hands, change nappy, etc
- repeat treatment 7 days later

## Crusted (Norwegian) scabies

Crusted scabies is seen in patients with suppressed immunity, especially HIV.

© Image used on license from DermNet NZ

The crusted skin will be teeming with hundreds of thousands of organisms.

Ivermectin is the treatment of choice and isolation is essential

123

Next question

## Textbooks

High-yield textbook

Extended textbook

## Links

Clinical Knowledge Summaries 19 14

Scabies guidelines

Suggest link Report broken link

Score: **25.6%**

| | |
|---|---|
| 1 | ✗ |
| 2 | ✓ |
| 3 | ✓ |
| 4 | ✗ |
| 5 | ✗ |
| 6 | ✗ |
| 7 | ✗ |
| 8 | ✗ |
| 9 | ✗ |
| 10 | ✗ |
| 11 | ✗ |
| 12 | ✗ |
| 13 | ✓ |
| 14 | ✓ |
| 15 | ✓ |
| 16 | ✗ |
| 17 | ✓ |
| 18 | ✓ |
| 19 | ✗ |
| 20 | ✗ |
| 21 | ✗ |
| 22 | ✗ |
| 23 | ✗ |
| 24 | ✓ |
| 25 | ✗ |
| 26 | ✓ |
| 27 | ✗ |
| 28 | ✗ |
| 29 | ✗ |
| 30 | ✓ |
| 31 | ✗ |
| 32 | ✗ |
| 33 | ✗ |

| | |
|---|---|
| 34 | ✗ |
| 35 | ✓ |
| 36 | ✗ |
| 37 | ✗ |
| 38 | ✗ |
| 39 | ✗ |
| 40 | ✗ |
| 41 | ✗ |
| 42 | ✓ |
| 43 | ✗ |
| 44 | ✗ |
| 45 | ✓ |
| 46 | ✓ |
| 47 | ✗ |
| 48 | ✗ |
| 49 | ✗ |
| 50 | ✗ |
| 51 | ✗ |
| 52 | ✗ |
| 53 | ✓ |
| 54 | ✗ |
| 55 | ✗ |
| 56 | ✗ |
| 57 | ✗ |
| 58 | ✗ |
| 59 | ✗ |
| 60 | ✗ |
| 61 | ✗ |
| 62 | ✓ |
| **63** | ✗ |
| 64 | ✓ |
| 65 | ✗ |
| 66 | ✓ |
| 67 | ✓ |
| 68 | ✗ |
| 69 | ✗ |

| | |
|---|---|
| 70 | ✗ |
| 71 | ✗ |
| 72 | ✗ |
| 73 | ✗ |
| 74 | ✗ |
| 75 | ✓ |
| 76 | ✗ |
| 77 | ✗ |
| 78 | ✗ |
| 79 | ✗ |
| 80 | ✗ |
| 81 | ✗ |
| 82 | ✓ |

All contents of this site are © 2024 Passmedicine Limited

Back to top

A 50-year-old woman presents with a painful burning rash one week after starting chemotherapy. She describes a tingling sensation that started three days previously, which then progressed to swelling and redness of both her hands. She now finds that is impacting on what she able to do at home. Over the last day, she has noticed a blister as well. She has otherwise been suffering from fatigue and nausea since starting chemotherapy. She has a past medical history of left breast cancer managed with wide local excision and axillary node clearance following adjuvant radiotherapy and chemotherapy with docetaxel, as well as endocrine therapy. What is the most appropriate management?

- Topical hydrocortisone
- Prednisolone
- Flucloxacillin
- Stop endocrine treatment
- Dose reduction of docetaxel

Submit answer

Reference ranges

Score: **28%**

1 ✗
2 ✓
3 ✓
4 ✗
5 ✗

| | |
|---|---|
| 6 | ✗ |
| 7 | ✗ |
| 8 | ✗ |
| 9 | ✗ |
| 10 | ✗ |
| 11 | ✗ |
| 12 | ✗ |
| 13 | ✓ |
| 14 | ✓ |
| 15 | ✓ |
| 16 | ✗ |
| 17 | ✓ |
| 18 | ✓ |
| 19 | ✗ |
| 20 | ✗ |
| 21 | ✗ |
| 22 | ✗ |
| 23 | ✗ |
| 24 | ✓ |
| 25 | ✗ |
| 26 | ✓ |
| 27 | ✗ |
| 28 | ✗ |
| 29 | ✗ |
| 30 | ✓ |
| 31 | ✗ |
| 32 | ✗ |
| 33 | ✗ |
| 34 | ✗ |
| 35 | ✓ |
| 36 | ✗ |
| 37 | ✗ |
| 38 | ✗ |
| 39 | ✗ |
| 40 | ✗ |
| 41 | ✗ |

| | |
|---|---|
| 42 | ✓ |
| 43 | ✗ |
| 44 | ✗ |
| 45 | ✓ |
| 46 | ✓ |
| 47 | ✗ |
| 48 | ✗ |
| 49 | ✗ |
| 50 | ✗ |
| 51 | - |
| 52 | - |
| 53 | - |
| 54 | - |
| 55 | - |
| 56 | - |
| 57 | - |
| 58 | - |
| 59 | - |
| 60 | - |
| 61 | - |
| 62 | - |
| 63 | - |
| **64** | - |

All contents of this site are © 2024 Passmedicine Limited

A 50-year-old woman presents with a painful burning rash one week after starting chemotherapy. She describes a tingling sensation that started three days previously, which then progressed to swelling and redness of both her hands. She now finds that is impacting on what she able to do at home. Over the last day, she has noticed a blister as well. She has otherwise been suffering from fatigue and nausea since starting chemotherapy. She has a past medical history of left breast cancer managed with wide local excision and axillary node clearance following adjuvant radiotherapy and chemotherapy with docetaxel, as well as endocrine therapy. What is the most appropriate management?

| | |
|---|---|
| Topical hydrocortisone | 19% |
| Prednisolone | 27% |
| Flucloxacillin | 4% |
| Stop endocrine treatment | 6% |
| Dose reduction of docetaxel | 44% |

The answer is dose reduction of docetaxel. This history describes palmar-plantar erythrodysesthesia which is severe enough to limit daily activities. Whilst all cases can benefit from supportive management with emollients, cooling therapy and skin protection, severe reactions which cause an impact on the quality of life will usually be managed with dose reduction in chemotherapy. Steroids are not helpful in this condition, and there is no evidence of infection and therefore antibiotics are not appropriate. This explains why answers A, B and C are incorrect. Her endocrine treatment would not cause this problem and modifying it would be of no benefit as well, which is why D is incorrect.

Discuss (4) Improve

Next question

## Palmar-plantar erythrodysesthesia

Palmar-plantar erythrodysesthesia is a common side effect of many chemotherapy treatments, occurring from days to months into treatment. It usually presents with tingling or numbness first in the fingers and palms and then toes and soles of the feet. This is then followed by an erythematous rash which can desquamate, blister and ulcerate which can be associated with onycholysis. Management depends on severity; mild reactions with only dysesthesia and no pain can be managed with supportive care, but severe reactions with serious desquamation, blistering and ulceration will need to have treatment delayed and the dose of chemotherapy reduced.

Source:

Moos, Roger Von, Beat J.k. Thuerlimann, Matti Aapro, Daniel Rayson, Karen Harrold, Jalid Sehouli, Florian Scotte, Domenica Lorusso, Reinhard Dummer, Mario E. Lacouture, Jurgen Lademann, and Axel Hauschild. 'Pegylated Liposomal Doxorubicin-associated Handfoot Syndrome: Recommendations of an International Panel of Experts.' European Journal of Cancer 44.6 (2008): 781-90.

+ Q 123

Next question >

B I A

**Textbooks**

High-yield textbook

Extended textbook

Score: **25.6%**

1 ✗
2 ✓

| | |
|---|---|
| 3 | ✓ |
| 4 | ✗ |
| 5 | ✗ |
| 6 | ✗ |
| 7 | ✗ |
| 8 | ✗ |
| 9 | ✗ |
| 10 | ✗ |
| 11 | ✗ |
| 12 | ✗ |
| 13 | ✓ |
| 14 | ✓ |
| 15 | ✓ |
| 16 | ✗ |
| 17 | ✓ |
| 18 | ✓ |
| 19 | ✗ |
| 20 | ✗ |
| 21 | ✗ |
| 22 | ✗ |
| 23 | ✗ |
| 24 | ✓ |
| 25 | ✗ |
| 26 | ✓ |
| 27 | ✗ |
| 28 | ✗ |
| 29 | ✗ |
| 30 | ✓ |
| 31 | ✗ |
| 32 | ✗ |
| 33 | ✗ |
| 34 | ✗ |
| 35 | ✓ |
| 36 | ✗ |
| 37 | ✗ |
| 38 | ✗ |

| | |
|---|---|
| 39 | ✗ |
| 40 | ✗ |
| 41 | ✗ |
| 42 | ✓ |
| 43 | ✗ |
| 44 | ✗ |
| 45 | ✓ |
| 46 | ✓ |
| 47 | ✗ |
| 48 | ✗ |
| 49 | ✗ |
| 50 | ✗ |
| 51 | ✗ |
| 52 | ✗ |
| 53 | ✓ |
| 54 | ✗ |
| 55 | ✗ |
| 56 | ✗ |
| 57 | ✗ |
| 58 | ✗ |
| 59 | ✗ |
| 60 | ✗ |
| 61 | ✗ |
| 62 | ✓ |
| 63 | ✗ |
| **64** | ✓ |
| 65 | ✗ |
| 66 | ✓ |
| 67 | ✓ |
| 68 | ✗ |
| 69 | ✗ |
| 70 | ✗ |
| 71 | ✗ |
| 72 | ✗ |
| 73 | ✗ |
| 74 | ✗ |

75 ✓
76 ✗
77 ✗
78 ✗
79 ✗
80 ✗
81 ✗
82 ✓

All contents of this site are © 2024 Passmedicine Limited

Back to top

A 54-year-old man presents with a facial rash of several months. He explains that, initially, it started with redness across the face, before progressing to its current appearance as shown below:

© Image used on license from DermNet NZ

He also mentions that it worsens in sunlight. He is otherwise fit and well, with no significant past medical history, nor any regular medications.

Given the likely diagnosis, which of the following is the most appropriate treatment?

- Topical adapalene
- Topical hydrocortisone
- Topical ketoconazole
- Topical ivermectin
- Topical tacrolimus

Submit answer

Reference ranges

Score: **28%**

| | |
|---|---|
| 1 | ✗ |
| 2 | ✓ |
| 3 | ✓ |
| 4 | ✗ |
| 5 | ✗ |
| 6 | ✗ |
| 7 | ✗ |
| 8 | ✗ |
| 9 | ✗ |
| 10 | ✗ |
| 11 | ✗ |
| 12 | ✗ |
| 13 | ✓ |
| 14 | ✓ |
| 15 | ✓ |
| 16 | ✗ |
| 17 | ✓ |
| 18 | ✓ |
| 19 | ✗ |
| 20 | ✗ |
| 21 | ✗ |
| 22 | ✗ |
| 23 | ✗ |
| 24 | ✓ |
| 25 | ✗ |
| 26 | ✓ |

| | |
|---|---|
| 27 | ✗ |
| 28 | ✗ |
| 29 | ✗ |
| 30 | ✓ |
| 31 | ✗ |
| 32 | ✗ |
| 33 | ✗ |
| 34 | ✗ |
| 35 | ✓ |
| 36 | ✗ |
| 37 | ✗ |
| 38 | ✗ |
| 39 | ✗ |
| 40 | ✗ |
| 41 | ✗ |
| 42 | ✓ |
| 43 | ✗ |
| 44 | ✗ |
| 45 | ✓ |
| 46 | ✓ |
| 47 | ✗ |
| 48 | ✗ |
| 49 | ✗ |
| 50 | ✗ |
| 51 | - |
| 52 | - |
| 53 | - |
| 54 | - |
| 55 | - |
| 56 | - |
| 57 | - |
| 58 | - |
| 59 | - |
| 60 | - |
| 61 | - |
| 62 | - |
| 63 | - |

| | |
|---|---|
| 64 | - |
| **65** | - |

All contents of this site are © 2024 Passmedicine Limited

A 54-year-old man presents with a facial rash of several months. He explains that, initially, it started with redness across the face, before progressing to its current appearance as shown below:

© Image used on license from DermNet NZ

He also mentions that it worsens in sunlight. He is otherwise fit and well, with no significant past medical history, nor any regular medications.

Given the likely diagnosis, which of the following is the most appropriate treatment?

| | |
|---|---|
| Topical adapalene | 7% |
| Topical hydrocortisone | 10% |
| Topical ketoconazole | 9% |
| Topical ivermectin | 70% |
| Topical tacrolimus | 4% |

The correct answer is topical ivermectin - the diagnosis here is that of rosacea. The photo shows

significant erythema across the forehead, nose and cheeks. Many papules and, to a lesser extent, pustules can also be seen across these same areas. The rosacea in this photo is not severe - rhinophyma of the nose would also be expected. The patient does appear to have some erythema and papules overlying the nose, which may be the start of rhinophyma. In severe rosacea, the rhinophyma would be more obvious than what is seen here. From the options above, topical ivermectin is the most appropriate treatment option in this case.

Topical adapalene is more commonly associated with the treatment of mild acne vulgaris, rather than rosacea. Typically, comedones would be present in acne vulgaris, colloquially referred to as 'whiteheads' and 'blackheads' depending on their appearance, which are not seen in this photo. Adapalene has been described in the literature as a potential alternative to topical metronidazole, although it is not recommended in guidelines for this purpose.

Hydrocortisone would be used for the treatment of facial eczema, not rosacea. Eczema would present with erythema and dryness, but not papules and pustules as seen in this photo. A mild corticosteroid may help to alleviate the appearance of erythema temporarily, but would not address the underlying issue.

Topical ketoconazole is an antifungal and would be used to treat seborrhoeic dermatitis rather than rosacea. This would present with erythema, but greasy, flaky scale rather than papules and pustules.

Tacrolimus can be used topically for steroid-resistant facial eczema, rather than stepping up to more potent steroids for the face. It is not routinely used in the management of rosacea.

Discuss | Improve

Next question

## Rosacea

Rosacea (sometimes referred to as acne rosacea) is a chronic skin disease of unknown aetiology.

Features

- typically affects nose, cheeks and forehead
- flushing is often first symptom
- telangiectasia are common
- later develops into persistent erythema with papules and pustules
- rhinophyma
- ocular involvement: blepharitis
- sunlight may exacerbate symptoms

Management

- simple measures
  - recommend daily application of a high-factor sunscreen
  - camouflage creams may help conceal redness
- predominant erythema/flushing
  - topical brimonidine gel may be considered for patients with predominant flushing but limited telangiectasia
  - brimonidine is a topical alpha-adrenergic agonist
  - this can be used on an 'as required basis' to temporarily reduce redness
  - it typically reduces redness within 30 minutes, reaching peak action at 3-6 hours, after which the redness returns to the baseline
- mild-to-moderate papules and/or pustules
  - topical ivermectin is first-line
  - alternatives include: topical metronidazole or topical azelaic acid
- moderate-to-severe papules and/or pustules
  - combination of topical ivermectin + oral doxycycline

Referral should be considered if

- symptoms have not improved with optimal management in primary care
  - laser therapy may be appropriate for patients with prominent telangiectasia
- patients with a rhinophyma

123

Next question

## Textbooks

High-yield textbook

Extended textbook

## Links

DermNet NZ — 11 / 17

Rhinophyma

BNF — 10 / 11

Acne rosacea

Dermnet NZ — 23 / 13

Acne rosacea

Clinical Knowledge Summaries — 19 / 10

Acne rosacea guidelines

Primary Care Dermatology Society — 27 / 9

Rosacea review

Suggest link

Report broken link

Score: **25.6%**

1 ✗
2 ✓
3 ✓
4 ✗

| | |
|---|---|
| 5 | ✗ |
| 6 | ✗ |
| 7 | ✗ |
| 8 | ✗ |
| 9 | ✗ |
| 10 | ✗ |
| 11 | ✗ |
| 12 | ✗ |
| 13 | ✓ |
| 14 | ✓ |
| 15 | ✓ |
| 16 | ✗ |
| 17 | ✓ |
| 18 | ✓ |
| 19 | ✗ |
| 20 | ✗ |
| 21 | ✗ |
| 22 | ✗ |
| 23 | ✗ |
| 24 | ✓ |
| 25 | ✗ |
| 26 | ✓ |
| 27 | ✗ |
| 28 | ✗ |
| 29 | ✗ |
| 30 | ✓ |
| 31 | ✗ |
| 32 | ✗ |
| 33 | ✗ |
| 34 | ✗ |
| 35 | ✓ |
| 36 | ✗ |
| 37 | ✗ |
| 38 | ✗ |
| 39 | ✗ |
| 40 | ✗ |

| | |
|---|---|
| 41 | ✗ |
| 42 | ✓ |
| 43 | ✗ |
| 44 | ✗ |
| 45 | ✓ |
| 46 | ✓ |
| 47 | ✗ |
| 48 | ✗ |
| 49 | ✗ |
| 50 | ✗ |
| 51 | ✗ |
| 52 | ✗ |
| 53 | ✓ |
| 54 | ✗ |
| 55 | ✗ |
| 56 | ✗ |
| 57 | ✗ |
| 58 | ✗ |
| 59 | ✗ |
| 60 | ✗ |
| 61 | ✗ |
| 62 | ✓ |
| 63 | ✗ |
| 64 | ✓ |
| **65** | ✗ |
| 66 | ✓ |
| 67 | ✓ |
| 68 | ✗ |
| 69 | ✗ |
| 70 | ✗ |
| 71 | ✗ |
| 72 | ✗ |
| 73 | ✗ |
| 74 | ✗ |
| 75 | ✓ |
| 76 | ✗ |

77 ✗
78 ✗
79 ✗
80 ✗
81 ✗
82 ✓

All contents of this site are © 2024 Passmedicine Limited

A 62-year-old man asks you to look at a lesion on his face:

© Image used on license from DermNet NZ and with the kind permission of Prof Raimo Suhonen

What is the most likely diagnosis?

- Keratoacanthoma
- Seborrhoeic keratoses
- Actinic keratosis
- Basal cell carcinoma
- Pyoderma gangrenosum

Submit answer

Reference ranges

Score: **28%**

| | |
|---|---|
| 1 | ✗ |
| 2 | ✓ |
| 3 | ✓ |
| 4 | ✗ |
| 5 | ✗ |
| 6 | ✗ |
| 7 | ✗ |
| 8 | ✗ |
| 9 | ✗ |
| 10 | ✗ |
| 11 | ✗ |
| 12 | ✗ |
| 13 | ✓ |
| 14 | ✓ |
| 15 | ✓ |
| 16 | ✗ |
| 17 | ✓ |
| 18 | ✓ |
| 19 | ✗ |
| 20 | ✗ |
| 21 | ✗ |
| 22 | ✗ |
| 23 | ✗ |
| 24 | ✓ |
| 25 | ✗ |
| 26 | ✓ |
| 27 | ✗ |
| 28 | ✗ |
| 29 | ✗ |
| 30 | ✓ |
| 31 | ✗ |
| 32 | ✗ |
| 33 | ✗ |
| 34 | ✗ |

| | |
|---|---|
| 35 | ✓ |
| 36 | ✗ |
| 37 | ✗ |
| 38 | ✗ |
| 39 | ✗ |
| 40 | ✗ |
| 41 | ✗ |
| 42 | ✓ |
| 43 | ✗ |
| 44 | ✗ |
| 45 | ✓ |
| 46 | ✓ |
| 47 | ✗ |
| 48 | ✗ |
| 49 | ✗ |
| 50 | ✗ |
| 51 | - |
| 52 | - |
| 53 | - |
| 54 | - |
| 55 | - |
| 56 | - |
| 57 | - |
| 58 | - |
| 59 | - |
| 60 | - |
| 61 | - |
| 62 | - |
| 63 | - |
| 64 | - |
| 65 | - |
| **66** | - |

All contents of this site are © 2024 Passmedicine Limited

Back to top

A 67-year-old woman attends with a skin lesion. She described falling whilst walking in the Scottish Highlands and sustaining a small cut on her leg. This initially seemed to heal, but the woman then noted a blood-filled blister which has since burst and left the painful lesion shown below:

© Image used on license from DermNet NZ

What is the most likely diagnosis?

| | |
|---|---|
| Abscess | 3% |
| Cutaneous vasculitis | 3% |
| Pyoderma gangrenosum | 76% |
| Sweet's syndrome | 9% |
| Venous insufficiency ulcer | 10% |

The photo shows a typical pyoderma gangrenosum lesion with a deep ulcer and surrounding violaceous pigmentation.

**Pyoderma gangrenosum** is the correct answer. The diagnosis is often made on the characteristic appearance and history.

**Cutaneous vasculitis** is incorrect. This is a differential to consider, but is rare and is usually more widespread. In this case, there are also no systemic symptoms that you might expect with vasculitis.

**Abscess** is incorrect. This would be a fluctuant swelling, often with overlying cellulitis and would usually be associated with systemic symptoms.

**Sweet's syndrome** is incorrect. It is also known as acute febrile neutrophilic dermatosis and is a rare condition. It usually causes rashes on the upper body and face. It is an important differential but is not the most likely diagnosis here given the distribution of the rash and its rarity.

**Venous insufficiency ulcer** is incorrect. With venous insufficiency, you would expect to see associated skin changes and longer duration. This patient has no history of peripheral vascular disease which makes venous insufficiency ulcer even less likely.

Discuss | Improve

Next question >

## Pyoderma gangrenosum

Pyoderma gangrenosum is a rare, non-infectious, inflammatory disorder. It is an uncommon cause of very painful skin ulceration. It may affect any part of the skin, but the lower legs are the most common site.

Pathophysiology

- pyoderma gangrenosum is classified as a neutrophilic dermatosis
- neutrophilic dermatoses are skin conditions characterised by dense infiltration of neutrophils in the affected tissue and this is often seen on biopsy

Causes

- idiopathic in 50%
- inflammatory bowel disease in 10-15%
  - ulcerative colitis
  - Crohn's
- rheumatological
  - rheumatoid arthritis
  - SLE
- haematological
  - myeloproliferative disorders

- lymphoma
- myeloid leukaemias
- monoclonal gammopathy (IgA)
- granulomatosis with polyangiitis
- primary biliary cirrhosis

Features
- location
  - typically on the lower limb
  - soften at the site of a minor injury as in this patient's case and this is known as pathergy
- initially features:
  - usually starts quite suddenly
  - small pustule, red bump or blood-blister
- later features:
  - the skin then breaks down resulting in an ulcer which is often painful
  - the edge of the ulcer is often described as purple, violaceous and undermined.
  - the ulcer itself may be deep and necrotic
- may be accompanied by systemic symptoms
  - fever
  - myalgia

Diagnosis
- often made by the characteristic appearance, associations with other diseases, the presence of pathergy, histology results and when other diseases have been ruled out
- histology is not specific and can vary depending on the time and site of the specimen but may be helpful in ruling out other causes of an ulcer.

Management
- the potential for rapid progression is high in most patients and most doctors advocate oral steroids as first-line treatment
- other immunosuppressive therapy, for example, ciclosporin and infliximab, have a role in difficult cases
- any surgery should be postponed until the disease process is controlled on immunosuppression to risk worsening of the disease (pathergy)

123

Next question

## Textbooks

High-yield textbook

Extended textbook

## Links

DermNet NZ 10 9

Stoma skin problems

DermNet NZ 19 6

Pyoderma gangrenosum

Suggest link Report broken link

Score: **25.6%**

| | |
|---|---|
| 1 | ✗ |
| 2 | ✓ |
| 3 | ✓ |
| 4 | ✗ |
| 5 | ✗ |

| | |
|---|---|
| 6 | ✗ |
| 7 | ✗ |
| 8 | ✗ |
| 9 | ✗ |
| 10 | ✗ |
| 11 | ✗ |
| 12 | ✗ |
| 13 | ✓ |
| 14 | ✓ |
| 15 | ✓ |
| 16 | ✗ |
| 17 | ✓ |
| 18 | ✓ |
| 19 | ✗ |
| 20 | ✗ |
| 21 | ✗ |
| 22 | ✗ |
| 23 | ✗ |
| 24 | ✓ |
| 25 | ✗ |
| 26 | ✓ |
| 27 | ✗ |
| 28 | ✗ |
| 29 | ✗ |
| 30 | ✓ |
| 31 | ✗ |
| 32 | ✗ |
| 33 | ✗ |
| 34 | ✗ |
| 35 | ✓ |
| 36 | ✗ |
| 37 | ✗ |
| 38 | ✗ |
| 39 | ✗ |
| 40 | ✗ |
| 41 | ✗ |

| | |
|---|---|
| 42 | ✓ |
| 43 | ✗ |
| 44 | ✗ |
| 45 | ✓ |
| 46 | ✓ |
| 47 | ✗ |
| 48 | ✗ |
| 49 | ✗ |
| 50 | ✗ |
| 51 | ✗ |
| 52 | ✗ |
| 53 | ✓ |
| 54 | ✗ |
| 55 | ✗ |
| 56 | ✗ |
| 57 | ✗ |
| 58 | ✗ |
| 59 | ✗ |
| 60 | ✗ |
| 61 | ✗ |
| 62 | ✓ |
| 63 | ✗ |
| 64 | ✓ |
| 65 | ✗ |
| 66 | ✓ |
| **67** | ✓ |
| 68 | ✗ |
| 69 | ✗ |
| 70 | ✗ |
| 71 | ✗ |
| 72 | ✗ |
| 73 | ✗ |
| 74 | ✗ |
| 75 | ✓ |
| 76 | ✗ |
| 77 | ✗ |

| | |
|---|---|
| 78 | ✗ |
| 79 | ✗ |
| 80 | ✗ |
| 81 | ✗ |
| 82 | ✓ |

All contents of this site are © 2024 Passmedicine Limited

A 67-year-old woman attends with a skin lesion. She described falling whilst walking in the Scottish Highlands and sustaining a small cut on her leg. This initially seemed to heal, but the woman then noted a blood-filled blister which has since burst and left the painful lesion shown below:

© Image used on license from DermNet NZ

What is the most likely diagnosis?

- Abscess
- Cutaneous vasculitis
- Pyoderma gangrenosum
- Sweet's syndrome
- Venous insufficiency ulcer

Submit answer

Reference ranges

Score: **28%**

| | |
|---|---|
| 1 | ✗ |
| 2 | ✓ |
| 3 | ✓ |
| 4 | ✗ |
| 5 | ✗ |
| 6 | ✗ |
| 7 | ✗ |
| 8 | ✗ |
| 9 | ✗ |
| 10 | ✗ |
| 11 | ✗ |
| 12 | ✗ |
| 13 | ✓ |
| 14 | ✓ |
| 15 | ✓ |
| 16 | ✗ |
| 17 | ✓ |
| 18 | ✓ |
| 19 | ✗ |
| 20 | ✗ |
| 21 | ✗ |
| 22 | ✗ |
| 23 | ✗ |
| 24 | ✓ |
| 25 | ✗ |
| 26 | ✓ |
| 27 | ✗ |
| 28 | ✗ |
| 29 | ✗ |
| 30 | ✓ |
| 31 | ✗ |
| 32 | ✗ |
| 33 | ✗ |
| 34 | ✗ |

| | |
|---|---|
| 35 | ✓ |
| 36 | ✗ |
| 37 | ✗ |
| 38 | ✗ |
| 39 | ✗ |
| 40 | ✗ |
| 41 | ✗ |
| 42 | ✓ |
| 43 | ✗ |
| 44 | ✗ |
| 45 | ✓ |
| 46 | ✓ |
| 47 | ✗ |
| 48 | ✗ |
| 49 | ✗ |
| 50 | ✗ |
| 51 | - |
| 52 | - |
| 53 | - |
| 54 | - |
| 55 | - |
| 56 | - |
| 57 | - |
| 58 | - |
| 59 | - |
| 60 | - |
| 61 | - |
| 62 | - |
| 63 | - |
| 64 | - |
| 65 | - |
| 66 | - |
| **67** | - |

All contents of this site are © 2024 Passmedicine Limited

A 67-year-old woman attends with a skin lesion. She described falling whilst walking in the Scottish Highlands and sustaining a small cut on her leg. This initially seemed to heal, but the woman then noted a blood-filled blister which has since burst and left the painful lesion shown below:

© Image used on license from DermNet NZ

What is the most likely diagnosis?

| | |
|---|---|
| Abscess | 3% |
| Cutaneous vasculitis | 3% |
| Pyoderma gangrenosum | 76% |
| Sweet's syndrome | 9% |
| Venous insufficiency ulcer | 10% |

The photo shows a typical pyoderma gangrenosum lesion with a deep ulcer and surrounding violaceous pigmentation.

**Pyoderma gangrenosum** is the correct answer. The diagnosis is often made on the characteristic appearance and history.

**Cutaneous vasculitis** is incorrect. This is a differential to consider, but is rare and is usually more widespread. In this case, there are also no systemic symptoms that you might expect with vasculitis.

**Abscess** is incorrect. This would be a fluctuant swelling, often with overlying cellulitis and would usually be associated with systemic symptoms.

**Sweet's syndrome** is incorrect. It is also known as acute febrile neutrophilic dermatosis and is a rare condition. It usually causes rashes on the upper body and face. It is an important differential but is not the most likely diagnosis here given the distribution of the rash and its rarity.

**Venous insufficiency ulcer** is incorrect. With venous insufficiency, you would expect to see associated skin changes and longer duration. This patient has no history of peripheral vascular disease which makes venous insufficiency ulcer even less likely.

Discuss | Improve

Next question >

## Pyoderma gangrenosum

Pyoderma gangrenosum is a rare, non-infectious, inflammatory disorder. It is an uncommon cause of very painful skin ulceration. It may affect any part of the skin, but the lower legs are the most common site.

Pathophysiology

- pyoderma gangrenosum is classified as a neutrophilic dermatosis
- neutrophilic dermatoses are skin conditions characterised by dense infiltration of neutrophils in the affected tissue and this is often seen on biopsy

Causes

- idiopathic in 50%
- inflammatory bowel disease in 10-15%
    - ulcerative colitis
    - Crohn's
- rheumatological
    - rheumatoid arthritis
    - SLE
- haematological
    - myeloproliferative disorders

- lymphoma
  - myeloid leukaemias
  - monoclonal gammopathy (IgA)
- granulomatosis with polyangiitis
- primary biliary cirrhosis

Features

- location
  - typically on the lower limb
  - soften at the site of a minor injury as in this patient's case and this is known as pathergy
- initially features:
  - usually starts quite suddenly
  - small pustule, red bump or blood-blister
- later features:
  - the skin then breaks down resulting in an ulcer which is often painful
  - the edge of the ulcer is often described as purple, violaceous and undermined.
  - the ulcer itself may be deep and necrotic
- may be accompanied by systemic symptoms
  - fever
  - myalgia

Diagnosis

- often made by the characteristic appearance, associations with other diseases, the presence of pathergy, histology results and when other diseases have been ruled out
- histology is not specific and can vary depending on the time and site of the specimen but may be helpful in ruling out other causes of an ulcer.

Management

- the potential for rapid progression is high in most patients and most doctors advocate oral steroids as first-line treatment
- other immunosuppressive therapy, for example, ciclosporin and infliximab, have a role in difficult cases
- any surgery should be postponed until the disease process is controlled on immunosuppression to risk worsening of the disease (pathergy)

123

Next question

## Textbooks

High-yield textbook

Extended textbook

## Links

DermNet NZ — 10 / 9

Stoma skin problems

DermNet NZ — 19 / 6

Pyoderma gangrenosum

Suggest link

Report broken link

Score: **25.6%**

1 ✗
2 ✓
3 ✓
4 ✗
5 ✗

| | |
|---|---|
| 6 | ✗ |
| 7 | ✗ |
| 8 | ✗ |
| 9 | ✗ |
| 10 | ✗ |
| 11 | ✗ |
| 12 | ✗ |
| 13 | ✓ |
| 14 | ✓ |
| 15 | ✓ |
| 16 | ✗ |
| 17 | ✓ |
| 18 | ✓ |
| 19 | ✗ |
| 20 | ✗ |
| 21 | ✗ |
| 22 | ✗ |
| 23 | ✗ |
| 24 | ✓ |
| 25 | ✗ |
| 26 | ✓ |
| 27 | ✗ |
| 28 | ✗ |
| 29 | ✗ |
| 30 | ✓ |
| 31 | ✗ |
| 32 | ✗ |
| 33 | ✗ |
| 34 | ✗ |
| 35 | ✓ |
| 36 | ✗ |
| 37 | ✗ |
| 38 | ✗ |
| 39 | ✗ |
| 40 | ✗ |
| 41 | ✗ |

| | |
|---|---|
| 42 | ✓ |
| 43 | ✗ |
| 44 | ✗ |
| 45 | ✓ |
| 46 | ✓ |
| 47 | ✗ |
| 48 | ✗ |
| 49 | ✗ |
| 50 | ✗ |
| 51 | ✗ |
| 52 | ✗ |
| 53 | ✓ |
| 54 | ✗ |
| 55 | ✗ |
| 56 | ✗ |
| 57 | ✗ |
| 58 | ✗ |
| 59 | ✗ |
| 60 | ✗ |
| 61 | ✗ |
| 62 | ✓ |
| 63 | ✗ |
| 64 | ✓ |
| 65 | ✗ |
| 66 | ✓ |
| **67** | ✓ |
| 68 | ✗ |
| 69 | ✗ |
| 70 | ✗ |
| 71 | ✗ |
| 72 | ✗ |
| 73 | ✗ |
| 74 | ✗ |
| 75 | ✓ |
| 76 | ✗ |
| 77 | ✗ |

| | |
|---|---|
| 78 | ✗ |
| 79 | ✗ |
| 80 | ✗ |
| 81 | ✗ |
| 82 | ✓ |

All contents of this site are © 2024 Passmedicine Limited

A 38-year-old man presents with a sudden onset rash. He is otherwise well in himself and has no notable past medical history. You see from his notes he has had a recent tonsillitis for which he received amoxicillin. On examination, there are multiple papules on his trunk and proximal extremities. There is a fine scale on several of these lesions. What is the most likely diagnosis?

- Drug eruption
- Pityriasis rosea
- Nummular dermatitis
- Guttate psoriasis
- Treponema pallidum

Submit answer

Reference ranges

Score: **28%**

| | |
|---|---|
| 1 | ✗ |
| 2 | ✓ |
| 3 | ✓ |
| 4 | ✗ |
| 5 | ✗ |
| 6 | ✗ |
| 7 | ✗ |
| 8 | ✗ |
| 9 | ✗ |
| 10 | ✗ |

11 ✗
12 ✗
13 ✓
14 ✓
15 ✓
16 ✗
17 ✓
18 ✓
19 ✗
20 ✗
21 ✗
22 ✗
23 ✗
24 ✓
25 ✗
26 ✓
27 ✗
28 ✗
29 ✗
30 ✓
31 ✗
32 ✗
33 ✗
34 ✗
35 ✓
36 ✗
37 ✗
38 ✗
39 ✗
40 ✗
41 ✗
42 ✓
43 ✗
44 ✗
45 ✓
46 ✓

| | |
|---|---|
| 47 | ✕ |
| 48 | ✕ |
| 49 | ✕ |
| 50 | ✕ |
| 51 | - |
| 52 | - |
| 53 | - |
| 54 | - |
| 55 | - |
| 56 | - |
| 57 | - |
| 58 | - |
| 59 | - |
| 60 | - |
| 61 | - |
| 62 | - |
| 63 | - |
| 64 | - |
| 65 | - |
| 66 | - |
| 67 | - |
| **68** | - |

All contents of this site are © 2024 Passmedicine Limited

A 38-year-old man presents with a sudden onset rash. He is otherwise well in himself and has no notable past medical history. You see from his notes he has had a recent tonsillitis for which he received amoxicillin. On examination, there are multiple papules on his trunk and proximal extremities. There is a fine scale on several of these lesions. What is the most likely diagnosis?

| | |
|---|---|
| Drug eruption | 18% |
| Pityriasis rosea | 13% |
| Nummular dermatitis | 2% |
| Guttate psoriasis | 65% |
| Treponema pallidum | 1% |

Acute onset of tear-drop scaly papules on trunk and limbs → ?guttate psoriasis

Important for me Less important

Guttate psoriasis usually presents in children and adults younger than 30 years of age. It can occur as the first presentation of psoriasis or as an acute exacerbation of plaque psoriasis, particularly after acute streptococcal infection (usually of the throat) or viral infection.

Lesions are small, round or oval (2 mm to 1 cm in diameter) scaly papules. They may be pink or red, but this can vary depending on the person's skin colour. Lesions occur all over the body, usually in large numbers and particularly on the trunk and proximal limbs (although the distal limbs can also be involved). Guttate psoriasis can occur on the face, ears, and scalp, but is rarely seen on the soles of the feet.

Discuss (4) Improve

Next question

## Guttate psoriasis

Guttate psoriasis is more common in children and adolescents. It may be precipitated by a streptococcal infection 2-4 weeks prior to the lesions appearing.

Features

- tear drop papules on the trunk and limbs
  - *gutta* is Latin for drop
  - pink, scaly patches or plques of psoriasis
- tends to be acute onset over days

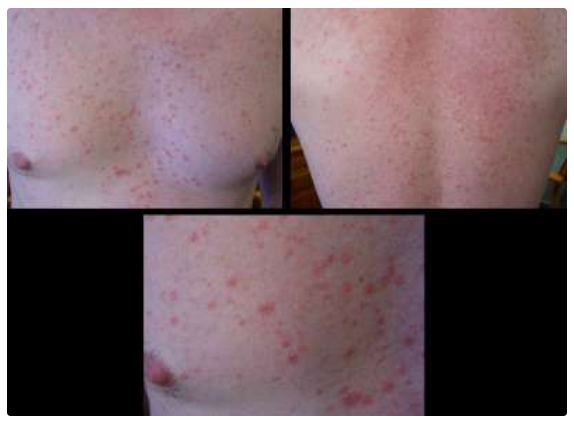

Management

- most cases resolve spontaneously within 2-3 months
- there is no firm evidence to support the use of antibiotics to eradicate streptococcal infection
- topical agents as per psoriasis
- UVB phototherapy
- tonsillectomy may be necessary with recurrent episodes

## Differentiating guttate psoriasis and pityriasis rosea

| | Guttate psoriasis | Pityriasis rosea |
|---|---|---|
| **Prodrome** | Classically preceded by a streptococcal sore throat 2-4 weeks | Many patients report recent respiratory tract infections but this is not common in questions |
| **Appearance** | 'Tear drop', scaly papules on the trunk and limbs | Herald patch followed 1-2 weeks later by multiple erythematous, slightly raised oval lesions with a fine scale confined to the outer aspects of the lesions.<br><br>May follow a characteristic distribution with the longitudinal diameters of the oval lesions running |

| | Guttate psoriasis | Pityriasis rosea |
|---|---|---|
| | | parallel to the line of Langer. This may produce a 'fir-tree' appearance |
| **Treatment / natural history** | Most cases resolve spontaneously within 2-3 months<br>Topical agents as per psoriasis<br>UVB phototherapy | Self-limiting, resolves after around 6 weeks |

+ Q 123

Next question >

## Textbooks

High-yield textbook

Extended textbook

## Links

Clinical Knowledge Summaries 12 7

Guttate psoriasis guidelines

Dermnet NZ 11 3

Guttate psoriasis

Suggest link Report broken link

## Media

Psoriasis

Osmosis - YouTube 2 0

Report broken media

Score: **25.6%**

| | |
|---|---|
| 1 | ✗ |
| 2 | ✓ |
| 3 | ✓ |
| 4 | ✗ |
| 5 | ✗ |
| 6 | ✗ |
| 7 | ✗ |
| 8 | ✗ |
| 9 | ✗ |
| 10 | ✗ |
| 11 | ✗ |
| 12 | ✗ |
| 13 | ✓ |
| 14 | ✓ |
| 15 | ✓ |
| 16 | ✗ |
| 17 | ✓ |
| 18 | ✓ |
| 19 | ✗ |
| 20 | ✗ |
| 21 | ✗ |
| 22 | ✗ |

| | |
|---|---|
| 23 | ✗ |
| 24 | ✓ |
| 25 | ✗ |
| 26 | ✓ |
| 27 | ✗ |
| 28 | ✗ |
| 29 | ✗ |
| 30 | ✓ |
| 31 | ✗ |
| 32 | ✗ |
| 33 | ✗ |
| 34 | ✗ |
| 35 | ✓ |
| 36 | ✗ |
| 37 | ✗ |
| 38 | ✗ |
| 39 | ✗ |
| 40 | ✗ |
| 41 | ✗ |
| 42 | ✓ |
| 43 | ✗ |
| 44 | ✗ |
| 45 | ✓ |
| 46 | ✓ |
| 47 | ✗ |
| 48 | ✗ |
| 49 | ✗ |
| 50 | ✗ |
| 51 | ✗ |
| 52 | ✗ |
| 53 | ✓ |
| 54 | ✗ |
| 55 | ✗ |
| 56 | ✗ |
| 57 | ✗ |
| 58 | ✗ |

| | |
|---|---|
| 59 | ✗ |
| 60 | ✗ |
| 61 | ✗ |
| 62 | ✓ |
| 63 | ✗ |
| 64 | ✓ |
| 65 | ✗ |
| 66 | ✓ |
| 67 | ✓ |
| **68** | ✗ |
| 69 | ✗ |
| 70 | ✗ |
| 71 | ✗ |
| 72 | ✗ |
| 73 | ✗ |
| 74 | ✗ |
| 75 | ✓ |
| 76 | ✗ |
| 77 | ✗ |
| 78 | ✗ |
| 79 | ✗ |
| 80 | ✗ |
| 81 | ✗ |
| 82 | ✓ |

All contents of this site are © 2024 Passmedicine Limited
Back to top

A 19-year-old man presents with the following rash. He feels well in himself and has no significant past medical history. The patient does mention a sore throat that occurred several weeks ago and resolved itself after a few days.

© Image used on license from DermNet NZ

Given the appearance above, what is the most likely diagnosis?

- Guttate psoriasis
- Lichen planus
- Mycosis fungoides
- Pityriasis rosea
- Pityriasis versicolor

Submit answer

Reference ranges

Score: **28%**

| | |
|---|---|
| 1 | ✗ |
| 2 | ✓ |
| 3 | ✓ |
| 4 | ✗ |
| 5 | ✗ |
| 6 | ✗ |
| 7 | ✗ |
| 8 | ✗ |
| 9 | ✗ |
| 10 | ✗ |
| 11 | ✗ |
| 12 | ✗ |
| 13 | ✓ |
| 14 | ✓ |
| 15 | ✓ |
| 16 | ✗ |
| 17 | ✓ |
| 18 | ✓ |
| 19 | ✗ |
| 20 | ✗ |
| 21 | ✗ |
| 22 | ✗ |
| 23 | ✗ |
| 24 | ✓ |
| 25 | ✗ |
| 26 | ✓ |
| 27 | ✗ |
| 28 | ✗ |
| 29 | ✗ |
| 30 | ✓ |
| 31 | ✗ |
| 32 | ✗ |
| 33 | ✗ |
| 34 | ✗ |

| | |
|---|---|
| 35 | ✓ |
| 36 | ✗ |
| 37 | ✗ |
| 38 | ✗ |
| 39 | ✗ |
| 40 | ✗ |
| 41 | ✗ |
| 42 | ✓ |
| 43 | ✗ |
| 44 | ✗ |
| 45 | ✓ |
| 46 | ✓ |
| 47 | ✗ |
| 48 | ✗ |
| 49 | ✗ |
| 50 | ✗ |
| 51 | - |
| 52 | - |
| 53 | - |
| 54 | - |
| 55 | - |
| 56 | - |
| 57 | - |
| 58 | - |
| 59 | - |
| 60 | - |
| 61 | - |
| 62 | - |
| 63 | - |
| 64 | - |
| 65 | - |
| 66 | - |
| 67 | - |
| 68 | - |
| **69** | - |

All contents of this site are © 2024 Passmedicine Limited

Back to top

A 19-year-old man presents with the following rash. He feels well in himself and has no significant past medical history. The patient does mention a sore throat that occurred several weeks ago and resolved itself after a few days.

© Image used on license from DermNet NZ

Given the appearance above, what is the most likely diagnosis?

| | |
|---|---|
| Guttate psoriasis | 79% |
| Lichen planus | 5% |
| Mycosis fungoides | 3% |
| Pityriasis rosea | 9% |
| Pityriasis versicolor | 3% |

Acute onset of tear-drop scaly papules on trunk and limbs → ?guttate psoriasis

Important for me    Less important

The photo above is typical of guttate psoriasis. Small, red, scaly plaques are visible. Some of the lesions in this photo have a 'tear-drop' appearance which is typical of guttate psoriasis. It classically follows a streptococcal throat infection several weeks prior. Most cases resolve

spontaneously within 2-3 months. Standard psoriasis treatment may be used if needed to help resolve symptoms and appearance.

Lichen planus appears different from the photo above, with flat-topped, shiny, violaceous, polygonal papules, typically clustered around the wrists and ankles. They are overlaid by fine lines called Wickham striae, not the generalised scales seen here.

Mycosis fungoides is the most common type of primary cutaneous T-cell lymphoma. Rather than small, tear-drop lesions as seen here, it presents with poorly-defined, larger, more widespread patches, often with atrophic skin. It often occurs around sun-exposed sites.

Pityriasis rosea is a reasonable differential - many patients report a preceding respiratory tract infection, but with regards to exam questions, this is not common. There is no mention of a herald patch in the question, which precedes the main pityriasis rosea rash by 1-2 weeks. The distribution of lesions typically follows a 'fir-tree' pattern, whereas, in the photo above, the distribution is relatively random.

Pityriasis versicolor is a fungal infection. Rather than the guttate lesions seen here, it leads to patchy, hypopigmented areas.

Discuss | Improve

Next question

## Guttate psoriasis

Guttate psoriasis is more common in children and adolescents. It may be precipitated by a streptococcal infection 2-4 weeks prior to the lesions appearing.

Features
- tear drop papules on the trunk and limbs
  - *gutta* is Latin for drop
  - pink, scaly patches or plques of psoriasis
- tends to be acute onset over days

Management

- most cases resolve spontaneously within 2-3 months
- there is no firm evidence to support the use of antibiotics to eradicate streptococcal infection
- topical agents as per psoriasis
- UVB phototherapy
- tonsillectomy may be necessary with recurrent episodes

## Differentiating guttate psoriasis and pityriasis rosea

| | Guttate psoriasis | Pityriasis rosea |
|---|---|---|
| **Prodrome** | Classically preceded by a streptococcal sore throat 2-4 weeks | Many patients report recent respiratory tract infections but this is not common in questions |
| **Appearance** | 'Tear drop', scaly papules on the trunk and limbs | Herald patch followed 1-2 weeks later by multiple erythematous, slightly raised oval lesions with a fine scale confined to the outer aspects of the lesions.<br><br>May follow a characteristic distribution with the longitudinal diameters of the oval lesions running parallel to the line of Langer. This may produce a 'fir-tree' appearance |
| **Treatment / natural history** | Most cases resolve spontaneously within 2-3 months<br>Topical agents as per psoriasis<br>UVB phototherapy | Self-limiting, resolves after around 6 weeks |

123

Next question

## Textbooks

High-yield textbook

Extended textbook

## Links

Clinical Knowledge Summaries 12 7

Guttate psoriasis guidelines

Dermnet NZ 11 3

Guttate psoriasis

Suggest link Report broken link

## Media

Psoriasis

Osmosis - YouTube 2 0

Report broken media

Score: **25.6%**

| | |
|---|---|
| 1 | ✗ |
| 2 | ✓ |
| 3 | ✓ |
| 4 | ✗ |
| 5 | ✗ |
| 6 | ✗ |
| 7 | ✗ |
| 8 | ✗ |
| 9 | ✗ |
| 10 | ✗ |
| 11 | ✗ |
| 12 | ✗ |
| 13 | ✓ |
| 14 | ✓ |
| 15 | ✓ |
| 16 | ✗ |
| 17 | ✓ |
| 18 | ✓ |
| 19 | ✗ |
| 20 | ✗ |
| 21 | ✗ |
| 22 | ✗ |
| 23 | ✗ |
| 24 | ✓ |
| 25 | ✗ |
| 26 | ✓ |
| 27 | ✗ |
| 28 | ✗ |
| 29 | ✗ |
| 30 | ✓ |
| 31 | ✗ |
| 32 | ✗ |

33 ✗
34 ✗
35 ✓
36 ✗
37 ✗
38 ✗
39 ✗
40 ✗
41 ✗
42 ✓
43 ✗
44 ✗
45 ✓
46 ✓
47 ✗
48 ✗
49 ✗
50 ✗
51 ✗
52 ✗
53 ✓
54 ✗
55 ✗
56 ✗
57 ✗
58 ✗
59 ✗
60 ✗
61 ✗
62 ✓
63 ✗
64 ✓
65 ✗
66 ✓
67 ✓
68 ✗

| | |
|---|---|
| **69** | ✗ |
| 70 | ✗ |
| 71 | ✗ |
| 72 | ✗ |
| 73 | ✗ |
| 74 | ✗ |
| 75 | ✓ |
| 76 | ✗ |
| 77 | ✗ |
| 78 | ✗ |
| 79 | ✗ |
| 80 | ✗ |
| 81 | ✗ |
| 82 | ✓ |

All contents of this site are © 2024 Passmedicine Limited

Back to top

A 67-year-old man presents to his general practitioner with skin lesions over his arms. They are not causing any itchiness or discomfort and have been developing over the past 6 months. He is otherwise well and his only past medical history of note includes hypertension and osteoarthritis.

The man reports he spends his time between the United Kingdom and a holiday home in Spain. He drinks approximately 10 units of alcohol per week and has a 20 pack-year smoking history.

© Image used on license from DermNet NZ

What is the diagnosis?

- Actinic keratoses
- Basal cell carcinoma
- Seborrhoeic dermatitis
- Seborrhoeic keratosis
- Squamous cell carcinoma

Submit answer

Reference ranges

Score: **28%**

| | |
|---|---|
| 1 | ✗ |
| 2 | ✓ |
| 3 | ✓ |
| 4 | ✗ |
| 5 | ✗ |
| 6 | ✗ |
| 7 | ✗ |
| 8 | ✗ |
| 9 | ✗ |
| 10 | ✗ |
| 11 | ✗ |
| 12 | ✗ |
| 13 | ✓ |
| 14 | ✓ |
| 15 | ✓ |
| 16 | ✗ |
| 17 | ✓ |
| 18 | ✓ |
| 19 | ✗ |
| 20 | ✗ |
| 21 | ✗ |
| 22 | ✗ |
| 23 | ✗ |
| 24 | ✓ |
| 25 | ✗ |
| 26 | ✓ |
| 27 | ✗ |
| 28 | ✗ |
| 29 | ✗ |
| 30 | ✓ |

| | |
|---|---|
| 31 | ✗ |
| 32 | ✗ |
| 33 | ✗ |
| 34 | ✗ |
| 35 | ✓ |
| 36 | ✗ |
| 37 | ✗ |
| 38 | ✗ |
| 39 | ✗ |
| 40 | ✗ |
| 41 | ✗ |
| 42 | ✓ |
| 43 | ✗ |
| 44 | ✗ |
| 45 | ✓ |
| 46 | ✓ |
| 47 | ✗ |
| 48 | ✗ |
| 49 | ✗ |
| 50 | ✗ |
| 51 | - |
| 52 | - |
| 53 | - |
| 54 | - |
| 55 | - |
| 56 | - |
| 57 | - |
| 58 | - |
| 59 | - |
| 60 | - |
| 61 | - |
| 62 | - |
| 63 | - |
| 64 | - |
| 65 | - |
| 66 | - |
| 67 | - |
| 68 | - |

| | |
|---|---|
| 69 | - |
| **70** | - |

All contents of this site are © 2024 Passmedicine Limited

A 67-year-old man presents to his general practitioner with skin lesions over his arms. They are not causing any itchiness or discomfort and have been developing over the past 6 months. He is otherwise well and his only past medical history of note includes hypertension and osteoarthritis.

The man reports he spends his time between the United Kingdom and a holiday home in Spain. He drinks approximately 10 units of alcohol per week and has a 20 pack-year smoking history.

© Image used on license from DermNet NZ

What is the diagnosis?

| | |
|---|---|
| Actinic keratoses | 83% |
| Basal cell carcinoma | 1% |
| Seborrhoeic dermatitis | 4% |
| Seborrhoeic keratosis | 11% |
| Squamous cell carcinoma | 1% |

The picture in this question depicts actinic keratoses which is the correct answer here. Sufferers often have several scaly/crusty lesions on sun-exposed areas such as the arms or head. As this man spends significant time in Spain, he is at an increased risk for developing these lesions.

Basal cell carcinomas classically present as a single pearly lump. There are several lesions in this instance and these are not consistent with this appearance. Basal cell carcinoma is therefore an incorrect answer.

Seborrhoeic dermatitis is a form of dermatitis triggered by Malassezia yeasts. This typically causes erythematous regions over the scalp, face, chest, and body creases. The distribution of the rash here as well as the scaly and crusty appearance is consistent with a diagnosis of actinic keratoses rather than seborrhoeic dermatitis.

Seborrhoeic keratoses are brown papules or plaques with a waxy appearance of unclear aetiology. The red and pink appearances of these lesions here are not consistent with this pathology.

Squamous cell carcinoma (SCC) will usually present as a solitary lesion and can arise from pre-existing actinic keratoses. An SCC will typically be larger than a lesion in actinic keratoses and may become tender or ulcerated. As these features are not present here, actinic keratoses is the correct answer.

Discuss (1) | Improve

Next question >

## Actinic keratoses

Actinic, or solar, keratoses (AK) is a common premalignant skin lesion that develops as a consequence of chronic sun exposure

Features

- small, crusty or scaly, lesions
- may be pink, red, brown or the same colour as the skin
- typically on sun-exposed areas e.g. temples of head
- multiple lesions may be present

Management options include

- prevention of further risk: e.g. sun avoidance, sun cream

- fluorouracil cream: typically a 2 to 3 week course. The skin will become red and inflamed - sometimes topical hydrocortisone is given following fluorouracil to help settle the inflammation
- topical diclofenac: may be used for mild AKs. Moderate efficacy but much fewer side-effects
- topical imiquimod: trials have shown good efficacy
- cryotherapy
- curettage and cautery

+ Q 123

Next question >

## Textbooks

High-yield textbook

Extended textbook

## Links

British Association of Dermatologists 9 9

2017 Actinic keratoses guidelines

DermNet NZ 27 11

Actinic keratoses

Primary Care Dermatology Society 14 5

Actinic keratosis

Suggest link

Report broken link

Score: **25.6%**

| | |
|---|---|
| 1 | ✗ |
| 2 | ✓ |
| 3 | ✓ |
| 4 | ✗ |
| 5 | ✗ |
| 6 | ✗ |
| 7 | ✗ |
| 8 | ✗ |
| 9 | ✗ |
| 10 | ✗ |
| 11 | ✗ |
| 12 | ✗ |
| 13 | ✓ |
| 14 | ✓ |
| 15 | ✓ |
| 16 | ✗ |
| 17 | ✓ |
| 18 | ✓ |
| 19 | ✗ |
| 20 | ✗ |
| 21 | ✗ |
| 22 | ✗ |
| 23 | ✗ |
| 24 | ✓ |
| 25 | ✗ |
| 26 | ✓ |
| 27 | ✗ |
| 28 | ✗ |
| 29 | ✗ |
| 30 | ✓ |
| 31 | ✗ |
| 32 | ✗ |

| | |
|---|---|
| 33 | ✗ |
| 34 | ✗ |
| 35 | ✓ |
| 36 | ✗ |
| 37 | ✗ |
| 38 | ✗ |
| 39 | ✗ |
| 40 | ✗ |
| 41 | ✗ |
| 42 | ✓ |
| 43 | ✗ |
| 44 | ✗ |
| 45 | ✓ |
| 46 | ✓ |
| 47 | ✗ |
| 48 | ✗ |
| 49 | ✗ |
| 50 | ✗ |
| 51 | ✗ |
| 52 | ✗ |
| 53 | ✓ |
| 54 | ✗ |
| 55 | ✗ |
| 56 | ✗ |
| 57 | ✗ |
| 58 | ✗ |
| 59 | ✗ |
| 60 | ✗ |
| 61 | ✗ |
| 62 | ✓ |
| 63 | ✗ |
| 64 | ✓ |
| 65 | ✗ |
| 66 | ✓ |
| 67 | ✓ |
| 68 | ✗ |

| | |
|---|---|
| 69 | ✗ |
| **70** | ✗ |
| 71 | ✗ |
| 72 | ✗ |
| 73 | ✗ |
| 74 | ✗ |
| 75 | ✓ |
| 76 | ✗ |
| 77 | ✗ |
| 78 | ✗ |
| 79 | ✗ |
| 80 | ✗ |
| 81 | ✗ |
| 82 | ✓ |

All contents of this site are © 2024 Passmedicine Limited

Back to top

A 24-year-old man who is normally fit and well presents with a new skin rash. He has no personal or family history of skin conditions. It started a couple of weeks ago with a lesion he noted on the hip, which is a patch approximately 4cm in diameter, mildly erythematous, with some mild scaling around the edge. He awoke this morning to find multiple smaller similar lesions, mainly on his back. The lesions are asymptomatic. How should this condition be managed?

- Topical antifungal eg. ketoconazole shampoo
- Mild topical steroid
- No treatment required
- Refer for phototherapy
- Oral steroids

Submit answer

Reference ranges

Score: **28%**

| | |
|---|---|
| 1 | ✗ |
| 2 | ✓ |
| 3 | ✓ |
| 4 | ✗ |
| 5 | ✗ |
| 6 | ✗ |
| 7 | ✗ |
| 8 | ✗ |
| 9 | ✗ |

| | |
|---|---|
| 10 | ✗ |
| 11 | ✗ |
| 12 | ✗ |
| 13 | ✓ |
| 14 | ✓ |
| 15 | ✓ |
| 16 | ✗ |
| 17 | ✓ |
| 18 | ✓ |
| 19 | ✗ |
| 20 | ✗ |
| 21 | ✗ |
| 22 | ✗ |
| 23 | ✗ |
| 24 | ✓ |
| 25 | ✗ |
| 26 | ✓ |
| 27 | ✗ |
| 28 | ✗ |
| 29 | ✗ |
| 30 | ✓ |
| 31 | ✗ |
| 32 | ✗ |
| 33 | ✗ |
| 34 | ✗ |
| 35 | ✓ |
| 36 | ✗ |
| 37 | ✗ |
| 38 | ✗ |
| 39 | ✗ |
| 40 | ✗ |
| 41 | ✗ |
| 42 | ✓ |
| 43 | ✗ |
| 44 | ✗ |
| 45 | ✓ |

| | |
|---|---|
| 46 | ✓ |
| 47 | ✗ |
| 48 | ✗ |
| 49 | ✗ |
| 50 | ✗ |
| 51 | - |
| 52 | - |
| 53 | - |
| 54 | - |
| 55 | - |
| 56 | - |
| 57 | - |
| 58 | - |
| 59 | - |
| 60 | - |
| 61 | - |
| 62 | - |
| 63 | - |
| 64 | - |
| 65 | - |
| 66 | - |
| 67 | - |
| 68 | - |
| 69 | - |
| 70 | - |
| **71** | - |

All contents of this site are © 2024 Passmedicine Limited

Back to top

A 24-year-old man who is normally fit and well presents with a new skin rash. He has no personal or family history of skin conditions. It started a couple of weeks ago with a lesion he noted on the hip, which is a patch approximately 4cm in diameter, mildly erythematous, with some mild scaling around the edge. He awoke this morning to find multiple smaller similar lesions, mainly on his back. The lesions are asymptomatic. How should this condition be managed?

| | |
|---|---|
| Topical antifungal eg. ketoconazole shampoo | 24% |
| Mild topical steroid | 9% |
| No treatment required | 65% |
| Refer for phototherapy | 1% |
| Oral steroids | 1% |

This is a typical history of pityriasis rosea, a self-limiting skin condition which most often occurs in teenagers and young people. The cause is unclear but thought to be viral in nature. An initial solitary 'herald patch' is followed some days to weeks later by multiple smaller lesions to the trunk. It is usually asymptomatic, in which case no treatment is required, but may cause a mild itch, in which case topical steroids and oral antihistamines could be considered. Referral to dermatology for phototherapy may be considered in extensive disease (some limited evidence of benefit).

Discuss Improve

Next question

# Pityriasis rosea

Pityriasis rosea describes an acute, self-limiting rash which tends to affect young adults. The aetiology is not fully understood but is thought that herpes hominis virus 7 (HHV-7) may play a role.

Features

- in the majority of patients there is no prodrome, but a minority may give a history of a recent viral infection
- herald patch (usually on trunk)
- followed by erythematous, oval, scaly patches which follow a characteristic distribution with the longitudinal diameters of the oval lesions running parallel to the line of Langer. This may produce a 'fir-tree' appearance

Management
- self-limiting - usually disappears after 6-12 weeks

## Differentiating guttate psoriasis and pityriasis rosea

| | Guttate psoriasis | Pityriasis rosea |
|---|---|---|
| **Prodrome** | Classically preceded by a streptococcal sore throat 2-4 weeks | Many patients report recent respiratory tract infections but this is not common in questions |
| **Appearance** | 'Tear drop', scaly papules on the trunk and limbs | Herald patch followed 1-2 weeks later by multiple erythematous, slightly raised oval lesions with a fine scale confined to the outer aspects of the lesions.<br><br>May follow a characteristic distribution with the longitudinal diameters of the oval lesions running parallel to the line of Langer. This may produce a 'fir-tree' appearance |

| | Guttate psoriasis | Pityriasis rosea |
|---|---|---|
| **Treatment / natural history** | Most cases resolve spontaneously within 2-3 months<br>Topical agents as per psoriasis<br>UVB phototherapy | Self-limiting, resolves after around 6 weeks |

AI + Q 123

Next question >

**Textbooks**

High-yield textbook

Extended textbook

**Links**

Clinical Knowledge Summaries 9 6

Pityriasis rosea

DermNet NZ 11 4

Pityriasis rosea

Suggest link Report broken link

Score: **25.6%**

| | |
|---|---|
| 1 | ✗ |
| 2 | ✓ |
| 3 | ✓ |
| 4 | ✗ |
| 5 | ✗ |
| 6 | ✗ |
| 7 | ✗ |
| 8 | ✗ |
| 9 | ✗ |
| 10 | ✗ |
| 11 | ✗ |
| 12 | ✗ |
| 13 | ✓ |
| 14 | ✓ |
| 15 | ✓ |
| 16 | ✗ |
| 17 | ✓ |
| 18 | ✓ |
| 19 | ✗ |
| 20 | ✗ |
| 21 | ✗ |
| 22 | ✗ |
| 23 | ✗ |
| 24 | ✓ |
| 25 | ✗ |
| 26 | ✓ |
| 27 | ✗ |
| 28 | ✗ |
| 29 | ✗ |
| 30 | ✓ |
| 31 | ✗ |
| 32 | ✗ |
| 33 | ✗ |

| | |
|---|---|
| 34 | ✗ |
| 35 | ✓ |
| 36 | ✗ |
| 37 | ✗ |
| 38 | ✗ |
| 39 | ✗ |
| 40 | ✗ |
| 41 | ✗ |
| 42 | ✓ |
| 43 | ✗ |
| 44 | ✗ |
| 45 | ✓ |
| 46 | ✓ |
| 47 | ✗ |
| 48 | ✗ |
| 49 | ✗ |
| 50 | ✗ |
| 51 | ✗ |
| 52 | ✗ |
| 53 | ✓ |
| 54 | ✗ |
| 55 | ✗ |
| 56 | ✗ |
| 57 | ✗ |
| 58 | ✗ |
| 59 | ✗ |
| 60 | ✗ |
| 61 | ✗ |
| 62 | ✓ |
| 63 | ✗ |
| 64 | ✓ |
| 65 | ✗ |
| 66 | ✓ |
| 67 | ✓ |
| 68 | ✗ |
| 69 | ✗ |

| | |
|---|---|
| 70 | ✗ |
| **71** | ✗ |
| 72 | ✗ |
| 73 | ✗ |
| 74 | ✗ |
| 75 | ✓ |
| 76 | ✗ |
| 77 | ✗ |
| 78 | ✗ |
| 79 | ✗ |
| 80 | ✗ |
| 81 | ✗ |
| 82 | ✓ |

All contents of this site are © 2024 Passmedicine Limited

Back to top

A 67-year-old man presents with a facial rash, which is more noticeable in the summer months. He describes flushing following sun exposure in the garden and eating spicy foods.

On examination, he has an erythematous, papular rash around his cheeks and forehead. There are visible pustules around his forehead and cheeks. There are no comedones and the rash is isolated to the face.

Which of the following would be the most appropriate first-line treatment?

- Topical hydrocortisone
- Topical ivermectin
- Oral tetracycline
- Azelaic acid
- Emollient cream

Submit answer

Reference ranges

Score: **28%**

| | |
|---|---|
| 1 | ✗ |
| 2 | ✓ |
| 3 | ✓ |
| 4 | ✗ |
| 5 | ✗ |
| 6 | ✗ |

| | |
|---|---|
| 7 | ✗ |
| 8 | ✗ |
| 9 | ✗ |
| 10 | ✗ |
| 11 | ✗ |
| 12 | ✗ |
| 13 | ✓ |
| 14 | ✓ |
| 15 | ✓ |
| 16 | ✗ |
| 17 | ✓ |
| 18 | ✓ |
| 19 | ✗ |
| 20 | ✗ |
| 21 | ✗ |
| 22 | ✗ |
| 23 | ✗ |
| 24 | ✓ |
| 25 | ✗ |
| 26 | ✓ |
| 27 | ✗ |
| 28 | ✗ |
| 29 | ✗ |
| 30 | ✓ |
| 31 | ✗ |
| 32 | ✗ |
| 33 | ✗ |
| 34 | ✗ |
| 35 | ✓ |
| 36 | ✗ |
| 37 | ✗ |
| 38 | ✗ |
| 39 | ✗ |
| 40 | ✗ |
| 41 | ✗ |
| 42 | ✓ |

| | |
|---|---|
| 43 | ✗ |
| 44 | ✗ |
| 45 | ✓ |
| 46 | ✓ |
| 47 | ✗ |
| 48 | ✗ |
| 49 | ✗ |
| 50 | ✗ |
| 51 | - |
| 52 | - |
| 53 | - |
| 54 | - |
| 55 | - |
| 56 | - |
| 57 | - |
| 58 | - |
| 59 | - |
| 60 | - |
| 61 | - |
| 62 | - |
| 63 | - |
| 64 | - |
| 65 | - |
| 66 | - |
| 67 | - |
| 68 | - |
| 69 | - |
| 70 | - |
| 71 | - |
| **72** | - |

All contents of this site are © 2024 Passmedicine Limited

Back to top

A 67-year-old man presents with a facial rash, which is more noticeable in the summer months. He describes flushing following sun exposure in the garden and eating spicy foods.

On examination, he has an erythematous, papular rash around his cheeks and forehead. There are visible pustules around his forehead and cheeks. There are no comedones and the rash is isolated to the face.

Which of the following would be the most appropriate first-line treatment?

| | |
|---|---|
| Topical hydrocortisone | 7% |
| Topical ivermectin | 71% |
| Oral tetracycline | 11% |
| Azelaic acid | 6% |
| Emollient cream | 5% |

Rosacea: topical ivermectin is first-line for patients mild papules and/or pustules

Important for me Less important

This rash is typical of rosacea. This can present as flushing, erythema, telangiectasia and rhinophyma (enlarged nose).

For mild symptoms, topical therapy such as ivermectin gel is first-line. Azelaic acid can also be used but is usually not as well tolerated, especially for patients with sensitive skin.

For moderate or severe symptoms, an oral tetracycline or erythromycin can be used.

Discuss (2) Improve

Next question

# Rosacea

Rosacea (sometimes referred to as acne rosacea) is a chronic skin disease of unknown aetiology.

Features

- typically affects nose, cheeks and forehead
- flushing is often first symptom
- telangiectasia are common
- later develops into persistent erythema with papules and pustules
- rhinophyma
- ocular involvement: blepharitis
- sunlight may exacerbate symptoms

Management

- simple measures
  - recommend daily application of a high-factor sunscreen
  - camouflage creams may help conceal redness
- predominant erythema/flushing
  - topical brimonidine gel may be considered for patients with predominant flushing but limited telangiectasia
  - brimonidine is a topical alpha-adrenergic agonist
  - this can be used on an 'as required basis' to temporarily reduce redness
  - it typically reduces redness within 30 minutes, reaching peak action at 3-6 hours, after which the redness returns to the baseline
- mild-to-moderate papules and/or pustules
  - topical ivermectin is first-line
  - alternatives include: topical metronidazole or topical azelaic acid
- moderate-to-severe papules and/or pustules
  - combination of topical ivermectin + oral doxycycline

Referral should be considered if

- symptoms have not improved with optimal management in primary care
  - laser therapy may be appropriate for patients with prominent telangiectasia

- patients with a rhinophyma

123

Next question

## Textbooks

High-yield textbook

Extended textbook

## Links

DermNet NZ 11 17

Rhinophyma

BNF 10 11

Acne rosacea

Dermnet NZ 23 13

Acne rosacea

Clinical Knowledge Summaries 19 10

Acne rosacea guidelines

Primary Care Dermatology Society 27 9

Rosacea review

Suggest link Report broken link

Score: **25.6%**

| | |
|---|---|
| 1 | ✗ |
| 2 | ✓ |
| 3 | ✓ |
| 4 | ✗ |
| 5 | ✗ |
| 6 | ✗ |
| 7 | ✗ |
| 8 | ✗ |
| 9 | ✗ |
| 10 | ✗ |
| 11 | ✗ |
| 12 | ✗ |
| 13 | ✓ |
| 14 | ✓ |
| 15 | ✓ |
| 16 | ✗ |
| 17 | ✓ |
| 18 | ✓ |
| 19 | ✗ |
| 20 | ✗ |
| 21 | ✗ |
| 22 | ✗ |
| 23 | ✗ |
| 24 | ✓ |
| 25 | ✗ |
| 26 | ✓ |
| 27 | ✗ |
| 28 | ✗ |
| 29 | ✗ |

30 ✓
31 ✗
32 ✗
33 ✗
34 ✗
35 ✓
36 ✗
37 ✗
38 ✗
39 ✗
40 ✗
41 ✗
42 ✓
43 ✗
44 ✗
45 ✓
46 ✓
47 ✗
48 ✗
49 ✗
50 ✗
51 ✗
52 ✗
53 ✓
54 ✗
55 ✗
56 ✗
57 ✗
58 ✗
59 ✗
60 ✗
61 ✗
62 ✓
63 ✗
64 ✓
65 ✗

| | |
|---|---|
| 66 | ✓ |
| 67 | ✓ |
| 68 | ✗ |
| 69 | ✗ |
| 70 | ✗ |
| 71 | ✗ |
| **72** | ✗ |
| 73 | ✗ |
| 74 | ✗ |
| 75 | ✓ |
| 76 | ✗ |
| 77 | ✗ |
| 78 | ✗ |
| 79 | ✗ |
| 80 | ✗ |
| 81 | ✗ |
| 82 | ✓ |

All contents of this site are © 2024 Passmedicine Limited

Back to top

A 25-year-old woman attends dermatology clinic for review of eczema. She has been suffering from eczema since she was young and has found the recent weather has been making her skin extremely dry and she finds that despite emollient application four times each day her skin is not improving. She also has asthma but this is well controlled and she rarely needs her inhaler. Apart from lotion emollients she is not using any creams currently. In the past she has needed topical steroids to manage her eczema when becomes very irritated. On examination the skin on over her flexural folds is very dry but does not appear irritated. What can be advised to help manage the dry skin?

- Advise to wear wool
- Advise strong topical steroid use
- Advise to change to cream rather than lotion emollient
- Prescribe topical tacrolimus
- Advise to change to a urea containing emollient

Submit answer

Reference ranges

Score: **28%**

| | |
|---|---|
| 1 | ✗ |
| 2 | ✓ |
| 3 | ✓ |
| 4 | ✗ |
| 5 | ✗ |
| 6 | ✗ |

| | |
|---|---|
| 7 | ✗ |
| 8 | ✗ |
| 9 | ✗ |
| 10 | ✗ |
| 11 | ✗ |
| 12 | ✗ |
| 13 | ✓ |
| 14 | ✓ |
| 15 | ✓ |
| 16 | ✗ |
| 17 | ✓ |
| 18 | ✓ |
| 19 | ✗ |
| 20 | ✗ |
| 21 | ✗ |
| 22 | ✗ |
| 23 | ✗ |
| 24 | ✓ |
| 25 | ✗ |
| 26 | ✓ |
| 27 | ✗ |
| 28 | ✗ |
| 29 | ✗ |
| 30 | ✓ |
| 31 | ✗ |
| 32 | ✗ |
| 33 | ✗ |
| 34 | ✗ |
| 35 | ✓ |
| 36 | ✗ |
| 37 | ✗ |
| 38 | ✗ |
| 39 | ✗ |
| 40 | ✗ |
| 41 | ✗ |
| 42 | ✓ |

| | |
|---|---|
| 43 | ✗ |
| 44 | ✗ |
| 45 | ✓ |
| 46 | ✓ |
| 47 | ✗ |
| 48 | ✗ |
| 49 | ✗ |
| 50 | ✗ |
| 51 | - |
| 52 | - |
| 53 | - |
| 54 | - |
| 55 | - |
| 56 | - |
| 57 | - |
| 58 | - |
| 59 | - |
| 60 | - |
| 61 | - |
| 62 | - |
| 63 | - |
| 64 | - |
| 65 | - |
| 66 | - |
| 67 | - |
| 68 | - |
| 69 | - |
| 70 | - |
| 71 | - |
| 72 | - |
| **73** | - |

All contents of this site are © 2024 Passmedicine Limited

Back to top

A 25-year-old woman attends dermatology clinic for review of eczema. She has been suffering from eczema since she was young and has found the recent weather has been making her skin extremely dry and she finds that despite emollient application four times each day her skin is not improving. She also has asthma but this is well controlled and she rarely needs her inhaler. Apart from lotion emollients she is not using any creams currently. In the past she has needed topical steroids to manage her eczema when becomes very irritated. On examination the skin on over her flexural folds is very dry but does not appear irritated. What can be advised to help manage the dry skin?

- Advise to wear wool — 3%
- Advise strong topical steroid use — 11%
- Advise to change to cream rather than lotion emollient — 39%
- Prescribe topical tacrolimus — 7%
- Advise to change to a urea containing emollient — 41%

Adding urea to emollients increases moisturising effect, but can be inflammatory

Important for me Less important

Asking her to change to a urea containing emollient can help control dryness and itch as this can provide a greater moisturizing effect. Using urea containing emollients can increase inflammation and so in a acute inflammatory flare this would be inappropriate and such patients should be treated with topical steroids.

Changing to cream emollients would be appropriate for weeping skin. Tacrolimus can be used by dermatologists for refractory eczema.

Discuss (5) Improve

Next question

# Eczema: management

## Management

Avoidance of triggers and skin care education

- Key components include avoiding known irritants, allergens, and providing guidance on gentle skin care routines.

Emollients

- Integral to all treatment plans, regardless of eczema severity.
- Advise on liberal and regular use, even when the skin is clear, to maintain skin hydration and barrier function.
- Selection of emollient should be based on patient preference to improve adherence
    - Creams are generally preferred by most people - adherence is key so
    - Ointments provide the strongest emollient effect and may be more effective. However, they are greasy and so may be more suitable for use at night.

Topical therapies

- Topical corticosteroids
    - Vital for managing flare-ups, with potency tailored to the severity and lesion location
    - Example treatments recommended by NICE:
    - Mild eczema: hydrocortisone 1%
    - Moderate eczema: betamethasone valerate 0.025% or clobetasone butyrate 0.05%
    - Severe eczema: betamethasone valerate 0.1%
- Topical calcineurin inhibitors
    - Suitable for sensitive skin regions; include agents like tacrolimus and pimecrolimus.
- Topical antimicrobials
    - Used when there is clinical evidence of secondary infection.

Systemic therapies

- Indicated for severe or unresponsive cases.
- Oral corticosteroids:
    - Employed cautiously for acute severe exacerbations.
- Immunosuppressants:
    - Ciclosporin, methotrexate, or azathioprine are reserved for chronic, severe eczema.
- Biologic therapies:
    - Dupilumab is an advanced option for cases unresponsive to conventional therapy.

Phototherapy

- Considered for extensive eczema

## Prognosis

Prognostic markers associated with severe disease include:

- onset at age 3-6 months
- severe disease in childhood
- associated asthma or hay fever
- small family size
- high IgE serum levels

123

Next question

### Textbooks

High-yield textbook

Extended textbook

### Links

British Association of Dermatologists 1 1

Atopic eczema guidelines

Clinical Knowledge Summaries 0 0

Atopic eczema

Suggest link

Report broken link

**Media**

Eczema

Osmosis - YouTube 👍 2 👎 0

Report broken media

Score: **25.6%**

| | |
|---|---|
| 1 | ✗ |
| 2 | ✓ |
| 3 | ✓ |
| 4 | ✗ |
| 5 | ✗ |
| 6 | ✗ |
| 7 | ✗ |
| 8 | ✗ |
| 9 | ✗ |
| 10 | ✗ |
| 11 | ✗ |
| 12 | ✗ |
| 13 | ✓ |
| 14 | ✓ |
| 15 | ✓ |
| 16 | ✗ |
| 17 | ✓ |
| 18 | ✓ |
| 19 | ✗ |
| 20 | ✗ |
| 21 | ✗ |
| 22 | ✗ |

| | |
|---|---|
| 23 | ✗ |
| 24 | ✓ |
| 25 | ✗ |
| 26 | ✓ |
| 27 | ✗ |
| 28 | ✗ |
| 29 | ✗ |
| 30 | ✓ |
| 31 | ✗ |
| 32 | ✗ |
| 33 | ✗ |
| 34 | ✗ |
| 35 | ✓ |
| 36 | ✗ |
| 37 | ✗ |
| 38 | ✗ |
| 39 | ✗ |
| 40 | ✗ |
| 41 | ✗ |
| 42 | ✓ |
| 43 | ✗ |
| 44 | ✗ |
| 45 | ✓ |
| 46 | ✓ |
| 47 | ✗ |
| 48 | ✗ |
| 49 | ✗ |
| 50 | ✗ |
| 51 | ✗ |
| 52 | ✗ |
| 53 | ✓ |
| 54 | ✗ |
| 55 | ✗ |
| 56 | ✗ |
| 57 | ✗ |
| 58 | ✗ |

| | |
|---|---|
| 59 | ✗ |
| 60 | ✗ |
| 61 | ✗ |
| 62 | ✓ |
| 63 | ✗ |
| 64 | ✓ |
| 65 | ✗ |
| 66 | ✓ |
| 67 | ✓ |
| 68 | ✗ |
| 69 | ✗ |
| 70 | ✗ |
| 71 | ✗ |
| 72 | ✗ |
| **73** | ✗ |
| 74 | ✗ |
| 75 | ✓ |
| 76 | ✗ |
| 77 | ✗ |
| 78 | ✗ |
| 79 | ✗ |
| 80 | ✗ |
| 81 | ✗ |
| 82 | ✓ |

All contents of this site are © 2024 Passmedicine Limited

A 41-year-old man presents with an itchy rash over his arms and abdomen. It has got gradually worse over the past three days.

© Image used on license from DermNet NZ

What is the most likely diagnosis?

- Scabies
- Pityriasis rosea
- Erythema multiforme
- Urticaria
- Guttate psoriasis

Submit answer

Reference ranges

Score: **28%**

| | |
|---|---|
| 1 | ✗ |
| 2 | ✓ |
| 3 | ✓ |
| 4 | ✗ |
| 5 | ✗ |
| 6 | ✗ |
| 7 | ✗ |
| 8 | ✗ |
| 9 | ✗ |
| 10 | ✗ |
| 11 | ✗ |
| 12 | ✗ |
| 13 | ✓ |
| 14 | ✓ |
| 15 | ✓ |
| 16 | ✗ |
| 17 | ✓ |
| 18 | ✓ |
| 19 | ✗ |
| 20 | ✗ |
| 21 | ✗ |
| 22 | ✗ |
| 23 | ✗ |
| 24 | ✓ |
| 25 | ✗ |
| 26 | ✓ |
| 27 | ✗ |
| 28 | ✗ |
| 29 | ✗ |
| 30 | ✓ |
| 31 | ✗ |
| 32 | ✗ |
| 33 | ✗ |

| | |
|---|---|
| 34 | ✗ |
| 35 | ✓ |
| 36 | ✗ |
| 37 | ✗ |
| 38 | ✗ |
| 39 | ✗ |
| 40 | ✗ |
| 41 | ✗ |
| 42 | ✓ |
| 43 | ✗ |
| 44 | ✗ |
| 45 | ✓ |
| 46 | ✓ |
| 47 | ✗ |
| 48 | ✗ |
| 49 | ✗ |
| 50 | ✗ |
| 51 | - |
| 52 | - |
| 53 | - |
| 54 | - |
| 55 | - |
| 56 | - |
| 57 | - |
| 58 | - |
| 59 | - |
| 60 | - |
| 61 | - |
| 62 | - |
| 63 | - |
| 64 | - |
| 65 | - |
| 66 | - |
| 67 | - |
| 68 | - |
| 69 | - |
| 70 | - |
| 71 | - |

72 -
73 -
**74** -

All contents of this site are © 2024 Passmedicine Limited

A 41-year-old man presents with an itchy rash over his arms and abdomen. It has got gradually worse over the past three days.

© Image used on license from DermNet NZ

What is the most likely diagnosis?

| | |
|---|---|
| Scabies | 29% |
| Pityriasis rosea | 24% |
| Erythema multiforme | 6% |
| Urticaria | 7% |
| Guttate psoriasis | 34% |

The linear burrows of the scabies mite are clearly seen on this image.

Discuss (8) | Improve

Next question

# Scabies

Scabies is caused by the mite *Sarcoptes scabiei* and is spread by prolonged skin contact. It typically affects children and young adults.

The scabies mite burrows into the skin, laying its eggs in the stratum corneum. The intense pruritus associated with scabies is due to a delayed-type IV hypersensitivity reaction to mites/eggs which occurs about 30 days after the initial infection.

Features
- widespread pruritus
- linear burrows on the side of fingers, interdigital webs and flexor aspects of the wrist
- in infants, the face and scalp may also be affected
- secondary features are seen due to scratching: excoriation, infection

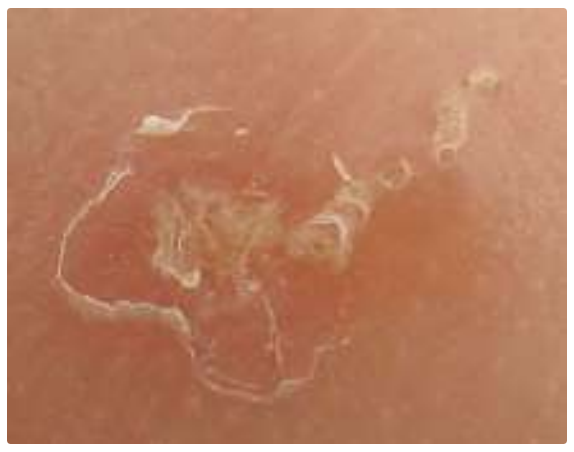

Management
- permethrin 5% is first-line
- malathion 0.5% is second-line
- give appropriate guidance on use (see below)
- pruritus persists for up to 4-6 weeks post eradication

Patient guidance on treatment
- avoid close physical contact with others until treatment is complete
- all household and close physical contacts should be treated at the same time, even if asymptomatic
- launder, iron or tumble dry clothing, bedding, towels, etc., on the first day of treatment to kill off mites.

The BNF advises to apply the insecticide to all areas, including the face and scalp, contrary to the manufacturer's recommendation. Patients should be given the following instructions:

- apply the insecticide cream or liquid to cool, dry skin
- pay close attention to areas between fingers and toes, under nails, armpit area, creases of the skin such as at the wrist and elbow
- allow to dry and leave on the skin for 8-12 hours for permethrin, or for 24 hours for malathion, before washing off
- reapply if insecticide is removed during the treatment period, e.g. If wash hands, change nappy, etc
- repeat treatment 7 days later

## Crusted (Norwegian) scabies

Crusted scabies is seen in patients with suppressed immunity, especially HIV.

© Image used on license from DermNet NZ

The crusted skin will be teeming with hundreds of thousands of organisms.

Ivermectin is the treatment of choice and isolation is essential

+ Q 123

Next question ›

## Textbooks

High-yield textbook

Extended textbook

## Links

Clinical Knowledge Summaries 19 14

Scabies guidelines

Suggest link Report broken link

Score: **25.6%**

| | |
|---|---|
| 1 | ✗ |
| 2 | ✓ |
| 3 | ✓ |
| 4 | ✗ |
| 5 | ✗ |
| 6 | ✗ |
| 7 | ✗ |
| 8 | ✗ |
| 9 | ✗ |
| 10 | ✗ |
| 11 | ✗ |
| 12 | ✗ |
| 13 | ✓ |
| 14 | ✓ |
| 15 | ✓ |
| 16 | ✗ |
| 17 | ✓ |
| 18 | ✓ |

| | |
|---|---|
| 19 | ✗ |
| 20 | ✗ |
| 21 | ✗ |
| 22 | ✗ |
| 23 | ✗ |
| 24 | ✓ |
| 25 | ✗ |
| 26 | ✓ |
| 27 | ✗ |
| 28 | ✗ |
| 29 | ✗ |
| 30 | ✓ |
| 31 | ✗ |
| 32 | ✗ |
| 33 | ✗ |
| 34 | ✗ |
| 35 | ✓ |
| 36 | ✗ |
| 37 | ✗ |
| 38 | ✗ |
| 39 | ✗ |
| 40 | ✗ |
| 41 | ✗ |
| 42 | ✓ |
| 43 | ✗ |
| 44 | ✗ |
| 45 | ✓ |
| 46 | ✓ |
| 47 | ✗ |
| 48 | ✗ |
| 49 | ✗ |
| 50 | ✗ |
| 51 | ✗ |
| 52 | ✗ |
| 53 | ✓ |
| 54 | ✗ |

| | |
|---|---|
| 55 | ✗ |
| 56 | ✗ |
| 57 | ✗ |
| 58 | ✗ |
| 59 | ✗ |
| 60 | ✗ |
| 61 | ✗ |
| 62 | ✓ |
| 63 | ✗ |
| 64 | ✓ |
| 65 | ✗ |
| 66 | ✓ |
| 67 | ✓ |
| 68 | ✗ |
| 69 | ✗ |
| 70 | ✗ |
| 71 | ✗ |
| 72 | ✗ |
| 73 | ✗ |
| **74** | ✗ |
| 75 | ✓ |
| 76 | ✗ |
| 77 | ✗ |
| 78 | ✗ |
| 79 | ✗ |
| 80 | ✗ |
| 81 | ✗ |
| 82 | ✓ |

All contents of this site are © 2024 Passmedicine Limited

Back to top

A 34-year-old woman presents with a rash on her face. She has been feeling generally unwell for around three months with lethargy and has a variety of joint pains

© Image used on license from DermNet NZ

What is the most likely diagnosis?

- Impetigo
- Perioral dermatitis
- Sarcoidosis
- Acne rosacea
- Systemic lupus erythematosus

Submit answer

Reference ranges

Score: **28%**

| | |
|---|---|
| 1 | ✗ |
| 2 | ✓ |
| 3 | ✓ |
| 4 | ✗ |
| 5 | ✗ |
| 6 | ✗ |
| 7 | ✗ |
| 8 | ✗ |
| 9 | ✗ |
| 10 | ✗ |
| 11 | ✗ |
| 12 | ✗ |
| 13 | ✓ |
| 14 | ✓ |
| 15 | ✓ |
| 16 | ✗ |
| 17 | ✓ |
| 18 | ✓ |
| 19 | ✗ |
| 20 | ✗ |
| 21 | ✗ |
| 22 | ✗ |
| 23 | ✗ |
| 24 | ✓ |
| 25 | ✗ |
| 26 | ✓ |
| 27 | ✗ |
| 28 | ✗ |
| 29 | ✗ |
| 30 | ✓ |
| 31 | ✗ |
| 32 | ✗ |
| 33 | ✗ |
| 34 | ✗ |
| 35 | ✓ |

| | |
|---|---|
| 36 | ✗ |
| 37 | ✗ |
| 38 | ✗ |
| 39 | ✗ |
| 40 | ✗ |
| 41 | ✗ |
| 42 | ✓ |
| 43 | ✗ |
| 44 | ✗ |
| 45 | ✓ |
| 46 | ✓ |
| 47 | ✗ |
| 48 | ✗ |
| 49 | ✗ |
| 50 | ✗ |
| 51 | - |
| 52 | - |
| 53 | - |
| 54 | - |
| 55 | - |
| 56 | - |
| 57 | - |
| 58 | - |
| 59 | - |
| 60 | - |
| 61 | - |
| 62 | - |
| 63 | - |
| 64 | - |
| 65 | - |
| 66 | - |
| 67 | - |
| 68 | - |
| 69 | - |
| 70 | - |
| 71 | - |
| 72 | - |
| 73 | - |

74 -

75 -

All contents of this site are © 2024 Passmedicine Limited

A 34-year-old woman presents with a rash on her face. She has been feeling generally unwell for around three months with lethargy and has a variety of joint pains

© Image used on license from DermNet NZ

What is the most likely diagnosis?

| | |
|---|---|
| Impetigo | 0% |
| Perioral dermatitis | 1% |
| Sarcoidosis | 1% |
| Acne rosacea | 17% |
| Systemic lupus erythematosus | 81% |

The correct answer is **Systemic lupus erythematosus**. This is a chronic autoimmune disease that can affect any system in the body, including the skin, joints, kidneys, heart and lungs. The classic malar or 'butterfly' rash seen in the image, along with systemic symptoms such as fatigue and arthralgia (joint pain), are characteristic of this condition. The rash typically spares the nasolabial folds. It's important to note that not all patients with lupus will present with this rash.

**Impetigo** is an incorrect answer. Impetigo is a highly contagious skin infection usually caused by *Staphylococcus aureus* or *Streptococcus pyogenes*. It generally presents as honey-coloured crusted lesions on exposed areas of skin and is more common in children. It would not explain this patient's systemic symptoms.

**Perioral dermatitis**, another incorrect option, typically presents as small red papules around the mouth and sometimes around the eyes or nose. The eruptions may be accompanied by mild itching or burning sensation but do not cause systemic symptoms like lethargy and joint pain.

**Sarcoidosis** is also an incorrect answer. While sarcoidosis can affect multiple organs and present with systemic symptoms similar to those described, its cutaneous manifestations are diverse but often include erythema nodosum (red tender nodules usually located on the shins) or specific lesions such as plaques, nodules or scars which look different from the presented image.

Finally, **Acne rosacea** is another incorrect choice. While it does present with facial redness and sometimes pustules similar to acne vulgaris, it primarily affects middle-aged adults and tends to be focused in the central face - cheeks, nose, forehead and chin. Rosacea does not cause systemic symptoms like fatigue or joint pains.

Discuss (2) | Improve

Next question

## Skin disorders associated with SLE

Skin manifestations of systemic lupus erythematosus (SLE)

- photosensitive 'butterfly' rash
- discoid lupus
- alopecia
- livedo reticularis: net-like rash

© Image used on license from DermNet NZ

Note the nasolabial sparing of the malar rash from this woman who has SLE

© Image used on license from DermNet NZ

Note how this image of cutaneous SLE is slightly atypical as it does not have the characteristic nasolabial sparing

+ Q 123

Next question >

## Textbooks

High-yield textbook

Extended textbook

## Links

DermNet NZ 1 3

Systemic lupus erythematosus

DermIS 3 1

Pictures of livedo reticularis

DermNet NZ 1 0

Discoid lupus erythematosus

Suggest link Report broken link

## Media

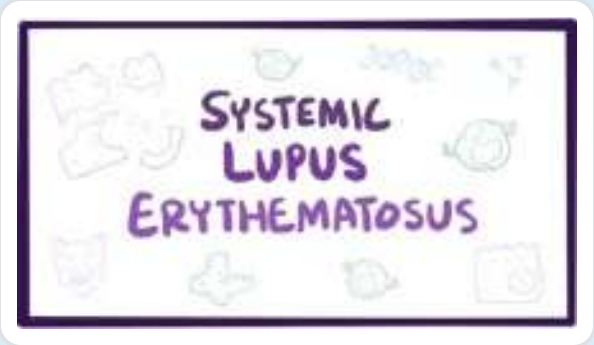


Systemic lupus erythematosus (SLE) - causes, symptoms, diagnosis & pathology

Osmosis - YouTube 1 1

Report broken media

Score: **25.6%**

1 ✗
2 ✓
3 ✓
4 ✗
5 ✗
6 ✗
7 ✗
8 ✗
9 ✗
10 ✗
11 ✗
12 ✗

| | |
|---|---|
| 13 | ✓ |
| 14 | ✓ |
| 15 | ✓ |
| 16 | ✗ |
| 17 | ✓ |
| 18 | ✓ |
| 19 | ✗ |
| 20 | ✗ |
| 21 | ✗ |
| 22 | ✗ |
| 23 | ✗ |
| 24 | ✓ |
| 25 | ✗ |
| 26 | ✓ |
| 27 | ✗ |
| 28 | ✗ |
| 29 | ✗ |
| 30 | ✓ |
| 31 | ✗ |
| 32 | ✗ |
| 33 | ✗ |
| 34 | ✗ |
| 35 | ✓ |
| 36 | ✗ |
| 37 | ✗ |
| 38 | ✗ |
| 39 | ✗ |
| 40 | ✗ |
| 41 | ✗ |
| 42 | ✓ |
| 43 | ✗ |
| 44 | ✗ |
| 45 | ✓ |
| 46 | ✓ |
| 47 | ✗ |
| 48 | ✗ |

| | |
|---|---|
| 49 | ✗ |
| 50 | ✗ |
| 51 | ✗ |
| 52 | ✗ |
| 53 | ✓ |
| 54 | ✗ |
| 55 | ✗ |
| 56 | ✗ |
| 57 | ✗ |
| 58 | ✗ |
| 59 | ✗ |
| 60 | ✗ |
| 61 | ✗ |
| 62 | ✓ |
| 63 | ✗ |
| 64 | ✓ |
| 65 | ✗ |
| 66 | ✓ |
| 67 | ✓ |
| 68 | ✗ |
| 69 | ✗ |
| 70 | ✗ |
| 71 | ✗ |
| 72 | ✗ |
| 73 | ✗ |
| 74 | ✗ |
| **75** | ✓ |
| 76 | ✗ |
| 77 | ✗ |
| 78 | ✗ |
| 79 | ✗ |
| 80 | ✗ |
| 81 | ✗ |
| 82 | ✓ |

All contents of this site are © 2024 Passmedicine Limited

A 29-year-old man presents with a rash on his trunk. Around two weeks ago he describes developing a patch of 'eczema' on his torso the size of 50 pence piece. Around a week later a number of smaller, red patches started to appear as well:

© Image used on license from DermNet NZ

He feels systemically well and has no history of note. What is the most likely diagnosis?

- Erythema multiforme
- Lichen planus
- Pityriasis rosea
- Guttate psoriasis
- Tinea corporis

Submit answer

Reference ranges

Score: **28%**

| | |
|---|---|
| 1 | ✗ |
| 2 | ✓ |
| 3 | ✓ |
| 4 | ✗ |
| 5 | ✗ |
| 6 | ✗ |
| 7 | ✗ |
| 8 | ✗ |
| 9 | ✗ |
| 10 | ✗ |
| 11 | ✗ |
| 12 | ✗ |
| 13 | ✓ |
| 14 | ✓ |
| 15 | ✓ |
| 16 | ✗ |
| 17 | ✓ |
| 18 | ✓ |
| 19 | ✗ |
| 20 | ✗ |
| 21 | ✗ |
| 22 | ✗ |
| 23 | ✗ |
| 24 | ✓ |
| 25 | ✗ |
| 26 | ✓ |
| 27 | ✗ |
| 28 | ✗ |
| 29 | ✗ |
| 30 | ✓ |
| 31 | ✗ |
| 32 | ✗ |
| 33 | ✗ |
| 34 | ✗ |

| | |
|---|---|
| 35 | ✓ |
| 36 | ✗ |
| 37 | ✗ |
| 38 | ✗ |
| 39 | ✗ |
| 40 | ✗ |
| 41 | ✗ |
| 42 | ✓ |
| 43 | ✗ |
| 44 | ✗ |
| 45 | ✓ |
| 46 | ✓ |
| 47 | ✗ |
| 48 | ✗ |
| 49 | ✗ |
| 50 | ✗ |
| 51 | - |
| 52 | - |
| 53 | - |
| 54 | - |
| 55 | - |
| 56 | - |
| 57 | - |
| 58 | - |
| 59 | - |
| 60 | - |
| 61 | - |
| 62 | - |
| 63 | - |
| 64 | - |
| 65 | - |
| 66 | - |
| 67 | - |
| 68 | - |
| 69 | - |
| 70 | - |
| 71 | - |
| 72 | - |

73 -
74 -
75 -
**76** -

All contents of this site are © 2024 Passmedicine Limited

A 29-year-old man presents with a rash on his trunk. Around two weeks ago he describes developing a patch of 'eczema' on his torso the size of 50 pence piece. Around a week later a number of smaller, red patches started to appear as well:

© Image used on license from DermNet NZ

He feels systemically well and has no history of note. What is the most likely diagnosis?

- Erythema multiforme 8%
- Lichen planus 2%
- Pityriasis rosea 76%
- Guttate psoriasis 13%
- Tinea corporis 2%

The earlier lesion represents a classical herald patch. Guttate psoriasis is generally has a more homogeneous, 'teardrop' appearance with a more pronounced scale. This image demonstrates the 'fir tree' appearance often seen in patients with pityriasis rosea.

Discuss Improve

Next question

## Pityriasis rosea

Pityriasis rosea describes an acute, self-limiting rash which tends to affect young adults. The aetiology is not fully understood but is thought that herpes hominis virus 7 (HHV-7) may play a role.

Features

- in the majority of patients there is no prodrome, but a minority may give a history of a recent viral infection
- herald patch (usually on trunk)
- followed by erythematous, oval, scaly patches which follow a characteristic distribution with the longitudinal diameters of the oval lesions running parallel to the line of Langer. This may produce a 'fir-tree' appearance

Management

- self-limiting - usually disappears after 6-12 weeks

## Differentiating guttate psoriasis and pityriasis rosea

| | Guttate psoriasis | Pityriasis rosea |
|---|---|---|
| **Prodrome** | Classically preceded by a streptococcal sore throat 2-4 weeks | Many patients report recent respiratory tract infections but this is not common in questions |
| **Appearance** | 'Tear drop', scaly papules on the trunk and limbs | Herald patch followed 1-2 weeks later by multiple erythematous, slightly raised oval lesions with a fine scale confined to the outer aspects of the lesions.<br><br>May follow a characteristic distribution with the longitudinal diameters of the oval lesions running parallel to the line of Langer. This may produce a 'fir-tree' appearance |
| **Treatment / natural history** | Most cases resolve spontaneously within 2-3 months<br>Topical agents as per psoriasis<br>UVB phototherapy | Self-limiting, resolves after around 6 weeks |

+ Q 123

Next question >

**Textbooks**

High-yield textbook

Extended textbook

**Links**

Clinical Knowledge Summaries 9 6

Pityriasis rosea

DermNet NZ 11 4

Pityriasis rosea

Suggest link Report broken link

Score: **25.6%**

| | |
|---|---|
| 1 | ✗ |
| 2 | ✓ |
| 3 | ✓ |
| 4 | ✗ |
| 5 | ✗ |
| 6 | ✗ |
| 7 | ✗ |
| 8 | ✗ |
| 9 | ✗ |
| 10 | ✗ |
| 11 | ✗ |
| 12 | ✗ |
| 13 | ✓ |
| 14 | ✓ |
| 15 | ✓ |
| 16 | ✗ |
| 17 | ✓ |
| 18 | ✓ |
| 19 | ✗ |
| 20 | ✗ |
| 21 | ✗ |
| 22 | ✗ |
| 23 | ✗ |

| | |
|---|---|
| 24 | ✓ |
| 25 | ✗ |
| 26 | ✓ |
| 27 | ✗ |
| 28 | ✗ |
| 29 | ✗ |
| 30 | ✓ |
| 31 | ✗ |
| 32 | ✗ |
| 33 | ✗ |
| 34 | ✗ |
| 35 | ✓ |
| 36 | ✗ |
| 37 | ✗ |
| 38 | ✗ |
| 39 | ✗ |
| 40 | ✗ |
| 41 | ✗ |
| 42 | ✓ |
| 43 | ✗ |
| 44 | ✗ |
| 45 | ✓ |
| 46 | ✓ |
| 47 | ✗ |
| 48 | ✗ |
| 49 | ✗ |
| 50 | ✗ |
| 51 | ✗ |
| 52 | ✗ |
| 53 | ✓ |
| 54 | ✗ |
| 55 | ✗ |
| 56 | ✗ |
| 57 | ✗ |
| 58 | ✗ |
| 59 | ✗ |

| | |
|---|---|
| 60 | ✗ |
| 61 | ✗ |
| 62 | ✓ |
| 63 | ✗ |
| 64 | ✓ |
| 65 | ✗ |
| 66 | ✓ |
| 67 | ✓ |
| 68 | ✗ |
| 69 | ✗ |
| 70 | ✗ |
| 71 | ✗ |
| 72 | ✗ |
| 73 | ✗ |
| 74 | ✗ |
| 75 | ✓ |
| **76** | ✗ |
| 77 | ✗ |
| 78 | ✗ |
| 79 | ✗ |
| 80 | ✗ |
| 81 | ✗ |
| 82 | ✓ |

All contents of this site are © 2024 Passmedicine Limited

Back to top

A 74-year-old man develops a painful blistering skin rash on his abdomen. He also complains of a sore throat, pain on swallowing and ulceration of the mouth:

© Image used on license from DermNet NZ

What is the most appropriate treatment?

- Oral prednisolone
- Supportive treatment only
- Intravenous flucloxacillin
- Oral dapsone
- Intravenous aciclovir

Submit answer

Reference ranges

Score: **28%**

| | |
|---|---|
| 1 | ✗ |
| 2 | ✓ |
| 3 | ✓ |
| 4 | ✗ |
| 5 | ✗ |
| 6 | ✗ |
| 7 | ✗ |
| 8 | ✗ |
| 9 | ✗ |
| 10 | ✗ |
| 11 | ✗ |
| 12 | ✗ |
| 13 | ✓ |
| 14 | ✓ |
| 15 | ✓ |
| 16 | ✗ |
| 17 | ✓ |
| 18 | ✓ |
| 19 | ✗ |
| 20 | ✗ |
| 21 | ✗ |
| 22 | ✗ |
| 23 | ✗ |
| 24 | ✓ |
| 25 | ✗ |
| 26 | ✓ |
| 27 | ✗ |
| 28 | ✗ |
| 29 | ✗ |
| 30 | ✓ |

| | |
|---|---|
| 31 | ✗ |
| 32 | ✗ |
| 33 | ✗ |
| 34 | ✗ |
| 35 | ✓ |
| 36 | ✗ |
| 37 | ✗ |
| 38 | ✗ |
| 39 | ✗ |
| 40 | ✗ |
| 41 | ✗ |
| 42 | ✓ |
| 43 | ✗ |
| 44 | ✗ |
| 45 | ✓ |
| 46 | ✓ |
| 47 | ✗ |
| 48 | ✗ |
| 49 | ✗ |
| 50 | ✗ |
| 51 | - |
| 52 | - |
| 53 | - |
| 54 | - |
| 55 | - |
| 56 | - |
| 57 | - |
| 58 | - |
| 59 | - |
| 60 | - |
| 61 | - |
| 62 | - |
| 63 | - |
| 64 | - |
| 65 | - |
| 66 | - |
| 67 | - |
| 68 | - |

69 -
70 -
71 -
72 -
73 -
74 -
75 -
76 -
**77** -

All contents of this site are © 2024 Passmedicine Limited

A 74-year-old man develops a painful blistering skin rash on his abdomen. He also complains of a sore throat, pain on swallowing and ulceration of the mouth:

© Image used on license from DermNet NZ

What is the most appropriate treatment?

| | |
|---|---|
| Oral prednisolone | 74% |
| Supportive treatment only | 7% |
| Intravenous flucloxacillin | 9% |
| Oral dapsone | 4% |
| Intravenous aciclovir | 5% |

Systemic glucocorticoids are the first-line treatment in pemphigus vulgaris

Important for me Less important

This patient has developed pemphigus vulgaris which is treated in the first instance by corticosteroids.

Discuss (3) Improve

Next question

## Pemphigus vulgaris

Pemphigus vulgaris is an autoimmune disease caused by antibodies directed against desmoglein 3, a cadherin-type epithelial cell adhesion molecule. It is more common in the Ashkenazi Jewish population.

Features

- mucosal ulceration is common and often the presenting symptom. Oral involvement is seen in 50-70% of patients
- skin blistering - flaccid, easily ruptured vesicles and bullae. Lesions are typically painful but not itchy. These may develop months after the initial mucosal symptoms. Nikolsky's describes the spread of bullae following application of horizontal, tangential pressure to the skin
- acantholysis on biopsy

Management

- steroids are first-line
- immunosuppressants

Next question

## Textbooks

High-yield textbook

Extended textbook

## Links

British Association of Dermatologists 7 2

2017 Guidelines for the management of pemphigus vulgaris

DermNet NZ 9 2

Pemphigus vulgaris

Suggest link Report broken link

## Media

Pemphigus vulgaris

Osmosis - YouTube 3 0

Report broken media

Score: **25.6%**

1 ✕

| | |
|---|---|
| 2 | ✓ |
| 3 | ✓ |
| 4 | ✗ |
| 5 | ✗ |
| 6 | ✗ |
| 7 | ✗ |
| 8 | ✗ |
| 9 | ✗ |
| 10 | ✗ |
| 11 | ✗ |
| 12 | ✗ |
| 13 | ✓ |
| 14 | ✓ |
| 15 | ✓ |
| 16 | ✗ |
| 17 | ✓ |
| 18 | ✓ |
| 19 | ✗ |
| 20 | ✗ |
| 21 | ✗ |
| 22 | ✗ |
| 23 | ✗ |
| 24 | ✓ |
| 25 | ✗ |
| 26 | ✓ |
| 27 | ✗ |
| 28 | ✗ |
| 29 | ✗ |
| 30 | ✓ |
| 31 | ✗ |
| 32 | ✗ |
| 33 | ✗ |
| 34 | ✗ |
| 35 | ✓ |
| 36 | ✗ |
| 37 | ✗ |

| | |
|---|---|
| 38 | ✗ |
| 39 | ✗ |
| 40 | ✗ |
| 41 | ✗ |
| 42 | ✓ |
| 43 | ✗ |
| 44 | ✗ |
| 45 | ✓ |
| 46 | ✓ |
| 47 | ✗ |
| 48 | ✗ |
| 49 | ✗ |
| 50 | ✗ |
| 51 | ✗ |
| 52 | ✗ |
| 53 | ✓ |
| 54 | ✗ |
| 55 | ✗ |
| 56 | ✗ |
| 57 | ✗ |
| 58 | ✗ |
| 59 | ✗ |
| 60 | ✗ |
| 61 | ✗ |
| 62 | ✓ |
| 63 | ✗ |
| 64 | ✓ |
| 65 | ✗ |
| 66 | ✓ |
| 67 | ✓ |
| 68 | ✗ |
| 69 | ✗ |
| 70 | ✗ |
| 71 | ✗ |
| 72 | ✗ |
| 73 | ✗ |

| | |
|---|---|
| 74 | ✗ |
| 75 | ✓ |
| 76 | ✗ |
| **77** | ✗ |
| 78 | ✗ |
| 79 | ✗ |
| 80 | ✗ |
| 81 | ✗ |
| 82 | ✓ |

All contents of this site are © 2024 Passmedicine Limited

Back to top

PassMedicine



A 29-year-old man present to the emergency department with a painful rash and fever. He was recently treated by his GP for a chest infection with oral amoxicillin. He found that his cough was improving but then noticed a painful rash. This was followed by a fever, joint pain and feeling generally unwell. On examination, he has a maculopapular rash with target lesions, mucosal erosions and blistering lesions including within his oral cavity. His chest is clear on examination. What timing of exposure is most consistent with Stevens-Johnson syndrome?

- Within minutes
- Within 24 hours
- Within 3-5 days
- Within 1-4 weeks
- Within 4-8 weeks

Submit answer

Reference ranges

Score: **28%**

| | |
|---|---|
| 1 | ✗ |
| 2 | ✓ |
| 3 | ✓ |
| 4 | ✗ |
| 5 | ✗ |
| 6 | ✗ |
| 7 | ✗ |
| 8 | ✗ |

9 ✗
10 ✗
11 ✗
12 ✗
13 ✓
14 ✓
15 ✓
16 ✗
17 ✓
18 ✓
19 ✗
20 ✗
21 ✗
22 ✗
23 ✗
24 ✓
25 ✗
26 ✓
27 ✗
28 ✗
29 ✗
30 ✓
31 ✗
32 ✗
33 ✗
34 ✗
35 ✓
36 ✗
37 ✗
38 ✗
39 ✗
40 ✗
41 ✗
42 ✓
43 ✗
44 ✗

| | |
|---|---|
| 45 | ✓ |
| 46 | ✓ |
| 47 | ✗ |
| 48 | ✗ |
| 49 | ✗ |
| 50 | ✗ |
| 51 | - |
| 52 | - |
| 53 | - |
| 54 | - |
| 55 | - |
| 56 | - |
| 57 | - |
| 58 | - |
| 59 | - |
| 60 | - |
| 61 | - |
| 62 | - |
| 63 | - |
| 64 | - |
| 65 | - |
| 66 | - |
| 67 | - |
| 68 | - |
| 69 | - |
| 70 | - |
| 71 | - |
| 72 | - |
| 73 | - |
| 74 | - |
| 75 | - |
| 76 | - |
| 77 | - |
| **78** | - |

All contents of this site are © 2024 Passmedicine Limited

Back to top

A 29-year-old man present to the emergency department with a painful rash and fever. He was recently treated by his GP for a chest infection with oral amoxicillin. He found that his cough was improving but then noticed a painful rash. This was followed by a fever, joint pain and feeling generally unwell. On examination, he has a maculopapular rash with target lesions, mucosal erosions and blistering lesions including within his oral cavity. His chest is clear on examination. What timing of exposure is most consistent with Stevens-Johnson syndrome?

| | |
|---|---|
| Within minutes | 1% |
| Within 24 hours | 29% |
| Within 3-5 days | 42% |
| Within 1-4 weeks | 23% |
| Within 4-8 weeks | 4% |

The correct answer is within 1-4 weeks. This patient has taken amoxicillin and subsequently developed a severe reaction. The description of a maculopapular rash with blistering lesions, oral involvement, fever and joint pain is all in keeping with Stevens-Johnson syndrome (SJS). SJS can occur within 1-4 weeks days of first drug exposure, and on average occurs at 14 days. In some cases, secondary exposure can lead to an earlier reaction within 48 hours but is more unusual. Another possibility is that it is secondary to Mycoplasma or Streptococcal infection. Drug reaction with eosinophilia and systemic symptoms usually occur within 2-6 weeks, whilst acute generalised exanthematous pustulosis occurs within 3-5 days.

Discuss (1) Improve

Next question

## Stevens-Johnson syndrome

Stevens-Johnson syndrome is a severe systemic reaction affecting the skin and mucosa that is almost always caused by a drug reaction.

Previously it was thought that Stevens-Johnson syndrome (SJS) was a severe form of erythema multiforme. They are now however considered as separate entities.

Causes

- penicillin
- sulphonamides
- lamotrigine, carbamazepine, phenytoin
- allopurinol
- NSAIDs
- oral contraceptive pill

Features

- the rash is typically maculopapular with target lesions being characteristic
  - may develop into vesicles or bullae
  - Nikolsky sign is positive in erythematous areas - blisters and erosions appear when the skin is rubbed gently
- mucosal involvement
- systemic symptoms: fever, arthralgia

Management

- hospital admission is required for supportive treatment

+ Q 123

Next question >

B I A

Textbooks

High-yield textbook

Extended textbook

## Links

British Association of Dermatologists 5 7

2016 UK guidelines for the management of Stevens-Johnson syndrome/toxic epidermal necrolysis

Suggest link Report broken link

## Media

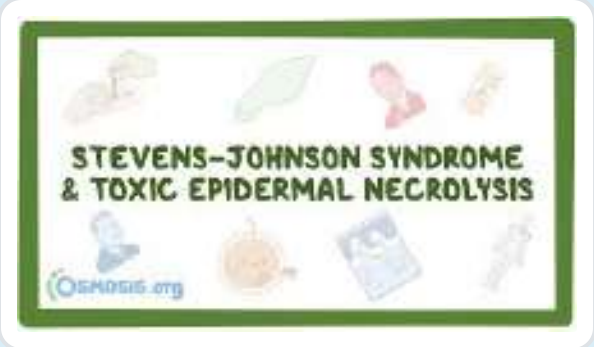


Stevensâ€"Johnson Syndrome & Toxic Epidermal Necrolysis

Osmosis - YouTube 2 0

Understanding Stevens-Johnson Syndrome and Toxic Epidermal Necrolysis

Osmosis - YouTube 0 0

Report broken media

Score: **25.6%**

1 ✗
2 ✓
3 ✓
4 ✗
5 ✗
6 ✗
7 ✗
8 ✗
9 ✗

| | |
|---|---|
| 10 | ✗ |
| 11 | ✗ |
| 12 | ✗ |
| 13 | ✓ |
| 14 | ✓ |
| 15 | ✓ |
| 16 | ✗ |
| 17 | ✓ |
| 18 | ✓ |
| 19 | ✗ |
| 20 | ✗ |
| 21 | ✗ |
| 22 | ✗ |
| 23 | ✗ |
| 24 | ✓ |
| 25 | ✗ |
| 26 | ✓ |
| 27 | ✗ |
| 28 | ✗ |
| 29 | ✗ |
| 30 | ✓ |
| 31 | ✗ |
| 32 | ✗ |
| 33 | ✗ |
| 34 | ✗ |
| 35 | ✓ |
| 36 | ✗ |
| 37 | ✗ |
| 38 | ✗ |
| 39 | ✗ |
| 40 | ✗ |
| 41 | ✗ |
| 42 | ✓ |
| 43 | ✗ |
| 44 | ✗ |
| 45 | ✓ |

46 ✓
47 ✗
48 ✗
49 ✗
50 ✗
51 ✗
52 ✗
53 ✓
54 ✗
55 ✗
56 ✗
57 ✗
58 ✗
59 ✗
60 ✗
61 ✗
62 ✓
63 ✗
64 ✓
65 ✗
66 ✓
67 ✓
68 ✗
69 ✗
70 ✗
71 ✗
72 ✗
73 ✗
74 ✗
75 ✓
76 ✗
77 ✗
**78** ✗
79 ✗
80 ✗
81 ✗

82 ✓

All contents of this site are © 2024 Passmedicine Limited

PassMedicine



You are asked to look at some skin lesions on a patient who has been admitted with an infective exacerbation of COPD.

© Image used on license from DermNet NZ

These skin lesions have been present for the past year. What is the most likely diagnosis?

- Multiple basal cell carcinomas
- Squamous cell carcinoma
- Actinic keratoses
- Seborrhoeic dermatitis
- Seborrhoeic keratoses

Submit answer

Reference ranges

Score: **28%**

| | |
|---|---|
| 1 | ✗ |
| 2 | ✓ |
| 3 | ✓ |
| 4 | ✗ |
| 5 | ✗ |
| 6 | ✗ |
| 7 | ✗ |
| 8 | ✗ |
| 9 | ✗ |
| 10 | ✗ |
| 11 | ✗ |
| 12 | ✗ |
| 13 | ✓ |
| 14 | ✓ |
| 15 | ✓ |
| 16 | ✗ |
| 17 | ✓ |
| 18 | ✓ |
| 19 | ✗ |
| 20 | ✗ |
| 21 | ✗ |
| 22 | ✗ |
| 23 | ✗ |
| 24 | ✓ |
| 25 | ✗ |
| 26 | ✓ |
| 27 | ✗ |
| 28 | ✗ |
| 29 | ✗ |
| 30 | ✓ |
| 31 | ✗ |
| 32 | ✗ |
| 33 | ✗ |

| | |
|---|---|
| 34 | ✗ |
| 35 | ✓ |
| 36 | ✗ |
| 37 | ✗ |
| 38 | ✗ |
| 39 | ✗ |
| 40 | ✗ |
| 41 | ✗ |
| 42 | ✓ |
| 43 | ✗ |
| 44 | ✗ |
| 45 | ✓ |
| 46 | ✓ |
| 47 | ✗ |
| 48 | ✗ |
| 49 | ✗ |
| 50 | ✗ |
| 51 | - |
| 52 | - |
| 53 | - |
| 54 | - |
| 55 | - |
| 56 | - |
| 57 | - |
| 58 | - |
| 59 | - |
| 60 | - |
| 61 | - |
| 62 | - |
| 63 | - |
| 64 | - |
| 65 | - |
| 66 | - |
| 67 | - |
| 68 | - |
| 69 | - |
| 70 | - |
| 71 | - |

| | |
|---|---|
| 72 | - |
| 73 | - |
| 74 | - |
| 75 | - |
| 76 | - |
| 77 | - |
| 78 | - |
| **79** | - |

All contents of this site are © 2024 Passmedicine Limited

You are asked to look at some skin lesions on a patient who has been admitted with an infective exacerbation of COPD.

© Image used on license from DermNet NZ

These skin lesions have been present for the past year. What is the most likely diagnosis?

| | |
|---|---|
| Multiple basal cell carcinomas | 2% |
| Squamous cell carcinoma | 3% |
| Actinic keratoses | 64% |
| Seborrhoeic dermatitis | 16% |
| Seborrhoeic keratoses | 15% |

Discuss (5) Improve

Next question

# Actinic keratoses

Actinic, or solar, keratoses (AK) is a common premalignant skin lesion that develops as a consequence of chronic sun exposure

Features

- small, crusty or scaly, lesions
- may be pink, red, brown or the same colour as the skin
- typically on sun-exposed areas e.g. temples of head
- multiple lesions may be present

Management options include

- prevention of further risk: e.g. sun avoidance, sun cream
- fluorouracil cream: typically a 2 to 3 week course. The skin will become red and inflamed - sometimes topical hydrocortisone is given following fluorouracil to help settle the inflammation
- topical diclofenac: may be used for mild AKs. Moderate efficacy but much fewer side-effects
- topical imiquimod: trials have shown good efficacy
- cryotherapy
- curettage and cautery

123

Next question ›

**Textbooks**

High-yield textbook

Extended textbook

**Links**

British Association of Dermatologists 9 9

2017 Actinic keratoses guidelines

DermNet NZ 27 11

Actinic keratoses

Primary Care Dermatology Society 14 5

Actinic keratosis

Suggest link

Report broken link

Score: **25.6%**

| | |
|---|---|
| 1 | ✗ |
| 2 | ✓ |
| 3 | ✓ |
| 4 | ✗ |
| 5 | ✗ |
| 6 | ✗ |
| 7 | ✗ |
| 8 | ✗ |
| 9 | ✗ |
| 10 | ✗ |
| 11 | ✗ |
| 12 | ✗ |
| 13 | ✓ |

| | |
|---|---|
| 14 | ✓ |
| 15 | ✓ |
| 16 | ✗ |
| 17 | ✓ |
| 18 | ✓ |
| 19 | ✗ |
| 20 | ✗ |
| 21 | ✗ |
| 22 | ✗ |
| 23 | ✗ |
| 24 | ✓ |
| 25 | ✗ |
| 26 | ✓ |
| 27 | ✗ |
| 28 | ✗ |
| 29 | ✗ |
| 30 | ✓ |
| 31 | ✗ |
| 32 | ✗ |
| 33 | ✗ |
| 34 | ✗ |
| 35 | ✓ |
| 36 | ✗ |
| 37 | ✗ |
| 38 | ✗ |
| 39 | ✗ |
| 40 | ✗ |
| 41 | ✗ |
| 42 | ✓ |
| 43 | ✗ |
| 44 | ✗ |
| 45 | ✓ |
| 46 | ✓ |
| 47 | ✗ |
| 48 | ✗ |
| 49 | ✗ |

| | |
|---|---|
| 50 | ✗ |
| 51 | ✗ |
| 52 | ✗ |
| 53 | ✓ |
| 54 | ✗ |
| 55 | ✗ |
| 56 | ✗ |
| 57 | ✗ |
| 58 | ✗ |
| 59 | ✗ |
| 60 | ✗ |
| 61 | ✗ |
| 62 | ✓ |
| 63 | ✗ |
| 64 | ✓ |
| 65 | ✗ |
| 66 | ✓ |
| 67 | ✓ |
| 68 | ✗ |
| 69 | ✗ |
| 70 | ✗ |
| 71 | ✗ |
| 72 | ✗ |
| 73 | ✗ |
| 74 | ✗ |
| 75 | ✓ |
| 76 | ✗ |
| 77 | ✗ |
| 78 | ✗ |
| **79** | ✗ |
| 80 | ✗ |
| 81 | ✗ |
| 82 | ✓ |

All contents of this site are © 2024 Passmedicine Limited

Back to top

A 62-year-old woman presents with painful 'bruises' on her shins and forearms.

© Image used on license from DermNet NZ

She cannot remember knocking herself. What is the most likely diagnosis?

- Idiopathic thrombocytopenic purpura
- Erythema ab igne
- Thrombotic thrombocytopenic purpura
- Erythema nodosum
- Cellulitis

Submit answer

Reference ranges

Score: **28%**

| | |
|---|---|
| 1 | ✗ |
| 2 | ✓ |
| 3 | ✓ |
| 4 | ✗ |
| 5 | ✗ |
| 6 | ✗ |
| 7 | ✗ |
| 8 | ✗ |
| 9 | ✗ |
| 10 | ✗ |
| 11 | ✗ |
| 12 | ✗ |
| 13 | ✓ |
| 14 | ✓ |
| 15 | ✓ |
| 16 | ✗ |
| 17 | ✓ |
| 18 | ✓ |
| 19 | ✗ |
| 20 | ✗ |
| 21 | ✗ |
| 22 | ✗ |
| 23 | ✗ |
| 24 | ✓ |
| 25 | ✗ |
| 26 | ✓ |
| 27 | ✗ |
| 28 | ✗ |
| 29 | ✗ |
| 30 | ✓ |

| | |
|---|---|
| 31 | ✗ |
| 32 | ✗ |
| 33 | ✗ |
| 34 | ✗ |
| 35 | ✓ |
| 36 | ✗ |
| 37 | ✗ |
| 38 | ✗ |
| 39 | ✗ |
| 40 | ✗ |
| 41 | ✗ |
| 42 | ✓ |
| 43 | ✗ |
| 44 | ✗ |
| 45 | ✓ |
| 46 | ✓ |
| 47 | ✗ |
| 48 | ✗ |
| 49 | ✗ |
| 50 | ✗ |
| 51 | - |
| 52 | - |
| 53 | - |
| 54 | - |
| 55 | - |
| 56 | - |
| 57 | - |
| 58 | - |
| 59 | - |
| 60 | - |
| 61 | - |
| 62 | - |
| 63 | - |
| 64 | - |
| 65 | - |
| 66 | - |
| 67 | - |
| 68 | - |

69 -
70 -
71 -
72 -
73 -
74 -
75 -
76 -
77 -
78 -
79 -
**80** -

All contents of this site are © 2024 Passmedicine Limited

A 62-year-old woman presents with painful 'bruises' on her shins and forearms.

© Image used on license from DermNet NZ

She cannot remember knocking herself. What is the most likely diagnosis?

| | |
|---|---|
| Idiopathic thrombocytopenic purpura | 3% |
| Erythema ab igne | 4% |
| Thrombotic thrombocytopenic purpura | 1% |
| Erythema nodosum | 91% |
| Cellulitis | 0% |

The most likely diagnosis for this 62-year-old woman presenting with painful 'bruises' on her shins

and forearms is **Erythema nodosum**. Erythema nodosum is a type of panniculitis, or inflammation of the subcutaneous fat. It presents as tender, erythematous nodules typically located on the anterior shins but can also appear on the forearms. The condition may occur spontaneously or be associated with systemic diseases such as sarcoidosis, inflammatory bowel disease or streptococcal infection.

**Idiopathic thrombocytopenic purpura (ITP)** is an autoimmune disorder characterised by low platelet count leading to easy bruising and excessive bleeding. However, the bruises in ITP are usually not painful which makes it less likely in this case.

**Erythema ab igne** is a skin condition caused by prolonged exposure to heat or infrared radiation. It presents as mottled, erythematous patches that can become permanent if exposure continues. Given that the patient does not report any relevant exposures and the lesions are painful rather than asymptomatic, this diagnosis would be less likely.

**Thrombotic thrombocytopenic purpura (TTP)** is a rare blood disorder that causes blood clots to form in small blood vessels throughout the body. This can lead to serious problems if left untreated such as kidney failure and stroke. The bruises seen in TTP are similar to those seen in ITP - they are usually not painful and often accompanied by other symptoms like fatigue, fever, confusion which have not been reported in this case.

Lastly, **Cellulitis** is an infection of the deeper layers of skin and underlying tissue. It causes redness and swelling on affected areas of skin which are warm to touch due to inflammation caused by bacteria (most commonly Group A Streptococcus or Staphylococcus aureus). Cellulitis typically affects one side of the body, unlike our case where both shins and forearms are involved hence making it less likely.

Discuss (2) | Improve

Next question ›

## Erythema nodosum

Overview
- inflammation of subcutaneous fat
- typically causes tender, erythematous, nodular lesions
- usually occurs over shins, may also occur elsewhere (e.g. forearms, thighs)
- usually resolves within 6 weeks
- lesions heal without scarring

Causes

- infection
  - streptococci
  - tuberculosis
  - brucellosis
- systemic disease
  - sarcoidosis
  - inflammatory bowel disease
  - Behcet's
- malignancy/lymphoma
- drugs
  - penicillins
  - sulphonamides
  - combined oral contraceptive pill
- pregnancy

123

Next question

**Textbooks**

High-yield textbook

Extended textbook

**Links**

DermNet NZ

Erythema nodosum

30 14

Suggest link

Report broken link

Score: **25.6%**

| | |
|---|---|
| 1 | ✗ |
| 2 | ✓ |
| 3 | ✓ |
| 4 | ✗ |
| 5 | ✗ |
| 6 | ✗ |
| 7 | ✗ |
| 8 | ✗ |
| 9 | ✗ |
| 10 | ✗ |
| 11 | ✗ |
| 12 | ✗ |
| 13 | ✓ |
| 14 | ✓ |
| 15 | ✓ |
| 16 | ✗ |
| 17 | ✓ |
| 18 | ✓ |
| 19 | ✗ |

| | |
|---|---|
| 20 | ✗ |
| 21 | ✗ |
| 22 | ✗ |
| 23 | ✗ |
| 24 | ✓ |
| 25 | ✗ |
| 26 | ✓ |
| 27 | ✗ |
| 28 | ✗ |
| 29 | ✗ |
| 30 | ✓ |
| 31 | ✗ |
| 32 | ✗ |
| 33 | ✗ |
| 34 | ✗ |
| 35 | ✓ |
| 36 | ✗ |
| 37 | ✗ |
| 38 | ✗ |
| 39 | ✗ |
| 40 | ✗ |
| 41 | ✗ |
| 42 | ✓ |
| 43 | ✗ |
| 44 | ✗ |
| 45 | ✓ |
| 46 | ✓ |
| 47 | ✗ |
| 48 | ✗ |
| 49 | ✗ |
| 50 | ✗ |
| 51 | ✗ |
| 52 | ✗ |
| 53 | ✓ |
| 54 | ✗ |
| 55 | ✗ |

| | |
|---|---|
| 56 | ✗ |
| 57 | ✗ |
| 58 | ✗ |
| 59 | ✗ |
| 60 | ✗ |
| 61 | ✗ |
| 62 | ✓ |
| 63 | ✗ |
| 64 | ✓ |
| 65 | ✗ |
| 66 | ✓ |
| 67 | ✓ |
| 68 | ✗ |
| 69 | ✗ |
| 70 | ✗ |
| 71 | ✗ |
| 72 | ✗ |
| 73 | ✗ |
| 74 | ✗ |
| 75 | ✓ |
| 76 | ✗ |
| 77 | ✗ |
| 78 | ✗ |
| 79 | ✗ |
| **80** | ✗ |
| 81 | ✗ |
| 82 | ✓ |

All contents of this site are © 2024 Passmedicine Limited

Back to top

A 24 year-old gentleman is referred for your opinion from the Emergency Department. He presented with his first tonic-clonic seizure. A CT scan of his head shows a contrast enhancing lesion in the left frontal lobe. On taking a history you elicit that he has been having recurrent nosebleeds and dark stools for the past 12 months.

What is the likely unifying diagnosis?

- Peutz Jeghers syndrome
- Hereditary haemorrhagic telangiectasia
- Tuberous sclerosis
- Von Willebrand disease
- Neurofibromatosis - type 2

Submit answer

Reference ranges

Score: **28%**

| | |
|---|---|
| 1 | ✗ |
| 2 | ✓ |
| 3 | ✓ |
| 4 | ✗ |
| 5 | ✗ |
| 6 | ✗ |
| 7 | ✗ |
| 8 | ✗ |

| | |
|---|---|
| 9 | ✗ |
| 10 | ✗ |
| 11 | ✗ |
| 12 | ✗ |
| 13 | ✓ |
| 14 | ✓ |
| 15 | ✓ |
| 16 | ✗ |
| 17 | ✓ |
| 18 | ✓ |
| 19 | ✗ |
| 20 | ✗ |
| 21 | ✗ |
| 22 | ✗ |
| 23 | ✗ |
| 24 | ✓ |
| 25 | ✗ |
| 26 | ✓ |
| 27 | ✗ |
| 28 | ✗ |
| 29 | ✗ |
| 30 | ✓ |
| 31 | ✗ |
| 32 | ✗ |
| 33 | ✗ |
| 34 | ✗ |
| 35 | ✓ |
| 36 | ✗ |
| 37 | ✗ |
| 38 | ✗ |
| 39 | ✗ |
| 40 | ✗ |
| 41 | ✗ |
| 42 | ✓ |
| 43 | ✗ |
| 44 | ✗ |

| | |
|---|---|
| 45 | ✓ |
| 46 | ✓ |
| 47 | ✗ |
| 48 | ✗ |
| 49 | ✗ |
| 50 | ✗ |
| 51 | - |
| 52 | - |
| 53 | - |
| 54 | - |
| 55 | - |
| 56 | - |
| 57 | - |
| 58 | - |
| 59 | - |
| 60 | - |
| 61 | - |
| 62 | - |
| 63 | - |
| 64 | - |
| 65 | - |
| 66 | - |
| 67 | - |
| 68 | - |
| 69 | - |
| 70 | - |
| 71 | - |
| 72 | - |
| 73 | - |
| 74 | - |
| 75 | - |
| 76 | - |
| 77 | - |
| 78 | - |
| 79 | - |
| 80 | - |
| **81** | - |

All contents of this site are © 2024 Passmedicine Limited

A 24 year-old gentleman is referred for your opinion from the Emergency Department. He presented with his first tonic-clonic seizure. A CT scan of his head shows a contrast enhancing lesion in the left frontal lobe. On taking a history you elicit that he has been having recurrent nosebleeds and dark stools for the past 12 months.

What is the likely unifying diagnosis?

| | |
|---|---|
| Peutz Jeghers syndrome | 6% |
| Hereditary haemorrhagic telangiectasia | 84% |
| Tuberous sclerosis | 7% |
| Von Willebrand disease | 1% |
| Neurofibromatosis - type 2 | 2% |

This young gentleman is likely to have a diagnosis of hereditary haemorrhagic telangiectasia (HHT). The contrast enhancing lesion on the CT scan represents an arterio-venous malformation. The history of recurrent nosebleeds and melena is typical of HHT and are secondary to telangiectasia on the nasal and gastrointestinal mucosa.

Discuss (3) Improve

Next question

## Hereditary haemorrhagic telangiectasia

Also known as Osler-Weber-Rendu syndrome, hereditary haemorrhagic telangiectasia (HHT) is an autosomal dominant condition characterised by (as the name suggests) multiple telangiectasia over the skin and mucous membranes. Twenty percent of cases occur spontaneously without prior family history.

There are 4 main diagnostic criteria. If the patient has 2 then they are said to have a possible

diagnosis of HHT. If they meet 3 or more of the criteria they are said to have a definite diagnosis of HHT:

- epistaxis : spontaneous, recurrent nosebleeds
- telangiectases: multiple at characteristic sites (lips, oral cavity, fingers, nose)
- visceral lesions: for example gastrointestinal telangiectasia (with or without bleeding), pulmonary arteriovenous malformations (AVM), hepatic AVM, cerebral AVM, spinal AVM
- family history: a first-degree relative with HHT

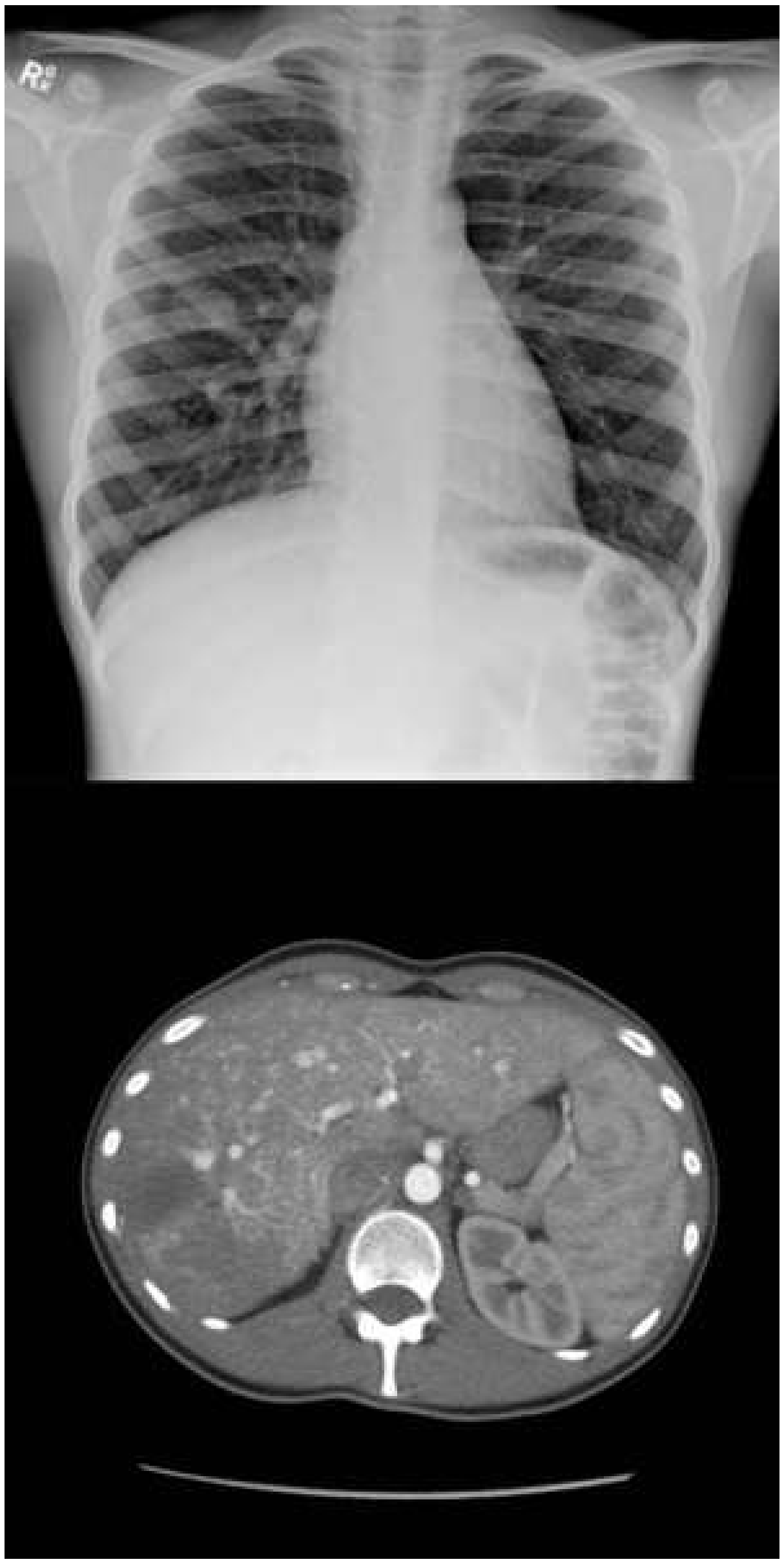

© Image used on license from Radiopaedia

The chest x-ray shows multiple pulmonary nodules representing arteriovenous malformations, the largest in the right mid-zone. The CT scan shows multiple hepatic arteriovenous malformations

Next question

## Textbooks

High-yield textbook

Extended textbook

## Links

DermNet NZ 5 6

Hereditary haemorrhagic telangiectasia

Postgraduate Medical Journal 5 1

Review of HHT

Suggest link Report broken link

Score: **25.6%**

| | |
|---|---|
| 1 | ✗ |
| 2 | ✓ |
| 3 | ✓ |
| 4 | ✗ |
| 5 | ✗ |
| 6 | ✗ |
| 7 | ✗ |
| 8 | ✗ |
| 9 | ✗ |

| | |
|---|---|
| 10 | ✗ |
| 11 | ✗ |
| 12 | ✗ |
| 13 | ✓ |
| 14 | ✓ |
| 15 | ✓ |
| 16 | ✗ |
| 17 | ✓ |
| 18 | ✓ |
| 19 | ✗ |
| 20 | ✗ |
| 21 | ✗ |
| 22 | ✗ |
| 23 | ✗ |
| 24 | ✓ |
| 25 | ✗ |
| 26 | ✓ |
| 27 | ✗ |
| 28 | ✗ |
| 29 | ✗ |
| 30 | ✓ |
| 31 | ✗ |
| 32 | ✗ |
| 33 | ✗ |
| 34 | ✗ |
| 35 | ✓ |
| 36 | ✗ |
| 37 | ✗ |
| 38 | ✗ |
| 39 | ✗ |
| 40 | ✗ |
| 41 | ✗ |
| 42 | ✓ |
| 43 | ✗ |
| 44 | ✗ |
| 45 | ✓ |

| | |
|---|---|
| 46 | ✓ |
| 47 | ✗ |
| 48 | ✗ |
| 49 | ✗ |
| 50 | ✗ |
| 51 | ✗ |
| 52 | ✗ |
| 53 | ✓ |
| 54 | ✗ |
| 55 | ✗ |
| 56 | ✗ |
| 57 | ✗ |
| 58 | ✗ |
| 59 | ✗ |
| 60 | ✗ |
| 61 | ✗ |
| 62 | ✓ |
| 63 | ✗ |
| 64 | ✓ |
| 65 | ✗ |
| 66 | ✓ |
| 67 | ✓ |
| 68 | ✗ |
| 69 | ✗ |
| 70 | ✗ |
| 71 | ✗ |
| 72 | ✗ |
| 73 | ✗ |
| 74 | ✗ |
| 75 | ✓ |
| 76 | ✗ |
| 77 | ✗ |
| 78 | ✗ |
| 79 | ✗ |
| 80 | ✗ |
| **81** | ✗ |

82 ✓

All contents of this site are © 2024 Passmedicine Limited

Back to top

A 70-year-old man presents to the dermatology clinic with a lesion on his lower shin. He noticed the lesion 3 weeks ago after going on a resort holiday in Turkey and wearing shorts for the first time in several months. He denies pain or itch but does think it is getting bigger in size. His past medical history includes ischaemic heart disease and chronic obstructive pulmonary disease.

His lesion is examined, as shown below:

© Image used on license from DermNet NZ

What is the most likely diagnosis?

- Basal cell carcinoma
- Malignant melanoma
- Seborrhoeic keratoses
- Solar lentigo
- Squamous cell carcinoma

Submit answer

Reference ranges

Score: **28%**

| | |
|---|---|
| 1 | ✗ |
| 2 | ✓ |
| 3 | ✓ |
| 4 | ✗ |
| 5 | ✗ |
| 6 | ✗ |
| 7 | ✗ |
| 8 | ✗ |
| 9 | ✗ |
| 10 | ✗ |
| 11 | ✗ |
| 12 | ✗ |
| 13 | ✓ |
| 14 | ✓ |
| 15 | ✓ |
| 16 | ✗ |
| 17 | ✓ |
| 18 | ✓ |
| 19 | ✗ |
| 20 | ✗ |
| 21 | ✗ |
| 22 | ✗ |
| 23 | ✗ |
| 24 | ✓ |
| 25 | ✗ |
| 26 | ✓ |
| 27 | ✗ |
| 28 | ✗ |
| 29 | ✗ |
| 30 | ✓ |

| | |
|---|---|
| 31 | ✗ |
| 32 | ✗ |
| 33 | ✗ |
| 34 | ✗ |
| 35 | ✓ |
| 36 | ✗ |
| 37 | ✗ |
| 38 | ✗ |
| 39 | ✗ |
| 40 | ✗ |
| 41 | ✗ |
| 42 | ✓ |
| 43 | ✗ |
| 44 | ✗ |
| 45 | ✓ |
| 46 | ✓ |
| 47 | ✗ |
| 48 | ✗ |
| 49 | ✗ |
| 50 | ✗ |
| 51 | - |
| 52 | - |
| 53 | - |
| 54 | - |
| 55 | - |
| 56 | - |
| 57 | - |
| 58 | - |
| 59 | - |
| 60 | - |
| 61 | - |
| 62 | - |
| 63 | - |
| 64 | - |
| 65 | - |
| 66 | - |
| 67 | - |
| 68 | - |

69 -
70 -
71 -
72 -
73 -
74 -
75 -
76 -
77 -
78 -
79 -
80 -
81 -
**82** -

All contents of this site are © 2024 Passmedicine Limited
Back to top

A 70-year-old man presents to the dermatology clinic with a lesion on his lower shin. He noticed the lesion 3 weeks ago after going on a resort holiday in Turkey and wearing shorts for the first time in several months. He denies pain or itch but does think it is getting bigger in size. His past medical history includes ischaemic heart disease and chronic obstructive pulmonary disease.

His lesion is examined, as shown below:

© Image used on license from DermNet NZ

What is the most likely diagnosis?

| | |
|---|---|
| Basal cell carcinoma | 1% |
| Malignant melanoma | 9% |
| Seborrhoeic keratoses | 76% |
| Solar lentigo | 13% |
| Squamous cell carcinoma | 1% |

**Seborrhoeic keratoses** is correct. This patient has a well-circumscribed pigmented lesion on his shin that appears flat on the skin surface. It also has the appearance of a wart-like texture. This is in keeping with a diagnosis of seborrhoeic keratoses, a benign lesion associated with increasing age, particularly beyond 60 years. Seborrhoeic keratoses often have a 'stuck-on' appearance as

seen with this patient. Treatment is not necessary for the lesions. However, curettage or cryotherapy can be offered for complete removal.

**Basal cell carcinoma** is incorrect. Basal cell carcinoma (BCC) is a locally-invasive cutaneous malignancy that is typically a slow-growing plaque with rolled edges and a smooth surface. They are usually pink or skin-coloured and, therefore, do not represent this patient's lesion.

**Malignant melanoma** is incorrect. Melanoma is a serious differential diagnosis to consider, particularly for pigmented lesions. However, characteristic features of malignant melanoma include asymmetry, irregular borders, bleeding, change in colour, increase in diameter and evolution. In contrast, this patient's lesion is well-circumscribed with no evidence of hyperpigmentation, bleeding, crusting or irregular borders.

**Solar lentigo** is incorrect. Solar lentigo is a benign patch of darkened skin secondary to a local proliferation of melanocytes. This process is triggered by UV radiation, giving solar lentigo the alternative name of 'age spots'. Seborrhoeic keratoses may arise from solar lentigo. However, unlike seborrhoeic keratoses, the skin is not thickened in solar lentigo, only darkened.

**Squamous cell carcinoma** is incorrect. Squamous cell carcinoma (SCC) is an invasive cutaneous malignancy that presents as an enlarging, crusted lesion that may ulcerate and are often tender. SCC typically progresses from actinic keratoses. They are non-melanocytic lesions, making SCC incorrect.

Discuss (1) | Improve

## Seborrhoeic keratoses

Seborrhoeic keratoses are benign epidermal skin lesions seen in older people.

Features
- large variation in colour from flesh to light-brown to black
- have a 'stuck-on' appearance
- keratotic plugs may be seen on the surface

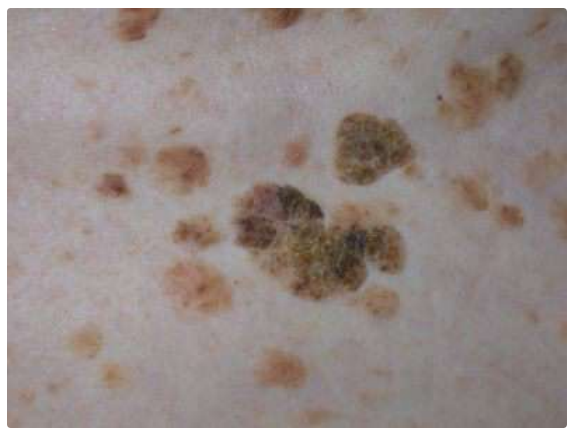

Management

- reassurance about the benign nature of the lesion is an option
- options for removal include curettage, cryosurgery and shave biopsy

123

## Textbooks

High-yield textbook

Extended textbook

## Links

DermNet NZ 5 5

Seborrhoeic keratoses

Suggest link Report broken link

Score: **25.6%**

| | |
|---|---|
| 1 | ✗ |
| 2 | ✓ |
| 3 | ✓ |
| 4 | ✗ |
| 5 | ✗ |
| 6 | ✗ |

| | |
|---|---|
| 7 | ✗ |
| 8 | ✗ |
| 9 | ✗ |
| 10 | ✗ |
| 11 | ✗ |
| 12 | ✗ |
| 13 | ✓ |
| 14 | ✓ |
| 15 | ✓ |
| 16 | ✗ |
| 17 | ✓ |
| 18 | ✓ |
| 19 | ✗ |
| 20 | ✗ |
| 21 | ✗ |
| 22 | ✗ |
| 23 | ✗ |
| 24 | ✓ |
| 25 | ✗ |
| 26 | ✓ |
| 27 | ✗ |
| 28 | ✗ |
| 29 | ✗ |
| 30 | ✓ |
| 31 | ✗ |
| 32 | ✗ |
| 33 | ✗ |
| 34 | ✗ |
| 35 | ✓ |
| 36 | ✗ |
| 37 | ✗ |
| 38 | ✗ |
| 39 | ✗ |
| 40 | ✗ |
| 41 | ✗ |
| 42 | ✓ |

| | |
|---|---|
| 43 | ✗ |
| 44 | ✗ |
| 45 | ✓ |
| 46 | ✓ |
| 47 | ✗ |
| 48 | ✗ |
| 49 | ✗ |
| 50 | ✗ |
| 51 | ✗ |
| 52 | ✗ |
| 53 | ✓ |
| 54 | ✗ |
| 55 | ✗ |
| 56 | ✗ |
| 57 | ✗ |
| 58 | ✗ |
| 59 | ✗ |
| 60 | ✗ |
| 61 | ✗ |
| 62 | ✓ |
| 63 | ✗ |
| 64 | ✓ |
| 65 | ✗ |
| 66 | ✓ |
| 67 | ✓ |
| 68 | ✗ |
| 69 | ✗ |
| 70 | ✗ |
| 71 | ✗ |
| 72 | ✗ |
| 73 | ✗ |
| 74 | ✗ |
| 75 | ✓ |
| 76 | ✗ |
| 77 | ✗ |
| 78 | ✗ |

79 ✗
80 ✗
81 ✗
**82** ✓

All contents of this site are © 2024 Passmedicine Limited